

The authors have nothing to disclose and have no conflicts of interest with regards to any products discussed in this manuscript.

Funded by the Epilepsy Foundation of Arizona and the Mayo School of Continuing Medical Education.

Received January 28, 2003. Accepted in final form March 28, 2003.

Address correspondence and reprint requests to Dr. J.I. Sirven, Department of Neurology, Mayo Clinic Hospital, Epilepsy 5W, 5777 E. Mayo Blvd., Phoenix, AZ 85054; e-mail: sirven.joseph@mayo.edu

Copyright © 2003 by AAN Enterprises, Inc.

## References

1. Eisenberg DM, Davis RB, Ettner SL, et al. Trends in alternative medicine use in the United States, 1990–1997: results of a follow-up national survey. *JAMA* 1998;280:1569–1575.

2. National Center for Complementary and Alternative Medicine. Major domains of complementary and alternative medicine. Available at <http://nccam.nih.gov/nccam/fcp/classify>. Accessed January 20, 2003.

3. Centers for Disease Control and Prevention. National Center for Health Statistics. Available at: <http://www.cdc.gov/nchs/fastats/epilepsy.htm>. Accessed January 20, 2003.

4. Fisher RS, Vickrey BG, Gibson P, et al. The impact of epilepsy from the patient's perspectives, II: views about therapy and health care. *Epilepsy Res* 2000;41:53–61.

5. Ramaratnam S, Sridharan K. Yoga for epilepsy: systematic review. *Cochrane Library* 2002 (issue 4).

6. Ramaratnam S, Baker GA, Goldstein L. Psychological treatments for epilepsy: systematic review. *Cochrane Library* 2002 (issue 4).

7. Morganstern LB, Viscoli CM, Kernan WN, et al. Use of ephedra-containing products and risk for hemorrhagic stroke. *Neurology* 2003;60:132–134.

## Response to sumatriptan in headache of MELAS syndrome

Takahiro Iizuka, MD; Fumihiko Sakai, MD; Motoi Endo, MD; and Norihiro Suzuki, MD

Migraine-like headache is the most common presenting symptom of stroke-like episode in patients with mitochondrial myopathy, encephalopathy, lactic acidosis, and stroke-like episodes (MELAS).<sup>1,2</sup> This study was designed to investigate the mechanism of headache in patients with MELAS and based on our recent report that neuronal hyperexcitability might initiate stroke-like episodes in MELAS.<sup>2</sup>

**Methods.** After obtaining informed consent, sumatriptan 3 mg was subcutaneously injected for intractable headache under serial EKG monitoring in two patients with MELAS, who carried the A3243G transition in transfer RNA<sup>Leu(UUR)</sup> gene, when headache intensity exceeded 8/10 of the Headache Scale. The clinical data obtained from a patient, who received an injection during the stroke-like episode, were compared with those in our series of 15 consecutive stroke-like episodes of six patients with MELAS, who did not receive injections during the episodes.<sup>2,3</sup>

**Results.** The first patient was a 40-year-old woman with incomplete phenotype of MELAS who had never had stroke-like episode but otherwise had typical manifestations. Since age 31, she had headaches characterized by episodic, bilateral, and throbbing pain with moderate or severe intensity and nausea or vomiting. In two bouts of headache, she reported complete resolution of headache within 15 minutes following injection. She had transient chest compression following injection, but no abnormal change on EKG was recorded.

The second patient was a 40-year-old woman with a history of stroke-like episode at age 34. She began to have throbbing pain in the right retro-orbital and temporal area, accompanied by photophobia, nausea, and vomiting. On day 11, she was admitted to our hospital with progressing headache refractory to analgesics. Neurologic examination showed a trigger point at the right supra-orbital notch but was otherwise unremarkable. Diffusion-weighted imaging (DWI) obtained on day 12 showed stroke-like lesion in the right temporal lobe (figure). On day 12, she reported marked improvement of headache within 10 minutes following injection. On day 13, EEG showed mild slowing activities in the right cerebral hemisphere. On day 14, SPECT using a tracer of <sup>99mTc</sup>-D,L-hexamethylpropyleneamine oxime showed focal hyperemia in the right temporoparietal cortex. On day 15, she developed epileptic seizure beginning with focal twitching in the left face, followed by generalized convulsive seizure. Serial DWI showed progressive cortical lesions spreading from the right temporal cortex to the parietal cortex. SPECT on day 28 showed a persistent focal hyperemia in the right parietal cortex.

In the other 15 stroke-like episodes without injection of sumatriptan, epileptic seizure developed in 10 episodes, progressive spreading lesions were seen in 4 of 15 episodes, epileptiform EEG discharges in 10 of 13 episodes, and focal hyperemia in 8 of 11 episodes on SPECT studies.

**Discussion.** Subcutaneous injection of sumatriptan was demonstrated to be very effective for all three bouts of intractable headache in patients with MELAS. No major adverse event developed, but one patient reported transient feeling of chest compression without changes on EKG. This patient's symptom is not likely

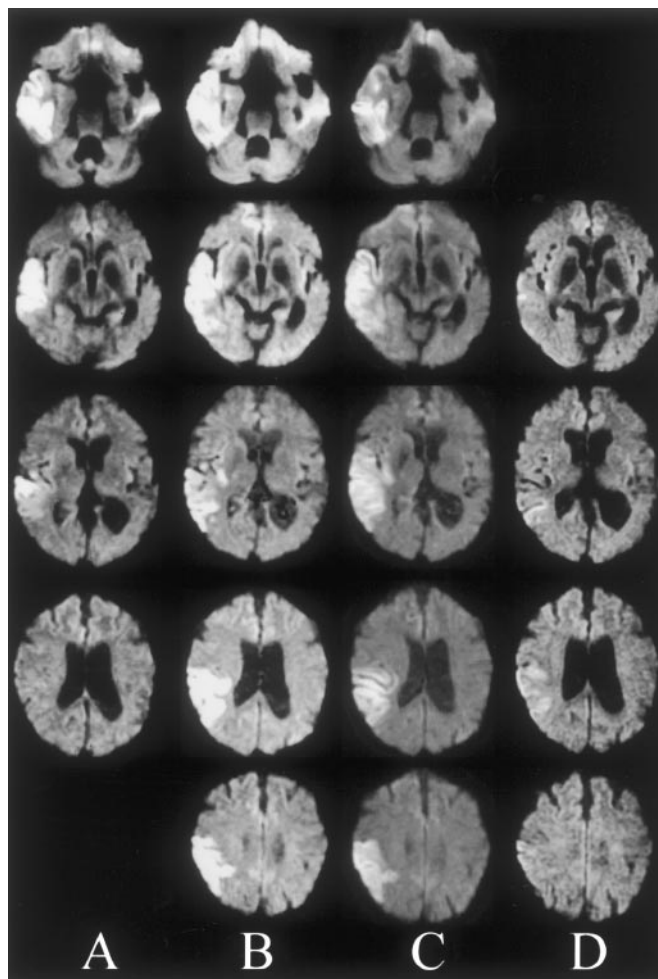


Figure. Serial diffusion-weighted imaging (DWI) obtained from a 40-year-old woman with mitochondrial myopathy, encephalopathy, lactic acidosis, and stroke-like episodes (MELAS) during the progressive stage of stroke-like episode. DWI was performed on day 12 (A), day 17 (B), day 22 (C), and day 52 (D). This patient began to have progressive pain in the right retro-orbital and temporal area. On day 12, she received an injection of sumatriptan, with dramatic improvement of headache. On day 15, she developed generalized convulsive seizure. Serial DWI show a continuous spread of the stroke-like lesion evolving from the right temporal lobe (A) to the surrounding posterior temporal and parietal cortex (B and C).

due to cardiac symptoms because patients with migraine often report similar symptoms following injection not associated with abnormal change on EKG.<sup>4</sup>

Another patient developed epileptic seizure 3 days following injection, but this epileptic seizure does not seem to be due to the direct effect of sumatriptan for the following reasons. First, epileptic seizure could occur at any stage of stroke-like episode. Second, progressive spreading lesions could be seen in 4 of 15 consecutive episodes without association with sumatriptan.<sup>3</sup> Third, a long interval between the injection and onset of epileptic seizure makes the possibility of a causative drug unlikely.

In migraine, sumatriptan is presumed to suppress headache by constricting the dilated vessels of the dura and brain, inhibiting the release of neuropeptides, or inhibiting the propagation of pain signals by C-fibers from the dura and vessel walls.<sup>5,6</sup> It may be too early to state its safety and efficacy in MELAS, and sumatriptan responsiveness may not be specific for migraine<sup>7</sup>; however, based on the current concepts of the pathophysiology of migraine and its pharmacokinetics, its dramatic effect on each severe headache may suggest a possible involvement of the trigeminovascular system in the pathogenesis of headache in MELAS.

Migraine-like headache may develop without stroke-like lesions but could be the first presenting symptom of stroke-like lesions, in which DWI shows early development of vasogenic edema in the corresponding cortex, possibly reflecting mitochondrial dysfunction in the capillary endothelium.<sup>2,3</sup> The resultant hypothesis is that headache as a presenting symptom of stroke-like lesions might be triggered by pericapillary plasma extravasation, leading to the activation of the first division of the trigeminal nerve fibers innervating the small vessels around the stroke-like lesion.

From the Department of Medicine (Neurology), School of Medicine, Kitasato University, Japan.

Presented at the 55th American Academy of Neurology Annual Meeting, April 3, 2003, Honolulu, HI.

Supported in part by a Health and Labour Science Research Grant (14220901).

Received February 16, 2003. Accepted in final form April 12, 2003.

Address correspondence and reprint requests to Dr. T. Iizuka, Department of Medicine (Neurology), School of Medicine, Kitasato University, 1-15-1 Kitasato Sagami-hara, Kanagawa, 228-8555, Japan; e-mail: takahiro@med.kitasato-u.ac.jp

Copyright © 2003 by AAN Enterprises, Inc.

## References

1. Pavlakis SG, Phillips PC, Dimauro S, De Vivo DC, Rowland LP. Mitochondrial myopathy, encephalopathy, lactic acidosis, and stroke-like episodes: a distinctive clinical syndrome. *Ann Neurol* 1984;16:481-488.
2. Iizuka T, Sakai F, Suzuki N, et al. Neuronal hyperexcitability in stroke-like episodes of MELAS syndrome. *Neurology* 2002;59:816-824.
3. Iizuka T, Tsukahara S, Takiyama Y, Suzuki N, Sakai F. Slowly progressive migration of cortical laminar necrosis. MRI characteristics for MELAS syndrome. *Neurology* 2001;56(suppl 3)A229. Abstract.
4. Tomita M, Suzuki N, Igarashi H, Endo M, Sakai F. Evidence against strong correlation between chest symptoms and ischemic coronary changes after subcutaneous sumatriptan injection. *Intern Med* 2002;41:622-625.
5. Goadsby PJ, Edvinsson L. Sumatriptan reverses the changes in calcitonin gene-related peptide seen in the headache phase of migraine. *Cephalalgia* 1991;11(suppl 11):3-4.
6. Cutrer FM, Schoenfeld D, Limmroth V, Panahian N, Moskowitz MA. Suppression by the sumatriptan analogue, CP-122, 288 of c-fos immunoreactivity in trigeminal nucleus caudalis induced by intracisternal capsaicin. *Br J Pharmacol* 1995;114:987-992.
7. Leira EC, Cruz-Flores S, Leacock RO, Abdulrauf SI. Sumatriptan can alleviate headaches due to carotid artery dissection. *Headache* 2001;41:590-591.

## A cluster headache family with possible autosomal recessive inheritance

Roberto De Simone, MD; Chiara Fiorillo, MD; Salvatore Bonuso, MD; and Giuseppe Castaldo, PhD

Until the early 1990s, cluster headache (CH) was considered a sporadic disorder, with a prevalence of 69 per 100,000.<sup>1</sup> The presence of CH in monozygotic twins<sup>2</sup> and in first- and second-degree relatives<sup>3</sup> suggested that genetic factors might be involved. Based on a mailed questionnaire, the prevalence of familial CH was 7%, and based on personal examination of alleged familial cases, it was 30%.<sup>3</sup> A large epidemiologic study suggested autosomal dominant inheritance can be involved in some families.<sup>4</sup> The current study describes a large kindred in which an autosomal recessive model could be involved.

The pedigree (figure) includes four related families from the Naples area (southern Italy). The proband (IV-1), diagnosed in March 2000, referred other relatives possibly affected. All living members were interviewed by telephone, and all possibly affected members were evaluated by a neurologist experienced in CH. Clinical information about deceased individuals, obtained from their descendants, allowed us to exclude CH.

CH, diagnosed according to International Headache Society criteria, was identified in eight (six females) of nine putative affected subjects. The ninth patient (II-3) was reported to be affected by recurrent, short-lasting, intense headache. He died before the study started, and we were unable to confirm CH. CH was excluded in the parents of all affected patients by direct clinical evaluation (for living) or by clinical information collected from the descendants.

Interestingly, two of the four families are linked by a double marriage: Two siblings of a family (II-4 and II-5) married 2 siblings of another (II-1 and II-2), leading to 11 and 9 offspring, with 2 affected individuals each. The overall prevalence of CH in the 127 living members was 6.29%, that is, 91-fold higher than that expected in the general population.<sup>1</sup> Table E-1 in the supplementary material on the *Neurology* Web site (go to [www.neurology.org](http://www.neurology.org)) shows the current age and the clinical findings of CH in the eight affected subjects. None of them was affected by other relevant diseases or by genetic disorders. None of them seems to have fertility alterations. The age at CH onset (15 to 30 years) and the frequency of cluster periods did not differ among the patients. Patient IV-1 had recurrent clusters of bilateral pain within an otherwise typical CH pattern. He was diagnosed as bearing a cluster-like headache as he fulfilled all criteria but unilaterality.

Several lines of evidence support an autosomal recessive model of inheritance in our kindred: The prevalence of CH found in the two double-related offspring (18 and 22%) is close to that expected for autosomal recessive transmission, and no direct paternal transmission was present in any case.

Additional material related to this article can be found on the *Neurology* Web site. Go to [www.neurology.org](http://www.neurology.org) and scroll down the Table of Contents for the August 26 issue to find the title link for this article.

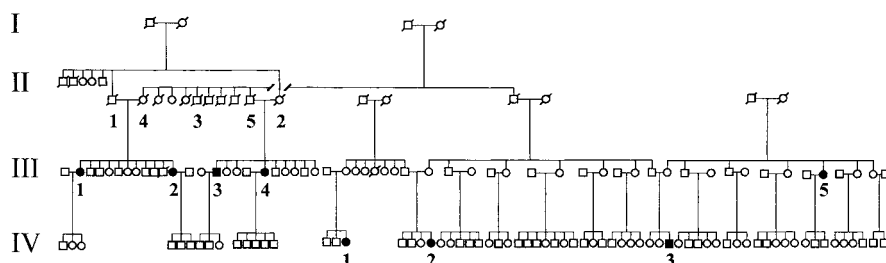


Figure. Pedigree of a large kindred of four related families in which eight members are affected by cluster headache (CH). The members with CH are indicated by filled symbols.

# Neurology®

## Response to sumatriptan in headache of MELAS syndrome

Takahiro Iizuka, Fumihiko Sakai, Motoi Endo, et al.

*Neurology* 2003;61;577-578

DOI 10.1212/01.WNL.0000078931.87815.B3

This information is current as of August 25, 2003

<b>Updated Information &amp; Services</b>	including high resolution figures, can be found at: <a href="http://www.neurology.org/content/61/4/577.full.html">http://www.neurology.org/content/61/4/577.full.html</a>
<b>References</b>	This article cites 6 articles, 1 of which you can access for free at: <a href="http://www.neurology.org/content/61/4/577.full.html#ref-list-1">http://www.neurology.org/content/61/4/577.full.html#ref-list-1</a>
<b>Subspecialty Collections</b>	This article, along with others on similar topics, appears in the following collection(s): <b>All Clinical trials</b> <a href="http://www.neurology.org/cgi/collection/all_clinical_trials">http://www.neurology.org/cgi/collection/all_clinical_trials</a> <b>All Headache</b> <a href="http://www.neurology.org/cgi/collection/all_headache">http://www.neurology.org/cgi/collection/all_headache</a> <b>Clinical trials Observational study (Cohort, Case control)</b> <a href="http://www.neurology.org/cgi/collection/clinical_trials_observational_study_cohort_case_control">http://www.neurology.org/cgi/collection/clinical_trials_observational_study_cohort_case_control</a> <b>Muscle disease</b> <a href="http://www.neurology.org/cgi/collection/muscle_disease">http://www.neurology.org/cgi/collection/muscle_disease</a> <b>Secondary headache disorders</b> <a href="http://www.neurology.org/cgi/collection/secondary_headache_disorders">http://www.neurology.org/cgi/collection/secondary_headache_disorders</a>
<b>Permissions &amp; Licensing</b>	Information about reproducing this article in parts (figures, tables) or in its entirety can be found online at: <a href="http://www.neurology.org/misc/about.xhtml#permissions">http://www.neurology.org/misc/about.xhtml#permissions</a>
<b>Reprints</b>	Information about ordering reprints can be found online: <a href="http://www.neurology.org/misc/addir.xhtml#reprintsus">http://www.neurology.org/misc/addir.xhtml#reprintsus</a>

*Neurology*® is the official journal of the American Academy of Neurology. Published continuously since 1951, it is now a weekly with 48 issues per year. Copyright . All rights reserved. Print ISSN: 0028-3878. Online ISSN: 1526-632X.

