

- 3 Keime-Guibert F, Graus F, Fleury A, Rene R, Honnorat J, Broet P, Delattre JY: Treatment of paraneoplastic neurological syndromes with antineuronal antibodies (anti-Hu, anti-Yo) with a combination of immunoglobulins, cyclophosphamide, and methylprednisolone. *J Neurol Neurosurg Psychiatry* 2000;68:479–482.
- 4 Blaes F, Strittmatter M, Merkelbach S, Jost V, Klotz M, Schimrigk K, Hamann GF: Intravenous immunoglobulins in the therapy of paraneoplastic neurological disorders. *J Neurol* 1999;246:299–303.
- 5 Graus F, Elkon KB, Lloberes P, Ribalta T, Torres A, Ussetti P, Valls J, Obach J, Agusti-Vidal A: Neuronal antinuclear antibody (anti-Hu) in paraneoplastic encephalomyelitis simulating acute polyneuritis. *Acta Neurol Scand* 1987;75:249–252.
- 6 Byrne T, Mason WP, Posner JB, Dalmau J: Spontaneous neurological improvement in anti-Hu-associated encephalomyelitis. *J Neurol Neurosurg Psychiatry* 1997;62:276–278.
- 7 Darnell RB, DeAngelis LM: Regression of small-cell lung carcinoma in patients with paraneoplastic neuronal antibodies. *Lancet* 1993;341:21–22.
- 8 Forman D, Rae-Grant AD, Matchett SC, Cowen JS: A reversible cause of hypercapnic respiratory failure: Lower motor neuronopathy associated with renal cell carcinoma. *Chest* 1999;115:899–901.
- 9 Ball JA, Warner T, Reid P, Howard RS, Gregson NA, Rossor MN: Central alveolar hypoventilation associated with paraneoplastic brain-stem encephalitis and anti-Hu antibodies. *J Neurol* 1994;241:561–566.
- 10 Graus F, Keime-Guibert F, Rene R, Benyahia B, Ribalta T, Ascaso C, Escaramis G, Delattre JY: Anti-Hu-associated paraneoplastic encephalomyelitis: Analysis of 200 patients. *Brain* 2001;124:1138–1148.

James F. Meschia, MD, Department of Neurology, Mayo Clinic  
4500 San Pablo Road, Jacksonville, FL 32224 (USA)  
E-Mail meschia.james@mayo.edu

*Eur Neurol* 2003;50:114–117  
DOI: 10.1159/000072512

### Focal Hand Myoclonus Caused by a Small Hematoma underneath the Cerebral Motor Cortex

P.C. Tsai<sup>a</sup>, F.C. Chang<sup>b</sup>, C.H. Tsai<sup>b</sup>, F.R. Jang<sup>a</sup>, A.N. Shen<sup>a</sup>, Y.T. Huang<sup>a</sup>, S.C. Lai<sup>a</sup>, T.H. Yeh<sup>a</sup>, M.K. Lu<sup>b</sup>, C.S. Lu<sup>a</sup>

<sup>a</sup>Movement Disorders Unit, Department of Neurology, Chang Gung Memorial Hospital, Taipei, and <sup>b</sup>Neuroscience Laboratory, Department of Neurology, China Medical College Hospital, Taichung, Taiwan

#### Introduction

Myoclonus is defined as sudden, brief, jerky, shock-like, involuntary movements arising from the central nervous system and involving extremities, face and trunk [1]. The causes of myoclonus are various [1]. Rarely, it was reported to be causal linked to a focal central nervous system lesion [2, 3]. Here we report a case of right-hand myoclonus caused by a small hematoma at the contralateral region underneath the motor cortex.

#### Case Report

The 59-year-old female patient developed an abrupt onset of right-hand weakness in association with severe headache and recurrent nocturnal fever about 23 days prior to admission. She was finally confirmed to have subacute bacteria endocarditis caused by *Streptococcus sanguis*. Neuroimaging studies revealed a small hematoma causally linked to mycotic aneurysm rupture over the left subcortical

motor area (fig. 1A). A focal stimulus-sensitive and arrhythmic jerk of the right hand was developed 5 weeks after the onset of the right-hand paresis. It ameliorated gradually and remained in trivial ring finger flickering 2 months later on follow-up. A series of electrophysiological investigations were conducted to illustrate the nature of the jerks and the findings of electromyography (EMG) and jerk-locked back average are shown in figures 1B and 2A. The average EMG burst duration was 175.09 ms (SD = 44.07). The somatosensory-evoked potential (SEP) study of the upper limb revealed no evidence of giant SEP and no C-response (data not shown). Since the hematoma was located below the left motor cortex, it is intriguing to know how the lesion will affect the Bereitschaftspotential (BP). The recording was secured on the 15th day after the onset of myoclonus and the results are shown in figure 2B.

#### Discussion

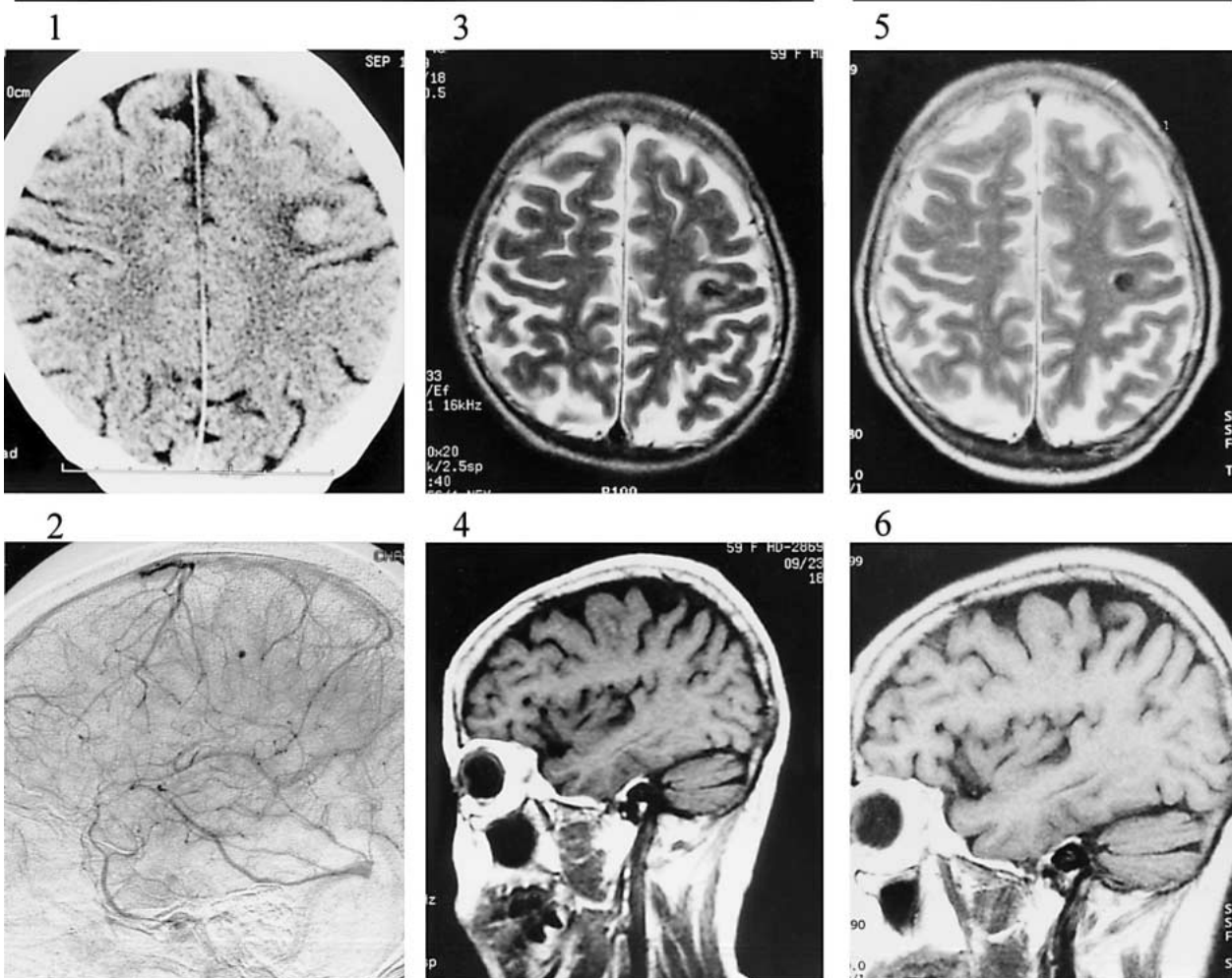
The relationship between the right-hand focal myoclonus and the tiny hematoma was clearly illustrated by neuroimaging study in the current case. There was no newly developed hemorrhage or infarction attributing to the appearance of the right-hand jerks (fig. 1A). Actually the perifocal edema around the hematoma was even diminished in the post-myoclonic films (fig. 1A). The long jerk with EMG burst duration of 175 ms discriminated the myoclonus from that of cortical origin [4]. Since the tiny hematoma was localized just below the primary motor cortex, it is necessary to elucidate the possible contribution of the cortical components to the generation of the myoclonus. The negative findings of jerk-locked back average and SEPs, however, made the possibility of ‘cortical’ origin unlikely, suggesting that the myoclonus could be subcortical in nature. The sparing of the motor cortex could also be strengthened by the findings of the preservation of the late components of BP. In subcortical lesion, as in the current case, the neural pathways rather than neurons were most likely to be severed. It would be then that networks connecting the subcortical-motor cortical domains were perturbed to cause the jerks as proposed by Lance and Adams [5]. In addition to the physical injury caused by the hematoma, the corruptive effect of hemosiderin, a decomposition product of hematoma, on the neural structure [6] should also be considered, which may share a role in the myoclonic generation in this case.

**Fig. 1. A** Images before and after the onset of myoclonus. **B** The surface EMG recording over the right flexor carpi radialis (FCR) and extensor digitorum communis (EDC). **A1** CAT scan shows a small hematoma located over the left submotor cortex. **A2** Lateral view of digitized subtraction angiograms reveal a tiny aneurysm over the compatible area of **A1**. **A3** Axial (T2-weighted) and **A4** sagittal (T1-weighted) views of magnetic resonance images verify a tiny hematoma over the left submotor cortex with perifocal edema. **A5** Axial (T2-weighted) and **A6** sagittal (T1-weighted) views of magnetic resonance images after the onset of myoclonus reveal the persistent presence of a small old hemorrhagic lesion located over the same area. The perifocal edema is less distinct (**A5**) as compared with their corresponding images in **A3** and **A4**. **B** Simultaneous EMG bursts are observed over the antagonist muscle pairs. The jerks may run in single or in hypersynchronous duplex EMG discharges (as indicated by arrows over the EDC). The amplified signal from the EDC reveals the long-duration nature of the EMG burst.

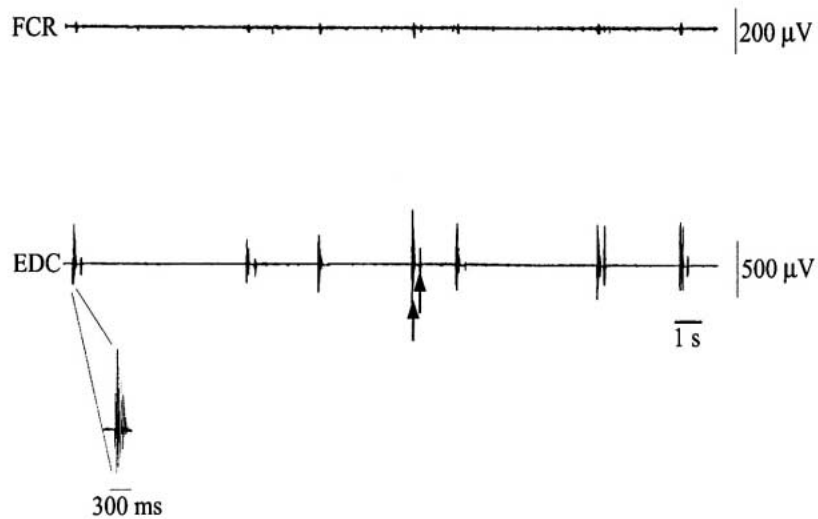
A

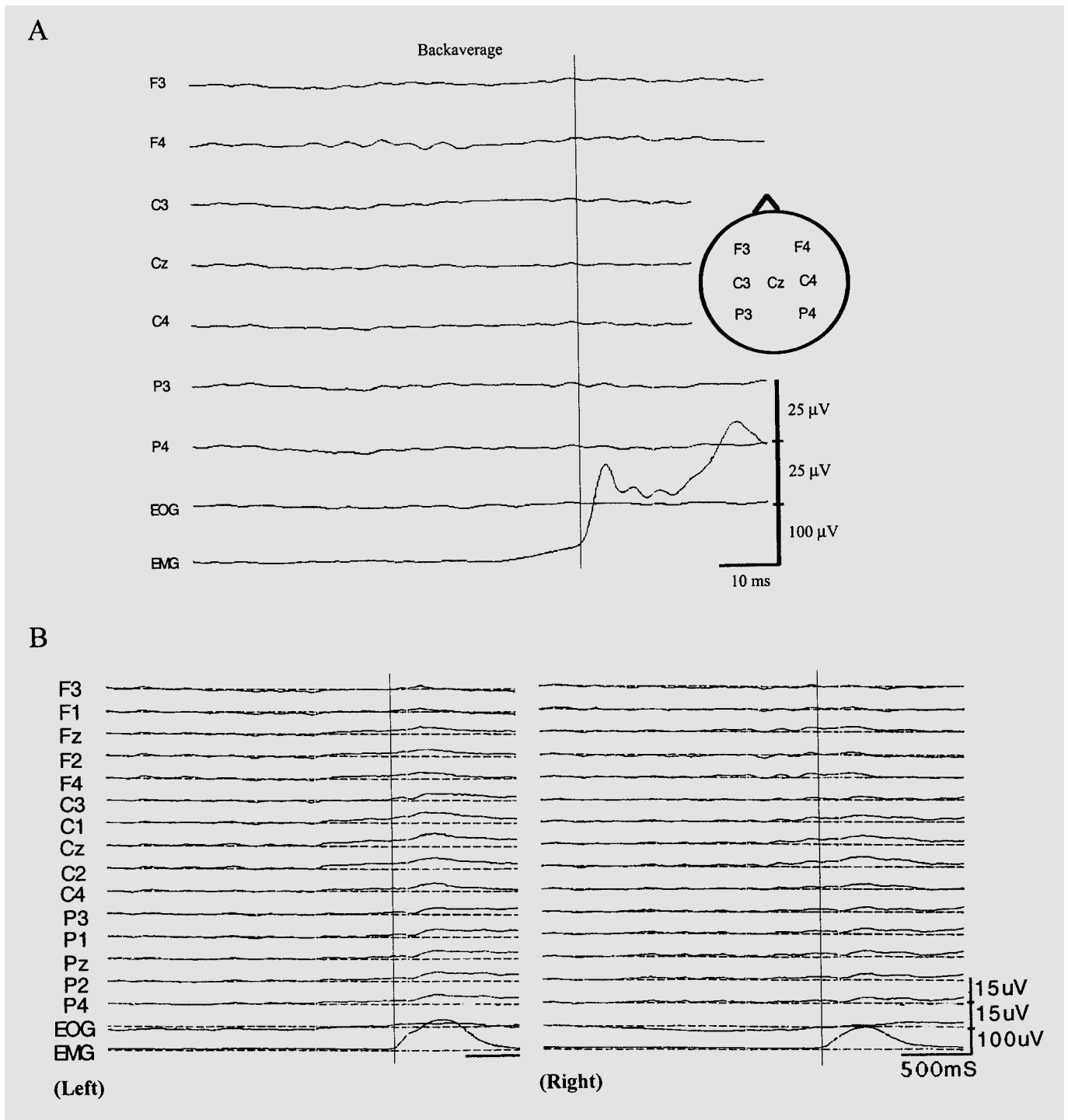
Pre-myoclonus

Myoclonus



B





**Fig. 2. A** Jerk-locked back average recording with EMG burst from the right extensor digitorum communis as the trigger. Seven cup electrodes were taped on the scalp according to the international 10–20 system (F3, C3, P3, Cz, F4, C4, P4). The figure is the average of 120 individual traces. No preceding electroencephalographic event could be observed. **B** BP recording with the EMG signal from the right and left extensor digitorum communis as the trigger. Fifteen cup electrodes were taped on the scalp according to a modified inter-

national 10–20 system (F3, F1, Fz, F2, F4, C3, C1, Cz, C2, C4, P3, P1, Pz, P2, P4). The figure in each panel is the average of 120 individual traces. Only the amplitudes of BP from the 0.5 s before to the onset of the voluntary EMG activity were measured. On moving the right EDC, the amplitudes of BP were 2.17, 2.72 and 2.84  $\mu$ V for C1, Cz and C2, respectively. The BP elicited by left EDC movement was also clearly observed over the C1, Cz and C2 with amplitudes of 4.50, 3.67 and 3.39  $\mu$ V, respectively.

### Acknowledgements

The authors thank Prof. P.D. Thompson at the Royal Adelaide Hospital, Australia, for his valuable suggestions in the discussion of the manuscript. The study was supported by grants from NMRP 047H, CMRP 710 and DMR 92011.

### References

- 1 Fahn S, Marsden CD, Van Woert MH: Definition and classification of myoclonus. *Adv Neurol* 1986;43:1–5.
- 2 Kao YF, Shih PY, Chen WH: An unusual concomitant tremor and myoclonus after a contralateral infarct at thalamus and subthalamic nucleus. *Kaohsiung J Med Sci* 1999;15:562–566.
- 3 Wang HC, Hsu WC, Brown P: Cortical tremor secondary to a frontal cortical lesion. *Mov Disord* 1999;14:370–374.
- 4 Obeso JA, Rothwell JC, Marsden CD: The spectrum of cortical myoclonus. *Brain* 1985;108:193–224.
- 5 Lance JW, Adams RD: The syndrome of intention or action myoclonus as a sequel to hypoxic encephalopathy. *Brain* 1963;86:111–136.
- 6 Pelak VS, Galetta SL, Grossman RI, Townsend JJ, Volpe NJ: Evidence for preganglionic pupillary involvement in superficial siderosis. *Neurology* 1999;53:1130–1132.

Dr. Chon-Haw Tsai, Department of Neurology  
China Medical College Hospital, 2, Yuh Der Road, Taichung 404 (Taiwan)  
Tel. +886 4 220 52121/ext 3685, Fax +886 4 220 33474  
E-Mail d8079@www.cmch.org.tw

*Eur Neurol* 2003;50:117–118

DOI: 10.1159/000072513

## Transient Paroxysmal Dyskinesia Associated with Focal Basal Ganglia Lesions

Siew-Ju See<sup>a</sup>, Ling-Ling Chan<sup>b</sup>, Eng-King Tan<sup>a</sup>

Departments of <sup>a</sup>Neurology and <sup>b</sup>Diagnostic Radiology,  
Singapore General Hospital, Singapore

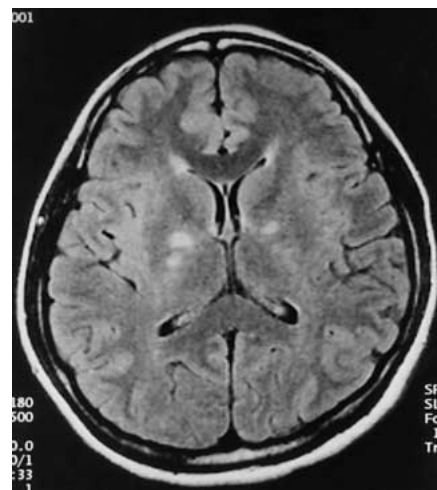
### Introduction

Paroxysmal kinesigenic dyskinesia (PKD) is a rare neurological condition that can be idiopathic or associated with ischaemic, inflammatory or metabolic derangements. Its pathophysiology remains a topic of intense debate with many investigators believing that it is related to dysfunction of basal ganglia structures. We report an unusual case of transient and reversible PKC associated with focal lesions on brain magnetic resonance imaging (MRI) and discuss the pathophysiologic mechanism.

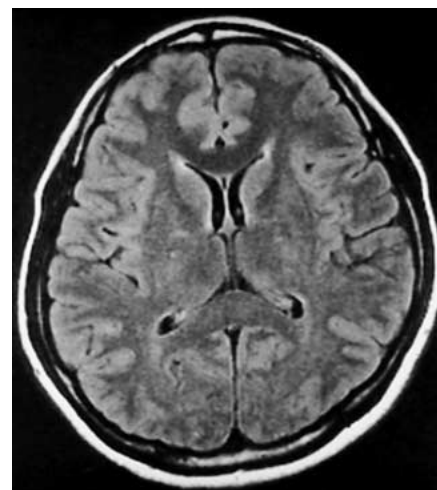
### Case Report

A 30-year-old woman presented with paroxysmal dystonic posturing of the right upper and lower extremities consisting of shoulder abduction, elbow and wrist flexion, flexion and extension at the metacarpophalangeal and interphalangeal joints respectively and flexion at the hip and knee. These episodes were precipitated by sudden movements such as getting up from a sitting position, and were preceded by an aura of sensation of 'tightness' in the affected limbs. There were 10–15 attacks per day, each lasting between 5 and 20 s. Between attacks, neurological examination was normal.

Brain MRI (fig. 1) revealed well-defined focal non-gadolinium-enhancing hyperintense (T2) lesions in the posterior part of the internal capsules and globus pallidi bilaterally. These were felt to be compatible with either a demyelinating or ischaemic process. Extensive investigations including thyroid function, calcium metabolism, fasting serum glucose, cholesterol and triglyceride levels, ESR, ANA, anti-Ds-DNA antibody, lupus anticoagulant and protein S, protein C



**Fig. 1.** Axial FLAIR (TR 9,000 ms/TE 100 ms/IR 2,500 ms/2 excitations) image demonstrating subcentimetre hyperintense lesions in the posterior limb of internal capsules and globi pallidi bilaterally.



**Fig. 2.** Corresponding axial FLAIR (identical parameters) image showing near total resolution of lesions 15 months later.

Copyright: S. Karger AG, Basel 2003. Reproduced with the permission of S. Karger AG, Basel. Further reproduction or distribution (electronic or otherwise) is prohibited without permission from the copyright holder.

Copyright: S. Karger AG, Basel 2003. Reproduced with the permission of S. Karger AG, Basel. Further reproduction or distribution (electronic or otherwise) is prohibited without permission from the copyright holder.