

---

## SHORT COMMUNICATION

---

### Case report

# Sympathetic ophthalmia associated with ocular and cerebral vasculitis: An angiographic and radiologic study

S. KADAYIFÇILAR, M. IRKEÇ, B. ELDEM

Hacettepe University School of Medicine, Department of Ophthalmology, Ankara - Turkey

---

**PURPOSE.** *To describe a case of sympathetic ophthalmia (SO) associated with ocular and cerebral vasculitis.*

**METHODS.** *The authors report a 38-year-old woman who presented with bilateral uveitis 7 years after a penetrating trauma to the right eye. Ocular examination included fundus fluorescein and indocyanine green angiography. Medical history disclosed an episode of dysarthria and right-sided weakness.*

**RESULTS.** *Anterior uveitis was present in the previously injured pseudophakic right eye, which harbored a piece of glass stuck in the lower temporal iris. In the left eye, vitreal inflammation with retinal sheathing and subretinal lesions was predominant. Besides retinal vasculitis, fundus angiography showed choroidal vasculitis. Neurologic studies were compatible with cerebral vasculitis.*

**CONCLUSIONS.** *In SO, choroidal vasculitis that is invisible clinically can be demonstrated angiographically. Although rare, inflammation can also affect the nervous system. (Eur J Ophthalmol 2003; 13: 584-7)*

**KEY WORDS.** *Sympathetic ophthalmia, Uveitis, Cerebral vasculitis*

*Accepted: March 10, 2003*

---

## INTRODUCTION

Sympathetic ophthalmia (SO) is defined as a bilateral granulomatous inflammation of the uveal tract following penetrating injury to one eye (1). Small white-yellow infiltrating lesions at the level of the retinal pigment epithelium (Dalen-Fuchs nodules) are typical of SO, whereas extraocular findings are very rare (1, 2). We report a patient with SO and cerebral vasculitis.

### Case report

A 38-year-old woman presented with blurred visual acuity in the left eye. Ocular history disclosed corneal penetration of the right eye due to a motor vehicle accident 7 years previously. After repair of the pene-

tration, extracapsular cataract extraction and posterior chamber intraocular lens (IOL) implantation had been performed. The patient had anterior uveitis in the same eye 5 years later.

At presentation, the visual acuity was 20/400 in the right eye and 20/25 in the left. Examination of the right eye revealed previous penetration scar at upper nasal cornea, 1+ cells in the anterior chamber with mutton fat keratic precipitates, and a piece of glass stuck in the lower temporal iris. The pupil was irregular with a nasal posterior synechia. Pigment deposits were noted on the IOL and the posterior capsule was fibrotic, precluding detailed ophthalmoscopy. B-scan ultrasonography did not disclose any peculiar inflammation in the vitreous. Trace cells were noted in the anterior chamber of the left eye, and ophthalmoscopy

disclosed vitreal inflammation with small inferior vitreous opacities and retinal perivascular sheathing. Subretinal white-yellow chorioretinal infiltrates were discernible inferiorly.

Fluorescein angiography (FA) disclosed prolonged arteriovenous transit time, retinal vascular staining and leakage, and late hyperfluorescence corresponding to the subretinal spots in the left eye (Fig. 1). Early stage indocyanine green angiography (ICGA) revealed leakage from the dilated choroidal vessels (Fig. 2). Hypofluorescent areas were noted in all stages of ICGA.

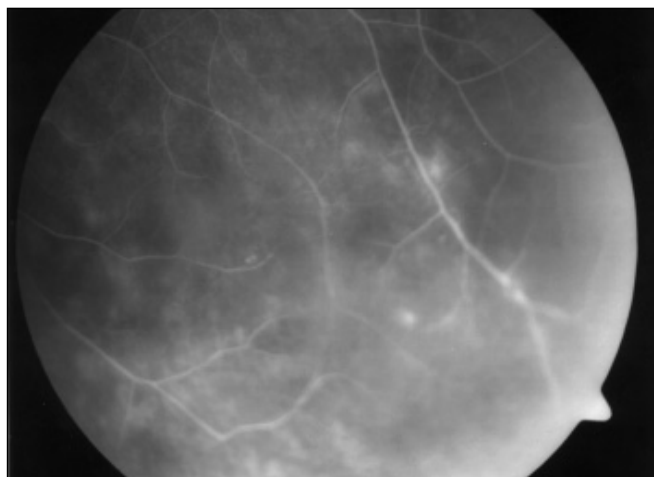
Medical history revealed an episode of dysarthria with weakness of the right extremities the previous year. Neurologic examination was within normal limits. Previous T2-weighted magnetic resonance images disclosed multiple enhancing lesions in pons, frontal lobe, temporooccipital region, parietal lobe, periventricular white matter, and caudate nucleus, which were implicative of cerebral vasculitis (Fig. 3).

Physical examination and laboratory work-up, including chest x-ray, complete blood count with differential white cell count, urinalysis, erythrocyte sedimentation rate, C-reactive protein, serum electrolytes, liver and kidney function tests, Venereal Disease Research Laboratory, serum angiotensin converting enzyme levels, serum calcium and phosphate levels, antinuclear antibody, anti-double stranded DNA antibody, antineutrophilic cytoplasmic antibody, lupus anticoagulant and anticardiolipin antibody, and rheumatoid factor, were within normal limits. The patient was found to be positive for HLA-DR4 antigen.

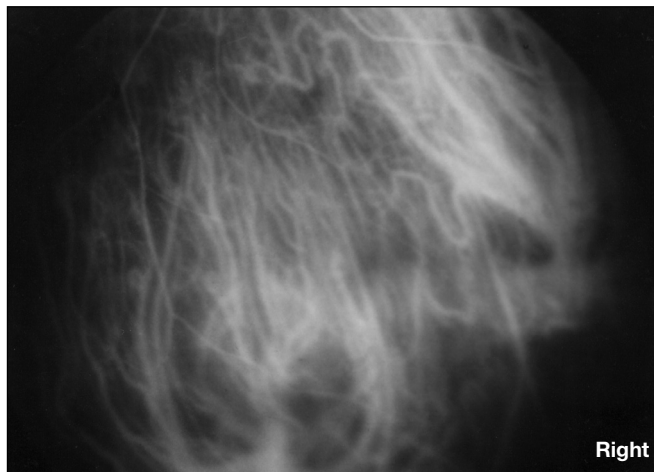
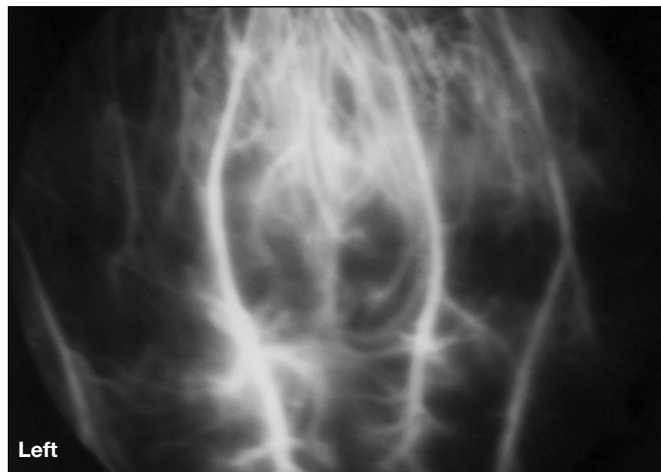
With the exclusion of systemic vasculitides, and the history of penetrating ocular trauma and bilateral ocular inflammation, the patient was thought to have SO, and oral prednisone therapy (1.5 mg/kg/day) combined with cyclosporine (5 mg/kg/day) was begun. Prednisone was slowly tapered. Within 4 months, the inflammation was controlled, confirmed by improved results on indocyanine green angiograms (Fig. 2).

## DISCUSSION

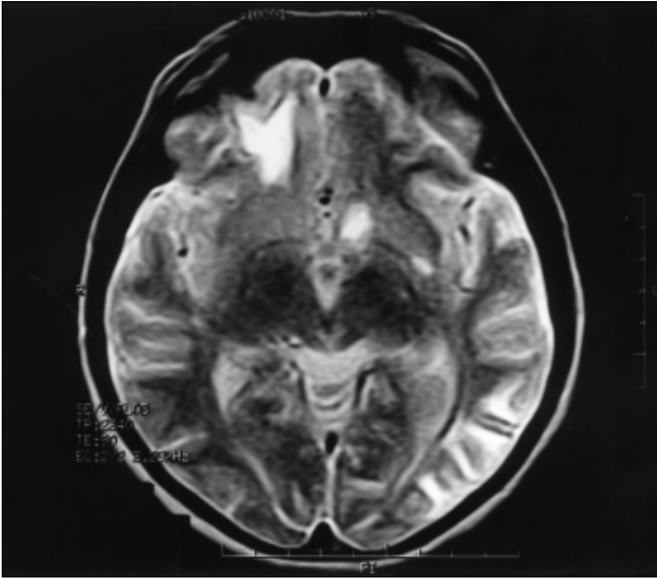
Theories for the inciting antigen in SO include hypersensitivity to uveal pigment, an infectious agent,



**Fig. 1** - Fluorescein angiography, late stage. Retinal vascular staining and leakage, hyperfluorescence corresponding to the subretinal spots in the left eye.



**Fig. 2** - **Left:** Choroidal vascular dilatation and leakage, with surrounding hypofluorescent areas, in early stage of indocyanine green angiography (ICGA). **Right:** 4 months later, the vessels are of normal caliber with no dilatation or leakage at the early stage of ICGA. No peculiar hypofluorescence is observed.



**Fig. 3** - Magnetic resonance imaging, T2-weighted image. Hyperintense lesion at the left lentiform nucleus, cortical and subcortical hyperintense lesions at the right frontal and left temporooccipital regions signifying chronic ischemic process.

or sensitivity to retinal or uveal proteins. Through penetrating ocular trauma, these antigens may gain access to the lymphatic system, leading to a T-cell-mediated immune process and resulting in bilateral uveitis and, very rarely, extraocular manifestations (1, 3). In our case, the penetrating trauma or the glass particle, although inert, may have resulted in sustained release of a uveal antigen, which in turn incited inflammation in the eyes and the nervous system.

In SO, genetic susceptibility was suggested due to the strong association with HLA-DR4 (1), which was positive in our patient as well.

In SO, the choroid is infiltrated predominantly by T lymphocytes (1, 2). Histopathologically, retinal perivasculitis has been reported in 30 to 50% of cases (2). This case demonstrated retinal perivasculitis both clinically and angiographically. Choroidal vasculitis, which to our knowledge has not been reported previously, was documented at the early stages of ICGA. Previous studies implied the importance of hypofluorescent dark dots on ICGA with regard to the activity of the disease (4). Hypofluorescent areas, probably corresponding to the focal choroidal infiltration, observed in the active stage of the disease in our case, were no longer peculiar on the control ICGA, confirming the resolution of the process.

Few patients with SO have been reported to demonstrate extraocular findings similar to those seen in Vogt-Koyanagi-Harada syndrome, such as cells in the cerebrospinal fluid, hearing disturbances, and hair and skin changes (1). Reports demonstrating the association of central nervous system vasculitis with ocular inflammation such as acute multifocal placoid pigment epitheliopathy have been increasing (5). The most frequently postulated pathogenetic mechanism for the production of vasculitis is the deposition of circulating immune complexes. Other proposed mechanisms include in situ formation of immune complexes, direct invasion of the vessel wall by antigen, antibodies to myelocyte lysosomal enzymes, cytotoxic antibodies to endothelium, and cell-mediated immune reactions to cell-wall antigens (6). Immunologic testing of patients with SO has verified T-cell activity against retinal antigens and helper and suppressor T cells have been demonstrated in the inflammatory lesions in ocular tissue from cases of SO (7). Therefore, cerebral vasculitis may be associated with SO through cell-mediated immune mechanisms. Although SO has been reported as an example of diffuse inflammation of the eyes and the central nervous system (3), the association between SO and cerebral vasculitis has not been previously reported.

Our case might be thought to have another disorder, likely autoimmune, with ocular and cerebral involvement. However, history of ocular trauma; presence of an intraocular foreign body continually irritating the iris; choroidal inflammation, best demonstrated with ICGA, in the other eye; and exclusion of other systemic vasculitis entities strongly imply the diagnosis of SO with cerebral vasculitis in this case, although definitive diagnosis for SO necessitates histologic confirmation.

In conclusion, in the event of ocular penetrating trauma, we recommend meticulous search for possible foreign bodies, and early removal when possible, to eliminate an additional risk factor for SO, which may rarely result in central nervous system complications.

Reprint requests to:  
Sibel Kadayifçılar, MD  
Hacettepe University School of Medicine  
Department of Ophthalmology  
06100 Sıhhiye  
Ankara, Turkey  
sibelkd@mailcity.com

## REFERENCES

1. Nussenblatt RB, Whitcup SM, Palestine AG. Sympathetic ophthalmia. In: Uveitis: Fundamentals and Clinical Practice. St. Louis: Mosby-Year Book; 1996: 299-311.
2. Chan C. Relationship between sympathetic ophthalmia, phacoanaphylactic endophthalmitis, and Vogt-Koyanagi-Harada disease. *Ophthalmology* 1988; 95: 619-24.
3. Martenet AC. Nervensystem und uveitis. *Klin Monatsbl Augenheilkd* 1988; 92: 83-6.
4. Bernasconi O, Auer C, Zografos L, Herbort CP. Indocyanine green angiographic findings in sympathetic ophthalmia. *Graefes Arch Clin Exp Ophthalmol* 1998; 236: 635-8.
5. O'Halloran HS, Berger JR, Lee WB, et al. Acute multifocal placoid pigment epitheliopathy and central nervous system involvement. *Ophthalmology* 2001; 108: 861-8.
6. Scott DGI, Watts RA. Classification of vasculitis. In: Maddison PJ, Isenberg DA, Woo P, Glass DN, eds. *Oxford Textbook of Rheumatology*. Vol. 2. New York: Oxford University Press; 1998: 1320-31.
7. American Academy of Ophthalmology. *Basic and Clinical Science Course 1996-1997: Intraocular Inflammation and Uveitis*. 1996; Section 9: 53-4.