

**Authors:**

Marcelo L. Berthier, MD  
 Jesús Pujol, MD  
 Alexandre Gironell, MD  
 Jaime Kulisevsky, MD  
 Joan Deus, PhD  
 Julián Hinojosa, PhD  
 Carles Soriano-Mas, PhD

**Affiliations:**

From the Department of Medicine, University of Malaga School of Medicine, Malaga, Spain (MLB); the Magnetic Resonance Center of Pedralbes, CETIR, Barcelona, Spain (JP, JD, CSM); the Movement Disorder Section, Department of Neurology, Sant Pau Hospital and Autonomous University of Barcelona, Barcelona, Spain (AG, JK); and the Marine Hospital of Torremolinos, Malaga, Spain (JH).

**Correspondence:**

Address requests for reprints to Marcelo L. Berthier, MD, Departamento de Medicina Facultad de Medicina, Universidad de Málaga, Campus Universitario Teatinos, 29.071, Málaga, España.

0894-9115/03/8209-0725/0  
*American Journal of Physical Medicine & Rehabilitation*  
 Copyright © 2003 by Lippincott Williams & Wilkins

DOI: 10.1097/01.PHM.0000083668.48396.84

**Case Report****Beneficial Effect of Donepezil on Sensorimotor Function After Stroke****ABSTRACT**

Berthier ML, Pujol J, Gironell A, Kulisevsky J, Deus J, Hinojosa J, Soriano-Mas C: Beneficial effect of donepezil on sensorimotor function after stroke. *Am J Phys Med Rehabil* 2003;82:725–729.

Pharmacotherapy of poststroke sensorimotor deficits is currently used alone or combined with physiotherapy to promote recovery of mobility problems. This case study examined the effectiveness of donepezil hydrochloride (HCl) administered to a stroke patient with chronic, dense, left sensorimotor deficit. The patient received donepezil HCl (5 mg daily for 4 wk, followed by 10 mg daily for 12 wk) but no physiotherapy. Baseline and posttreatment evaluations were performed with the Fugl-Meyer scale and the Rivermead Mobility Index. One month after starting donepezil HCl (10 mg/day), sensorimotor function improved dramatically in the hemiplegic lower limb and shoulder. It was concluded that donepezil HCl may be an effective treatment for improving sensorimotor function in chronic stroke patients. Randomized controlled trials are required to support these preliminary findings.

**Key Words:** Sensorimotor Deficits, Stroke, Donepezil Hydrochloride, Functional Magnetic Resonance Imaging, Transcranial Magnetic Stimulation, Bereitschaftspotentials

**L**arge hemispheric infarcts impede the functional recovery of contralateral sensorimotor deficits by reducing the capacity of surviving peri-infarct tissue for reorganization.<sup>1</sup> Although some recovery of motor function occurs in the weeks to months after the stroke, the effectiveness of conventional physiotherapy in cases showing little or no spontaneous functional recovery is limited, particularly when mobility problems remain for >1 yr.<sup>2</sup> However, a new physiotherapeutic technique for the densely hemiplegic upper limb (constraint-induced movement therapy)

produces prolonged functional improvement,<sup>3</sup> and psychostimulant treatments in combination with physiotherapy improve functional motor recovery.<sup>4,5</sup>

Pharmacologic treatments in stroke patients are directed to restore neurotransmitter system deficiencies, and agents that restore or augment norepinephrine, dopamine, and serotonin activity have been used to promote recovery of hemiplegia, neglect, and aphasia.<sup>4–6</sup> Recent studies in animal models and in humans indicate that central cholinergic neurotransmission is involved in motor function.<sup>7–9</sup> A positron emission tomography study in monkeys found that activation of the somatosensory cortex induced by contralateral somatosensory stimulation is abolished by scopolamine and reversed by physostigmine and tacrine.<sup>7</sup> Transcranial magnetic stimulation (TMS) studies in healthy volunteers found that antagonists of muscarinic receptors (atropine, scopolamine) modify the excitability of the motor cortex<sup>8</sup> and substantially attenuate the magnitude of use-dependent plasticity.<sup>9</sup> Donepezil hydrochloride (HCl) is a reversible acetylcholinesterase inhibitor with a selective central action.<sup>10</sup> It is safe and widely prescribed to improve cognition and memory in patients with Alzheimer's disease and other neurologic conditions (i.e., head trauma).<sup>10,11</sup> To evaluate the efficacy of cholinergic therapy in improving sensorimotor deficits associated with stroke, we used donepezil HCl to treat a stroke patient and examined its effects on cortical reorganization using functional magnetic resonance imaging (fMRI) and neurophysiologic techniques.

## CASE REPORTS

The patient was a 64-yr-old, strongly right-handed woman who, at age 59, suffered a large right-hemisphere ischemic infarction, which left her with a dense left hemiplegia,

left hemisensory loss, and “crossed” conduction aphasia. After the stroke, she received two sessions of traditional physiotherapy daily for 2 yr. Because she was unable to recover voluntary movements, physiotherapy was stopped, and she had not received physiotherapy since then. By that time, an MRI disclosed a large infarct in the vascular territory of the right middle cerebral artery involving the temporoparietal cortex and extending deeply into the posterior insula, putamen, corona radiata, and internal capsule. There was a severe shrinkage of the right cerebral peduncle. The inferior frontal, primary sensorimotor, dorsolateral prefrontal, and mesial frontoparietal cortices and the thalamus and a small portion of the posterior limb of the internal capsule were spared. Regional cerebral blood flow, measured with single photon emission computed tomography and 99m TC-HMPAO (Ceretek, Exametazime, Amersham Madrid, Spain), was significantly decreased (regions of interest,  $<0.70$  [values in normal controls,  $\geq 0.93$ ])<sup>12</sup> in the whole right hemisphere, even in those regions that did not show structural damage on MRI (thalamus, primary sensorimotor cortex—lateral and mesial).

On the baseline neurologic evaluation, carried out 5 yr after stroke onset, she had a dense left spastic hemiplegia for proximal and distal motor function with sensory loss. She did not show signs of neglect. Her score on the Fugl-Meyer scale<sup>13</sup> was 10 (motor component for upper limb, 4 [range, 0–66]; motor component for lower limb, 6 [range, 0–34]; sensation, 0 [range, 0–24]), and her Rivermead Mobility Index<sup>14</sup> score was 6 (range, 0–15). A repeat tridimensional MRI confirmed the precise location of the infarct.

After signing an informed consent agreement, the patient received 5 mg of donepezil HCl daily for 1 mo, followed by 10 mg daily for 3 mo, and thereafter, a 4-wk washout period. Adverse events were monitored during

therapy. Two weeks after receiving donepezil HCl (5 mg/day), the patient developed touch- and warmth-evoked allodynia in the left foot, calf, and forearm. Allodynia lasted 2 wk, and its disappearance coincided with the recovery of sensation for touch, temperature, and joint-position sense in the left leg and arm. Four weeks after starting 10 mg of donepezil HCl, she began to recover voluntary movements of the left leg and shoulder, but the left hand remained totally plegic. Eight weeks later, her Fugl-Meyer scale score increased to 34 (motor component for upper limb, 7; motor component for lower limb, 18; sensation, 9) and her Rivermead Mobility Index score to 13. Recovery of motor function in the left foot was associated with the development of mirror movements, yet passive flexion-extension exercises of the left foot did not elicit visible movements in the unaffected right foot. Donepezil HCl did not induce adverse effects. Withdrawal evaluation 4 wk later revealed the maintenance of gains in sensorimotor function obtained during treatment (Fugl-Meyer scale score, 34; Rivermead Mobility Index score, 13).

## ANCILLARY STUDIES

Twelve weeks after starting donepezil HCl treatment (10 mg/day), the functional correlates of recovery were examined with fMRI and neurophysiologic techniques (Bereitschaftspotential and TMS).

**Functional MRI.** The patient was scanned 12 wk after initiation of donepezil HCl treatment (10 mg/day) on a 1.5-T magnetic resonance scanner (Signa, GE Medical Systems, Milwaukee, WI) equipped with echo-speed gradients and single-shot echoplanar imaging software.<sup>15,16</sup> Eight interleaved slices, parallel to the anteroposterior commissure line, were obtained for each functional sequence to cover the cortical motor system (four slices).<sup>16,17</sup> The functional time series consisted of 60 con-

secutive images obtained in 3 min, in which 30-sec periods of rest and activation were alternated. The patient was instructed to perform active, self-initiated movements of the left foot. In addition, passive flexion-extension movements were performed by the examiner to assess the proprioceptive sensory input of the motor-sensory loop.<sup>6</sup> Foot exercises were selected because recovery of motor function during donepezil HCl treatment mainly took place in the distal left leg and because active shoulder movements of the plegic arm induced head movements.

**Bereitschaftspotential.** The Bereitschaftspotential (BP) recordings were obtained with an analogic amplifier (Grass 8-pluss electroencephalogram) and further processed using an analog/digital converter Neuroscan 3.0 (Herndon, VA). Brisk voluntary unilateral extensions of the left deltoid muscle (recorded by surface electromyography) were repeated at a self-paced rate of every 4–5 sec. The electroencephalographic segments from 2 sec before to 1 sec after the trigger movement were digitized and stored at a sampling rate of 400 Hz. The stored electroencephalographic segments were average-time locked to the precise onset of the rectified electromyograph, which was determined through off-line inspection of each trial. During this procedure, trials with apparently significant artifacts were excluded. The amplitude of the early BP component (650 msec before electromyographic onset) and the late BP component (negative slope, maximal BP negativity peak minus BP negativity peak at 650 msec before electromyographic onset) were identified by visual inspection.<sup>18</sup>

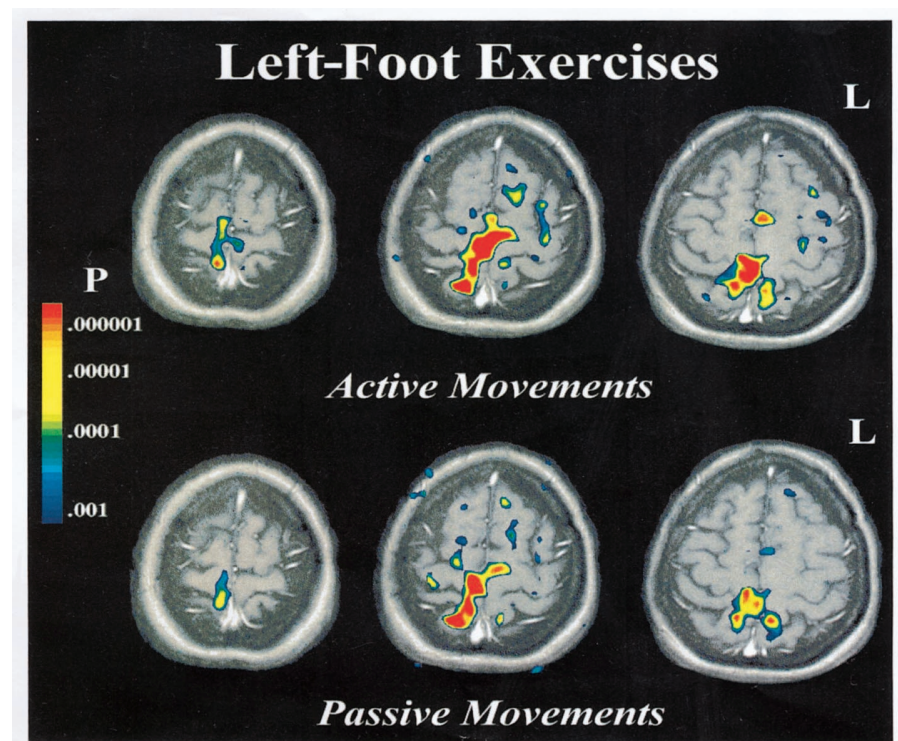
**TMS.** TMS was delivered using a 90-mm outer diameter circular coil, which was applied centered at the vertex with a posterior-to-anterior-

induced current for the stimulated hemisphere (Magstim Rapid, Carmarthenshire, UK). Motor-evoked potential (MEP) was recorded at the right abductor pollicis brevis muscle and at right and left deltoid muscles. Motor threshold was assessed by application of single stimuli for activation of the right abductor pollicis brevis muscle. After cortical stimulation at 20% over motor threshold, latency and amplitude of the MEPs recorded at deltoid muscles were measured during maximal voluntary contraction. Two to four repetitions were performed, and the latency was measured to the highest amplitude reasonable MEP. Cervical root (neck) stimulation was also performed at 100% of stimulator output to calculate the central conduction time.

## RESULTS

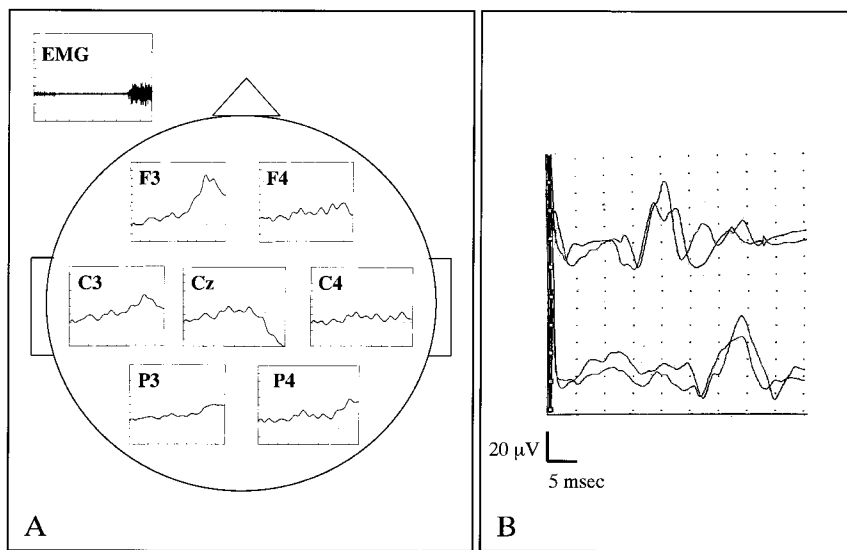
**Functional MRI.** Active flexion-extension movements of the paretic left foot basically induced activation of the contralateral right mesial sensorimotor cortex, together with functional activity in the supplementary motor area (Fig. 1). The activation pattern was accurately replicated in a second fMRI trial with the active task, and similar results were obtained after passive flexion-extension movements of the left foot (Fig. 1).

**Bereitschaftspotential.** The voluntary contraction of the left deltoid muscle was preceded by a BP of higher amplitude in the ipsilateral electroencephalographic leads, especially in the late part or negative slope. Ipsilateral leads, early/late parts: F3, 7.7/11.8  $\mu\text{V}$ ; C3,



**Figure 1:** Functional magnetic resonance imaging. The activation pattern observed in our patient during left foot flexion-extension movements is shown in three consecutive slices at the brain's vertex region. There is a relevant activation of contralateral sensorimotor cortices, with minor ipsilateral contribution. Supplementary motor area was activated bilaterally. Similar patterns were observed in both active and passive situations, although the extension of the changes was greater in the former. Activation images are displayed in pseudo color, scaled according to significance, and superimposed on corresponding anatomic images.





**Figure 2:** Neurophysiologic studies. *A*, movement-related cortical potentials obtained as the patient performed a left deltoid contraction movement. Note the higher amplitude of the potential obtained at the ipsilateral leads, especially for the second part of the potential (negative slope). Horizontal calibration, 250 msec; vertical calibration, 5  $\mu\text{V}$ . *B*, motor-evoked potentials obtained at the deltoid muscles (contralateral, upper trace; ipsilateral, lower trace) after transcranial magnetic stimulation of the left motor cortex. Note the latency delay of the response induced in the ipsilateral muscle. Two consecutive trials are superimposed in each trace to show consistency of the responses. Horizontal calibration, 5 msec; vertical calibration, 20  $\mu\text{V}$ . EMG, electromyography.

6.4/7.3  $\mu\text{V}$ ; P3, 3.1/4.6  $\mu\text{V}$ . Contralateral leads: F4, 4.5/1.9  $\mu\text{V}$ ; C4, 3.3/0.7  $\mu\text{V}$ ; P4, 3.1/1.9  $\mu\text{V}$  (Fig. 2).

**TMS.** Motor threshold for the right abductor pollicis brevis muscle and central conduction time elicited with TMS were within normal limits (62% and 9.0 msec, respectively). The MEP latency at the right abductor pollicis brevis muscle was 22.8 msec and 11.8 msec at the right deltoid muscle. Interestingly, a MEP was also recorded at the ipsilateral deltoid muscle with a latency of 24.1 msec (Fig. 2). When stimulation was applied over the right motor cortex, no MEPs were recorded at the abductor pollicis brevis or at the deltoid muscles, even at the maximal stimulator output intensity.

## DISCUSSION

In the present case, recovery of chronic sensorimotor deficits followed donepezil HCl treatment, ad-

ministered 5 yr after onset. Such a late response in a stroke patient in the absence of a concomitant physiotherapy treatment that can by itself explain the patient's recovery, coupled with allodynia preceding sensory recovery and the improvement of left foot and shoulder movements, suggest that donepezil HCl enhanced neural activity in surviving brain systems. To the best of our knowledge, this is the first study that examines the efficacy of donepezil HCl on poststroke sensorimotor deficits. The cortical activation pattern correlating with recovered foot functions was documented with fMRI as an almost identical pattern of activation of the contralateral mesial somatosensory cortex and the supplementary motor area during active and passive left foot movements. Neurophysiologic techniques (BP and TMS) showed an enhancement of ipsilateral motor representations during active movements of the left shoulder, suggesting

recruitment of ipsilateral motor pathways.<sup>19</sup>

Structural MRI disclosed a large right cortical infarct with subcortical extension and major involvement of the corticospinal motor and sensory pathways, except for a small part of the posterior limb of the internal capsule and the "leg representation zone" in mesial somatosensory cortex (Brodmann's areas 4, 312, and 5). Moreover, these structurally intact peri-infarct regions still showed a marked hypoperfusion on a brain single photon emission computed tomography performed 2 yr after stroke onset. Thus, it is possible that these islets of spared parenchyma did not promote functional recovery of the hemiplegic lower limb under physical therapy because they remained disconnected for a long period after the stroke as a result of enduring central input alterations.<sup>20</sup>

The earliest clinical changes during donepezil HCl (5 mg/day) treatment involved improvement of deficits in left foot sensation, perhaps through a short-lived maladaptive reorganization resulting in touch- and warmth-evoked allodynia, followed by left leg motor recovery and proximal left arm improvement. Recent evidence in humans shows that reduced input to a cortical sensory region leads to reduced excitability of adjacent motor cortex<sup>20</sup> and that somatosensory stimulation increases hand muscle strength of stroke patients.<sup>21</sup> It is therefore possible that donepezil HCl contributes in reversing the deprivation of sensory input by activating sensory processing and ultimately promoting motor function recovery. Maladaptive plastic changes also occurred for motor function because functional recovery in the left foot was associated with the development of mirror movements.

Reorganization of the motor system was probably not confined to the contralateral somatosensory cortex. Less dramatic, though clinically evident, left shoulder recovery was also

observed. Because of the virtually massive damage to the internal capsule, the recovered motor function in this bodily region was presumably controlled by ipsilateral structures, as suggested by BP and TMS, that may also be receptive to the beneficial action of donepezil HCl. Although our findings suggest that donepezil HCl is a potentially viable treatment option for patients with chronic post-stroke sensorimotor deficits, randomized, controlled clinical trials are necessary to support these preliminary findings.

## REFERENCES

1. Nudo RJ, Friel KM: Cortical plasticity after stroke: Implications for rehabilitation. *Rev Neurol (Paris)* 1999;155:713-7
2. Green J, Forster A, Bogle S, et al: Physiotherapy for patients with mobility problems more than 1 year after stroke: A randomised controlled trial. *Lancet* 2002; 359:199-203
3. Levy CE, Nichols DS, Schmalbrock PM, et al: Functional MRI evidence of cortical reorganization in upper-limb stroke hemiplegia treated with constraint-induced movement therapy. *Am J Phys Med Rehabil* 2001;80:4-12
4. Walker-Batson D, Smith P, Curtis S, et al: Amphetamine paired with physical therapy accelerates motor recovery after stroke: Further evidence. *Stroke* 1995;26: 2254-9
5. Scheidtman K, Fries W, Muller F, et al: Effect of levodopa in combination with physiotherapy on functional motor recovery after stroke: A prospective, randomised, double-blind study. *Lancet* 2001; 358:787-90
6. Pariente J, Loubinoux I, Carel C, et al: Fluoxetine modulates motor performance and cerebral activation of patients recovering from stroke. *Ann Neurol* 2001;50: 718-29
7. Tsukada H, Kakiuchi T, Ando I, et al: Functional activation of cerebral blood flow abolished by scopolamine is reversed by cognitive enhancers associated with cholinesterase inhibition: A positron emission tomography study in unanesthetized monkeys. *J Pharmacol Exp Ther* 1997;281:1408-14
8. Liepert J, Schardt S, Weiller C: Orally administered atropine enhances motor cortex excitability: A transcranial magnetic stimulation study in human subjects. *Neurosci Lett* 2001;300:149-52
9. Sawaki L, Borojerdi B, Kaelin-Lang A, et al: Cholinergic influences on use-dependent plasticity. *J Neurophysiol* 2002;87:166-71
10. Birks JS, Melzer D, Beppu H: Donepezil for mild and moderate Alzheimer's disease. *Cochrane Database Syst Rev* 2000;4:CD001190
11. Masanic CA, Bayley MT, van Reekum R, et al: Open-label study of donepezil in traumatic brain injury. *Arch Phys Med Rehabil* 2001;82:896-901
12. Berthier ML, Posada A, Puentes C, et al: Brain SPECT imaging in transcortical aphasias: The functional status of the left perisylvian language cortex. *Eur J Neurol* 1997;4:551-60
13. Fugl-Meyer AR, Jääskö L, Leyman I, et al: The post-stroke hemiplegic patient: I. A method for evaluation of physical performance. *Scand J Rehabil Med* 1975; 7:13-31
14. Collen FM, Wade DT, Robb GF, et al: The Rivermead Mobility Index: A further development of the Rivermead Motor Assessment. *Int Disabil Studies* 1991;13: 50-4
15. Pujol J, Roset-Llobet J, Rosinés-Cubells D, et al: Brain cortical activation during guitar-induced hand dystonia studied by functional MRI. *Neuroimage* 2000;12:257-67
16. Pujol J, Monells J, Tolosa E, et al: Pseudoathetosis in a patient with cervical myelitis: Neurophysiologic and functional MRI studies. *Mov Disord* 2000;15: 1288-93
17. Tamas LB, Shibasaki H: Cortical potentials associated with movement: A review. *J Clin Neurophysiol* 1985;2:157-71
18. Rothwell JC, Hallett M, Berardelli A, et al: Magnetic stimulation: Motor evoked potentials. The International Federation of Clinical Neurophysiology. *Electroencephalogr Clin Neurophysiol* 1999; 52(suppl):97-103
19. Wassermann EMW, Fuhr P, Cohen LG, et al: Effects of transcranial magnetic stimulation on ipsilateral muscles. *Neurology* 1991;41:1795-9
20. Rossini PM, Rossi S, Tecchio F, et al: Focal brain stimulation in healthy humans: Motor maps changes following partial hand sensory deprivation. *Neurosci Lett* 1996;214:191-5
21. Conforto AB, Kaelin-Lang A, Cohen LG: Increased in hand muscle strength of stroke patients after somatosensory stimulation. *Ann Neurol* 2002;51:122-5