

Brief reports

This section will carry communications of work in progress, preliminary research reports, or interesting and unusual vignettes. Such reports will be considered for their practical clinical relevance or heuristic value.

Korsakoff syndrome following chronic subdural hematoma

Takuji Inagaki, M.D.^{a,*}, Yoshiko Shimitzu, M.D.^b, Ken Tsubouchi, M.D.^a,
Isamu Momose, M.D.^a, Tsuyoshi Miyaoka, M.D.^a, Soichi Mizuno, M.D.^a,
Toshiro Kishi, M.D.^a, Chikako Yamamori, M.D.^b, Jun Horiguchi, M.D.^a

^aDepartment of Psychiatry, Shimane Medical University, Izumo, Japan

^bMatsue Aoba Hospital, Matsue, Japan

Abstract

We describe a patient who developed Korsakoff syndrome following a spontaneous chronic subdural hematoma. The present case demonstrates persistence of both amnesia and confabulation long after recovery from the acute phase of spontaneous chronic subdural hematoma. There are few reports describing persistent amnesia with confabulation following brain damage. We considered that chronic subdural hematoma in the bilateral frontal and temporal lobes caused amnesia and confabulations, and these conditions persisted as a result of organic atrophic changes of both the frontal and temporal lobes due to long-term compression by chronic subdural hematoma. © 2003 Elsevier Inc. All rights reserved.

Keywords: Amnesia; Confabulation; Korsakoff syndrome; Subdural hematoma

1. Introduction

Korsakoff syndrome is a neurobehavioral disorder which consists of memory dysfunction with retrograde and anterograde amnesia, disorientation, confabulation, and limited insight into dysfunction, but with preserved intelligence. The most common etiology of Korsakoff syndrome is thiamine deficiency secondary to alcoholism. There are few case reports of organic brain syndrome, demonstrating persistent amnesia with confabulation following the anterior communication artery rupture, head injury, and cerebral infarction [1,2].

We report a case that developed Korsakoff syndrome following chronic subdural hematoma. The present case suggests that frontal lobe dysfunction may particularly contribute to the development of persistent amnesia with confabulation, i.e., Korsakoff syndrome.

2. Case report

2.1. Clinical description

The patient was a right-handed 55-year-old woman. There was no history of head injury or other neurological or psychiatric diseases. She had no history of drug or alcohol abuse. After graduating from junior high school (9th grade), she had worked as a secretary until the age of 55. She performed routine living activities normally.

In November 1999, she was 54 years old and developed health problems. She retired in March 2000. In April, she presented with insomnia, appetite loss and body weight loss, and was admitted to the general hospital. Because the patient also complained of depressive mood with dysphoria, and bothersome and general fatigue, she was referred to our psychiatric department. The patient was diagnosed as having depression and antidepressant medication (maprotiline 20–30 mg/d) was started. Although her appetite improved during a couple of weeks, she developed perplexed and strange behavior, i.e., she became distracted for a long time while in the toilet, she started to remove her dress when told her meal was ready. These symptoms developed suddenly and fluctuated from day to day. She also developed night

* Corresponding author. Tel.: +81-853-202262; fax: +81-853-202260.

E-mail address: inagak@shimane-med.ac.jp (T. Inagaki).

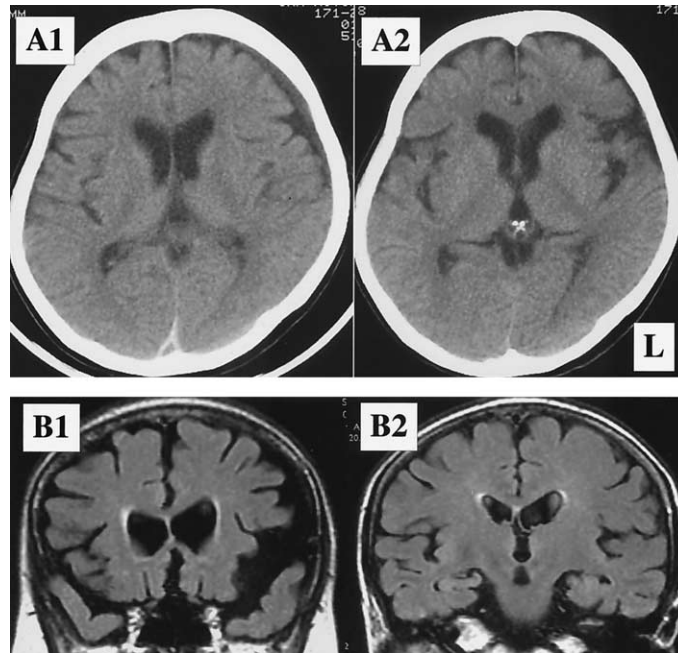


Fig. 1. A1: Brain CT showing chronic subdural hematoma left side dominantly on admission; A2: Diminished subdural hematoma one month after admission; B1 and B2: Flair MR images demonstrate frontal and temporal atrophy with preservation of mesial temporal regions.

delirium, and, therefore, was admitted to our psychiatric ward. On admission, brain CT demonstrated a low-density area on the left frontal region dominantly, indicating chronic subdural hematoma (Fig. 1A). We decided to follow the development of the hematoma clinically by serial CT scanning. In the event of increased fluid accumulation, we intended to perform surgery. After one week her delirious state was improved and the patient became stable and alert. She could wear makeup scrupulously and take a meal without spilling her food. She could answer questions with concentration. However, memory dysfunction with severe amnesia (deficit in both anterograde and retrograde memory systems), disorientation, and confabulation were apparent. For example, she answered that she was in a distant place and a different hospital, and that she was employed in a shop. She said her father was alive (in fact, her father died ten years earlier). Retrograde amnesia was more prominent than anterograde amnesia. She spoke indifferently and sometimes smiled. She also demonstrated limited insight into her dysfunction. These cognitive disturbances were identical to those of Korsakoff syndrome. She scored a 16 on the Hasegawa's dementia rating scale [3], which was in the moderate range. EEG was within normal limits and there was no elevation in a Herpes Simplex titer. The serum levels of vitamin B1, B12, and folate were within the normal range. Although CT demonstrated spontaneous resolution of chronic subdural hematoma, unstable gait and appetite loss continued until June. Her gait was wide based, not ataxic as is usually observed in Wernicke's syndrome. Citicoline iv administration (250 mg/day) was prescribed for ten days. Citicoline was administered for the treatment of cognitive and behavioral disturbance associated with

chronic cerebral disorders. However, there was no remarkable change in her psychotic symptoms. In July, the size of the hematoma gradually diminished on brain CT (Fig.A2), however, she developed emotional lability, i.e., suddenly laughing or crying.

Three months after admission she asked about her house and she said her sister lived in the house which was not the truth. Her sister lived a distance away. The import of the story was wide of the mark. Subdural hematoma had diminished, but frontal and temporal lobe atrophy were noted along with enlargement of bilateral Sylvius fissures (Fig.B1), and preservation of the medial temporal lobes including hippocampal region (Fig.B2). SPECT (with 99m Tc-HMPAO) demonstrated low perfusion in the bilateral frontal, temporal, and parietal lobes, but normal perfusion in the basal ganglia region. She gradually became apathetic and almost bedridden. She said her house was burnt in a fire and she was afraid of giving someone trouble. Therefore, she blamed herself and confabulation was persisted. The loss of spontaneity became conspicuous. She forgot things such as her brother's visit and her recent meal and her amnesia and disorientation remained. From October, five months after admission, she first reported hearing a voice that blamed her for causing a fire from her head. This seemed to be auditory hallucination but could not be distinguished from confabulation. We did not use any neuroleptics. In November, she was moved to another mental hospital for rehabilitation. Thereafter, despite being able to walk, she became almost bedridden. She was autistic, apathetic, and negativistic. Her conversation was repetitive and her contact was superficial.

2.2. Neuropsychological evaluation

She had no signs of aphasia, apraxia or agnosia. She had a Hasegawa's dementia rating scale score of 18, 20, and 25 in May, June, and September in 2000, respectively. Benton Test indicated memory deterioration and the Bender Geshalt Test scores were 106, 118, and 147 in May, June, and October, respectively. These results suggested brain dysfunction. The card sorting test, which evaluates frontal lobe function, indicated perseverance of incorrect reaction and suggested frontal hypofunction. Her total IQ was 77 (verbal IQ 81, performance IQ 73) on the Wechsler Adult Intelligence Scale-Revised in August 2000.

3. Discussion

The present case first developed depressive mood and subsequent delirious state and, therefore, was referred to our hospital. Brain CT disclosed chronic subdural hematoma of the left side dominantly. She had no history of head injury, so chronic subdural hematoma was considered to have occurred spontaneously. As delirium improved, she demonstrated disorientation, amnesia and confabulation. These symptoms were compatible with Korsakoff syndrome. The most common etiology of Korsakoff syndrome is thiamine deficiency secondary to alcoholism [4]. There are a few case reports describing this condition in association with organic brain syndrome. There are some reports that developed persistent anterograde amnesia with marked confabulation following anterior communicating artery rupture, head injury, and cerebral infarction [1,2]. To our knowledge, there are no reports of subsequent subdural hematoma. Korsakoff syndrome is a neurobehavioral disorder that consists of memory dysfunction with retrograde and anterograde amnesia, disorientation, confabulation, and limited insight into dysfunction, but with preserved intelligence. Amnesic syndrome occurs after severe bilateral damage to the medial temporal lobes, the diencephalons or basal forebrain [5]. It has been reported that structural or neurochemical lesions within the limbic-diencephalic circuits produce anterograde amnesia [1], whereas frontal dysfunction either produces or contributes to retrograde amnesia [1,6]. In the present case, retrograde amnesia was more prominent than anterograde amnesia often observed in alcoholic Korsakoff's syndrome. This clinical finding was contributed to frontal lobe damages. The basal forebrain is the critical site responsible for amnesic syndrome despite the absence of diencephalic and mesial temporal lesions [2]. On the other hand, frontal lobe dysfunction (especially damage to the orbital medial pathways) may produce spontaneous confabulation [1,6]. De Luca et al. [2] suggested that confabulation in subjects with aneurysm of the anterior communicating artery may involve both frontal lobe lesions and damage to the basal forebrain.

A review of the relevant literature suggests that amnesia and confabulation are frequently observed in patients during the acute stage of recovery from traumatic brain injury, but some studies report persistent amnesia with severe confabulation in traumatic brain injury patients beyond the post-acute phase of recovery [5]. The present case also demonstrated persistence of both amnesia and confabulation long after the acute phase of recovery after spontaneous chronic subdural hematoma.

In the present case, amnesia and confabulation appeared from the early stage, and persisted despite reduction of the subdural hematoma. Tanaka et al. [7] speculated that CBF reduction in patients with chronic subdural hematoma occurs initially in central areas like the basal ganglia and thalamus, and then, as brain compression and displacement progress, extends to the whole hemisphere, including the cortex. Therefore, we considered that, in this case, chronic subdural hematoma in the bilateral frontal and temporal lobes caused amnesia and confabulation. Furthermore, amnesia and confabulation had been continued as a result of organic atrophic changes in both the frontal and temporal lobes (brain atrophy and low blood perfusion) by long-term compression of chronic subdural hematoma. Similarly, in cases of alcoholic Korsakoff syndrome, impaired flow in the frontal regions was correlated with impaired performance on tests of memory and orientation [8].

The personality changes including asportaneity were considered due to frontal lobe syndrome [2].

References

- [1] Kopelman MD. The Korsakoff syndrome. *Br J Psychiat* 1995;166: 154–173.
- [2] DeLuca J, Diamond BJ. Aneurysm of the anterior communicating artery: a review of neuroanatomical and neuropsychological sequelae. *J Clin Exp Neuropsychol* 1995;17:100–121.
- [3] Katoh S, Simogaki H, Onodera A, et al. Development of the revised version of Hasegawa's dementia scale (HDR-S). *Gerontopsychiatry (Ronen Seishinigaku Zashi)* 1991;2:1339–1347 (in Japanese).
- [4] Visser PJ, Krabbendam L, Verhey FR, et al. Brain correlates of memory dysfunction in alcoholic Korsakoff's syndrome. *J Neurol Neurosurg Psychiatry* 1999;67:774–778.
- [5] Demery JA, Hanlon RE, Bauer RM. Profound amnesia and confabulation following traumatic brain injury. *Neurocase* 2001;7:295–302.
- [6] Kopelman MD. Frontal dysfunction and memory deficits in the alcoholic Korsakoff syndrome and Alzheimer-type dementia. *Brain* 1991; 114:117–137.
- [7] Tanaka A, Yoshinaga S, Kimura M. Xenon-enhanced computed tomographic measurement of cerebral blood flow in patients with chronic subdural hematomas. *Neurosurgery* 1990;27:554–561.
- [8] Hunter R, McLuskie R, Wyper D, et al. The pattern of function-related regional cerebral blood flow investigated by single photon emission tomography with 99m Tc-HMPAO in patients with presenile Alzheimer's disease and Korsakoff's psychosis. *Psychol Med* 1989;19:847–855.