

Subacute Hypoglossal Nerve Paresis with Internal Carotid Artery Dissection

Fred W. Lindsay, DO, David Mullin, MD, Michael A. Keefe, MD

Objectives: To describe a case of an isolated hypoglossal nerve palsy in a patient with a spontaneous internal carotid artery dissection (ICAD). This condition is a well-recognized cause of cerebral ischemic stroke in patients younger than 45 years of age. Isolated cranial nerve neuropathy is a rare presentation. More common manifestations include incomplete hemiparesis, hemiparesis, Horner syndrome, cervical bruit, pulsatile tinnitus, and multiple cranial nerve palsies. **Methods:** A comprehensive literature search (Ovid, MEDLINE) for the presentation, diagnostic evaluation, treatment, and outcome of patients with internal carotid artery dissection was performed. **Results:** A 43-year-old man presented with a 3-week history of mild dysarthria. There was no history of craniocervical trauma. The physical examination revealed an isolated left hypoglossal nerve paresis. Magnetic resonance imaging and angiography findings were consistent with a left skull base ICAD. The patient was successfully treated with anticoagulation therapy. The current rate of cranial nerve involvement is estimated at 10% of all ICADs. This is the second report of isolated hypoglossal nerve palsy without hemiparesis in a case of atraumatic ICAD. **Conclusions:** Patients with an ICAD infrequently present to the otolaryngologist because of its head and neck manifestations. It is crucial to recognize atypical findings and to perform an accurate and prompt diagnostic evaluation. The foundation of treatment is aggressive anticoagulation, with surgical or radiologic intervention reserved for cases demonstrating life-threatening progression. **Key Words:** hypoglossal nerve paresis, internal carotid artery dissection, dysarthria, hemiparesis.

Laryngoscope, 113:1530–1533, 2003

Poster Presentation: The Western Section of the American Laryngological, Rhinological, and Otological Society February 1-3, 2002 Pasadena, CA.

Department of Otolaryngology-Head and Neck Surgery, Naval Medical Center San Diego, San Diego, California, U.S.A.

Editor's Note: This Manuscript was accepted for publication May 7, 2003.

The views expressed in this article are those of the authors and do not reflect the official policy or position of the Department of the Navy, Department of Defense, or the United States Government.

Correspondence to Fred W. Lindsay, DO, Naval Medical Center San Diego, Department of Otolaryngology-Head and Neck Surgery, 34520 Bob Wilson Drive, San Diego, CA 92134, U.S.A.

The evolution of identifying patients with an internal carotid artery dissection (ICAD) over the past 30 years has revealed many variable presentations. Most commonly, the patients are middle-aged and presented with variable penetration of hemiparesis, hemiparesis, oculosympathetic palsy, pulsatile tinnitus, and cervical bruits. Isolated cranial nerve findings are rare, but even more so when there are no other signs or symptoms. We describe a patient who presented with only one cranial nerve involved.

METHODS AND RESULTS

A comprehensive literature search (Ovid, MEDLINE) for the presentation, diagnostic evaluation, treatment, and outcome of patients with internal carotid artery dissection was performed. Six cases of isolated cranial nerve XII palsies are reported, with four appearing in the literature recently.^{1–3} All patients except one had hemiparesis in addition to a palsy.

CASE REPORT

A 43-year-old man with no significant medical history initially consulted his primary care provider because of a 3-week period of worsening difficulty speaking on the phone. The patient was then urgently referred for a comprehensive head and neck examination. A social history revealed a 20 pack-year history of smoking. There was no recent cervical trauma. The patient had a recently increasing social stress (divorce), trace dysphagia with thin liquids, and dysarthria. He denied weight loss, headache, visual changes, or peripheral weakness. Physical examination revealed a left hypoglossal nerve paralysis. Results of nasopharyngoscopy were within normal limits. There was no gross muscle weakness, and cervical and ophthalmologic examination findings were grossly normal.

Magnetic resonance imaging and magnetic resonance angiography were performed, which identified a left-sided skull base ICAD (Fig. 1). The patient underwent an angiogram for confirmation of the lesion and analysis of the dynamic disease. The classic subintimal dissection "string sign" was identified without evidence of aneurysmal dilation (Fig. 2). The patient was admitted for intravenous anticoagulation with heparin, followed by oral warfarin. When the patient was discharged on hospital day 3, the hypoglossal nerve palsy was resolving and no other focal deficits were noted. The patient remained on warfarin anticoagulation until a 5-month follow-up magnetic resonance angiography scan confirmed complete resolution of the dissection. Clinical resolution was complete 2 months after radiographic resolution.

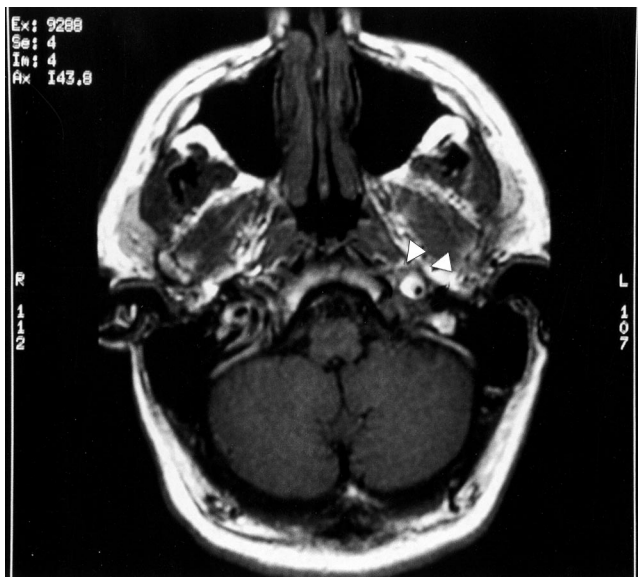

Fig. 1. T1-weighted magnetic resonance imaging scan showing an abnormal flow pattern consistent with dissection of the left internal carotid artery (arrow).

DISCUSSION

Dissection of the ICAD is a rare cause of cerebrovascular accidents and cranial nerve palsies. In a patient with documented disease, there are many clinical presentations, ranging from stroke to nonspecific headache. The classic triad of Horner syndrome (oculosympathetic palsy), hemicrania, and ischemic symptoms is the most common constellation of symptoms, being present in 50% of patients overall and in 20% of patients at presentation.⁴ Ischemic symptoms may occur in the form of transient ischemic attack, complete stroke, or cranial nerve palsies. One study found cranial nerve palsies to be present in up to 12% of patients, with the lower cranial nerves (XII, IX, X, and XI in various combinations) being the most frequently involved.^{4,5} Other studies have shown a 90% incidence of severe headache as a presenting symptom, typically of a different quality than usual in patients with a history of migraine headaches.^{4,5} Other reported head and neck findings, often leading to referral to an otolaryngologist, include dysarthria, dysphagia, pulsatile tinnitus, dysgeusia, recurrent laryngeal nerve paralysis, and ocular motor palsy.

Mokri et al.³ reviewed patients with ICAD at the Mayo Clinic with interesting results. In the patients with documented ICAD, less than 5% had isolated cranial nerve findings and 10% had some cranial nerve deficit. The hypoglossal nerve (XII) was the most commonly involved cranial nerve, with 43% having a deficit. The theorized explanation for this predominance is the hypoglossal nerve's close relationship with the internal carotid artery in the retrostyloid compartment of the neck. The trigeminal nerve (V) was the next most commonly affected, followed by glossopharyngeal nerve (IX) and the vagus nerve (X). It is estimated that half of all ICAD patients have variable Horner syndrome on presentation, with some patients lacking the anhidrosis component.

There are few reports of isolated tongue dysfunction in the literature. Palsy of the twelfth nerve is most commonly accompanied by other cranial nerve palsies or a Horner syndrome with hemicrania and without cerebral ischemia.^{1,2,6} Mokri et al.,² in reviewing the literature and their data, found that the majority of these patients were referred to otolaryngologists. It must be remembered that the absence of headache in the presence of any of the above symptoms does not rule out dissection.⁷

The estimated dissection occurrence rate of 2.6 in 100,000 patients per annum is most likely a low estimate, because many patients are minimally symptomatic. The rate is directly effected by patients treated as having an embolic stroke without identifying the carotid artery as the inciting site.^{4,5,8} In patients younger than 30 years of age with stroke symptoms, it is estimated that at least 20% of cases involve an ICAD.⁹ The percentage of cases with ICAD as a cause decreases as the patient-group gets older, to an overall rate estimated at 2% of all strokes. Most cervical dissections were historically thought to be secondary to trauma. This trauma could be as serious as a multi-injury motor vehicle accident or as minimal as a head thrust from chiropractic manipulation. There is growing literature identifying the majority of patients with spontaneous dissections.^{1,3,5}

Extracranial dissections account for 90% of the lesions. This process usually begins approximately 2 cm distal to the common carotid bifurcation, near the C2-3

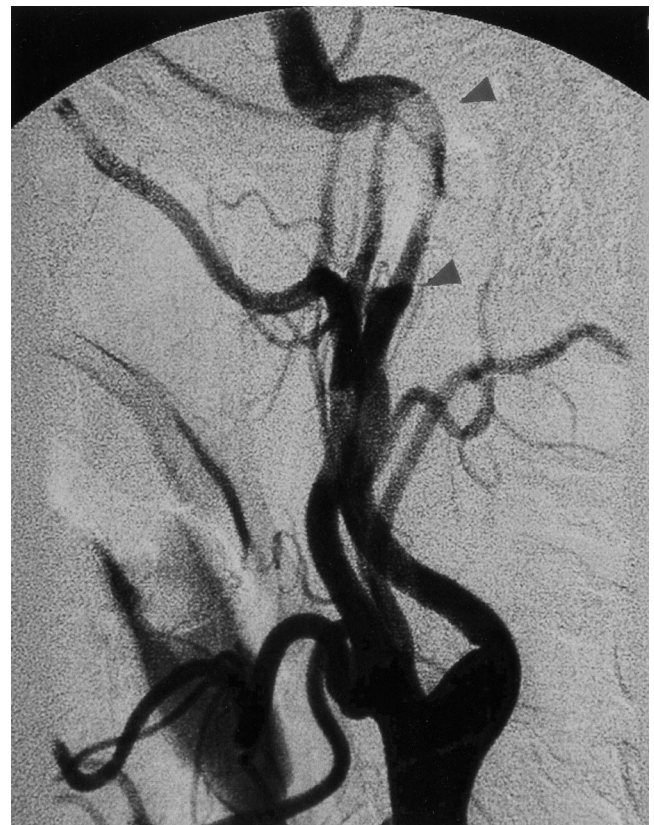


Fig. 2. An angiogram confirmed the internal carotid dissection. The area between the arrows represents the classic string sign.

vertebral level. Dissections are produced by penetration of blood into the vessel wall, usually the medial layer. Accumulated blood between the intima and the media corresponds to a luminal narrowing. A dissection between the media and adventitia creates an aneurysmal dilatation.¹⁰ Fibromuscular dysplasia, Marfan syndrome, and syphilis are a few of the known forerunners to this entity. Mokri et al.¹¹ reviewed the cases of 36 patients and found a prevalence of 14% of the patients with fibromuscular dysplasia. In addition, they found hypertension in 36% of patients, which is more prevalent than observed in the general population. Almost half were active smokers, and another quarter had a history of oral contraceptive use in the past 2 years or had a history of migraine headaches. It appears that arteriosclerosis has little role as a cause of ICAD.¹²

There is debate about the mechanism of lower cranial nerve palsy and Horner syndrome. It is believed that the periarterial sympathetic system is directly affected by the dissection. The sympathetic plexus running along the internal carotid artery projects to the pupil and Mullers muscle. ICAD and the resulting involvement of the sympathetic plexus leads to the common findings of ptosis and miosis. The external carotid periarterial fibers innervating the sudoriferous (sweat) glands of the face are typically spared in ICADs. This explains the manifestation of an incomplete Horner syndrome.² The compression of cranial nerves in the retrostyloid compartment of the neck is a plausible explanation if all lesions had aneurysmal components, which they do not. It is postulated that an anomalous artery originating from the petrous or extrapetrous internal carotid artery in the neck is compromised, leading to direct nerve ischemia. There is also the possibility of an anomalous ascending pharyngeal artery that occludes or spasms during dissection and temporarily interrupts the blood supply to the skull base and multiple cranial nerves.

Several radiologic methods have been used for obtaining the diagnosis. Magnetic resonance imaging and magnetic resonance angiography are the growing standards of care. In cases of carotid dissection, the intramural hemorrhage appears as crescent-shaped hyperintensity that surrounds the narrowed lumen. The estimated sensitivity and specificity for the diagnosis is greater than 90%. This imaging method has its drawbacks: low sensitivity for fibromuscular dysplasia and for aneurysmal dissections.⁵ The gold standard for diagnosis at this time continues to be a carotid and cerebral angiogram. A tapered stenotic segment is the most common finding and is referred to as a *string sign*. Mokri et al.¹¹ found that 32 of 46 (70%) patients had this dissection pattern. Cervical and transcranial Doppler ultrasonography has been used by several authors for monitoring intracranial hemodynamic effects and for the resolution of dissection.^{5,8}

Anticoagulation is the treatment of choice. Most authors favor heparin for a minimum of 72 hours while the patients are started on warfarin and coagulation parameters are stabilized at 1.5 to 2.5 INR.^{1,4,5} Endovascular stenting and balloon dilation have been used and described in the literature as alternatives to surgical therapy in patients with progressive conditions.^{13,14} Surgery is recommended only in the most dire of cases because of

the risk for further morbidity. Multiple procedures have been used for ICAD, including endarterectomy, resection with grafting, thrombectomy, and extracranial-intracranial bypass. Balloon occlusion studies to assess for collateral cerebral blood flow should be performed prior to surgical intervention if possible.¹⁰

Spontaneous ICAD is considered to have a favorable outcome, with approximately 90% of patients' conditions resolving without serious sequelae. Most reports find that recanalization is seen in more than two thirds of patients, and the recurrence rate is less than 10%.⁴

There is a growing body of reports of spontaneous ICAD with and without cranial nerve findings. It is believed that one third to one half of patients will have some progressive cerebrovascular symptoms after presentation with headache, Horner syndrome, or other softer physical signs.¹⁵ To our knowledge, this is the second report of an isolated cranial nerve XII finding without hemiparesis, trauma, visual complaints, or oculosympathetic palsy.

CONCLUSIONS

Internal carotid artery dissection with an isolated cranial nerve finding is rare. An astute otolaryngologist, in performing a head and neck examination, will most likely never miss an obvious cranial nerve paralysis. Vigilance in responding to the atypical presentations of ICAD is warranted because the condition of patients with this process can easily deteriorate to a cerebrovascular accident that could be life threatening. Magnetic resonance imaging and magnetic resonance angiography are excellent tools for expeditiously evaluating acute or subacute cranial nerve deficits. Angiography remains the standard for diagnosis of ICAD in most institutions. Patients with this diagnosis should be admitted to intensive care for anticoagulation and observation. Surgery and endovascular stenting are reserved for patients whose condition progresses on anticoagulation therapy. Full recovery and resolution of dissection is the most likely outcome.

BIBLIOGRAPHY

1. Verdale P, Herve S, Kossowski M, et al. Spontaneous dissection of the internal carotid artery in its extracranial portion, revealed by a hypoglossal paralysis: report of four cases. *Ann Otol Rhinol Laryngol* 2001;110:794-798.
2. Mokri B, Schievink W, Olsen K, Piepgras D. Spontaneous dissection of the cervical internal carotid artery. Presentation with lower cranial nerve palsies. *Arch Otol Head Neck Surg* 1992;118:431-435.
3. Mokri B, Silbert P, Schievink W, Piepgras D. Cranial nerve palsy in spontaneous dissection of the extracranial internal carotid artery. *Neurology* 1996;46:356-359.
4. Guillon B, Levy C. Internal carotid artery dissection: an update. *J Neurol Sci* 1998;153:146-158.
5. Zetterling M, Carlstrom C, Konrad P. Internal carotid artery dissection. *Acta Neurol Scand* 2000;101:1-7.
6. Waespe W, Niesper J, Imhof HG, Valavanis A. Lower cranial nerve palsies due to internal carotid dissection. *Stroke* 1988;19:1561-1564.
7. Fisher CM. The headache and pain of spontaneous carotid dissection. *Headache* 1982;22:60-65.
8. Schievink WI, Mokri B, Whisart JP. Internal carotid artery dissection in a community, Rochester, Minnesota, 1987-1992. *Stroke* 1993;24:1678-1680.
9. Bogousslavsky J, Regli F. Ischemic stroke in adults younger than 30 years of age. Cause and prognosis. *Arch Neurol*

1987;44:479–482.

10. Anson J, Crowell R. Cervicocranial arterial dissection. *Neurosurg* 1991;29:89–96.
11. Mokri B, Sundt T, Houser OW, Piepgras D. Spontaneous dissection of the cervical internal carotid artery. *Ann Neurol* 1986;19:126–138.
12. Mokri B. Traumatic and spontaneous extracranial internal carotid artery dissections. *J Neurol* 1990;237:356–361.
13. DeOcampo J, Brillman J, Levy D. Stenting: a new approach to carotid dissection. *J Neuroimaging* 1997;7:187–190.
14. Hong MK, Satler LF, Gallino R, Leon MB. Intravascular stenting as a definitive treatment of spontaneous carotid artery dissection. *Am J Cardiol* 1997;79:538.
15. Bogousslavsky J, Despland PA, Regli F. Spontaneous carotid dissection with acute stroke. *Arch Neurol* 1987;44:137–140.

Color Photos for Cover of THE **Laryngoscope**™ FOUNDED IN 1896

Authors are encouraged to submit color photographs to be considered as the cover illustration. The photo should relate to the subject of the manuscript submitted for publication but need not be used in the manuscript.

If the photo appears as an illustration in the manuscript, please indicate which photo is suggested for the cover. If the photo is not part of the manuscript, please submit two (2) copies with the manuscript and indicate that an additional photo has been included for possible use as a cover photo.

The cover photo must be accompanied by a separate legend written for the interest of the general reader. The cover legend appears on the last page of the Table of Contents. Authors are encouraged to refer to previous issues of *The Laryngoscope* for examples of cover legends.