

CASE REPORT

Hot-water epilepsy in an adult: ictal EEG, MRI and SPECT features

F. LISOVOSKI, S. PRIER, P. KOSKAS, T. DUBARD, J.L. STIEVENART*, H. DEHEN & J. CAMBIER

*Clinique Neurologique Paul Castaigne et *Service de Médecine Nucléaire, Hôpital Beaujon, Clichy, France*

Correspondence to Dr F. Lisovoski, Clinique Neurologique Paul Castaigne, Hôpital Beaujon, 100 Boulevard du Général Leclerc, 92110 Clichy, France

Reflex epilepsy constitutes a rare form of epileptic seizures. We observed a 20-year-old man who presented with seizures induced by immersion in hot water. The trigger stimulus was specific. Contrast CT scan and MRI were all normal, not revealing any structural lesion. Ictal EEG recorded during a hot bath showed focal epileptic discharges in the left temporo-occipital area. Interictal SPECT showed a hypometabolism in the same cerebral region. Neuroimaging studies were rarely performed in this uncommon type of epilepsy. Nevertheless, in our case the result of the SPECT suggests a localized functional disturbance in the emergence of the disorder.

Key words: reflex epilepsy; partial seizures; hot water; SPECT.

INTRODUCTION

Epileptic seizures precipitated by sensory stimuli are considered as 'reflex epilepsy' and constitute only 5-6% of all cases of epilepsy. The nature of the critical stimulus varies: auditory, olfactory, visual or tactile stimuli can provoke epileptic fits. Epilepsy induced by water immersion has been previously reported, especially in India. The first reports described three children aged 10 years, 7 years and 5 months¹⁻³. Magnetic resonance imaging (MRI) and single photon emission computed tomography (SPECT) examination have been performed infrequently. Moreover, this type of reflex epilepsy is rare in Europe, particularly in adults.

We report a case of hot-water epilepsy in a 20-year-old patient with ictal electroencephalogram (EEG) recording, MRI and SPECT results. We discuss the mechanism of this uncommon type of epilepsy.

CASE REPORT

The patient was born at full-term and birth was uncomplicated: forceps were used during

the delivery. During childhood, he presented with dyslexia leading to a moderate school backwardness. At the age of 10 years, he had some episodic sleep-walking troubles, but there was no psychomotor retardation and neurological examination was normal. In particular, there was no hypotonia.

He developed seizures at the age of 15 years. These consisted of spasmodic contractions of his right hand followed by painful paresthesias of his right upper limb, repetition of the same syllable, then loss of consciousness with generalized convulsions. EEG, CT scan and cerebral angiography were normal. Treatment with sodium valproate in a daily dose of 1500 mg was efficacious. No new epileptic seizures occurred under this treatment. Anticonvulsant medication was continued until the age of 18 years and was then gradually withdrawn. At the age of 20 years, the patient began to experience stereotyped abnormal sensations when taking his bath. Whenever he immersed himself in hot water, he immediately had a feeling of being forced to count in his mind and felt strange without losing consciousness. These episodes were always accompanied by the same 'dream': he saw himself in his bath at the age of

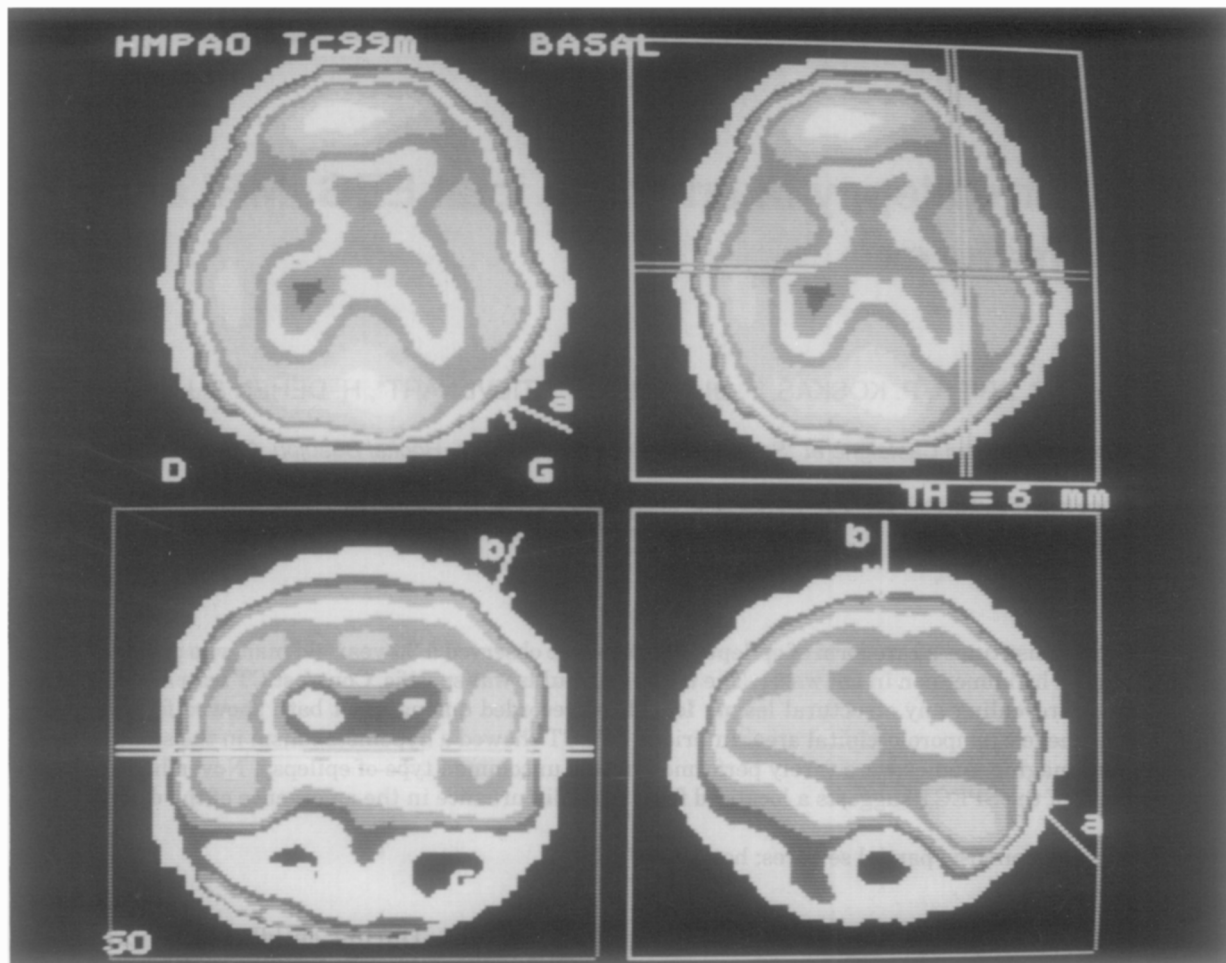


Fig. 1: Transverse, coronal and sagittal slices of interictal SPECT (HMPAO Tc 99 m, transverse slices obtained 10 min after injection in a plane parallel to the orbito-meatal line, reconstruction with a Wiener filter). Transverse views 5 cm above the orbito-meatal line show marked hypoperfusion predominating in the left temporo-occipital region.

4–5 years, playing with his toys. This dreamy state stopped immediately after he came out of the hot water. On one occasion the troubles appeared whilst the patient was showering. Neither heat nor steam was sufficient to provoke the symptoms unless bathing. Neurological examination was normal.

The results of routine blood chemistry were normal. An EEG was recorded in usual conditions and was normal. Hyperventilation as well as intermittent light stimulation did not provoke any abnormalities. CT scan and MRI were normal. SPECT showed a marked left temporo-occipital hypoperfusion (Fig. 1). A 24-hour EEG recording was performed. When the patient was placed into hot water (37°C) for bathing, he reported the feelings described above. At the same time, the EEG showed discharges of irregular and rhythmical spikes or spikes and slow waves in the left temporo-occipital area (Fig. 2). To confirm these findings, a

repeat examination was made under similar circumstances producing the same results. Antiepileptic drug treatment with carbamazepine was started and found to be effective.

DISCUSSION

The outstanding feature of the case reported here is that the epileptic phenomenon was always induced by the same condition and it was therefore considered as reflex epilepsy. Steam alone did not provoke seizure, eliminating a reflex epilepsy induced by an olfactory stimulus. Reflex epilepsy due to water immersion has been previously reported^{1–3} and is known as 'hot-water epilepsy' or 'water-immersion epilepsy', the largest series studied being from Southern India⁴. In this region, the custom for washing is to pour cupfuls of hot water directly over the head. The temperature

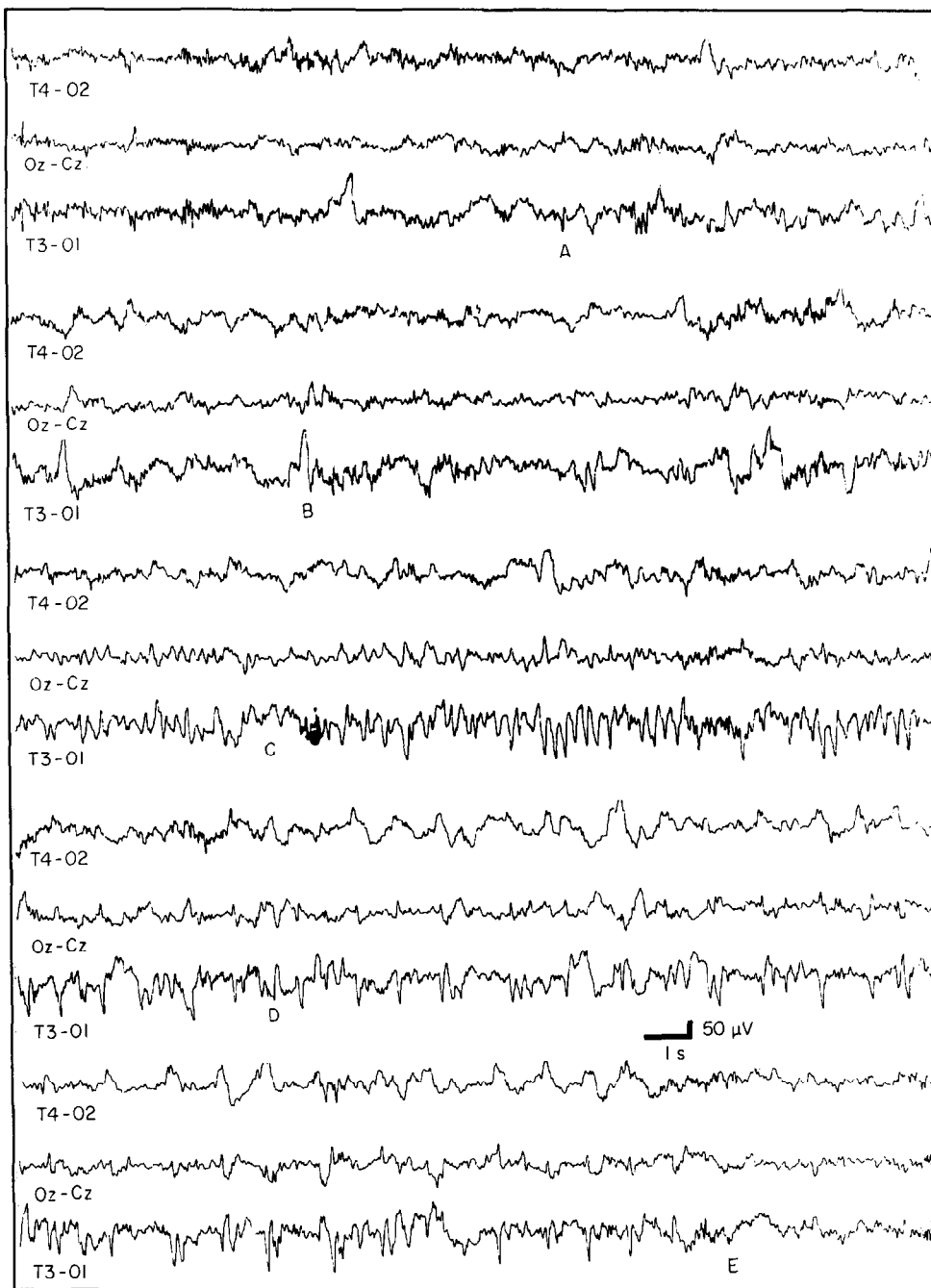


Fig. 2: EEG recording of a seizure during hot bath. A. Left temporo-occipital spikes which become more frequent in B, C and D. Left rhythmic spikes with subsequent irregular spike and slow waves. E. End of seizure.

of water used for bathing in India ranges between 40–50°C, which is higher than the temperature of water used in Europe. Seizure frequency depended upon the frequency of head bathing. This disorder is more common in children, with cases more frequent among male than female patients⁴. The onset of hot-water epilepsy in adults is rare, particularly in Europe, explaining why few studies using neuroimaging techniques have been devoted to this type of reflex epilepsy.

The simultaneous mechanical and thermal

stimulation constituted a highly specific stimulus: attempts to provoke seizures by other methods such as blowing hot air or using water of ambient temperature failed to induce seizures. Pouring hot water only on the head did not lead to seizures in our patient. On the other hand, immersion in hot water was not absolutely necessary, since a shower could induce an attack.

Complex partial seizures constituted the most frequent clinical presentation in a previous report⁵. Sixteen to 38% of the patients

developed non-reflex epilepsy by the end of 2 years after the onset of hot-water epilepsy^{6,7}, but in very few patients non-reflex epilepsy could precede reflex epilepsy⁴. In the present case, non-reflex epilepsy preceded the reflex partial seizures, which should be classified as simple partial seizures with psychic symptoms and not as complex partial seizures according to the classification of the International League Against Epilepsy⁸.

The pathophysiology of this type of epilepsy is not clear. The possibility of a syncope of vasogenic origin has been suggested in the literature⁹, but this hypothesis could be ruled out in the present case because of ictal EEG recordings. Few cases of hot-water epilepsy have been studied by MRI. It has been suggested that a structural lesion in the temporal lobe could explain partial seizures and focal features of ictal EEC¹⁰. MRI was normal in our case, but we cannot rule out this hypothesis. Another approach for this type of epilepsy is to consider a locally increased excitability of cerebral structures. SPECT allowed a functional cerebral investigation. Interictal SPECT in our case disclosed a hypometabolism in the left temporo-occipital region, which could constitute a cerebral focus inducing seizures. However, the relation between the reflex mechanism of this epilepsy and the functional involvement of these cerebral structures remains unclear. Nevertheless, an ictal SPECT study could be more useful in understanding the mechanism of this reflex epilepsy if it could be realized during the ictal period.

Changing the method of bathing can constitute a sufficient treatment. Considering the

existence of a potential cerebral focus, anti-epileptic drug treatment with carbamazepine allows the best control of this epilepsy.

REFERENCES

1. Allen, I.M. Observations on cases of reflex epilepsy. *New Zealand Medical Journal* 1945; **44**: 135–142.
2. Mofenson, H.C., Weymuller, C.A. and Greensher, J. Epilepsy due to water immersion—An unusual case of reflex sensory epilepsy. *Journal of the American Medical Association* 1965; **191**: 600–601.
3. Keipert, J.A. Epilepsy precipitated by bathing: water-immersion epilepsy. *Australian Paediatric Journal* 1969; **5**: 244–247.
4. Satishchandra, P., Shivaramakrishana, A., Kaliaperumal, V.G. and Schoenberg, B.S. Hot-water epilepsy: a variant of reflex epilepsy in Southern India. *Epilepsia* 1988; **29**: 52–56.
5. Mani, K.S., Mani, A.J. and Ramesh, C.K. Hot water epilepsy. A peculiar type of reflex epilepsy. Clinical and electroencephalographic features in 108 cases. *Trans American Neurological Association* 1975; **99**: 224–226.
6. Subrahmanayam, H.S. Hot-water epilepsy. *Neurology (India)* 1972; **20** (Suppl. II): 241–243.
7. Mani, K.S., Mani, A.J., Ramesh, C.K. and Ahuja, G.K. Hot-water epilepsy, clinical and electroencephalographic features—study of 60 cases. *Neurology (India)* 1972; **20** (Suppl. II): 237–240.
8. Commission on Classification and Terminology of the International League Against Epilepsy. Proposal for revised clinical and electroencephalographic classification of epileptic seizures. *Epilepsia* 1981; **22**: 489–501.
9. Roos, R.A.C. and Van Dijk, J.G. Reflex-epilepsy induced by immersion in hot water. *European Neurology* 1988; **28**: 6–10.
10. Szymonowicz, W. and Meloff, K.L. Hot-water epilepsy. *Canadian Journal of Neurological Sciences* 1978; **5**: 247–251.