

# Bilateral Cerebrovascular Accidents in Incontinentia Pigmenti

Loretta Fiorillo, MD\*,  
D. Barry Sinclair, MD<sup>†</sup>,  
Mary L. O'Byrne, MD<sup>†</sup>, and  
Alfons L. Krol, MD\*

**Incontinentia Pigmenti is an X-linked dominant neurocutaneous disorder with central nervous system manifestations in 30% of cases, including seizures and mental retardation. Ischemic or hemorrhagic cerebrovascular accidents have been reported rarely in incontinentia pigmenti. Chart review and literature search was performed following identification of the index case. We describe a patient with incontinentia pigmenti who developed bilateral cerebrovascular accidents in the neonatal period, with resultant severe neurologic sequelae. This is the second reported case of bilateral cerebrovascular accidents in a patient with incontinentia pigmenti. This finding may be secondary to cerebrovascular anomalies, similar to those observed in the retina. Recognition of cerebrovascular accidents as a complication of incontinentia pigmenti will hopefully lead to earlier recognition and treatment. © 2003 by Elsevier Inc. All rights reserved.**

Fiorillo L, Sinclair DB, O'Byrne ML, Krol AL. Bilateral cerebrovascular accidents in incontinentia pigmenti. *Pediatr Neurol* 2003;29:66-68.

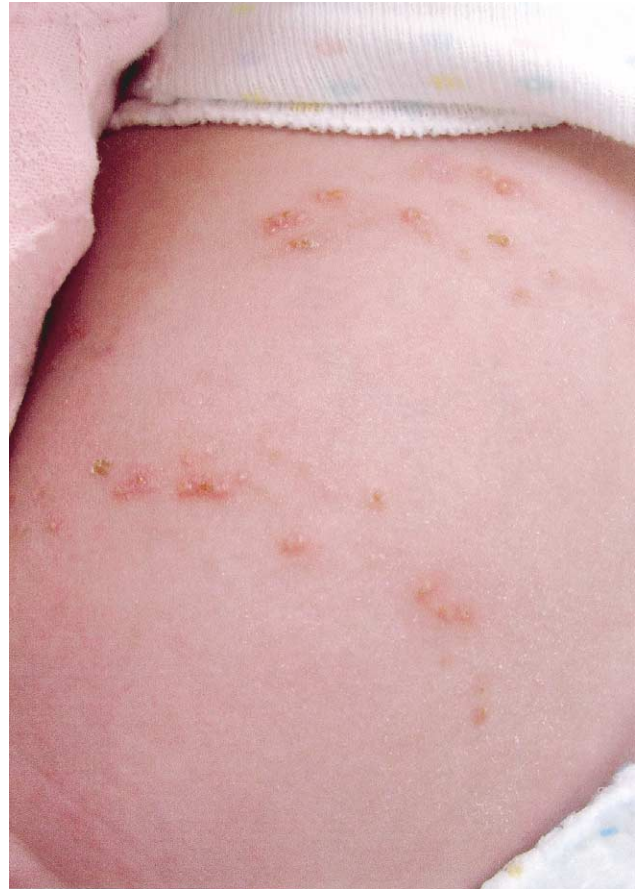

Figure 1. Typical early dermatologic findings with vesicles were identified soon after birth.

## Introduction

Incontinentia pigmenti (IP) or Bloch-Sulzberger syndrome is an X-linked dominant neurocutaneous disorder with cutaneous, dental, ocular, and central nervous system (CNS) manifestations [1]. The incidence of the latter is said to be higher in the sporadic form of the disease and may reach 30%. CNS involvement in the neonatal period is a poor prognostic sign. Seizures, spasticity, developmental delay, and microcephaly are the most commonly reported manifestations. The pathogenesis of CNS abnormalities is unknown, but it may relate to cerebral or cerebrovascular anomalies, similar to those observed in the retina.

From the Division of \*Pediatric Dermatology, <sup>†</sup>Pediatric Neurology, Walter Mackenzie Health Sciences Centre, University of Alberta, Edmonton, Alberta, Canada.

Communications should be addressed to:  
Dr. Sinclair, Director, Division of Pediatric Neurology; 2C3 Walter MacKenzie Health Sciences Centre; University of Alberta; Edmonton, Alberta, Canada T6G 2B7  
Received August 20, 2002; accepted January 28, 2003.

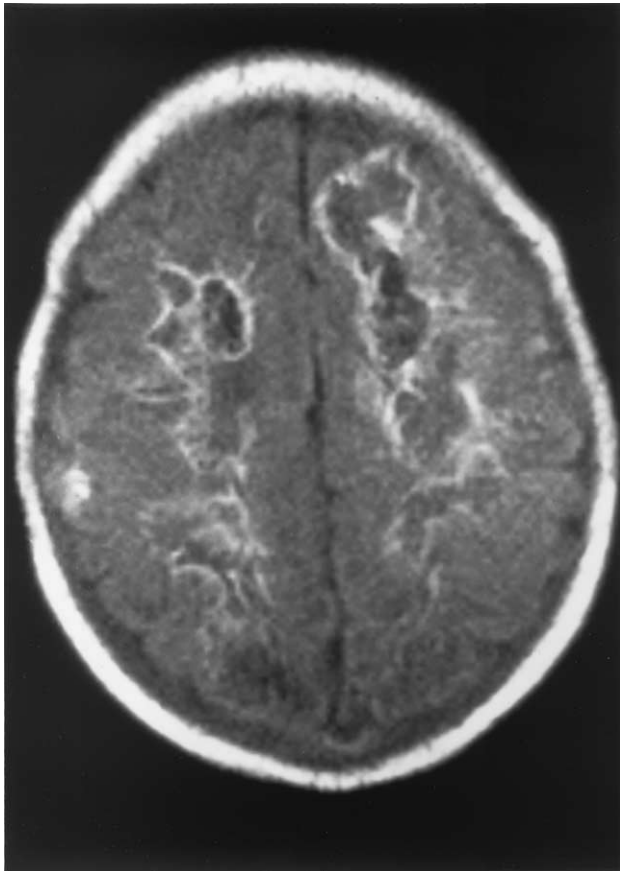


Figure 2. MRI on day 11 (TR6000/TE105). Axial flair images indicate markedly abnormal signal change in deep and subcortical white matter of the cerebrum due to widespread bilateral ischemia and infarction with hemorrhagic and microcalcification of the affected regions.

## Case Report

A 3200-g term female was delivered by cesarean section for mild fetal distress to a 25-year-old primigravida mother. The infant was well at birth, with Apgar scores of 9 and 10 at 1 and 5 minutes, respectively. There was no history of genital herpes in either parent, or alcohol or drug use. A bilateral vesicular rash on forearms and thighs was noted at birth, with clusters of flaccid vesicles with cloudy content (Fig 1). The general physical examination was normal, including normal neurologic examination. The infant was well for the first 2 days.

On day 3 she became lethargic, then irritable, developed apnea and facial twitching; the skin eruption increased with development of new vesicles, large erythematous and urticarial plaques. After a full septic evaluation, she was started on cefotaxime, cloxacillin, and acyclovir. On day 4 she developed repetitive multifocal seizures of simple and partial complex types. She also developed transient apneic spells with the seizures for which she was intubated, mechanically ventilated, and transferred to a tertiary care center. Seizures were difficult to control and finally responded to a number of antiepileptic medications including phenobarbital, phenytoin, and diazepam, but remained difficult to control. Blood, urine, and cerebrospinal fluid (CSF) cultures were negative. Skin biopsy showed epidermal spongiosis, exocytosis of eosinophils in the epidermis, and dermal eosinophilic infiltrate both perivascular and diffuse, confirming a diagnosis of incontinentia pigmenti.

Computed tomography (CT) scan of the brain on day 5 documented diffuse cerebral ischemia and edema, particularly involving the cerebral white matter. Magnetic resonance imaging (MRI) performed on day 11 (Fig 2) showed markedly abnormal signal in the deep and subcortical white matter bilaterally, only sparing the right temporal lobe. A repeat

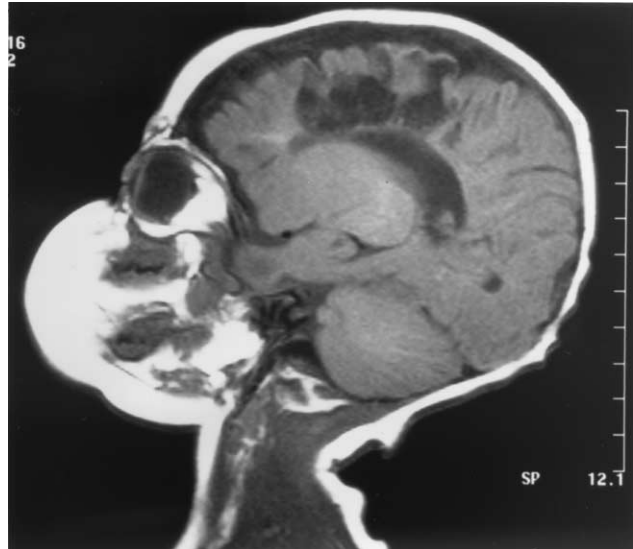


Figure 3. MRI at 3 months (TR540/TE15). Sagittal sequence demonstrates extensive areas of low and absent signal in the white matter of the frontal and parietal lobes, suggestive of extensive encephalomalacia and periventricular leukomalacia.

MRI at 3½ months (Fig 3) revealed extensive bilateral encephalomalacia and periventricular leukomalacia with gliosis, from previous ischemic insult. Electroencephalogram (EEG) indicated a slow and disorganized background with multifocal epileptiform discharges over both hemispheres.

Eye examination with fluorescein angiography revealed capillary non-perfusion of the superior retina, from 11 to 1 o'clock in the right eye and a similar but smaller area of non-perfusion in the left eye.

Seizures became controlled on day 8. Phenytoin and diazepam were discontinued. The child is now 23 months old; her cutaneous manifestations have evolved to marbled hypopigmentation of both legs with atrophy of hair follicles, bizarre hyperpigmented streaks on trunk, and delayed eruption of teeth. She has not had further seizures and remains on phenobarbital monotherapy. Persistent CNS manifestations include spastic quadriplegia, severe global cognitive developmental delay, and microcephaly. A repeat CT of the head at 19 months revealed no interval change in the areas of infarction. Ocular symptoms include bilateral severe hyperopia, right exotropia and mild right amblyopia.

Complete cutaneous, dental, ocular, and genetic examination of the mother including analysis of the NF-kappa B essential modulator (NEMO) gene failed to reveal any abnormality, and our patient was thought to represent a spontaneous mutation.

## Discussion

Skin manifestations of IP are well characterized and pathognomonic. They are divided into four stages: Stage 1, characterized by crops of vesicles in linear distribution. These are often present at birth or develop in the first week of life in the majority of cases. Stage 2 is characterized by hyperkeratotic and verrucous papules. Stage 3 is characterized by whorls of hyperpigmentation. Stage 4 is characterized by scarring hypopigmentation.

CNS manifestations include spastic tetraplegia and diplegia, mental retardation, microcephaly, and seizures. The pathogenesis of the CNS correlates is incompletely understood. Ischemic cerebrovascular accidents (CVA) as a complication of IP and as a cause of severe neurologic

sequelae has been recognized only recently, and to our knowledge there are only 8 reported cases [2-6] of which only one was bilateral [6]. Because neuroimaging studies have not been routinely conducted in IP, it is possible that the frequency of CVA is underestimated, and that it could account for at least a subset or even the majority of the observed cases of spastic paresis, seizures, and mental retardation.

Vascular abnormalities and occlusion of the retinal vessels are well described in the literature and have been also demonstrated in this patient by retinal fluorescein angiography. It is possible that the retinal and cerebral vasculature share the same vulnerability, either to inflammation or as part of hypersensitivity reaction to an abnormal protein expressed by the mutant gene [4].

Lack of awareness of ischemic or hemorrhagic CVA as complications of IP lead to a search for alternative explanation for the presence of MRI changes. Shuper et al. postulated that the bilateral hemorrhagic necrosis observed in their patient's MRI was due to a primary destructive encephalopathy [6]. A very extensive search for an infection or inflammatory cause, including a needle biopsy of the brain, was negative. In our patient, the MRI evidence of ischemic stroke was initially thought to be secondary to hypoxic-ischemic encephalopathy at birth, but careful review of birth records and of the first 2 days of life failed to substantiate this hypothesis. Bacterial and viral cultures of CSF, blood, and urine were negative; HSV serology was also negative, excluding an infectious cause. Eventually a diagnosis of bilateral CVA as a complication of IP was made. IP needs to be included in the list of differential

diagnosis of neonatal or infantile CVA, at least in the female population.

## Conclusion

Cerebrovascular accidents can be unrecognized neurologic complication of IP. We recommend neuroimaging with MRI/magnetic resonance angiography of all cases of IP at time of diagnosis to identify possible baseline CNS abnormalities. Repeat investigations should be performed upon the onset of seizures or other new neurologic sign to exclude CVA as a cause for neurologic symptoms. Hopefully, recognition of CVA as a complication of IP will lead to earlier detection and treatment.

## References

- [1] **Mirowski** GW, **Caldemeyer** KS. Incontinentia pigmenti. *J Am Acad Dermatol* 2000;43:517-8.
- [2] **Chatkupt** S, **Gozo** A, **Wolansky** L, **Sun** S. Characteristic MR findings in a neonate with incontinentia pigmenti. *AJR Am J Radiol* 1993;160:372-4.
- [3] **Pellegrino** RJ, **Shah** AJ. Vascular occlusion associated with incontinentia pigmenti. *Pediatr Neurol* 1994;10:73-4.
- [4] **Lee** G, **Goldberg** M, **Gillard** J, **Barker** P, **Bryan** N. Intracranial assessment of incontinentia pigmenti using magnetic resonance imaging, angiography, and spectroscopic imaging. *Arch Pediatr Adolesc Med* 1995;149:573-80.
- [5] **Kasai** T, **Kato** Z, **Matsui** E, et al. Cerebral infarction in incontinentia pigmenti: The first report of a case evaluated by single photon emission computed tomography. *Acta Paediatr* 1997;86:665-7.
- [6] **Shuper** A, **Bryan** RN, **Singer** H. Destructive encephalopathy in incontinentia pigmenti: A primary disorder? *Pediatr Neurol* 1990;6:137-40.