

# VISUAL ASSOCIATIVE AGNOSIA AND OPTIC APHASIA. A SINGLE CASE STUDY AND A REVIEW OF THE SYNDROMES\*

Lucio Iorio<sup>1</sup>, Angelamaria Falanga<sup>2</sup>, Nina A. Fragassi<sup>2</sup> and Dario Grossi<sup>2</sup>

(<sup>1</sup>Neurological Department, Scientific Institute Sanatrix, Venafro, Isernia; <sup>2</sup>Neurological Clinic, University of Naples)

## INTRODUCTION

Visual associative agnosia is a rare neuropsychological syndrome characterized by a defect in recognizing visually presented stimuli despite normal visual perceptual and intellectual processes (Lissauer, 1890). There are two main anatomical explanations of the syndrome. Benson, Segarra and Albert (1974) pointed to the presence of bilateral temporo-occipital lesions, a finding confirmed by the case of Albert, Soffer, Silverberg et al. (1979). The latter authors suggested that bilateral damage in infero-temporo-occipital regions, often due to infarction in the territory of posterior cerebral arteries, produces a visuo-limbic disconnection, which hampers the transmission of visual input to the visual memory store in the limbic system. In reviewing the topic, Alexander and Albert (1983) proposed that visual associative agnosia is always the consequence of bilateral lesions.

Yet there is clear evidence of visual associative agnosia due to left unilateral occipital damage (Ferro and Santos, 1984; Mc Carthy and Warrington, 1986). This finding is in keeping with the greater impairment found following left hemisphere damage in associative functions and semantic categorization (De Renzi, Scotti and Spinnler, 1969; Warrington, 1982). Visual agnosia from left sided lesion has been interpreted in terms of visuo-verbal disconnection (Geschwind, 1965), on the assumption that interruption of interhemispheric transfer through the corpus callosum in patients with right hemianopia would prevent visual information received by the right hemisphere from reaching language areas sited in the left hemisphere. This interpretation is virtually identical to that given for optic aphasia (Freund, 1889), a syndrome in which the defect of visual naming is not due to recognition disturbance. The linkage between the two syndromes is stressed by the fact that both often result from left posterior cerebral artery infarction, and some authors (Rubens, 1979; De Renzi, Zambolin and Crisi, 1987) have proposed that they may represent different degrees of the same disturbance, optic aphasia being less severe than visual agnosia.

From the clinical point of view, the distinction should be focused on evidence of recognition of the object, in agreement with the definition of the syn-

---

\* A preliminary version of this paper was presented at the Sixth European Workshop on Cognitive Neuropsychology, Bressanone (Italy), 1988.

dromes. Visual agnosia is labelled as a disturbance of recognition (Lissauer, 1890), whereas it is a requirement for the diagnosis of optic aphasia that mis-named objects are correctly recognized (Freund, 1889; Beauvois, 1982). Those naming errors that bear a relationship to the stimulus may provide information about recognition. Circumlocutions are suggestive of correct identification, semantic errors of access to the semantic field of the item, and visual errors of complete failure of recognition. Other responses bearing no relationship to the stimulus, such as unrelated, perseverative and confabulatory responses, as well as “no responses”, are not informative of the level at which the visual input has been processed. Recognition should be verified with an inquiry or with tasks not requiring a verbal response, such as pantomimes, semantic categorization, and matching objects for function. However, the outcome of these tests should be interpreted with caution, because they can be passed even if the patient has achieved only superordinate semantic knowledge, without identification of the subordinate category to which the item belongs. Following the above criteria, we have investigated the nature of the naming disorder in the present case, and have found aspects both of visual associative agnosia and of optic aphasia, a finding that challenges the anatomoclinical autonomy of the two syndromes.

#### CASE REPORT

G.P., a 60 year-old right-handed coral-cutter, with 5 years of schooling, suddenly developed right paresthesias followed by right hemiparesis and hemianopia. In the following days the motor deficit improved whereas difficulties in reading and in recognizing objects and pictures became evident. The patient came to our observation one month after the onset. He was oriented in time and space and complained of disturbances of vision and memory. Neurological examination revealed mild right hemiparesis, hypoesthesia in the right upper limb, alexia, difficulty in recognizing objects from vision and right hemianopia (confirmed by perimetry). Language and the remaining neurological examination were normal. A CT-scan, carried out two months later, showed a left occipital area of hypodensity, compatible with an infarction in the territory of left posterior cerebral artery (Figure 1).

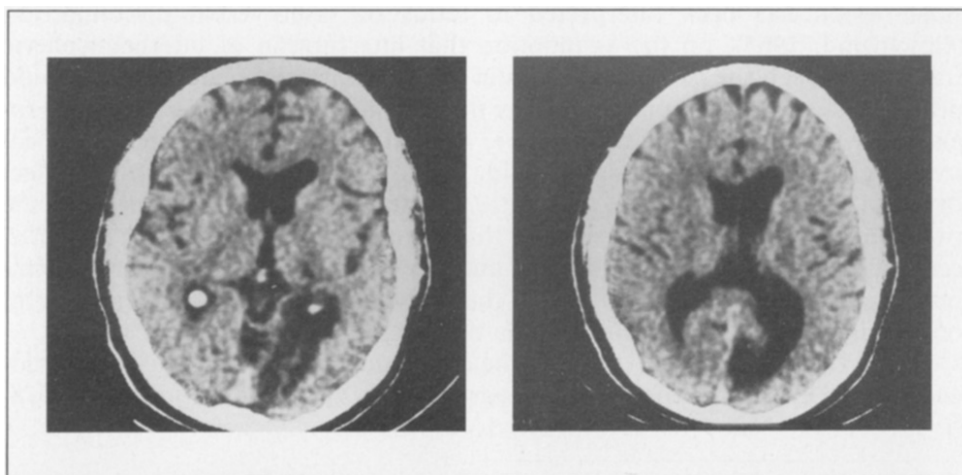


Fig. 1 - CT scan showing infarction in the territory of the left posterior cerebral artery.

*General neuropsychological testing*

*Intellectual level.* G.P.'s full scale IQ on the W.A.I.S. was 79. He found greater difficulty in the subtests requiring a visual analysis (verbal IQ 85, performance IQ 72). His score on Raven's Coloured Progressive Matrices (1984) was 21/36 (25th centile).

*Language.* Spontaneous speech was fluent, without paraphasias, circumlocutions, articulatory or syntactic errors. On a standard language examination (Basso, Capitani and Vinolo, 1979) naming problems were found for visually presented stimuli (see below). Repetition was normal. He scored 24/36 on the shortened version of the Token Test. Spontaneous writing and writing to dictation were flawless. Reading was impaired. He could read 34/42 (81%) letters, 50/61 (82%) words (11/13 functors, 19/20 verbs, 11/16 adjectives, 9/12 nouns, 24/30 high frequency words, 26/31 low frequency words) and 26/53 (49%) non-words. His mean reading time increased with the letter length (7 sec. for words of 4-7 letters and 13 sec. for words of 8-11 letters, 10 sec. for non-words of 4-6 letters and 16 sec. for non-words of 7-9 letters), a finding compatible with a pattern of letter-by-letter reading. Number writing and reading were well performed.

*Memory.* Verbal digit span was 4. Corsi's spatial span was 4. Both were in the normal range (Orsini, Grossi, Capitani et al., 1987). Word span of 3 was below normal range (Spinnler and Tognoni, 1987). The criterion for spatial learning (span + 2) was not reached in 20 trials. Logical memory was impaired: he could recall only 6.3 out of the 16 events of a story (Spinnler and Tognoni, 1987). Recall of remote and recent events of his life was good.

*Visuo-perceptive assessment.* G.P. performed well in matching to sample a complex geometrical figure (39/43) when given three alternatives and a meaningless figure (3/3) when given 8 alternatives. He could detect 15 out of 73 overlapping drawings in 4 minutes (Rey, 1966). His performance in naming black and white photographs of objects did not differ from naming outline drawings of the same photographs (8/14 correct for both).

*Drawings.* Spontaneous drawings of 20 items were artistically sketched, but sometimes they lacked important details. For example, a giraffe was drawn without the characteristic long neck and a bicycle without pedal and saddle. He copied well 8 complex geometrical figures and 8 objects, sometimes using a line-by-line strategy.

*Scenes.* Sixty coloured photographs or pictures of scenes were presented one at a time and the patient was asked to describe and interpret them. He scored 25/60 correct. Errors can be categorized as follows.

- Inability to interpret the scene (in 23 items). For example a picture of the Virgin and her Son was described as a woman with a baby and a picture representing typically dressed and armed arabs was described as "some men".
- Addition of pertinent but not present details (in 7 items). For example, in describing a dinner table he mentioned foods that were not depicted. This type of response represents a sort of confabulation.
- Description of a limited portion of the picture (in 2 items). For example in a photograph representing people bathing in a river, he only described buildings on one side of the river, without recognizing the river. These omissions did not consistently affect one side of the pictures.
- Visual errors (in 2 items), such as tyres → rolls of paper, or bricks.
- No response (in 1 item).

*Colours.* G.P. made no errors in a same-different judgement between two colours, even if they were different shades of the same colour.

Colour naming and pointing to the colour named by the examiner was tested by placing 15 coloured chips on the table in front of the patient. He was correct in naming 9 out of 15 colours and in pointing to 5 out of 8.

Colour-picture association was tested by asking the patient to colour and name 19 black and white drawings, chosen so as to have a typical colour. Of the 13 pictures that were re-

cognized 6 were correctly coloured and 7 were not. In telling the colour of the same items, when their name was provided, he scored 14/19.

*Faces.* 24 photographs of faces of famous people were presented for naming or identification. G.P. always recognized that the stimulus was a face. He correctly named 9 faces. Other 6 photographs were precisely identified but not named. In 9 cases he declared of not having seen the face before.

### Special Studies

The tests reported in this section aimed at evaluating whether the naming disturbance was modality specific and at differentiating visual agnosia from optic aphasia. Three categories of tests were given:

- (A) tests of naming,
- (B) tests of recognition not requiring a verbal response,
- (C) verbal-visual matching tests.

#### (A) NAMING

Visual naming, tactile naming and naming from definition were investigated in order to assess if the disorder was modality-specific.

#### Visual Naming

The patient was presented with 84 real objects and 280 prototypical pictures and requested to name them (Table I). The latter category included 18 coloured and 33 black and white photographs and 219 coloured and 10 line drawings.

TABLE I  
*Visual Naming*

	Objects (N = 84)	Pictures (N = 280)
Correct	67 (80%)	164 (59%)
Immediate	48 (57%)	125 (45%)
Delayed	19 (23%)	39 (14%)
Errors	7 (7%)	72 (26%)
Semantic	4 (4%)	43 (16%)
Superordinate	2 (2%)	21 (8%)
Coordinate	2 (2%)	22 (8%)
Circumlocutions	1 (1%)	14 (5%)
Visual	1 (1%)	14 (5%)
Unrelated	1 (1%)	1 (0%)
No response	10 (12%)	44 (15%)

Correct responses were classified as immediate or delayed according to whether they were given within 5 seconds or between 5 and 30 seconds.

Errors were classified as:

*Semantic errors*, if there was a semantic relationship with the stimulus. These errors were further divided into superordinate errors, if the response was the name of the category (e.g. mouse → animal, glass → vessel) and coordinate errors, if another member of the category was given. The latter responses usually had a visual similarity with the stimulus (e.g. hammer

→ pick), although sometimes they did not (e.g. thimble → button).

*Circumlocutions*, if the item was identified with a sentence (e.g. coffee-pot → the thing we use to make coffee).

*Visual errors*, if there was a visual but not a semantic similarity with the stimulus (e.g. a teddy bear → a baby, a feather → a leaf, a magnifying lens → a tennis racket). They were often preceded by a prolonged inspection of the stimulus.

*Unrelated errors*, if there was neither a semantic nor a visual relationship with the stimulus. In one of the two unrelated errors (tree → horse) G.P. realized that the picture did not represent a horse only when asked to point to its head, legs and tail. In the other (paddock → cork) he rejected his own response, but could not say the function or mime the use of the object, although he said that it was familiar to him.

*No response*, if the patient did not give any response within 30 seconds. In this case, questions related to the familiarity, the physical attributes (material, size, weight), the use (who and how), the function and the semantic category of the stimulus were asked, in order to ascertain whether the patient had some knowledge of it. In the majority of cases, G.P. showed to have no information about the item. However, partial information could be demonstrated in some cases, for example, a sense of familiarity, or knowledge of physical attributes (especially for real objects). In few cases he showed to have gained access to the category or to have identified the object. On the whole, in 10/10 of "no responses" for objects and in 35/44 of "no responses" for pictures no semantic information about the item presented was provided.

Occasionally, the correct name was produced during the inquiry, as if the proposed questions facilitated recognition and naming of the item, e.g., a nest → ... (Examiner: have you never seen it?) ... I have a confused idea ... (E.: is it small or large?) ... small ... (E.: heavy or light?) ... light ... (E.: what does it make you think about?) ... I don't know ... (E.: where can it be found?) ... perhaps outside ... (E.: is it related to animals?) ... maybe ... eggs? ... (E.: not exactly) ... eggs in a basket? ... (E.: not exactly, it's a basket made by birds) a nest! Now I see it clearly! In some cases G.P. seemed to rely mainly on the global shape of the stimulus, but to be unable to pick up the details necessary to identify it. For example, for a ruler, he said: "it's a long object ... it can be many things", for an egg: "... it can be everything with an ovoid shape".

It can be noted that his performance was better for objects than for pictures (80% versus 59% correct) and that errors varied from those indicating complete failure to recognize the item (visual and unrelated errors and "no responses" with no access to the semantic field), to those indicating access to the semantic field of the item (semantic errors and "no responses" when the access to the semantic field could be demonstrated) to those indicating correct identification of the item (circumlocutions and "no responses" of anomic type).

### *Tactile Naming*

The patient was requested to name, with his eyes closed, an object placed in his left hand (the right one was not tested because of sensorimotor loss). He correctly named 27/30 objects.

### *Naming from Definition*

The patient had to provide the name of an object in response to its verbal definition, which was based mainly on its function. He gave 51 correct responses for 52 definitions.

### *Comparison between Visual Naming, Tactile Naming and Naming from Definition*

Seventeen objects were presented in the three modalities. G.P. named 17 objects from definition (100%), 15 from tactile presentation (88%) and 11 from visual presentation (65%). The defect appeared to be more marked for the visual modality.

*(B) TESTS OF RECOGNITION NOT REQUIRING VERBAL RESPONSES*

These tests aimed to assess whether the patient's inability to recognize objects and pictures from vision could also be demonstrated when verbal responses were not required, thus allowing a distinction between visual associative agnosia and optic aphasia.

*Categorization of Pictures*

Forty six pictures of objects from 5 categories (17 animals, 4 flowers, 5 fruits, 8 vehicles, 12 articles of clothing) were displayed on the table in front of the patient, who was requested to group together members of the same type. He was not informed of the number of categories and had no time limit.

The patient formed 13 groups shown by Table II.

TABLE II  
*Categorization of Pictures*

Category	Comment
Tiger, elephant	Wild animals
6 birds, cat, sheep, frog	Flying animals
Horse, zebra, donkey, dog	Domestic animals
2 fishes	
4 flowers	
Watermelon, melon	
Strawberry, cherry, pear	
Boat	
4 cars	
2 airplanes	
Train	
9 articles of clothing	
3 shoes	Cars ... no ... shoes

*Categorization of Graphic Symbols*

Thirty five cards were placed in front of the patient displaying the following 7 categories of graphic symbols: 5 Italian letters, 5 Greek letters, 5 Arabic numerals, 5 Roman numerals, 5 mathematical signs, 5 musical signs and 5 punctuation signs. He was asked to group the members of the same type without information of the number of categories and with no time limit. As shown by Table III only musical signs were correctly categorized.

TABLE III  
*Categorization of Graphic Symbols*

Category	Comment
5 Italian letters, 1 Arabic numeral, 1 Greek letter, 1 Roman numeral	Letters
5 musical signs	Musical notes
2 Roman numerals	Roman numerals
4 Arabic numerals	Numbers
All other signs	I don't know how to classify these cards

*Matching Objects for Function*

Thirty two objects were put in front of the patient. They were so chosen as to form 16 pairs of objects having the same function and name though visually dissimilar (e.g. two types of razors, of keys, etc.). The patient had to sort the two objects having the same function.

G.P. formed 11 correct pairs in 10 minutes. The remaining 10 objects were left on the table.

*Matching Pictures for Function*

The patient was asked to match the picture of an object with that of an object having the same function and name but visually dissimilar, in a three pictures choice. In most trials the alternatives were semantically unrelated.

G.P. gave 23 correct responses on 25 trials. The better performance on this than on the previous task may depend on differences in the number of choices and the nature of stimuli. In the three-choice task, it was sufficient to recognize two items to make a correct selection (note that a proportion of recognition of 2/3 is predicted by his naming performance), whereas in the object task there was a much wider number of alternatives. Furthermore, preliminary data on semantic categories suggest that G.P. generally recognizes at the superordinate semantic level items belonging to the categories of animals, vehicles, clothing (included in the picture task), while he fails to recognize utensils and small common objects (included in the object task). This differential access to superordinate semantic knowledge might contribute to explain the different performance in the picture and the object task.

*Probed Visual Knowledge*

The patient was presented with 4-5 pictures and requested to point to those having the property described by the examiner: e.g. which one flies? among an airplane, a ship, a horse and a fly. G.P. indicated the correct items in 5 out of 12 trials. He included a ship among flying objects, did not recognize a thimble and a stove as made of metal, and judged a duck smaller than a snail and a frog.

*(C) VERBAL-VISUAL MATCHING TESTS**Verbal-visual Matching for Objects*

Ten objects were placed on a table before the patient who had to point to the one named by the examiner. Responses were all correct (10/10).

*Verbal-visual Matching for Pictures*

The patient had to point to the picture named by the examiner on an array of 20 semantically and perceptually distinct pictures (Basso et al., 1979). He was correct in 19/20 pictures. The role of semantic and perceptual similarity was investigated by means of a three-choice matching test including semantic, perceptual and semantic-perceptual distractors (Chieffi, Carlomagno, Silveri et al., 1989). Both semantic and perceptual similarity among items misled patient's response (2/18 errors in the semantic condition, 4/18 in the perceptual condition, 4/18 in the semantic-perceptual condition, 3/18 in the semantic control subset, 1/18 in the perceptual control subset). The number of errors was more than three standard deviations higher than the mean error score for normal subjects in all conditions except in the perceptual control subset where it only exceeded one standard deviation. The results indicate that the patient had difficulty in precisely identifying an item within its semantic and perceptual field.

## DISCUSSION

*Comments on Data*

G.P. presents a naming defect that is specific for the visual modality, because it is absent in tactile naming, in naming from definition and in spontaneous language. The naming defect is due in most cases to a defect of recognition, because the patient also fails in tests of recognition that do not require a verbal response. The defect of recognition cannot be attributed to visuo-perceptual difficulties because G.P. can match to sample complex geometrical figures and meaningless figures and can describe and copy objects that he does not recognize. This pattern of symptoms is congruent with the syndrome of visual associative agnosia. The defect of recognition varies from a complete failure to recognize the item to access to incomplete semantic information. Visual errors and the predominance of "no responses", as well as his performance on tests of matching objects for function and probed visual knowledge, reveal that the patient has not extracted adequate semantic information from the perceived stimulus. He often remains perplexed in front of the object, describes it and, after a prolonged inspection from different points of view, explicitly admits not to know it. This behaviour fits well the classical description of agnosic patients. Teuber (1968) defined visual agnosia "a normal percept that has somehow been stripped of its meaning", and Head (1926), describing object naming in a visual agnosic patient, reports: "not only he is unable to name or demonstrate its use, but he does not remember ever to have seen it before" (quoted by Rubens and Benson, 1971).

In other conditions his defect of recognition is less severe, allowing access to incomplete semantic information. In fact semantic errors seem to be the result of the transfer of general semantic information to the verbal output. For instance, G.P. sometimes explicitly stops at the level of the general category, producing a superordinate error (orange → a fruit ... (Examiner: which fruit?) ... I don't know). When he proceeds into the category he may produce a correct delayed response (pear → a fruit ... a pear), or a visually-similar semantic error (hammer → pick, cup → glass, lion → dog), or a visually-dissimilar semantic error (thimble → button, suspenders → belt, ruler → rubber). Sometimes G.P. cannot decide between two members of the same semantic category of the stimulus (e.g. paint-brush → a chisel ... or a screw-driver, walnut → a hazelnut ... or an almond, zebra → a horse ... or a donkey). Limitation of access to only general semantic information is also shown by G.P.'s performance in other tasks, such as picture categorization and verbal-visual matching tasks. For instance, G.P. includes in the category of flying animals a cat, a sheep, and a frog, indicating correct access to the superordinate category of animals, but insufficient recognition within the category. In a verbal-visual matching test he fails when pictures are semantically related, whereas he performs well when pictures are semantically distinct, indicating difficulty only when the choice is among members of the same category.

Finally, there are some minor aspects of G.P.'s performance that are not characteristic of visual associative agnosia and recall the syndrome of optic



aphasia. For instance, in the case of "circumlocutions", there is evidence that the patient has recognized the stimulus. A word finding problem can also be entertained for those correct delayed responses in which G.P. shows signs of having recognized the item immediately (e.g. child → man ... no ... boy ... no ... child, glass → lamp ... no ... vessel ... no ... glass) and for those "no responses" in which the subsequent inquiry demonstrates recognition of the stimulus (for example, he can mime the use of a pick and describe the use of a tent). Incorrect naming of recognized stimuli is also present in other tasks, such as matching pictures for function (when G.P., while correctly associating two pictures of a bed, names one of them a car) or description of scenes (when G.P. confabulates on the basis of the correctly named items).

In conclusion, this patient presents a clinical picture of visual associative agnosia, ranging from a complete failure of recognition to incomplete semantic specification, associated with some elements of optic aphasia.

### *Visual Associative Agnosia vs. Optic Aphasia*

Prompted by the presence in our patient of signs of both visual associative agnosia and optic aphasia we reviewed the recent literature, to verify how frequently has this association been reported in other cases. We collected 22 case reports of visual associative agnosia and 12 case reports of optic aphasia, from vascular or neoplastic etiology, where the site of lesion was documented by autopsy, neurosurgical report, MRI or CT scan data or was suggested by the clinical picture and the presence of visual field defect<sup>1</sup>. Responses were categorized as pointing to complete failure to recognize the item (visual errors, inability to demonstrate the use, other documented instances of failure of recognition), incomplete semantic specification (semantic errors, confusion between items of the same semantic field in categorization and matching tasks, answering general but not specific semantic questions about visual stimuli) and visual anomia (circumlocutions, correct demonstration of use, other documented instances of anomia)<sup>2</sup>. Thirteen cases of visual associative agnosia were due to bilateral lesions in the infero-temporo-occipital region (Table IV), and 9 to left unilateral lesions (Table V). All of the 12 cases of optic aphasia had left unilateral lesions in the infero-temporo-occipital region (Table VI). Also listed are the type of naming errors reported. When an error analysis was not reported, we categorized the examples cited, according to the present classification.

In bilateral cases the clinical picture resembles that of classical visual associative agnosia. There is scarce evidence of anomia and of incomplete semantic specification, which were found in 2 and 3 cases, respectively, out of 13. In two other cases evidence of access to semantic knowledge appears only at a later examination carried out 3 months (Mack and Boller, 1977) and 7 years after the onset (Gomori and Hawryluk, 1984). In the case of Ratcliff and Newcombe

---

<sup>1</sup> It must be pointed out that conventional neurological examination and early neuroradiology do not allow to determine with sufficient accuracy the anatomical damage. Therefore, the conclusions drawn from the present review need to be confirmed by studies using recent neuroradiological techniques.

<sup>2</sup> The term anomia is here, indifferently, used for indicating failure to produce a name or the production of incorrect names, in the presence of normal recognition of the item.

TABLE IV  
*Visual Associative Agnosia. Bilateral Infero-Temporal-Occipital Lesions †*

First author	Etiology	Visual field defect	Failure of recognition	Incompl. semantic specification	Visual anomalous defect	Type of naming errors reported
Rubens (1971)	Infarction (A)	Right hemianopia	+	-	-	Visual, no response
Benson (1974)	L.-R. p.c.a.					
Albert (1975)	Infarction (A)	Right upper quadrantopia	+	+	-	Semantic, delayed responses, failures of naming
Albert (1979)	L.-R. p.c.a.					
Mach (1977)	Infarction (CT)	Right hemianopia	+	*	-	Semantic, visual, delayed responses, no response
	L.-R. p.c.a.	left upper quadrantopia				
Wapner (1978)	Infarction	Right upper quadrantopia	+	-	-	Delayed responses, failures of identification
(Left handed)	L.-R. p.c.a.	Incomplete right lower, left upper quadrantopia				
Levine (1978)††	Resection for recidivant meningioma (NS-CT)	Left hemianopia	+	-	-	Visual, unrelated, perseverations, delayed responses, no response
(Left handed)		Incomplete right upper quadrantopia				
Cambier (1980)	Infarction (A)	Left hemianopia	+	-	-	Visual, delayed responses
	L.-R. p.c.a.					
Dumont (1981)	Infarction (CT)	Right hemianopia	+	-	-	—
	L. p.c.a.					
	R. m.c.a.					
Ratcliff (1982)	Infarction (CT)	Left hemianopia	+	*	-	Visual
	Encephalitis?					
Alexander (1983)	Multiple intracerebral hematomas (CT)	Incomplete bilateral upper quadrantopia	+	-	+	Visual
Gomori (1984)	Infarction (CT)	Right hemianopia	+	*	-	—
	L.-R. p.c.a.	Incomplete left upper quadrantopia				
Riddoch (1987)	Infarction (CT)	Bilateral upper quadrantopia	+	+	-	Visual, delayed responses, no response
	L.-R. p.c.a.					
Kawahata (1989)	Multiple intracerebral hematomas (CT-MRI)	Incomplete bilateral upper quadrantopia	+	-	-	Visual, no response
Grailet (1990)	Infarction (CT)	Bilateral upper quadrantopia	+	+	+	Visual, circumlocutions
	L. p.c.a.					
	L.-R. m.c.a.					

† In the case of Dumont (1981) and Grailet (1990) the right lesion is in the parieto-temporo-occipital area.

†† In Levine's case the visual field defect indicates bilateral lesions, while CT and NS indicate a right sided lesion.

Legend: + = present, - = not reported, \* = see text for details.

A = Autopsy, CT = CT scan, MRI = MRI scan, NS = Neurosurgery.

L. (R.) p. (m.) c.a. = Left (Right) posterior (middle) cerebral artery.

(1982) there is evidence of superordinate semantic knowledge only for the category of animals. Also the type of naming response suggests that the disturbance is mainly agnosic in nature. In the majority of cases, patients fail to recognize objects. They observe them for a long time, describe their parts, often say "I don't know", "I'm not sure", or make hypotheses as to what the object could be. Responses are often the result of inferential reasoning, based on the visual features of the stimulus. Consequently, most errors are visual. Semantic

TABLE V  
*Visual Associative Agnosia. Unilateral Infero-Temporo-Occipital Lesions †*

First author	Etiology	Visual field defect	Failure of recognition	Incompl. semantic specification	Visual anomic defect	Type of naming errors reported
Ettlinger (1961)	Vascular	Right hemianopia	+	+	+	Semantic, perseverations, delayed responses, failures of identification, no response
Lhermitte (1973)	Infarction L. p.c.a.	Right hemianopia	+	+	-	Semantic, visual, unrelated, perseverations, confabulations, no response
Hécaen (1974)††	Resection for glioblastoma (NS)	Right hemianopia	+	+	+	Semantic, visual, unrelated, perseverations, no response
Pillon (1981)	Infarction (CT) L. p.c.a.	Right hemianopia	+	+	+	Semantic, unrelated, perseverations, confabulations
Ferro (1984)	Infarction (CT) L. p.c.a.	Right hemianopia	+	+	+	Semantic, visual, unrelated, perseverations, circumlocutions, no response
Morin (1984)	Intracerebral hematoma (CT)	Right hemianopia	+	+	-	Semantic, unrelated, perseverations, confabulations
Larrabee (1985) (Case 1)	Infarction (CT) L. p.c.a.	Right hemianopia	+	-	-	-
McCarthy (1986)	Infarction (CT) L. p.c.a.	Right hemianopia	+	+	-	Semantic, failures of recognition
Benke (1988)	Intracerebral hematoma (NS-CT)	Right hemianopia	+	-	+	Misidentifications, perseverations, circumlocutions, confabulations, no response

† All left sided lesions.

†† For Hécaen's case judgements were based on patient's comment.

Legend: + = present, - = not reported.

A = Autopsy, CT = CT scan, MRI = MRI scan, NS = Neurosurgery.

L. p.c.a. = Left posterior cerebral artery.

errors are rare. If present, semantic knowledge tends to be limited to the supordinate level. This behaviour is well exemplified by the cases of Rubens and Benson (1971), Wapner, Judd and Gardner (1978), Cambier, Masson, Elghozi et al. (1980), Riddoch and Humphreys (1987a), Kawahata and Nagata (1989), and Grailet, Seron, Bruyer et al. (1990).

On the other hand, in the 21 unilateral cases taken together, there is a considerable overlap between the two syndromes. In 5 out of the 9 cases that have

TABLE VI  
*Optic Aphasia. Unilateral Infero-Temporo-Occipital Lesions †*

First author	Etiology	Visual field defect	Failure of recognition	Incompl. semantic specification	Visual anomic defect	Type of naming errors reported
Lhermitte (1973)	Infarction L. p.c.a.	Right hemianopia	+	+	+	Semantic, visual, unrelated, perseverations, delayed responses
Michel (1979)	Infarction (A) L. p.c.a.	Right hemianopia	-	+	+	Semantic, perseverations, confabulations, no response
Assal (1980)	Infarction (CT) L. p.c.a. L. m.c.a.	Right hemianopia	+	+	+	Semantic, unrelated
McCormick (1983)	Glioblastoma (CT-NS)	Right hemianopia	-	-	+	Circumlocutions, delayed responses
Poeck (1984)	Infarction L. p.c.a.	Right hemianopia	+	+	+	Semantic, perseverations, confabulations, no response
Gil (1985)	Infarction (CT) L. p.c.a.	Right hemianopia	+	+	+	Semantic, visual, unrelated, perseverations, confabulations, no response
Larrabee (1985) (Case 2)	Resection for intraventr. meningioma (CT-NS)	Right hemianopia	+	+	+	Semantic, perseverations
Lindeboom (1985)	Infarction (CT) L. p.c.a.	Right hemianopia	+	+	+	Semantic, perseverations, delayed responses, no response
Pena-Casanova (1985)	Infarction (CT) L. p.c.a.	Right hemianopia	+	+	+	Semantic, unrelated, circumlocutions, delayed responses, no response
Rapcsak (1987)	Intracerebral hematoma (CT)	Normal	-	-	+	No response
Riddoch (1987)	Extradural hematoma (CT)	Right hemianopia	+	+	+	Semantic, visual
Coslett (1989)	Infarction L. p.c.a.	Right hemianopia	+	+	+	Semantic, visual, unrelated, perseverations, no response

† All left sided lesions.

Other accepted headings are: visual or optic anomia, visual-verbal or visual-speech disconnection, left hemisphere deaf-ferentation.

Legend: + = present, - = not reported.

A = Autopsy, CT = CT scan, MRI = MRI scan, NS = Neurosurgery.

L. p. (m.) c.a. = Left posterior (middle) cerebral artery.

been labelled as visual associative agnosia there is evidence of a visual anomic disturbance, and in 9 out of 12 cases labelled as optic aphasia there is evidence of complete failure to recognize the item. Moreover, in 17 out of 21 unilateral cases there is evidence of incomplete semantic specification, and the pattern of naming errors is similar in most unilateral cases, including semantic, visual, perseverative, unrelated and confabulatory errors, as well as "no responses".

This finding is in agreement with the association of visual agnosia and visual-verbal disconnection reported by some authors (Lhermitte, Chedru and Chain, 1973; Albert, Reches and Silverberg, 1975; Pillon, Signoret and Lhermitte, 1981; Ferro and Santos, 1984; Morin, Rivrain, Eustache et al., 1984). However, in cases of visual associative agnosia the problem of recognition is prevalent, whereas in cases of optic aphasia a pure defect of naming predominates and the disturbance of recognition, if present, is mild. It must be also pointed out that there is not evidence of an association of the disorders in 4 agnosic and 2 optic aphasic cases, in which only a disturbance of recognition or of naming is reported. Taken together, left unilateral cases appear to have some common features distinguishing them from bilateral cases. In most cases, patients make a remarkable proportion of semantic errors, and show evidence of partial semantic recognition, indicating substantial, although incomplete, access to semantic knowledge. They also appear to gain semantic information without recourse to logical strategies. Furthermore, verbal responses have often lost any connection with the visual features of the stimulus (visually-dissimilar semantic errors, perseverative and unrelated errors, confabulations).

In conclusion, the review of the literature points out that visual associative agnosia and optic aphasia are associated in left unilateral lesions, while bilateral lesions appear to cause a rather classical form of visual associative agnosia, of greater severity than the unilateral one. In unilateral lesions, the syndromes of visual associative agnosia and optic aphasia overlap as regards failure of recognition, visual anomia, access to partial semantic knowledge and type of naming errors, although some cases are more shifted towards visual agnosia and others towards optic aphasia. These findings contribute to reconcile current explanations of visual associative agnosia, suggesting that a left sided lesion is necessary for the clinical expression of the syndrome and is often sufficient to produce it, but the clinical picture is less severe than in bilateral cases and has a different pattern of naming responses. The linkage with optic aphasia in left unilateral cases remains unclear. Optic aphasia can be a milder form of visual associative agnosia, thus implying that a unique process, involved in the association of a visual stimulus with the corresponding internal representations, would produce a defect of recognition or a pure defect of naming, depending on the severity of its disruption. This argument is supported by the presence, in our case and in most of the unilateral cases under review, of disturbances of identification of different severity, from complete failure of recognition, to incomplete semantic specification, to visual anomia, and by the existence of patients with visual associative agnosia who evolve towards a syndrome resembling optic aphasia when visual recognition improves (Rubens, 1979; De Renzi et al., 1987; Benke, 1988). Alternatively, the association of the two syndromes might depend on the contiguity of the cerebral areas responsible for them, which all belong to the territory of the left posterior cerebral artery.

Finally, the difference between unilateral and bilateral cases suggests that a healthy right hemisphere contributes to the extraction of semantic information from visual stimuli and to the presence of perseverations, confabulations and unrelated and semantic errors, in patients with visual associative agnosia and optic aphasia. Available data do not allow us to determine if the right hemi-

sphere simply transmits perceptually categorized information to the left hemisphere, where they are semantically processed (De Renzi et al., 1969; Warrington, 1982), or if it itself achieves an incomplete semantic analysis.

#### ABSTRACT

The case is presented of a patient who showed visual naming disturbances caused by a left occipital infarction. His performance on tests of visual naming, of recognition not requiring a verbal response, and of verbal-visual matching demonstrated a wide range of qualitatively different errors, including complete inability to recognize the object, access to partial semantic knowledge, and mere name finding difficulty. On the basis of the present case and of a review of the recent literature, the clinical distinction between visual associative agnosia and optic aphasia and the relation of these disorders with the anatomical site of lesion are discussed.

*Acknowledgements.* We wish to thank Prof. E. De Renzi, Prof. E. Warrington and Dr. L. Troiano for their helpful comments, Dr. S. Chieffi for providing the material of the verbal-visual matching test and the patient G.P. for his cooperation.

#### REFERENCES

- ALBERT, M.L., RECHES, A., and SILVERBERG, R. Associative visual agnosia without alexia. *Neurology*, 25: 322-326, 1975.
- ALBERT, M.L., SOFFER, D., SILVERBERG, R., and RECHES, A. The anatomic basis of visual agnosia. *Neurology*, 29: 876-879, 1979.
- ALEXANDER, M.P., and ALBERT, M.L. The anatomical basis of visual agnosia. In A. Kertesz (Ed.), *Localization in Neuropsychology*. New York: Academic Press, 1983, pp. 393-415.
- ASSAL, G., and REGLI, F. Syndrome de disconnexion visuo-verbale et visuo-gestuelle. Aphasie optique et apraxie optique. *Revue Neurologique*, 136: 365-376, 1980.
- BASSO, A., CAPITANI, E., and VIGNOLO, L.A. Influence of rehabilitation on language skills in aphasic patients. A controlled study. *Archives of Neurology*, 36: 190-196, 1979.
- BEAUVOIS, M.F. Optic aphasia: a process of interaction between vision and language. *Philosophical Transactions of the Royal Society of London*, 298: 35-47, 1982.
- BENKE, T. Visual agnosia and amnesia from a left unilateral lesion. *European Neurology*, 28: 236-239, 1988.
- BENSON, D.F., SEGARRA, J., and ALBERT, M.L. Visual agnosia-prosopagnosia. *Archives of Neurology*, 30: 307-310, 1974.
- CAMBIER, J., MASSON, M., ELGHOZI, D., HENIN, D., and VIADER, F. Agnosie visuelle sans hémianopie droite chez un sujet droitier. *Revue Neurologique*, 136: 727-740, 1980.
- CHIEFFI, S., CARLOMAGNO, S., SILVERI, M.C., and GAINOTTI, G. The influence of semantic and perceptual factors on lexical comprehension in aphasic and right-damaged patients. *Cortex*, 25: 591-598, 1989.
- COSLETT, H.B., and SAFFRAN, E.M. Preserved object recognition and reading comprehension in optic aphasia. *Brain*, 112: 1091-1110, 1989.
- DE RENZI, E., SCOTTI, G., and SPINNLER, H. Perceptual and associative disorders of visual recognition: relation to the side of cerebral lesion. *Neurology*, 19: 634-642, 1969.
- DE RENZI, E., ZAMBOLIN, A., and CRISI, G. The pattern of neuropsychological impairment associated with left posterior cerebral artery infarcts. *Brain*, 110: 1099-1116, 1987.
- DUMONT, I., GRIGGIO, A., DUPONT, H., JACQUY, J. A propos d'un cas d'agnosie visuelle avec prosopagnosie et agnosie des couleurs. *Acta Psychiatrica Belgica*, 81: 25-45, 1981.
- ETTLINGER, G., and WYKE, M. Defects in identifying objects visually in a patient with cerebrovascular disease. *Journal of Neurology, Neurosurgery and Psychiatry*, 24: 254-259, 1961.
- FERRO, J.M., and SANTOS, M.E. Associative visual agnosia: a case study. *Cortex*, 20: 121-134, 1984.
- FREUND, D.C. Über Optische Aphasie und Seelenblindheit. *Archiv für Psychiatrie und Nervenkrankheiten*, 20: 276-297, 1989.
- GESCHWIND, N. Disconnection syndromes in animals and man. *Brain*, 88: 585-644, 1965.
- GIL, R., PLUCHON, C., TOULLAT, G., MICHENAU, D., ROGEW, R., and LEFEVRE, J.P. Disconnexion visuo-verbale (aphasie optique) pour les objets, les images, les couleurs et les visages avec alexie abstractive. *Neuropsychologia*, 23: 333-349, 1985.

- GOMORI, A.J., and HAWRYLUK, G.A. Visual agnosia without alexia. *Neurology*, 34: 947-950, 1984.
- GRAILET, J.M., SERON, X., BRUYER, R., COYETTE, F., and FREDERIX, M. Case report of a visual integrative agnosia. *Cognitive Neuropsychology*, 7: 275-309, 1990.
- HEAD, H. *Aphasia and Kindred Disorders of Speech*. London: Cambridge University Press, 1926.
- HÉCAEN, G., GOLDBLUM, M.C., MASURE, M.C., and RAMIER, A.M. Une nouvelle observation d'agnosie d'objet. Déficit de l'association ou de la categorization, spécifique de la modalité visuelle? *Neuropsychologia*, 12: 447-464, 1974.
- KAWAHATA, N., and NAGATA, K. A case of associative visual agnosia: neuropsychological findings and theoretical considerations. *Journal of Clinical and Experimental Neuropsychology*, 11: 645-664, 1989.
- LARRABEE, G.J., LEVIN, H.S., HUFF, F.J., KAY, M.C., and GUINTO, F.C. Visual agnosia contrasted with visual-verbal disconnection. *Neuropsychologia*, 23: 1-12, 1985.
- LEVINE, D.N. Prosopagnosia and visual object agnosia: a behavioral study. *Brain and Language*, 5: 341-365, 1978.
- LHERMITTE, F., and BEAUVOIS, M.F. A visual-speech disconnection syndrome. Report of a case with optic aphasia, agnosic alexia and colour agnosia. *Brain*, 96: 695-714, 1973.
- LHERMITTE, F., CHEDRU, F., and CHAIN, F. A propos d'un cas d'agnosie visuelle. *Revue Neurologique*, 128: 301-322, 1973.
- LINDEBOOM, J., and SAVINKELS, J.A. Interhemispheric communication in a case of total visuo-verbal disconnection. *Neuropsychologia*, 24: 781-792, 1986.
- LISSAUER, H. Ein fall von Seelenblindheit nebst einem Beitrage zur Theorie Derselben. *Archiv für Psychiatrie und Nervenkrankheiten*, 21: 222-270, 1890.
- MACK, J.L., and BOLLER, F. Associative visual agnosia and its related deficits: the role of the minor hemisphere in assigning meaning to visual perceptions. *Neuropsychologia*, 15: 345-349, 1977.
- MC CARTHY, R.A., and WARRINGTON, E.K. Visual associative agnosia: a clinicoanatomical study of a single case. *Journal of Neurology, Neurosurgery and Psychiatry*, 49: 1233-1240, 1986.
- MCCORMICK, G.F., and LEVINE, D.A. Visual anomia: a unidirectional disconnection. *Neurology*, 33: 664-666, 1983.
- MICHEL, F., SCHOTT, B., BOUCHER, M., and KOPP, N. Alexie sans agraphie chez un malade ayant un hémisphère gauche deafferente (Hémianopie, hémianesthésie, hémianacousie). *Revue Neurologique*, 135: 347-364, 1979.
- MORIN, P., RIVRAIN, Y., EUSTACHE, F., LAMBERT, J., COURTHEUX, P. Agnosie visuelle et agnosie tactile. *Revue Neurologique*, 140: 271-277, 1984.
- ORSINI, A., GROSSI, D., CAPITANI, E., LAIACONA, L., PAPAGNO, C., and VALLAR, G. Verbal and spatial immediate memory span: Normative data from 1355 adults and 1112 children. *Italian Journal of Neurological Sciences*, 8: 539-548, 1987.
- PEÑA-CASANOVA, J., ROIG-ROVIRA, T., BERMUDEZ, A., and TOLOSA-SARRO, E. Optic aphasia, optic apraxia and loss of dreaming. *Brain and Language*, 26: 63-71, 1985.
- PILLON, B., SIGNORET, J.L., and LHERMITTE, F. Agnosie visuelle associative. Role de l'hémisphère gauche dans la perception visuelle. *Revue Neurologique*, 137: 831-842, 1981.
- POECK, K. Neuropsychological demonstration of splenial interhemispheric disconnection in a case of optic anomia. *Neuropsychologia*, 22: 707-713, 1984.
- RATCLIFF, G., and NEWCOMBE, F. Object recognition: some deductions from the clinical evidence. In A.W. Ellis (Ed.), *Normality and Pathology in Cognitive Function*. New York: Academic Press, 1982, pp. 147-171.
- RAPCSAK, S.Z., ROTH, L.J.G., and HEILMAN, K.M. Phonological alexia with optic and tactile anomia: a neuropsychological and anatomical study. *Brain and Language*, 31: 109-121, 1987.
- RAVEN, J.C. *Matrici Progressive Colore* (It. Ed.). Firenze: Organizzazioni Speciali, 1984.
- REY, A. *Les Troubles de la Memoire et leur Examen Psychometrique*. Bruxelles: Charles Dessart Editeur, 1966.
- RIDDOCH, M.J., and HUMPHREYS, G.W. Visual object processing in optic aphasia: a case of semantic access agnosia. *Cognitive Neuropsychology*, 4: 131-185, 1987a.
- RIDDOCH, M.J., and HUMPHREYS, G.W. A case of integrative visual agnosia. *Brain*, 110: 1431-1462, 1987b.
- RUBENS, A.B. Agnosia. In K.M. Heilman and E. Walenstein (Eds.), *Clinical Neuropsychology*. New York and Oxford: Oxford University Press, 1979, pp. 233-267.
- RUBENS, A.B., and BENSON, D.F. Associative visual agnosia. *Archives of Neurology*, 24: 305-316, 1971.
- SPINLER, H., and TOGNONI, G. Standardizzazione e taratura italiana di test neuropsicologici. *Italian Journal of Neurological Sciences. Suppl. Vol. 6*, 1987.
- TEUBER, H.L. Alteration of perception and memory in man. In L. Weiskrantz (Ed.), *Analysis of Behavioural Change*. New York: Harper and Row, 1968.
- WAPNER, W., JUDD, T., and GARDNER, H. Visual agnosia in an artist. *Cortex*, 14: 343-364, 1978.
- WARRINGTON, E.K. Neuropsychological studies of object recognition. *Philosophical Transactions of the Royal Society of London*, 298: 15-33, 1982.