

TACTILE AGNOSIA AND TACTILE APHASIA: SYMPTOMATOLOGICAL AND ANATOMICAL DIFFERENCES

Kunihiko Endo¹, Motomaro Miyasaka², Hideo Makishita², Nobuo Yanagisawa³ and
Morihiro Sugishita⁴

(¹Department of Neuropsychology, Rehabilitation Unit, Keiyo Hospital Rehabilitation Center, Maruko-Machi, Nagano, ²Department of Neurology, Keiyo Hospital Rehabilitation Center, ³Department of Clinical Neurology, Shinshu University, School of Medicine, Matsumoto, and ⁴Department of Clinical Neurology, Tokyo Metropolitan Institute for Neurosciences, Tokyo, Japan)

INTRODUCTION

Disturbances of information processing in the tactile recognition system are classified into four types. Ahylognosia is a disturbance in the ability to discriminate materials. Amorphognosia is a disturbance in the ability to differentiate forms. Tactile agnosia (tactile asymbolia) is the inability to recognize the identity of objects in the absence of ahylognosia and amorphognosia (Delay, 1935). Tactile aphasia is the inability to name tactually identified objects in the absence of aphasic anomia (Geschwind, 1965).

Only about 20 cases of tactile agnosia have been reported: tactile agnosia of the left hand due to a callosal lesion (Hoff, 1931); tactile agnosia of the right hand due to a left hemisphere lesion (Raymond and Egger, 1906; Campora, 1925; Hécaen and David, 1945; Ohashi, 1965, case 77); tactile agnosia limited to the four fingers of the right hand due to a left hemisphere lesion (Bonhoeffer, 1918); bilateral tactile agnosia due to a left hemisphere lesion (Oppenheim, 1906; Goldstein, 1916; Foix, 1922, four cases); tactile agnosia of the left hand due to a right hemisphere lesion (Poggio, 1908; Rose and Egger, 1908; Gerstmann, 1918; P. Marie, Bouttier and van Bogaert, 1924; Ohashi, 1965, case 76); tactile agnosia of the right hand and sensory disturbance of the left hand due to a bilateral lesion (Kutner, 1917); tactile agnosia of the left hand due to a bilateral lesion (Guillain and Bize, 1932); bilateral tactile agnosia due to a bilateral lesion (Lhermitte and Ajuriaguerra, 1938). These studies revealed that tactile agnosia could occur with mild or no disturbance in the discrimination of object material and form, namely in the absence of ahylognosia or amorphognosia. However, these case reports, which appeared before Geschwind's (1965) influential paper, did not distinguish the concept of tactile agnosia from that of tactile aphasia.

On the other hand, tactile aphasia of the left hand has sometimes been observed in commissurotomed patients. This symptom is generally attributed to the disconnection of the right hemisphere (left hand) from the speech dominant left hemisphere. Beauvois, Saillant, Meininger et al. (1978) found that tactile aphasia could occur in both hands, but were cautious in drawing a conclusion about the pathogenesis of the symptom, since there were no other published cases confirming it.

The purpose of this article is to provide evidence for the independent existence of tactile agnosia and tactile aphasia and to contrast the lesional localization and pathogenesis of the two disorders.

CASE 1

Y.K., a 74-year-old man, was left handed, but used his right hand for writing and using chopsticks. His third son was also left handed. He had 11 years of education, and had been working as a licensed tax accountant. He had been on medication because of diabetes mellitus since 1963.

In the autumn of 1984, difficulty in writing and calculating cost him his job. On the morning of March 7, 1985, he complained of "numbness" of his left hand. He tried to dress himself, but could not use his left hand. Soon he lost consciousness. He was admitted to a nearby hospital where a CT scan showed an old infarction in the left angular gyrus. He mumbled something recurrently, but what he said was incoherent. On March 10, he regained consciousness and his speech was audible. On that day, he was observed to use his left hand when scratching his face (he could not use the right hand due to intravenous drip infusion). When his right hand was released, he no longer tried to use his left hand. He often looked for the left hand saying he had lost it somewhere. Before the end of March he could walk, but often collided with objects placed on his left side. He could not return to his room by himself because he could not learn its location. Abnormal use of the right hand was also observed; for example, he tried to put a safety razor in his mouth, and to brush his teeth with a tube of toothpaste. He also had problems in dressing; for instance, he put his trousers over his head. From the beginning of April, his abnormalities gradually diminished. On June 19, he was admitted to Kakeyu Hospital Rehabilitation Center for his difficulty in using the left hand and reading and writing disturbances.

Neurological Examination at the Time of Admission

On confrontation a left homonymous hemianopia and a quadrantopia of the right lower visual field were found. There was a mild spastic hemiparesis on the left side. Deep tendon reflexes were normal, Babinski sign was absent, and the snout reflex was observed. Both light touch and deep sensation were mildly impaired on the left upper extremity, and moderately impaired on the left lower extremity. No deficit was shown on the right limbs.

Neuroradiological Examination

CT scan was undertaken on October 22 (horizontal sections parallel to the orbitomeatal line) and October 30 (coronal sections), 1985. Each section was 10 mm thick. The CT scans were compared with Déjérine's monograph (1895), the horizontal sections of Matsui and Hirano (1977), and the coronal sections of Salamon and Huang (1980).

Horizontal section 8 cm above the OM line (Figure 1, A): A low density area was observed in the left angular gyrus. In the right hemisphere, the lesion involved the posterior central gyrus, the supramarginal gyrus, the first temporal gyrus, and the angular gyrus. The subcortical lesion involved the posterior parts of the arcuate fasciculus, external capsule, and

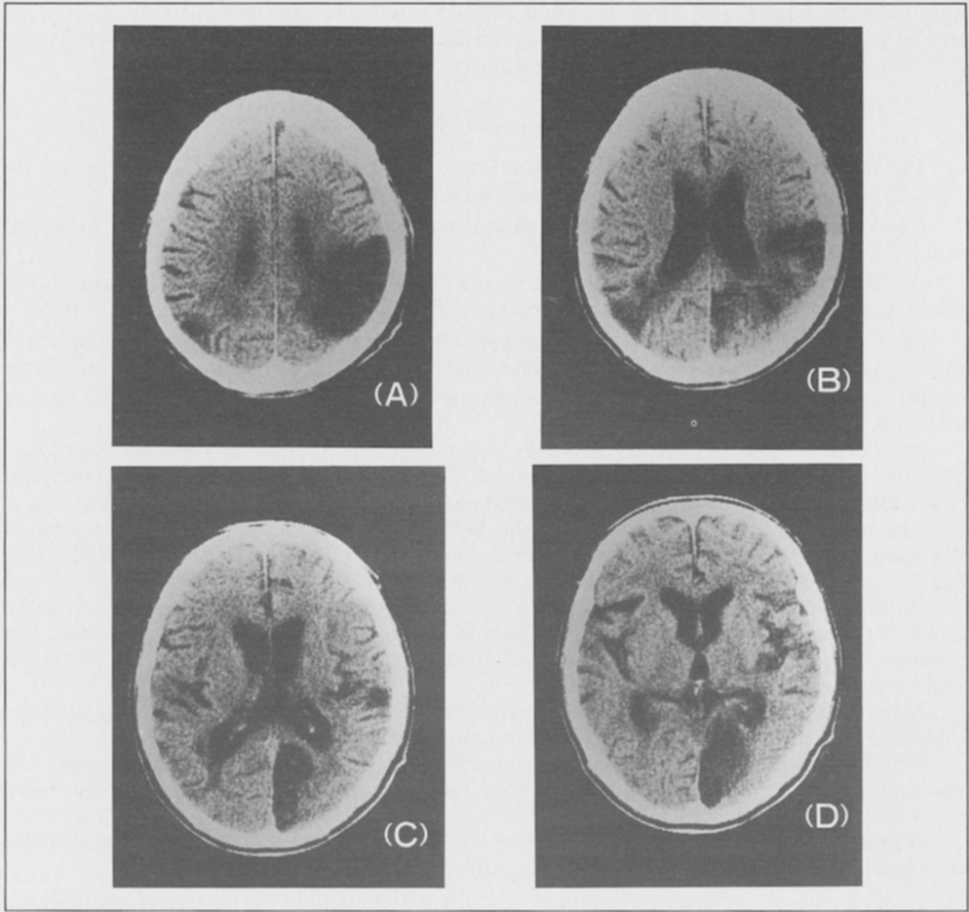


Fig. 1 - CT scans of Case 1. Slices A, B, C, and D represent horizontal sections 8 cm, 7 cm, 6 cm, and 5 cm above the OM line.

coronal radiations. Section 7 cm above the OM line (Figure 1, B): The left angular gyrus was damaged, and the subcortical lesion involved the inferior longitudinal fasciculus, the optic radiations, and the posterior callosal radiations. In the right hemisphere, in addition to the lesion of the parietal lobe and the posterior part of the temporal lobe, a cortico-subcortical lesion of the precuneus was observed. Section 6 cm above the OM line (Figure 1, C): In the left hemisphere, the lesion of the angular gyrus appeared as two small low density areas adjacent to the inferior horn of the lateral ventricle. The lesion involved the inferior longitudinal fasciculus and the posterior callosal radiations. In the right hemisphere, the lesion in the parietal lobe and the temporal lobe appeared as a small low density area of the first temporal gyrus. Extensive portions of the cortico-subcortical regions of the first occipital gyrus and the cuneus were involved. Section 5 cm above the OM line (Figure 1, D): Cortico-subcortical regions of the right first occipital gyrus, the cuneus, the lingual gyrus, and the calcarine cortex were involved.

rCBF was measured by single photon emission CT (Tomomatic 64, xenon 133 inhalation method). Ischemic regions on the rCBF map accorded well with the low density areas of the CT scan.

DSA (digital subtraction angiography) revealed a tight stenosis of the left middle cerebral artery (M_1), and arteriosclerotic changes of the branches of the left middle cerebral artery. Moderate stenosis was observed at the right internal carotid artery (C_1) and the right

middle cerebral artery (M_1 , M_2). The right angular artery and the right anterior cerebral artery were occluded. Tight stenosis was observed at the origin of the right vertebral artery, and the right posterior cerebral artery did not appear.

Neuropsychological Examination

The patient cooperated during the examination with patience. He was aware of his illness, though not having full insight into his situation.

(1) *Arousal level and attention*: The patient was alert, but the distribution of his attention to the left was disturbed.

(2) *Intelligence*: The patient scored 70 on the verbal IQ and 69 on the performance IQ of the WAIS Japanese edition. Left unilateral spatial neglect reduced the performance IQ.

(3) *Episodic memory*: Recent memory was severely impaired while remote memory was slightly impaired. He was disoriented in time and space, but did not produce confabulations.

(4) *Language*: Mild anomia and severe agraphia were observed, but he had no difficulty in daily conversation.

Spontaneous speech: His tone of voice, velocity of articulation, and prosody were normal. Phonetic disintegration was not observed. On very rare occasions, self-corrected phonemic errors were noted. Self-corrected verbal paraphasias were rare. In confrontation naming, the patient scored 18 out of 20 on the SLTA (Japanese Standard Language Test of Aphasia), and 92/100 on a 100 word vocabulary test (subsequently, he scored 95/100). Neither grammatical nor syntactical disturbances were noted.

Auditory comprehension: Both phonetic and semantic comprehension was preserved. An auditory retention span of 3 words showed a mild disturbance. Comprehension of logical and grammatical relations (Luria) was preserved. Token test was not feasible because of his left unilateral spatial neglect.

Repetition: Repetition was mildly disturbed; he could repeat sentences up to 27 syllables on SSDD (Schuell Sasanuma Differential Diagnosis of Aphasia).

Reading: Reading aloud and reading comprehension of both kanji (ideogram) words and kana (phonogram) words was preserved. Oral reading and comprehension of written sentences was mildly disturbed.

Writing: Spontaneous writing was severely impaired; the patient could not even write his own name, but he could copy his name and address.

(5) *Calculation*: Acalculia was very severe; the patient could only carry out one-digit addition.

(6) *Praxis*: Ideomotor apraxia was evidenced by the amorphous movements made with both hands when he tried to carry out symbolic gestures (e.g., waving goodbye, saluting) or pretended to use objects (e.g., a toothbrush, or a comb) in response to verbal commands. Amorphous movements also appeared on rare occasion when he manipulated real objects. However, these symptoms disappeared within a month. His sequential manipulation of real objects (e.g., making tea) was correct, so there was no ideational apraxia. Buccofacial apraxia was not observed. His preserved ability to copy a cube ruled out the presence of constructional apraxia. Mild dressing apraxia and motor neglect (*négligence motrice*) of the left upper extremity were observed.

(7) *Gnosia*: Finger agnosia and left unilateral spatial neglect were observed. Body parts agnosia was also observed; the patient could not point to his body parts in response to verbal command. Right-left disorientation was not noted. Unilateral body agnosia, which had been noted in the acute period, was not observed. Topographical memory of maps was preserved. The patient could indicate the locations of major Japanese cities on a blank map except for those in the west (left) side.

Visual recognition of objects was preserved (details of the tests of visual recognition will be described later). Auditory recognition was also preserved; when the patient heard tape recorded familiar sounds (e.g., a telephone bell, the sound of waves), and was asked to select the corresponding source from four pictures, he was successful in 16 trials out of 18. However, when the recognition involved objects presented tactually to the right hand (healthy side), the patient complained that he could not identify them.

Detailed Neuropsychological Examination of Tactile Recognition (Right Hand)

Two normal geriatric subjects of Case 1's age served as controls. The subjects were seated in front of a table, where a wooden shield prevented them from seeing their hands or the test items. The table was covered with a thick sheet of soundproof cloth to eliminate auditory cues when objects were manipulated. Pauses were introduced every several trials of the tactile tests, to prevent fatigue and to reduce the lability of function.

The neurological examination had not disclosed a sensory deficit of the right hand. We gave, however, in addition, two tests of tactile localization and two-point discrimination to make sure that minor impairment had not escaped our attention.

(1) Tactile localization

Procedure: The examiner touched a point on the right hand of the patient, then asked him to indicate the point by touching it with his tongue. This peculiar response mode was chosen because of sensory disturbances and motor neglect in the left hand.

Results: The responses were correct.

(2) Two-point discrimination

Procedure: The examiner touched the finger pad of the patient with a pair of plastic needles of a slide caliper (Takei Co. Ltd., esthesiometer of Spearman type) and asked him to respond "one" or "two". The distance of the needles was varied from 0 to 1, 2, 3, 4, 5, or 6 mm in a random order, and each step was presented ten times (method of constant stimuli) for a total of 70 trials.

Results: The 50% discrimination threshold of the patient was 2.4 mm on the index finger, which did not differ from normal data (2.2 mm; Weber, 1846). The 50% discrimination threshold was 2.6 mm on the thumb, 2.6 mm on the middle finger, 3.0 mm on the ring finger, and 3.0 mm on the little finger.

A. Hylognosis

(1) Weight

Procedure: Subjects were asked to choose the heavier of two stimuli that were identical in form and size but different in weight (Takei Co. Ltd., 111a). Four types of pairs (50 g vs. 52 g, 50 g vs. 54 g, 50 g vs. 56 g, 50 g vs. 58 g) were used. Each pair of stimuli was presented ten times in random order for a total of 40 trials. In half of the trials the heavier weight was presented on the right side, and in the other half on the left side. The side order was randomized.

Results: The numbers of correct responses of the patient were 7/10 for the comparison of 50 g vs. 52 g, 8/10 for 50 g vs. 54 g, 9/10 for 50 g vs. 56 g, 10/10 for 50 g vs. 58 g. They did not differ from those of normal controls.

(2) Texture

Procedure: The subjects were asked to palpate with the right hand two pieces of sandpaper (waterproof abrasive paper) with subtly different textures and to indicate the rougher one. Two pieces of 115 mm × 70 mm sandpaper were attached to a cardboard of 272 mm × 392 mm, 80 mm apart. Four types of pairs, that is, JIS (Japan Industrial Standard) CC CW 800 (grains to the linear inch)

vs. 400, 800 vs. 600, 800 vs. 1000, 800 vs. 1200, were used. Each pair was presented ten times in random order for a total of 40 trials. In half of the trials, the rougher piece of sandpaper was presented on the right side, and in the other half on the left side. The side order was randomized.

Results: The numbers of correct responses of the patient were 10/10 for the comparison of 800 vs. 400, 10/10 for 800 vs. 600, 9/10 for 800 vs. 1000, 10/10 for 800 vs. 1200. They did not differ from those of normal controls.

(3) *Material*

Procedure: Five 40×65 mm pieces of leather, cowhide, the back of cowhide, pigskin, the back of pigskin, and synthetic leather were attached to a plastic board. A piece of leather identical to one of these five stimuli was presented initially, and then the subject was asked to choose the matching stimulus among the five alternatives. Tests were also done with five pieces of cloth, that is, silk, canvas, felt, wool (knit), and terry cloth.

Results: The performance of the patient did not differ from that of the normal controls; the number of correct responses of the patient was 7/10, while those of the normal subjects were 7/10 and 5/10 respectively.

B. *Morphognosis*

(1) *Discrimination of patterns (two-dimensional figures)*

Procedure: Three sets of 5 to 6 plastic figures representing variations of circles, triangles and squares, respectively, about 30×30 mm in size, and 1.5 mm thick, were attached to a plastic board. A figure identical to one of these patterns was presented followed by the corresponding set of alternatives among which the patient had to recognize the identical stimulus. The total number of trials was 16 (5, 5 and 6 stimuli).

Results: The performance of the patient did not differ from that of controls; The patient had 14/16 correct responses while the normal controls scored 14/16 and 13/16.

(2) *Discrimination of form (three-dimensional figures)*

Procedure 1. The patient palpated an object with his eyes closed, and then was asked to draw a picture of it with his eyes open.

Results: He could draw the form of tactually presented objects, though the orientation of his drawing was sometimes different from that in which the objects were usually used (Figure 2).

Procedure 2. Spanners of different forms were used. The subject palpated a spanner which was placed in a bag to prevent him from seeing it, and then was asked to draw a picture of it with the same hand (tactile presentation). Subsequently, he was asked to draw the same pictures looking at the objects (visual presentation).

Results: He could draw the pictures in a recognizable way even when they had been presented tactually (Figure 3).

(3) *Matching of objects*

Procedure 1. Tactile-tactile matching of objects. The patient was asked to match to sample five objects (e.g., a chalk, a nail, a pencil, and a screw) presented out of vision. 15 trials were given.

Results: The task embarrassed the patient. For example, palpating two nails,

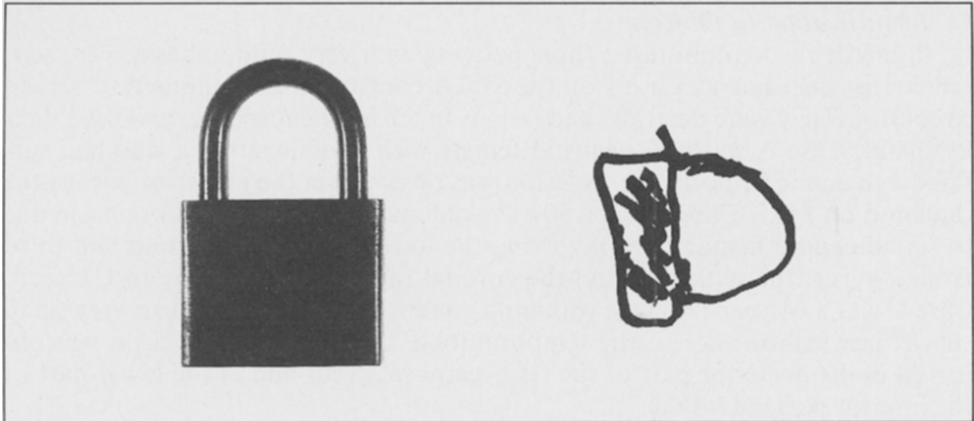


Fig. 2 - Example of a drawing of tactually presented objects.

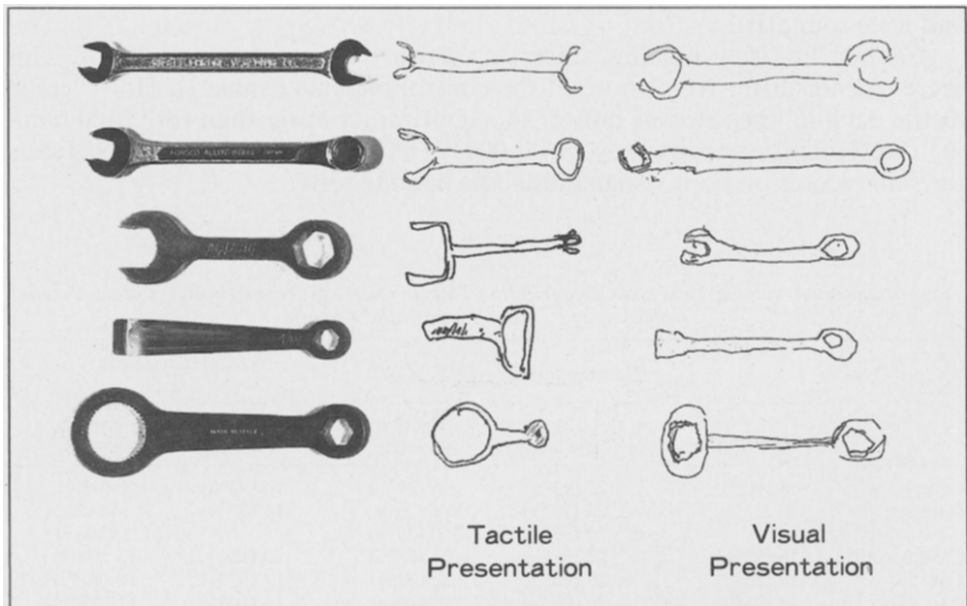


Fig. 3 - Discrimination of three dimensional figures. Drawings of spanners presented visually and tactually.

he pointed out minute differences of scratches on their surface or the difference of the salience of the points between them, and insisted that they were different. When instructed to simply indicate which alternative was more similar to the sample, he responded correctly (14/15).

Procedure 2. Visual-tactile matching of objects. The patient was asked to match an object presented visually with its analogue from a group of five objects presented tactually. 20 trials were given.

Results. He was correct on all trials (20/20).

C. Identification of Objects

In tactile recognition tests, three patients with very mild aphasia, who scored almost the same as Case 1 on the SLTA confrontation naming test, served as control. They were dextrals, had lesions in the left hemisphere, and used their left hand. Case A was a 57-year-old female with anomic aphasia who had suffered a thalamic hemorrhage. A lesion was observed in the posterior part of the thalamus on MRI. Case B was a 50-year-old male with mild motor aphasia due to subarachnoid hemorrhage involving the lower part of the second and third frontal gyrus, the putamen, and the coronal radiations according to CT scan. Case C was a 64-year-old male with mild conduction aphasia due to a very small subcortical hemorrhage of the temporal lobe. On MRI a small lesion was observed in the posterior part of the first temporal gyrus and in the lower part of the inferior parietal lobule.

(1) Naming of objects

Procedure: Visual and tactile presentation tests were carried out with the same 24 objects. The stimuli were small enough to be handled with one hand, and were soundless.

Results: In visual naming, Case 1's correct response rate was 22/24. This score did not differ from those of the control patients (Table I). However, in tactile naming, the rate was only 5/24, significantly lower than for visual naming (McNemar's test, two way, $p = 0.0001$). The control patients had virtually the same scores on both visual and tactile naming tests.

TABLE I

Performances on Naming Tests and Categorization Tests in Case 1 (Tactile Agnosia), Case 2 (Tactile Aphasia), and Three Cases of Mild Aphasia

	Naming tests			Categorization tests	
	SLTA* (N = 20)	Visual (N = 24)	Tactile (N = 24)	Visual (N = 15)	Tactile (N = 15)
Case 1	18 (90%)	22 (92%)	5 (21%)	14 (93%)	0 (0%)
Case 2	17 (85%) #	22 (92%) #	R 6 (25%) L 6 (25%)	14 (93%)	R 15 (100%) L 14 (93%)
Case A	18 (90%)	22 (92%)	21 (88%)	15 (100%)	15 (100%)
Case B	17 (85%)	23 (96%)	22 (92%)	13 (87%)	12 (80%)
Case C	15 (75%)	20 (83%)	19 (79%)	15 (100%)	15 (100%)

*Confrontation naming on Japanese Standard Language Test of Aphasia.

Verbal definition naming was used. For details, see text.

A few examples of the patient's tactile naming are given.

A pencil: "This is something hexagonal, long and narrow, ..., This is a pencil!"

An egg: "... (examiner: is it a ping-pong ball?). "...No, it is not. A ping-pong ball is perfect sphere." (examiner: Is it an egg?). "...I can't remember such a thing."

A button: "This is tiny and circular." (examiner: Is it a coin?). "No it isn't a coin, it is plastic."

(2) Categorization of objects

Procedure 1: Testing was carried out under the conditions of visual presentation and tactile presentation. On visual categorization (Figure 4), an object (e.g., a fork) was presented initially, then four objects (e.g., a metal comb, a pair of scissors, a spanner, and a knife) were introduced. The patient was asked to choose the one (i.e., knife) which formed a semantic pair with the object presented initially.

On tactile categorization, an object was placed into a hand for palpation, then placed under the back of the hand (between the back of the hand and the soundproof carpet) in order to aid the patient to remember it. Next, four objects were placed into the same hand successively and the patient was told that one of them formed a pair with the object which had been placed under the back of his hand. This first presentation was given for practice and no categorization



Fig. 4 - Examples of the object categorization test.

was required. In the testing session, the patient was asked to raise his hand when the objects presented to the palm and back of the hand formed a pair. The procedure was repeated twice when the patient did not answer. If the patient did not respond to the third presentation, his response was regarded as an error. 15 trials under both visual and tactile conditions were carried out. In the categorization tests, either the objects of the trial differed in shape but were of the same material (e.g., Figure 4, upper), or they differed both in shape and material (Figure 4, lower).

Results: The patient could categorize objects when they were presented visually (14/15). His scores did not differ from those of the control group. However, he could not categorize objects at all (0/15) under the tactile presentation condition. The difference was statistically significant (McNemar's test, two way, $p = 0.0006$). The control patients could categorize tactually presented objects, and their performances did not differ from that on the visual presentation (Table I).

Procedure 2: This was an easy task in which three objects (e.g., a padlock, a magnifying glass, and a key) were presented and the patient was asked to select the two that were semantically related (a padlock and a key). Twelve trials were carried out both in the visual and the tactile condition.

Results: The patient performed correctly in the visual condition (12/12), while the number of correct responses was at chance level in the tactile condition (4/12). The difference was statistically significant (McNemar's test, two way, $p = 0.0013$).

(3) *Pantomiming the use of objects.*

Procedure: The patient was blindfolded and asked to pantomime how he would use the objects he was palpating. 15 trials were carried out.

Results: The patient could not pantomime the use of any tactually presented object. He waved his hand from side to side in front of his face, no matter what the object was. On the contrary, he could demonstrate the use of objects in response to verbal commands.

(4) *Tactile identification of objects named by the examiner.*

Procedure: The patient was asked to find the object named by examiner from among four objects given to him in succession. 24 trials were carried out. When the patient could point to the object, it was presented again tactually, and he was asked to name it.

Results: In the pointing test a mild disturbance was observed (17/24). In contrast, on the naming test the deficit was severe (7/17). Naming was significantly worse than pointing (Fischer exact probability test, one way, $p = 0.044$). In the control group, the correct responses in the pointing and naming tests were 23/24 and 22/23 for case A, 24/24 and 23/24 for case B, and 24/24 and 23/24 for case C.

Comment: The patient had neither ahylognosia nor amorphognosia. However, he could not name, categorize, or pantomime the use of tactually presented objects. He was diagnosed as having tactile agnosia (tactile asymbolia). Both visual and auditory recognition were preserved.

CASE 2

H.O. was a 63-year-old right-handed man whose parents, sister, and four children were dextrals. He had been a woodworker and had eight years of education. On the night of December 1, 1980, he accidentally fell off a cliff while riding a bicycle under the influence of liquor. He crawled up by himself but fell down again. When he was rescued by a passer-by, he was unconscious and was taken to a nearby surgical clinic. The following day he was transferred to the Nagano Red Cross Hospital because he was still unconscious. A right hemiparesis was observed. An acute left epidural haematoma was diagnosed by CT scan and was evacuated the same day. The haematoma, shaped like a lens and measuring up to 2.5 cm in thickness, centered on the left parietal lobe. The patient regained consciousness January 3, 1981, began to talk three days later, and began to walk in April. There were no records of neuropsychological findings. On May 20, 1981, he was received into the Kakeyu Hospital Rehabilitation Center for rehabilitation of activities of daily living (ADL).

Neurological Examination at the Time of Admission

Goldmann perimetry revealed a right homonymous hemianopia. The patient's visual acuity was 0.2 in both eyes. Performance on Ishihara's color-blindness test was normal. There was a mild spastic hemiparesis on the right side that affected the leg more severely than the arm and the lower face. Deep tendon reflexes were hyperactive and the plantar response was indifferent on the right side. Light touch was slightly impaired on the right side, whereas deep sensation was normal. Tactile point localization was slightly disturbed in the right hand. Sensory extinction with tactile double simultaneous stimulation was present in the right hand. Motor coordination was normal in the finger-nose test. "Ataxie optique" (Garcin, Rondot and Recondo, 1967; Hirayama, Toma, Hiyama et al., 1983) was detected in the right hand in the left peripheral visual field. No neurological abnormalities were found in the left limbs.

Neuroradiological Examination

CT scans were undertaken on April 27, 1982, with a SOMATOME 2 CT Scanner (Figure 5).

Horizontal section 8 cm above the OM line (Figure 5, A): The subcortical region of the left angular gyrus was damaged, and the posterior parts of the arcuate fasciculus, the external capsule, and the coronal radiations as well as the posterior callosal radiations were involved by the lesion. Section 7 cm above the OM line (Figure 5, B): A subcortical lesion of the left angular gyrus involved the inferior longitudinal fasciculus, the optic radiations, and the posterior callosal radiations. Coronal section (Figure 5, C): The lesion was located above the lateral ventricle and involved the posterior callosal radiations extensively. The lesion descended in a long and narrow fashion on the side of the internal wall of the posterior horn of the lateral ventricle, and affected the callosal radiations from the splenium of the corpus callosum. Another left lesion was observed in the region adjacent to the external wall of the posterior horn of the lateral ventricle, and involved the inferior longitudinal fasciculus and the optic radiations. Further, a mild atrophy of the left hemisphere was observed. The CT scan revealed that the right hemisphere was intact.

Single photon emission CT (xenon 133 inhalation method) revealed an ischemic region in the posterior part of the left hemisphere. In the right hemisphere, decrease of rCBF was observed in the border zone of the middle cerebral artery. Reduction of the rCBF in the posterior part of the right hemisphere was not significant as in Case 1.

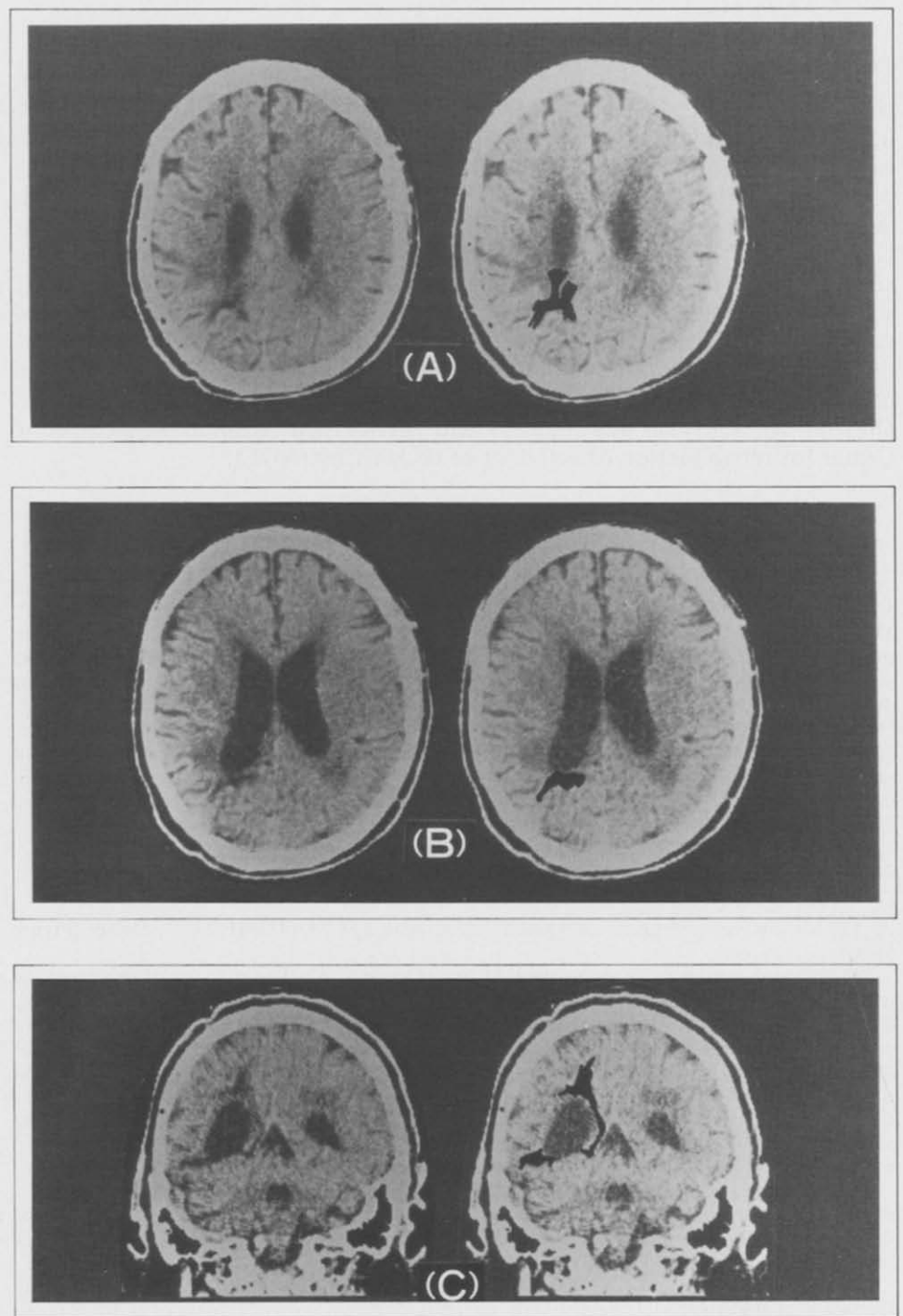


Fig. 5 - CT scans of Case 2. Slices A and B represent horizontal sections 8 cm and 7 cm above the OM line. Slice C represents a coronal section.

Neuropsychological Examination

The patient cooperated in the examination. He complained that his head had become unclear after his injury, however, he did not seem to be seriously worried about it.

(1) *Arousal level and attention* were normal.

(2) *Intelligence*: The patient had a verbal IQ of 63 and a performance IQ of 80 on the WAIS Japanese edition.

(3) *Episodic memory*: The patient's immediate recall was good (6 digits forward), but recent memory was severely impaired. Remote memory was slightly impaired. Memory function improved progressively but some disturbances continued.

(4) *Language*: Very mild anomic aphasia, severe alexia and agraphia were observed. The patient had no difficulty in daily conversation.

Spontaneous speech: There were no signs of dysprosody, phonetic disintegration or phonemic paraphasia. Circumlocutions and self-corrected verbal paraphasias were noted on rare occasions. In object naming (verbal definition naming) his score was 17/20 on the SLTA (Japanese Standard Language Test of Aphasia). This score was almost identical to the scores of Case 1 and the three controls. Neither grammatical nor syntactical disturbances were noted.

Auditory comprehension: Auditory comprehension was slightly impaired. Case 2 could not comprehend sentences when they were involved in style. Auditory retention span was 4 words.

Repetition: The patient could repeat a sentence up to 33 syllables on the SSDD (Schuell Sasanuma Differential Diagnosis of Aphasia).

Reading: Reading aloud and reading comprehension of kanji (ideogram) words were severely impaired. He could not read aloud kana (phonogram) words at all; comprehension was at chance level.

Writing: Agraphia was severe. He could only sign his name in kanji.

(5) *Calculation*: Acalculia was very severe. He could not do written sums. He could do addition and multiplication of single digits mentally.

(6) *Praxis*: He could pantomime the use of objects in response to verbal commands. He could also perform symbolic gestures to verbal commands and imitate the gestures made by the examiner. Therefore there was no ideomotor apraxia. His sequential manipulation of real objects was correct, so there was no ideational apraxia. There was no buccofacial, constructional or dressing apraxia.

(7) *Gnosia*: The patient showed finger agnosia, right-left disorientation and body parts agnosia. There were no signs of unilateral neglect of personal and extrapersonal space. Visual recognition was preserved; he could visually categorize objects (14/15) and do "odd object out" (9/10). However, visual naming disturbance due to a visual speech disconnection was observed (optic aphasia of the left visual field in the presence of right homonymous hemianopia). The correct responses on verbal definition naming and visual naming were 34/40 and 12/40 respectively (McNemar's test, two way, $p=0.000006$). Thus the patient presented both optic aphasia and tactile aphasia, although in the present paper we will confine ourselves to the discussion of the latter, for the sake of brevity. Auditory recognition was also preserved; 16/18 (see Case 1 for the procedure).

Neuropsychological Examinations of Tactile Aphasia

The patient was either blindfolded or prevented from seeing his hands or test items by a wooden shield.

A. Comparison between Tactile Naming and Verbal Definition Naming

Procedure: Three sets of comparison tests, verbal definition naming vs. right hand tactile naming, verbal definition naming vs. left hand tactile naming, and right hand vs. left hand tactile naming, were carried out. In order to counter-

balance the effects of learning, fatigue and so on, the two conditions were alternated in ABBA order in each test. Under the condition of verbal definition naming, a verbal definition (e.g., "What is the name of the instrument you use when you have a cold and take your temperature") was read out by the experimenter. 24 trials were carried out in each condition.

Results: The correct responses on verbal definition naming and right hand tactile naming were 22/24 vs. 6/24, respectively (McNemar's test, two way, $p=0.0004$). Those on verbal definition naming and left hand tactile naming were 23/24 vs. 11/24, respectively (McNemar's test, two way, $p=0.0016$). No difference was observed between right hand and left hand tactile naming, 6/24 vs. 6/24, respectively.

B. Comparison between Tactile Categorization and Tactile Naming

Procedure: 15 trials of the tactile categorization test for both hands were conducted (For details, see Case 1, C-2, procedure 1, tactile categorization). When a categorization was correct, the target object, which had been placed under the back of the hand, was placed on the palm, and the patient was asked to name it.

Results: Numbers of correct responses for the tactile categorization and tactile naming tests were 15/15 and 4/15 respectively for the right hand (Fisher Exact Probability Test, one way, $p=0.000025$), and 14/15 and 3/14, respectively for the left hand (Fisher Exact Probability Test, one way, $p=0.0001$). The patient's score in the categorization test was identical to those of the control patients (Table I), while his performance on the naming test was significantly worse.

Examples of misnaming after correct categorization were:

Right hand

- a toothbrush: "This is a necktie pin."
- a fork: "This is a bottle opener."
- a pencil: "This is a weight from a balance scale."
- a coffee cup: "This absorbs ink..."

Left hand

- a toothbrush: "This is a tea strainer."
- a fork: "I've forgotten it..."
- a pencil: "A cigarette, I can't retrieve..., a pipe..."
- a coffee cup: "I've forgotten it."

C. Tactile Semantic Grouping

Procedure: Six objects (e.g., a hammer, a toothbrush, an eraser, a toothpaste, a pencil, a nail) were presented tactually, and the patient was asked to make three groups of semantically related pairs (e.g., a hammer and a nail, a toothbrush and a toothpaste, and a pencil and an eraser). Four trials (12 groupings) were carried out for both the right and the left hand.

Result: Correct responses were 11/12 for the right hand, and 12/12 for the left hand. Thus Case 2 recognized the objects he could not name.

D. Interhemispheric Transfer of Somatosensory Information

Procedure: With his eyes closed, the patient palpated an object with one hand. Then he was asked to select the identical object from among five objects presented to the other hand. Ten trials were conducted.

Result: The responses were 100% correct, showing that the connection of the somatosensory systems of the left and the right hemisphere was intact.

Comment: In aphasics, object naming is equally disturbed across the modalities of sensory stimulation (Spree, Benton and van Allen, 1966; Goodglass, Barton and Kaplan, 1968). On the contrary, Case 2 showed a very mild naming disturbance in response to auditory stimulation and a severe disorder in response to tactile stimulation. Hence the tactile naming disturbance of Case 2 was modality specific and could not be attributed to aphasic anomia.

The numbers of correct responses on the tactile naming test were almost identical for Case 2 (6/24) and for Case 1 (5/24), however, their performance on tactile categorization tasks was markedly different; Case 1 could not categorize objects at all, while Case 2 could categorize objects as well as control patients (Table I). Case 2 was diagnosed as having bilateral tactile aphasia because he could not name tactually presented objects, although tactile recognition was intact.

DISCUSSION

Puchelt's (1844) report of five cases with "partielle Empfindungslähmung" (partial sensory paralysis) has been considered the first attempt to distinguish tactile recognition disturbance from tactile sensory disturbance (Delay, 1935). Wernicke (1895) outlined the symptomatology and the anatomy of tactile agnosia. He distinguished two phases of tactile recognition. Primary identification is the recognition of the tactile qualities; i.e., dimension, form, consistency, unevenness, texture, etc., of an object. Secondary identification is the recognition of the significance of an object. Primary sensory paralysis is a disturbance of primary recognition which occurs when the retrieval of past sensations remaining as memory images in the sensory cortex is impaired by the lesion. Secondary sensory paralysis, a disturbance of the secondary recognition, occurs when the association of the retrieved tactile image with the other sensory images is prevented. The patient cannot identify object although he can recognize their tactile qualities. Raymond and Egger (1906) reported a case with "tactile aphasia" of the right hand. The patient could not name a tactually presented object, while she could recognize the tactile qualities of the objects. The authors concluded that the association among the elementary tactile sensations of their patient was preserved, while the association with the speech area was destroyed. Déjérine (1906, 1907) disagreed with their conclusion, since he believed that the patient "did not know" what the objects were, and therefore had "agnosia", and not aphasia. Claparède (1906) also disagreed with Raymond and

Egger (1906). He divided tactile agnosia into stereo-agnosia, which corresponds to Wernicke's primary sensory paralysis, and tactile asymbolia, i.e., secondary sensory paralysis. A number of reports of tactile agnosia followed. Delay (1935) made a comprehensive survey of studies on the pathology of tactile recognition up to that time. He classified the disturbances of tactile recognition (astereognosia) into ahylognosia, amorphognosia and tactile asymbolia.

In the history of tactile agnosia, terminological confusion is frequent. First, when the word "tactile" is used to represent one of elementary sensations, the term literally means tactile sensation. But when the same term is used in the context of "tactile agnosia", it refers to identification by touching. Under such a condition, the subject uses all somesthetic sensations, not only tactile sensation but also other surface sensations and deep sensation. Second, "stereognosis" meant primary recognition for Claparède (1906), and the whole tactile recognition process, including both primary and secondary recognition, for Delay (1935). Third, different terms are used by researchers for the disturbance of secondary identification: e.g., secondary sensory paralysis (Tastlähmung, Wernicke, 1895), tactile asymbolia (asymbolie tactile, Claparède, 1906; Delay, 1935), tactile agnosia (agnosie tactile, Déjérine, 1906, 1907), pure astereognosia (astéréognosie pure, Guillain and Bize, 1932), transcortical tactile paralysis (transkortikale Tastlähmung, Kutner, 1907), cortical sensibility disturbance (kortikale Sensibilitätsstörungen, Goldstein, 1916), pure tactile agnosia (Reine taktile Agnosie, Gerstmann, 1918), etc.

Bay (1944) strongly denied the existence of tactile agnosia. He investigated six cases and concluded that the severity of the elementary sensation deficit was proportional to that of the "so-called agnosia", and the disturbances of tactile recognition were a direct consequence of the disturbances of the primary sensation.

Geschwind (1965) also cast doubt upon the existence of tactile agnosia. The callosal-damaged patient of Geschwind and Kaplan (1962) incorrectly named objects placed in the left hand when blindfolded. Geschwind concluded that this defect was one of naming, not of recognition. The patient's tactile recognition was obviously preserved because he could handle the objects correctly with the left hand. He interpreted the patient's tactile aphasia (tacto-verbal disconnection) as a result of the failure of the somesthetic information in the right hemisphere to cross to the opposite speech dominant hemisphere due to the callosal lesion. Geschwind (1965) presumed that the cases that had been described as tactile agnosia in the literature were actually tactile aphasia. Further cases with left hand tactile aphasia occurring after callosal lesions have been reported (Balaceanu, Gheorghiu, Lupu et al., 1970; Brion and Jedynek, 1972; Dimond, Scammell, Brouwers et al., 1977; Yamadori, Osumi, Ikeda et al., 1980; Gersh and Damasio, 1981; Degos, Gray, Louarn et al., 1987; Kawamura, Hirayama and Yamamoto, 1989). Beauvois et al. (1978) showed that tactile aphasia could occur in both hands.

Thus, not only the differentiation between tactile agnosia and disturbances of primary sensation, but also that between tactile agnosia and tactile aphasia is indispensable to verify the existence of tactile agnosia.

The Symptoms of Tactile Agnosia and Tactile Aphasia

Case 1's ability to differentiate weight, texture, and materials of tactually presented objects as efficiently as normal geriatric controls did mean that he had normal hylognosis. His discrimination of two and three dimensional figures was also preserved, indicating that his morphognosis was normal. Nevertheless, he could not name objects when they were presented tactually (5/24). His performance on categorization tests revealed that he could not name tactually presented objects because he "did not know" them, and thus he deserved the diagnosis of tactile agnosia. Also Case 2 scored very poorly (6/24) on tactile naming test, but he could categorize objects as well as control patients. Case 2 was diagnosed as having tactile aphasia.

Visual and auditory recognition were preserved both in Cases 1 and 2, who scored identically on the visual categorization test (14/15) and the auditory recognition test (16/18). Performances in confrontation naming were also almost identical (18/20 and 17/20, respectively).

Patients with associative visual agnosia cannot categorize visually presented objects (Rubens and Benson, 1971; Hécaen, Goldblum, Masure et al., 1974; Albert, Reches and Silverberg, 1975), while patients with optic aphasia (visual-speech disconnection syndrome) can (Branch Coslett and Saffran, 1989). The evidence from our patients revealed that parallel conditions occurred in the tactile modality.

Until recently, the schema of Wernicke (1895) has been employed to explain the symptoms of tactile agnosia. We think that a modern approach, based on the concepts of cognitive psychology, provides a more powerful interpretation of the symptoms of tactile agnosia and of the difference between tactile agnosia and tactile aphasia. According to this schema, palpating an object activates somatosensory receptors, which send the information to a register of somatosensory stimuli (Figure 6). The information is then sent to somatosensory short term memory (STM), where it is compared with information retrieved from somatosensory long term memory (LTM) in which past memories of palpation are stored. The comparison permits differentiation of the material and form of the object, and achievement of hylognosis and morphognosis (Figure 6), for example, that the palpated object is made of plastic, is tiny, and circular. The information on the material and form of the object is then compared with the information retrieved from semantic (conceptual) memory (Collins and Quillian, 1969; Rips, Shoben and Smith, 1973; Warrington, 1975; De Renzi, Liotti and Nichelli, 1987) in which semantic knowledge of objects is stored. This process results in the recognition of the palpated object (Figure 6, descending pathway), e.g., that it is a button, and not a coin, a snap, or a zipper.

Tactile agnosia occurs when information on the material and form of an object, analyzed in the somatosensory STM, cannot access semantic memory, while tactile aphasia occurs when retrieved semantic memory is not transmitted to lexical memory (Figure 6).

In Case 1 tactile naming and tactile categorization were severely disturbed, while the identification of the object named by examiner among tactually presented objects was only mildly disturbed (examination C-4). Such a dissocia-

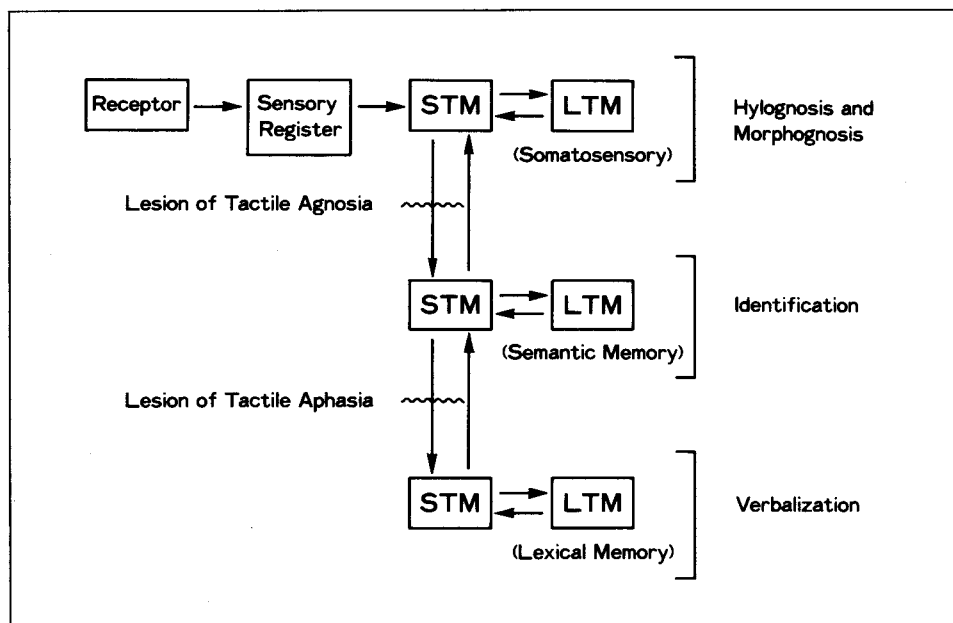


Fig. 6 - Flow chart of information processing in tactile agnosia and tactile aphasia.

tion, which has also been observed in a patient with associative visual agnosia (Albert et al., 1975), can be explained by the schema presented above (Figure 6). In the pointing test, the verbal name provided by the examiner is first decoded by lexical memory, and then activates semantic memory (Figure 6, ascending pathway), allowing the retrieval of the concept of the object. This information is transmitted to the somatosensory memory storage, where it activates the information on the material and the form of the object. At the same time, as the patient palpates objects, the information from the somatosensory receptors reaches the somatosensory STM, where it is analyzed. Thus the information on the stimulus he is palpating can be compared with the verbal information from the examiner, allowing judgment of same or different. If the lesion blocks the transmission of information along the ascending pathway, pointing of tactually presented objects will be disrupted.

Lesion and Pathogenesis of Tactile Agnosia and Tactile Aphasia

The cases so far reported in the literature under the heading of tactile agnosia shed little light for the understanding of its lesion and pathogenesis, because they did not provide information sufficient to decide whether they represented instances of tactile agnosia or tactile aphasia. Only three cases can serve as a basis for our discussion: our case of tactile agnosia and two cases of bilateral tactile aphasia (our case and the case of Beauvois et al., 1978).

CT scans of Case 1 (tactile agnosia) demonstrated a low density area in the

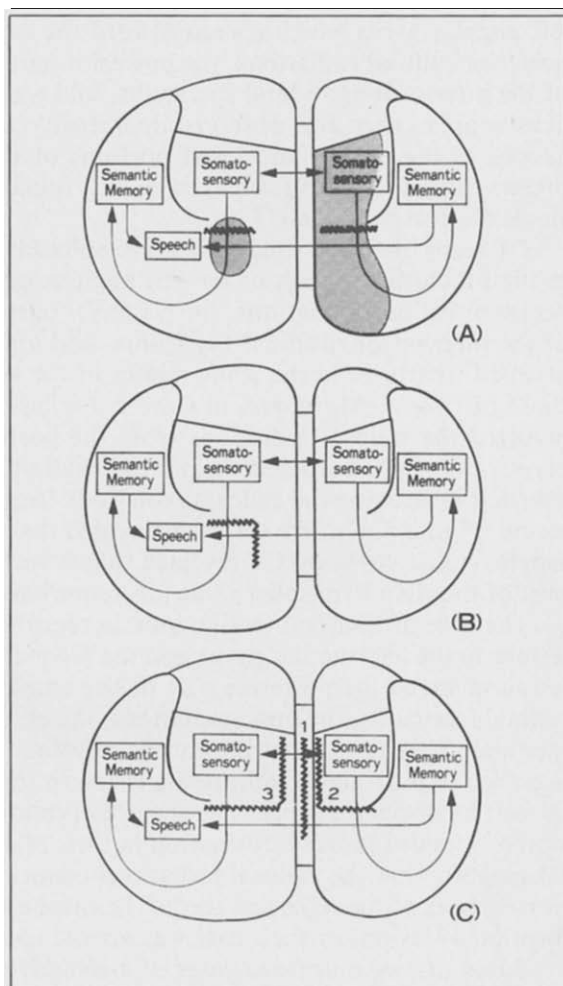
left angular gyrus which spread toward the lateral ventricle, and involved the posterior callosal radiations, the posterior part of the arcuate fasciculus, a part of the inferior longitudinal fasciculus, and a part of the optic radiations. Low density areas were also observed in extensive regions of the right parietal lobe as well as the medial and basal portions of the right occipital lobe. Regions preserved on CT scans seemed to be well functioning, based on the evidence of single photon emission CT.

CT scans of Case 2 (bilateral tactile aphasia) demonstrated a low density area in the subcortical region of the left angular gyrus, and the involvement of the posterior callosal radiations, the posterior part of the arcuate fasciculus, a part of the inferior longitudinal fasciculus, and a part of the optic radiations. The affected structures in the white matter of the left angular gyrus were similar to those of Case 1. Moreover, in Case 2, the lesion overlaid the lateral ventricle, involved the callosal radiations from the posterior part of the truncus of the corpus callosum, bordered the internal wall of the posterior horn of the lateral ventricle destroying the callosal radiations from the splenium of the corpus callosum (Figure 5, C). The CT scan revealed that the right hemisphere was intact. Single photon emission CT revealed that reduction of the rCBF in the posterior part of the right hemisphere was less remarkable than in Case 1.

The case of bilateral tactile aphasia reported by Beauvois et al. (1978) had lesions in the left angular gyrus and the second temporal gyrus. The subcortical lesion involved the posterior part of the arcuate fasciculus, the inferior longitudinal fasciculus, the optic radiations, the occipital vertical fasciculus, and the tapetum. They noted that the corpus callosum was not involved. However, the presence of pure alexia indicated a lesion in the posterior callosal radiations of the left hemisphere. Moreover, the preservation of inter-hemispheric transmission of somatosensory information in their case as well as in our Case 2 (cf. test D) suggests that the callosal radiations connecting the somatosensory association cortices of the right and the left hemisphere were preserved. Therefore, the location of lesions of their case was almost identical with ours.

Based on two autopsied cases of associative visual agnosia with bilateral lesions of the inferior longitudinal fasciculi (Rubens and Benson, 1971; Benson, Segarra and Albert, 1974; Albert et al., 1975; Albert, Soffer, Silverberg et al., 1979), visual agnosia has been thought to be due to the defective transfer of information from the visual association cortex (areas 18, 19) to the memory stores of the limbic system and the temporal lobe. Cases with a disturbance of semantic memory, namely, those who could not recognize objects whatever the modality of sensory stimulation, had wide and irregular lesions in the basal portion of the left temporal lobe, and a smaller lesion in the right inferior temporal lobe or insula (Cummings and Duchon, 1981, Case 4, autopsy, Pick disease, this patient was reported as Case 3 by Warrington, 1975; De Renzi et al., 1987, MRI, encephalitis; Pietrini, Nertempi, Vaglia et al., 1988, Case 2, CT and MRI, encephalitis). In these patients, the most affected structure was the anterior portion of the left inferior temporal lobe. However, this region was also affected significantly in the cases without semantic memory disturbance reported by the same authors (Cummings and Duchon, 1981, Cases 1, 2, and 3, autopsy, Pick disease; Pietrini et al., 1988, Case 1, CT and MRI, encephalitis).

Fig. 7 - A model of the locus of lesion and pathogenesis of tactile agnosia and tactile aphasia. Transmission of information is assumed to be disturbed in the regions indicated by zigzag lines. (A) Tactile agnosia. The shadowed areas denote the lesion of Case 1. (B) Bilateral tactile aphasia. (C) 1: Unilateral tactile aphasia of the left hand; inter-hemispheric disconnection syndrome. 2: Unilateral tactile agnosia of the left hand; isolation of the right somatosensory association cortex. 3: Unilateral tactile agnosia of the right hand; isolation of the left somatosensory association cortex.



Semantic memory disturbance was not noted in the nine cases of bilateral medial temporal lobe resection reported by Scoville and Milner (1957), including Case H.M. who was given a series of detailed neuropsychological examinations. In these cases, the temporal tip, the medial surface of the temporal lobe, the uncus, the amygdaloid nucleus, or the hippocampus were removed bilaterally. The lateral edge of the resection was the temporal horn, so the middle and posterior part of the inferior temporal lobe was intact (Scoville and Milner, 1957, Figures 1 and 2). These findings suggest that the middle and posterior parts of the inferior temporal lobe are the regions crucially implicated in semantic memory. In addition, the patients of Scoville and Milner (1957) indicate that information from the sensory association cortices can be transferred to the semantic memory store of the inferior temporal lobe, without intervention of the medial temporal lobe or Papez circuit. The above mentioned cases with semantic memory disturbance had bilateral lesions, and in commissurotomy

patients object recognition was achieved by either hemisphere (Geschwind and Kaplan, 1962; Gazzaniga and Sperry, 1967). Therefore, the inferior temporal lobe appears to participate in semantic memory bilaterally.

Sensory association cortex, semantic memory system, and their connecting pathways appear to function as a circuit for object recognition. Lesion of the connecting pathways will produce agnosia of a given modality.

Somatosensory association cortices of the parietal lobe perform tactile primary recognition (hylognosis and morphognosis) (Figure 7). The region responsible for tactile secondary recognition is unknown. However, we assume that recognition of a tactually presented object occurs when the information on the material and form of the object analyzed in the somatosensory association cortex is compared with the information in the semantic memory system. Two pathways can connect the somatosensory association cortex with the inferior temporal lobe. One goes by way of the posterior part of the arcuate fasciculus, to the posterior part of the middle temporal gyrus and the angular gyrus, then reaches the inferior temporal gyrus via short fibers (Djérine, 1895, p. 756, 748). The other goes through the posterior part of the arcuate fasciculus, is transmitted to the occipital vertical fasciculus, relayed to the inferior longitudinal fasciculus, and then goes forward to the inferior temporal lobe (Djérine, 1895, pp. 781-782). When these circuits are bilaterally encroached upon by the lesion, object recognition does not occur, despite preserved hylognosis and morphognosis (Figure 7, A). In Case 1, the arcuate fasciculus and the inferior longitudinal fasciculus were destroyed in the white matter of the left angular gyrus. The same structures were encroached upon in the right hemisphere by the extensive lesion. This combination of lesions isolated the left somatosensory association cortex from semantic memories, resulting in tactile agnosia of the right hand (Figure 7, A).

In the left hemisphere, there was no lesion which disconnects the visual association cortex or the auditory association cortex from the inferior temporal lobe on CT scan.

Case 1 was a sinistral. However, the hemisphere dominant for language was likely to be the left since only mild oral language disturbance occurred after extensive damage to the right hemisphere, and alexia and agraphia could well have resulted from damage to the left angular gyrus.

Also the pathogenesis of bilateral tactile aphasia due to a unilateral lesion in the left angular gyrus can be explained by our schema. In the left hemisphere, the lesion of the arcuate fasciculus and the inferior longitudinal fasciculus disconnected the somatosensory association cortex from semantic memory. The efficient inter-hemispheric transmission of somatosensory information, shown by test D, suggested that the connection between the right and left somatosensory association cortices was preserved. Thanks to its integrity, the right hemisphere could match the information transmitted by the right hand (and processed by the left hemisphere) with the information directly received from the left hand, and thus it could recognize objects palpated with either the right or the left hand. However, the lesion in the posterior-callosal radiations running through the subcortical regions of the left angular gyrus disconnected the tactile recognition area of the right hemisphere from the speech area of the left

hemisphere (Figure 7, B). The hypothesis that this is the route linking the tactile recognition region of the right hemisphere with the speech area is borne out by the fact that the posterior part of the truncus of the corpus callosum was damaged in the cases of unilateral left side tactile aphasia (Dimond et al., 1977; Gersh and Damasio, 1981; Degos et al., 1987; Kawamura et al., 1989).

Granted that unilateral tactile aphasia of the left hand exists (Figure 7, C-1), is it conceivable that also unilateral tactile agnosia can occur? We predict that when the right somatosensory association cortex is disconnected from the semantic memory system by a lesion in the right arcuate fasciculus and the inferior longitudinal fasciculus, and at the same time, disconnected from the left hemisphere by a lesion of the posterior callosal radiations, tactile agnosia limited to the left hand will appear (Figure 7, C-2). In the same vein, we argue that when the left somatosensory association cortex is disconnected from both the semantic memory system of the ipsilateral hemisphere and the somatosensory association cortex of the contralateral hemisphere, tactile agnosia limited to the right hand will occur (Figure 7, C-3).

Finally, we would like to argue that our hypothesis is not at variance with the lesion reported in previous cases of tactile "agnosia".

Apparently three cases of tactile agnosia attributed to a frontal lesion disprove our hypothesis. In the case of Poggio (1908), tactile naming disturbance of the left hand appeared after the removal of two cysticercus cysts, one located in the second frontal gyrus and the other in the "center of fingers" of the right hemisphere. Since the patient also showed mild sensory disturbance of the left hand, we cannot be sure that the lesion was restricted to the frontal lobe. The case of P. Marie et al. (1924) had tactile naming disturbance of the left hand due to a glioma in the first and second frontal gyrus of the right hemisphere. After removal of the glioma, hemiplegia and sensory disturbance of the left side was observed. It is not clear whether the lesion was restricted to the frontal lobe, and callosal radiations were indeed intact. The presence of severe memory disturbance and disorientation pre and postoperatively, suggests that the lesion was so extensive as to invade the contralateral hemisphere through the corpus callosum. Hécaen and David's (1945) patient was injured by seven small fragments of a shell in the left fronto-parietal region. The fragments were found not only in the frontal lobe but also in the supramarginal gyrus and the temporal lobe. Tactile agnosia was observed in the right hand, but its meaning is undermined by the fact that the patient had a flaccid hemiplegia, and could not consequently move the fingers of his right hand. This inability in palpation might have been responsible for the impaired object recognition. Therefore, it seems hazardous to conclude from these cases that frontal lesions can cause tactile agnosia.

Three cases of tactile agnosia have been autopsied. Lhermitte and Ajuriaguerra's (1938) patient had senile dementia. Significant atrophy was observed in the cortico-subcortical regions of the left temporal lobe and the parietal lobe, and in the cortico-subcortical regions of the right temporal and occipital lobe. Disturbance of tactile information processing was observed in both hands. This patient fits the description of bilateral tactile agnosia illustrated in Figure 7, A. In a case reported by Goldstein (1915), a large cystic lesion was found in the left

hemisphere. It began at the posterior portion of the anterior central gyrus and extended posteriorly, involving the posterior central gyrus, the supramarginal gyrus, the angular gyrus, and the posterior portion of the corpus callosum. No abnormality was found in the right hemisphere. Disturbance of tactile information processing was observed in both hands. This case appears to correspond to the description of bilateral tactile aphasia in Figure 7, B. The patient of Hoff (1931) had a dense gliosis in the corpus callosum, and the disturbance was observed in the left hand. This patient may have had tactile aphasia of the left hand (Figure 7, C-1). In conclusion, the findings from autopsied cases are not incompatible with our hypothesis.

We conclude that tactile agnosia and tactile aphasia are different in terms of their symptoms and of the responsible neuroanatomical lesions, and we argue that both modality specific agnosia and modality specific aphasia in the visual and tactile recognition systems share a fundamentally similar mechanism of generation.

ABSTRACT

Two patients with tactile naming disorders are reported. Case 1 (right hand tactile agnosia due to bilateral cerebral infarction) differentiated tactile qualities of objects normally, but could neither name nor categorize the objects. Case 2 (bilateral tactile aphasia after operation of an epidural left parietal haematoma) had as severe a tactile naming disturbance as Case 1, but could categorize objects normally, demonstrating that tactile recognition was preserved. Case 1 may be the first case of tactile agnosia clearly differentiated from tactile aphasia. CT scans of Case 1 revealed lesions in the left angular gyrus, and in the right parietal, temporal, and occipital lobes. Case 2 had lesions in the left angular gyrus and of posterior callosal radiations. Our findings suggest that tactile agnosia appears when the somatosensory association cortex is disconnected by a subcortical lesion of the angular gyrus from the semantic memory store located in the inferior temporal lobe, while tactile aphasia represents a tactual-verbal disconnection.

Acknowledgements. The authors are grateful to Professor Hiroshi Kuru, Department of Radiology, Juntendo University, for the important consultation on the evaluation of CT scans of Case 2. Thanks are also due to Dr. Akira Otsuka, Department of Neurosurgery, Nagano Red Cross Hospital, to Prof. Tohru Masui, Sugiyama Zyogakuen University, and to Dr. Tsutomu Fujita, Director of the Keiyo Hospital Rehabilitation Center. Appreciation is due to Dr. Kazuyoshi Fukuzawa and Dr. Rebecca E. Fukuzawa for their supervision of the English.

REFERENCES

- ALBERT, M.L., RECHES, A., and SILVERBERG, R. Associative visual agnosia without alexia. *Neurology*, 25: 322-326, 1975.
- ALBERT, M.L., SOFFER, D., SILVERBERG, R., and RECHES, A. The anatomic basis of visual agnosia. *Neurology*, 29: 876-879, 1979.
- BALACEANU, C., GHEORGHIU, M., LUPU, A., and GHEORGHITA, N. Syndrome de dysconnexion interhémisphérique dans un cas de thrombose du tronc artériel branchio-céphalique. *Revue Neurologique*, 123: 44-48, 1970.
- BAY, E. Zum problem der tactilen Agnosie. *Deutsche Zeitschrift für Nervenheilkunde*, 156: 1-3, 64-96, 1944.
- BEAUVOIS, M.F., SAILLANT, B., MEININGER, V., and LHERMITTE, F. Bilateral tactile aphasia: A tacto-verbal dysfunction. *Brain*, 101: 381-401, 1978.

- BENSON, D.F., SEGARRA, J., and ALBERT, M.L. Visual agnosia-prosopagnosia. A clinicopathologic correlation. *Archives of Neurology*, 30: 307-310, 1974.
- BONHOEFFER, K. Partielle reine Tastlähmung. *Monatsschrift für Psychiatrie und Neurologie*, 43: 141-145, 1918.
- BRANCH COSLETT, H., and SAFFRAN, E.M. Preserved object recognition and reading comprehension in optic aphasia. *Brain*, 112: 1091-1110, 1989.
- BRION, S., and JEDYNAK, C.P. Troubles du transfert interhémisphérique (callosal disconnection). A propos de trois observations de tumeurs du corps calleux. Le signe de la main étrangère. *Revue Neurologique*, 126: 257-266, 1972.
- CAMPORA, G. Astereognosis: Its causes and mechanism. *Brain*, 18: 65-71, 1925.
- CLAPARÈDE, E. Agnosie et asymbolie. A propos d'un soi-disant cas d'aphasie tactile. *Revue Neurologique*, 14: 803-805, 1906.
- COLLINS, A.M., and QUILLIAN, M.R. Retrieval time from semantic memory. *Journal of Verbal Learning and Verbal Behavior*, 8: 240-247, 1969.
- CUMMINGS, J.L., and DUCHEN, L.W. Kluver-Bucy Syndrome in Pick disease: Clinical and pathologic correlations. *Neurology*, 31: 1415-1422, 1981.
- DEGOS, J.D., GRAY, F., LOUARN, F., ANSQUER, J.C., POIRIER, J., and BARBIZET, J. Posterior callosal infarction. Clinicopathological correlations. *Brain*, 10: 1155-1171, 1987.
- DÉJÉRINE, J. *Anatomie des Centres Nerveux*. Paris: Rueff, 1895 (reprint Paris: Masson, 1980).
- DÉJÉRINE, J. Considérations sur la soi-disant "aphasie tactile". *Revue Neurologique*, 13: 597-601, 1906.
- DÉJÉRINE, J. A propos de l'agnosie tactile. *Revue Neurologique*, 15: 781-784, 1907.
- DERAY, J. *Les Astéréognosies. Pathologie du Toucher*. Paris: Masson et Cie, 1935.
- DE RENZI, E., LIOTTI, M., and NICHELLI, P. Semantic amnesia with preservation of autobiographic memory. A case report. *Cortex*, 23: 575-597, 1987.
- DIMOND, S.J., SCAMMELL, R.E., BROUWERS, E.Y.M., and WEEKS, R. Functions of the centre section (trunk) of the corpus callosum in man. *Brain*, 100: 543-562, 1977.
- FOIX, C. Sur une variété de troubles bilatéraux de la sensibilité par lésion unilatérale du cerveau. *Revue Neurologique*, 29: 322-331, 1922.
- GARCIN, R., RONDOT, P., and RECONDO, J. De Ataxie optique localisée aux deux hémichamps homonymes gauches (étude clinique avec présentation d'un film). *Revue Neurologique*, 116: 707-714, 1967.
- GAZZANIGA, M.S., and SPERRY, R.W. Language after section of the cerebral commissures. *Brain*, 90: 131-148, 1967.
- GERSH, F., and DAMASIO, A.R. Praxis and writing of the left hand may be served by different callosal pathways. *Archives of Neurology*, 38: 634-636, 1981.
- GERSTMANN, J. Reine taktile Agnosie. *Monatsschrift für Psychiatrie und Neurologie*, 44: 329-343, 1918.
- GESCHWIND, N., and KAPLAN, E. A human cerebral disconnection syndrome. *Neurology*, 12: 675-685, 1962.
- GESCHWIND, N. Disconnexion syndromes in animals and man. *Brain*, 88: 237-294, 585-644, 1965.
- GOLDSTEIN, K. Über kortikale Sensibilitätsstörungen. *Neurologisches Zentralblatt*, 35: 825-827, 1916.
- GUILLAIN, G., and BIZE, P.R. Astéréognosie pure par lésion corticale pariétale traumatique. *Revue Neurologique*, 39: 502-509, 1932.
- HASEGAWA, T., TAKEDA, K., TSUKUDA, I., TAKEUCHI, I., and WADA, A. Standard language test of aphasia. Tokyo: Homeido Shoten, 1975.
- HÉCAEN, H., and DAVID, M. Syndrome pariétal traumatique: Asymbolie tactile et hémiasomatognosie paroxystique et douloureuse. *Revue Neurologique*, 77: 113-124, 1945.
- HÉCAEN, H., GOLDBLUM, M.C., MASURE, M.C., and RAMIER, A.M. Une nouvelle observation d'agnosie d'objet. Déficit de l'association ou de la catégorisation, spécifique de la modalité visuelle. *Neuropsychologia*, 12: 447-464, 1974.
- HIRAYAMA, K., TOMA, S., HIYAMA, Y., KITA, K., and KAWAMURA, M. Semiological analysis of optic ataxia (ataxie optique de Garcin) and its possible mechanism. *Clinical Neurology (Rinsho Shinkeigaku)*, 23: 605-612, 1983.
- HOFF, F. Balkentumor mit linksseitiger Astereognosis und Apraxie. *Deutsche Zeitschrift für Nervenheilkunde*, 123: 89-100, 1931.
- KAWAMURA, M., HIRAYAMA, K., and YAMAMOTO, H. Different interhemispheric transfer of kanji and kana writing evidenced by a case with left unilateral agraphia without apraxia. *Brain*, 112: 1011-1018, 1989.
- KUTNER, R. Die transkortikale Tastlähmung. *Monatsschrift für Psychiatrie und Neurologie*, 21: 191-205, 1907.
- LHERMITTE, J., and AJURIAGUERRA, J. DE Asymbolie tactile et hallucinations du toucher. Étude anatomo-clinique. *Revue Neurologique*, 70: 492-495, 1983.
- MAIRE, P., BOUTTIER, H., and VAN BOGAERT, L. Sur un cas de tumeur préfrontale droite. Troubles de l'orientation dans l'espace. *Revue Neurologique*, 31: 209-221, 1924.
- MATSUI, T., and HIRANO, A. *An Atlas of the Human Brain for Computerized Tomography*. Tokyo: Igaku Shoin, 1977.

- OHASHI, H. *Clinical Neuropsychology (Rinsho Nobyorigaku)*. Tokyo: Igaku Shoin, 1965, pp. 346-348.
- OPPENHEIM, H. Über einen bemerkenswerten Fall von Tumor cerebri. *Berliner Klinische Wochenschrift*, 30: 1001-1004, 1906.
- PIETRINI, V., NERTEMPI, P., VAGLIA, A., REVELLO, M., PINNA, V., and FERRO-MILONE, F. Recovery from herpes simplex encephalitis: selective impairment of specific semantic categories with neuroradiological correlation. *Journal of Neurology, Neurosurgery, and Psychiatry*, 51: 1284-1293, 1988.
- POGGIO, E. Die korticale Lokalisation der Asymbolie. *Neurologisches Zentralblatt*, 27: 817-818, 1908.
- PUCHELT, F. Über partielle Empfindungslähmung. *Heidelberg Medizinisch Annalen*, 10: 485, 1844.
- RAYMOND, F., and EGGER, M. Un cas d'aphasie tactile. *Revue Neurologique*, 14: 371-375, 1906.
- RIPS, L.J., SHOEN, E.J., and SMITH, E.E. Semantic distance and the verification of semantic relations. *Journal of Verbal Learning and Verbal Behavior*, 12: 1-20, 1973.
- ROSE, F., and EGGER, M. Stéréoagnosie et asymbolie tactile. *Semaine Médicale*, 44: 517-524, 1908.
- RUBENS, A.B., and BENSON, F. Associative visual agnosia. *Archives of Neurology*, 24: 305-316, 1971.
- SALAMON, G., and HUANG, Y.P. *Computed Tomography of the Brain*. New York: Springer-Verlag, 1980.
- SASANUMA, S. Test for differential diagnosis of aphasia. In S. Sasanuma, M. Itoh, T.S. Watamori, Y. Fukusako and H. Monoi (Eds.), *Language Therapy for Aphasia*. Tokyo: Igaku Shoin, 1978.
- SCOVILLE, W.B., and MILNER, B. Loss of recent memory after bilateral hippocampal lesions. *Journal of Neurology, Neurosurgery, and Psychiatry*, 20: 11-21, 1957.
- WARRINGTON, E.K. The selective impairment of semantic memory. *Quarterly Journal of Experimental Psychology*, 27: 635-657, 1975.
- WEBER, E.H. *Der Tastsinn und das Gemeingefül. Handwörterbuch der Physiologie*, 1846 (Cited from Deray, 1935. op. cit., p. 175).
- WERNICKE, C. Zwei Fälle von Rindenläsion. *Arbeiten aus der psychiatrischen Klinik in Breslau*, 2: 35, 1895.
- YAMADORI, A., OSUMI, Y., IKEDA, H., and KANAZAWA, Y. Left unilateral agraphia and tactile anomia. Disturbance seen after occlusion of the anterior cerebral artery. *Archives of Neurology*, 37: 88-91, 1980.