

SHORT REPORT

Lacunar thalamic stroke with pure cerebellar and proprioceptive deficits

José A Gutrecht, Amir A Zamani, Deepak N Pandya

Abstract

Case reports of two patients with cerebellar ataxia and proprioceptive sensory loss are presented. MRI of the brain revealed lesions of the ventroposterior part of the thalamus. These patients illustrate clinically the anatomical independence of cerebellar and sensory pathways in the thalamus. We suggest that the ataxic deficit is caused by interruption of cerebellar outflow pathways in the thalamus and not secondary to sensory deafferentation.

(*J Neurol Neurosurg Psychiatry* 1992;55:854-856)

Ischaemic lacunar strokes occur frequently in the thalamus.^{1,2} Small haemorrhages in the thalamus may also produce lacunar strokes^{3,4} with similar clinical deficits.⁵ The lateral syndrome is the most common and has one of the best known cluster of findings of the thalamic syndromes.⁶ This syndrome and its anatomical location of the responsible lesion were first described by Dejerine and Roussy⁷ in 1906.

Reported cases of "pure" thalamic syndromes with deficits in only one or two tracts or systems deficits are rare.⁸⁻¹¹ We report two cases of lacunar thalamic stroke that produced a contralateral combination of a cerebellar deficit and proprioceptive sensory loss.

Case reports

A 63 year old right handed man was seen at the Lahey Clinic Medical Center because of the sudden onset of dysaesthesia of the right side of the face and distal right limbs and an inability to walk that lasted for one hour. Three days earlier, he had had an episode of nausea, decreased concentration, and an inability to read that lasted for a few hours. The patient has diabetes mellitus and hypertension, and he was taking tolbutamide and metoprolol. Neurological examination demonstrated dysdiadochokinesis and dysmetria with terminal tremor in the right limbs that did not worsen with closed eyes. A mild subjective decreased pain sensation was observed in the right side of the face and right hand, but touch, position, and temperature sensation were normal. Two-point discrimination and stereognosis were greatly decreased in the right hand. No weakness was noted. Stretch reflexes were hypoactive but symmetrical. Plantar reflexes were normal.

MRI of the brain showed a small lesion in the lateral posterior aspect of the left thalamus (fig 1). No source of an embolus was found. Cerebral angiography was not performed. The deficits abated in several days.

A 74 year old right handed man complained of sudden onset of inability to control the right arm and leg despite normal strength, unsteadiness, and a "frozen feeling" in the right side of the face and right hand. History included hypertension treated with methyldopa and triamterene/hydrochlorothiazide. Mild dysarthria, inconsistently decreased pain sensation, dysdiadochokinesis, and decomposition of movements in the right limbs were noted. CT of the head showed a small left lateral thalamic haemorrhage. The findings improved in a few weeks. Neurological examination at the Lahey Clinic seven months later revealed slightly decreased touch and pain sensations but normal temperature sensation and position sense with moderately diminished two-point discrimination and graphaesthesia in the right hand. Mild dysmetria, terminal tremor, and decreased finger and foot tapping ability were present on the right side. No weakness was present, and the stretch reflexes were normoactive and symmetrical. Plantar reflexes were normal. MRI of the brain performed

Department of
Neurology, Lahey
Clinic Medical Center,
Burlington,
Massachusetts
J A Gutrecht

Department of
Radiology, Brigham
and Women's Hospital,
Boston, Massachusetts
A A Zamani

Department of
Anatomy and
Neurology, Boston
University Medical
School, Boston,
Massachusetts, and
the Bedford Veterans
Administration
Hospital, Bedford,
Massachusetts, USA
D N Pandya

Correspondence to:
Dr Gutrecht, Department of
Neurology, Lahey Clinic
Medical Center, 41 Mall
Road, Burlington, MA
01805.

Received 12 September
1991
and in revised form
6 December 1991.
Accepted 18 December
1991

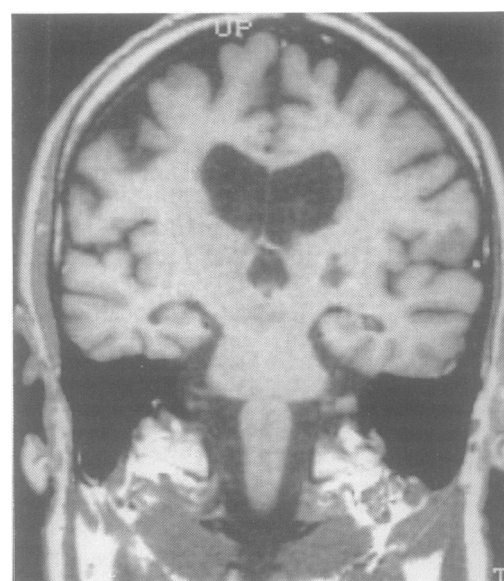
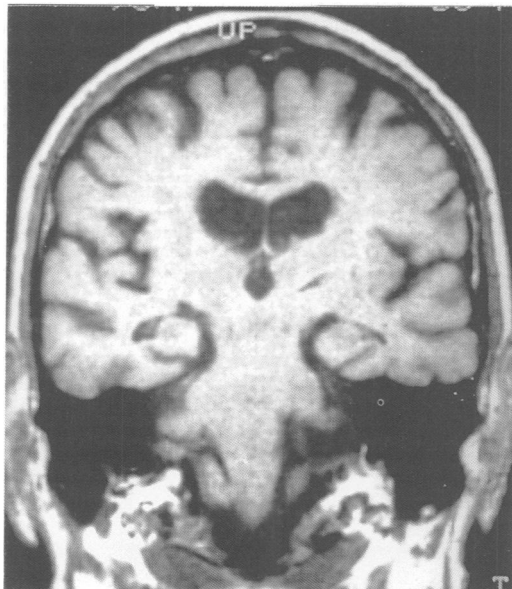


Figure 1 (Case 1). Coronal T₁-weighted (Magnetom 1.0 T; TR 0.65 s, TE 17 ms, 3 mm slice) image through posterior thalamic regions demonstrates a well-defined irregular area of low intensity in the lateral portion of the left thalamus.

Figure 2 (Case 2). Coronal T₁-weighted (Magnetom 1.0 T, TR 0.65 s, TE 20 ms, 4 mm slice) image through posterior thalamic regions demonstrates a linear area of low signal intensity in the lateral portion of the left thalamus.



almost one year later showed a lesion in the lateral posterior area of the left thalamus (fig 2).

Discussion

Thalamic ischaemic strokes frequently produce multiple symptoms and signs because of involvement of different nuclei as well as subthalamic regions that share blood supply. Small haemorrhages in these areas may produce similar symptoms.⁵ The best known and most common thalamic syndrome is the classic lateral or Dejerine-Roussy⁷ syndrome. On the other hand, well-defined "pure" thalamic syndromes are uncommon. These "pure" syndromes are characterised by involvement of one or two tracts. Isolated proprioceptive sensory loss,⁸ pure sensory deficit,⁹ ataxic hemiparesis,¹⁰ and cerebellar syndromes¹¹ have been reported.

Our two patients had deficits in the proprioceptive and more impressively, cerebellar domains. The cerebellar deficits were typical and did not worsen with closure of the eyes. Since the original description by Dejerine and Roussy,⁷ sensory deficits have been ascribed to a lesion in the ventral posterior nucleus. The origin of hemiataxia in these patients, however, has caused some argument. In 1908, Vincent¹² was the first to suggest that the cerebellar deficit was caused by involvement of cerebellar pathways in the subthalamic region as they enter the thalamus, although no pathological confirmation was available. Dejerine and Roussy,⁷ however, believed that the ataxic component in the syndrome was from the sensory deficits. In 1955, Garcin¹³ presented the case of a patient who had increasing hemiataxia while severe deficits of proprioceptive sensation in the same limbs subsided. Anatomical examination of the brain revealed a lacuna in the posterolateral region of the contralateral thalamus. He¹³ stated that the cerebellar deficits were explained by the thalamic lesion without subthalamic involvement.

Lack of causal correlation of sensory and cerebellar deficits was further suggested by the case reported by Garcin and Lapresle¹¹ in 1969. Their patient had no sensory deficits, and the lacuna found at necropsy was on the medial aspect of the contralateral thalamus. In the series of Bogousslavsky *et al*¹⁴ five of 18 patients with the lateral thalamic syndrome had severe ataxia "unrelated" to sensory deficits. Other cases of sensory deficits without ataxia have been reported,⁵ thus strongly suggesting independence of ataxic limb movement and sensory deficits. The patient described by Boiten and Lodder¹⁰ had cerebellar ataxia without sensory deficits. Sacco *et al*⁹ suggested that the limb ataxia in one patient with "pure" proprioceptive sensory loss was caused by the sensory deficits although the ataxic movements were present only in the arm and not in the leg despite sensory loss in both limbs. Recently, Dobato *et al*¹⁵ suggested that the incoordination of limb movements was caused by sensory deafferentation rather than involvement of cerebellar pathways.

Anatomical studies¹⁶ in monkeys have shown that dense input of cerebellar fibres to the contralateral thalamus exists. These fibres arise in the dentate nucleus of the cerebellum and terminate in the cell-sparse ventral posterolateral nucleus, oral division and ventral lateral nucleus, caudal division of the thalamus whereas the posterior columns medial lemniscal fibres terminate in the adjacent ventral posterolateral caudalis nucleus. These two tracts do not overlap in the thalamus. However, some overlap of cerebellar and spinothalamic fibres occurs as some of the latter terminate in the ventral posterolateral nucleus, oral division.¹⁶ It is therefore conceivable that a small lesion in the ventroposterior area of the thalamus could produce deficits in sensory or cerebellar pathways or both according to its location. The size and location of the lacunar lesion would be defined by the territory of the blood supply and size of the terminal perforating branches of the thalamo-geniculate arterial stalk or haemorrhage.

We suggest that the hemiataxia in our two patients is independent of the sensory deficits and is caused by involvement of cerebellar pathways in the thalamus. The independence of the cerebellar and proprioceptive sensation systems agrees with the known neuroanatomy and functional connections of the thalamus.¹⁷

- 1 Fisher CM. Lacunes: Small, deep cerebral infarcts. *Neurology* 1965;15:774-84.
- 2 Orgogozo JM, Bogousslavsky J. Lacunar syndromes. In: Toole JF, ed. *Handbook of clinical neurology. Vascular diseases Part II*. New York: Elsevier, 1989:235-69.
- 3 Mori E, Tabuchi M, Yamadori A. Lacunar syndrome due to intracerebral hemorrhage. *Stroke* 1985;16:454-9.
- 4 Millikan C, Futrell N. The fallacy of the lacune hypothesis. *Stroke* 1990;21:1251-7.
- 5 Kawahara N, Sato K, Muraki M, Tanaka K, Kaneko M, Uemura K. CT classification of small thalamic hemorrhages and their clinical implications. *Neurology* 1986;36:165-72.
- 6 Martin JJ. Thalamic syndromes. In: Vinken PJ, Bruyn GW, eds. *Handbook of clinical neurology*. Amsterdam: North-Holland, 1968:469-96.
- 7 Dejerine J, Roussy G. Le syndrome thalamique (1). *Rev Neurol* 1906;12:521-32.
- 8 Fisher CM. Pure sensory stroke involving face, arm, and leg. *Neurology* 1965;15:76-80.

- 9 Sacco RL, Bello JA, Traub R, Brust JCM. Selective proprioceptive loss from a thalamic lacunar stroke. *Stroke* 1987;18:1160-3.
- 10 Boiten J, Lodder J. Ataxic hemiparesis following thalamic infarction. *Stroke* 1990;21:339-40.
- 11 Garcin R, Lapresle J. Incoordination cérébelleuse du membre inférieur par lésion localisée dans la région interne du thalamus contro-latéral. *Rev Neurol* 1969;120:5-13.
- 12 Vincent C. Syndrome thalamique avec troubles cérébelleux et vaso-asymétrie. *Rev Neurol* 1908;16:553-6.
- 13 Garcin R. Syndrome cérébello-thalamique par lésion localisée du thalamus—Avec une digression sur le “signes de la main creuse” et son intérêt séméiologique. *Rev Neurol* 1955;93:143-9.
- 14 Bogousslavsky J, Regli F, Uske A. Thalamic infarcts: Clinical syndromes, etiology, and prognosis. *Neurology* 1988;38:837-48.
- 15 Dobato JL, Villanueva JA, Giménez-Roldán S. Sensory ataxic hemiparesis in thalamic hemorrhage. *Stroke* 1990;21:1749-53.
- 16 Asanuma C, Thach WT, Jones EG. Distribution of cerebellar terminations and their relation to other afferent terminations in the ventral lateral thalamic region of the monkey. *Brain Res Rev* 1983;5:237-65.
- 17 Ilinsky IA, Kultas-Ilinsky K. Sagittal cytoarchitectonic maps of the *Macaca mulatta* thalamus with a revised nomenclature of the motor-related nuclei validated by observations on their connectivity. *J Comp Neurol* 1987;262:331-64.