

## Case Reports

# Irish Brogue After Stroke

Glenn M. Seliger, MD; Gary M. Abrams, MD; and Amy Horton, MS.CCC-SLP

**Background:** We describe a patient who presented a unique variation of the previously described acquired foreign accent syndrome.

**Case Description:** A 65-year-old woman developed an Irish brogue immediately after a deep left hemisphere stroke. The newly accented speech possibly represented a previously learned speech pattern.

**Conclusions:** Suppressed prosodic speech patterns may reemerge in the setting of brain injury. (*Stroke* 1992;23:1655–1656)

**KEY WORDS** • aphasia • cerebral infarction • speech

The appearance of unlearned, accented speech after brain injury has been rarely reported.<sup>1–7</sup> To our knowledge, the emergence of a previously learned accent as a consequence of a cerebral infarction has not been observed. We recently encountered a patient whose speech was characterized by an Irish brogue immediately after a subcortical infarction of the left hemisphere. Our case suggests that accented language is a learned motor behavior and that injury to motor systems may unmask suppressed or inhibited areas of the brain involved in accented speech.

### Case Report

A 65-year-old left-handed woman developed sudden onset of slurred speech and right-side weakness. She was admitted to a hospital for diagnostic evaluation and treatment. Initial neurological examination was notable for dysarthria accompanied by a dense right hemiplegia. Computed tomography of the brain was negative, and within 48 hours her dysarthria improved markedly. Close acquaintances who visited the patient commented on the clearly discernible and newly acquired Irish brogue that characterized her speech. Natives of Ireland who were unaware of the patient's background identified her accent as characteristic of Northern Ireland, from which her mother had originated.

She was transferred to our neurorehabilitation unit 2 weeks after onset of the stroke. Significant findings on neurological examination included very mild dysarthria with a moderate Irish brogue, normal language function, and a right hemiplegia.

Detailed speech and language evaluation revealed the following salient features suggestive of an Irish brogue.<sup>8</sup> There was mild dysarthria characterized by compensatory alveolar and lingual palatal articulatory movements. Suprasegmental speech pattern was ob-

served as indicated by a gliding (four–six semitones) melodic intonation pattern, dialect-related phonemic vowel substitutions (e.g., /tudai/ /t dao/), vowel elongations (e.g., /deiz/ /daiz/), and diphthongal alternations (e.g., /how li/ /hav li/). In addition, all vowels preceding a final consonantal /r/ were changed to /a/ and were temporally elongated and stressed.

Magnetic resonance imaging of the brain showed an area of increased signal intensity on T2-weighted sequences and decreased intensity on T1-weighted sequences in the centrum semiovale extending just posterior to the waist of the left lateral ventricle (Figure 1). Three weeks after the infarction, the new accent had noticeably faded, although the patient noted that her speech pattern had not returned to baseline. At 4 months after the stroke, the Irish brogue had almost completely disappeared.

### Discussion

The patient appeared to present a new variation of the previously reported foreign accent syndrome.<sup>1–7</sup> The syndrome has been described as the development of a foreign accent, without evident exposure to the new accent, in an individual recovering from aphasia. Blumstein et al<sup>7</sup> reported the case of a patient with a stroke who retained near-normal language function but developed a “generic” foreign accent during the recovery of dysarthric speech. Careful review of the rare reports in the literature<sup>1–7</sup> would seem to confirm the nonspecificity of the newly exhibited accents and the lack of clear consensus on the prosodic origin of this phenomenon.

In contrast, while the premorbid accent of our patient was alternatively described as “Bronx” or “New York,” multiple independent observers easily identified the newly manifested accent as an Irish brogue. Our patient gave a history of extensive childhood exposure to individuals with Irish accents, although she did not explicitly recall having Irish-accented speech. However, a review of the speech and language literature suggests that very young preschool children adopt the prosodic pattern of their primary care givers.<sup>9,10</sup> We have clear documentation that the patient's mother spoke with an Irish brogue.

From the Department of Neurology, College of Physicians and Surgeons, Columbia University (G.M.S., G.M.A.), New York; and the Departments of Neurology and Speech and Audiology, Helen Hayes Hospital (G.M.S., G.M.A., A.H.), West Haverstraw, N.Y.

Address for correspondence: Glenn M. Seliger, MD, Helen Hayes Hospital, Route 9W, West Haverstraw, NY 10993.

Received May 22, 1992; final revision received June 30, 1992; accepted July 15, 1992.

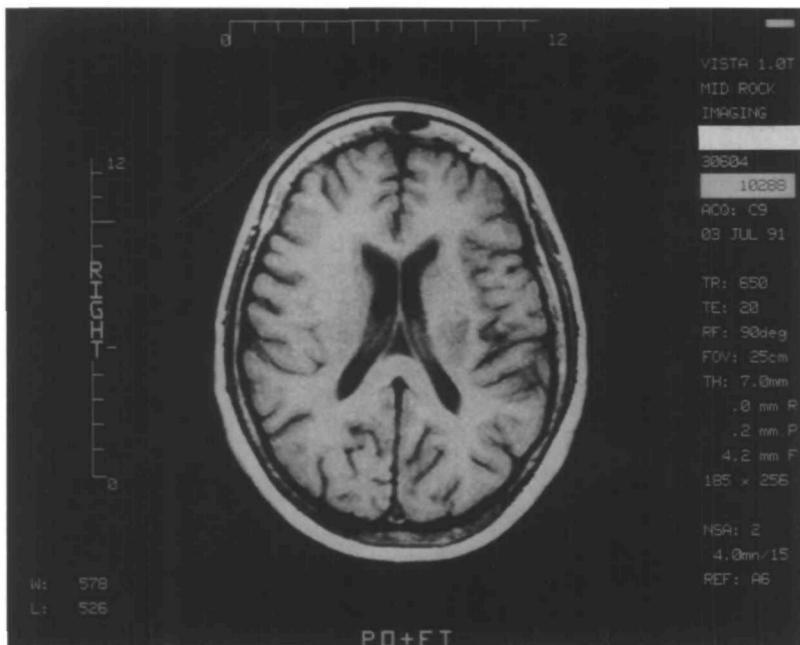


FIGURE 1. Magnetic resonance image of brain of 65-year-old woman whose speech was characterized by an Irish brogue after subcortical infarction of left hemisphere. Area of increased signal intensity in centrum semi-ovale extends just posterior to waist of left lateral ventricle.

It is interesting to speculate that this “new” accent may have represented the return of a previously suppressed prosody pattern rather than an accent acquired during the recovery process. There have been multiple theories postulated to account for neurological recovery from brain injury, e.g., sprouting, diaschisis, pairing, redundancy, functional substitution, cortical reorganization, and inefficient synapses.<sup>11</sup> Although there are multiple neurophysiological hypotheses for the observed phenomenon in our patient, we would like to speculate on two possible options.

Jenkins et al<sup>12</sup> have shown that cortical reorganization of neurosystems beginning within a few hours of injury may play a role in neurological recovery of function. The proposed mechanism for this early reorganization is unmasking of previously suppressed neural circuitry. The question arises as to whether the emergence of an accent is analogous to the unmasking phenomenon suggested by Jenkins et al. We propose that the childhood accent of our patient may have become suppressed by subsequent language development.

The reappearance of her accent during the injury and recovery process associated with cerebral infarction may represent a unique expression of hierarchical neural organization. This case is consistent with the hypothesis that suppressed neural systems that reappear with brain injury may have been functional at an earlier time in neurodevelopment.

The work of Ojemann and Whitaker,<sup>13</sup> however, suggests an alternative explanation. They have theorized that when languages are learned at different ages, their anatomic localizations in the brain may differ. If accents are acquired in a similar manner, their anatomic localizations in the brain may also be distinct and separated from other motor areas associated with language. Following this line of reasoning, it could be hypothesized that this patient’s “New York accent”

center was damaged by the stroke, and her “Irish accent” center was left relatively undamaged. The Irish accent thus reappeared in her everyday speech. With recovery, the New York accent center subsequently reestablished dominance over the Irish accent center.

#### Acknowledgment

The authors would like to thank William M. Jenkins, PhD, for his thoughtful comments on this report.

#### References

- Schiff HB, Alexander MP, Naeser MA, Galaburda AM: Aphemia: Clinical-anatomical correlations. *Arch Neurol* 1983;40:720-727
- Monrad-Krohn GH: The third element of speech prosody and its disorders, in *Problems of Dynamic Neurology*. Jerusalem, Hebrew University Press, 1963, pp 101-118
- Monrad-Krohn GH: The prosodic quality of speech and its disorders. *Acta Psychiatr Neurol Scand* 1947;22:255-269
- Monrad-Krohn GH: Dysprosody or altered “melody of language.” *Brain* 1947;70:405-415
- Monrad-Krohn GH: Altered melody of language (“dysprosody”) as an element of aphasia. *Acta Psychiatr Neurol Scand Suppl* 1947; 46:204-212
- Whitty CWM: Cortical dysarthria and dysprosody of speech. *J Neurol Neurosurg Psychiatry* 1964;27:507-510
- Blumstein SE, Alexander MP, Ryalls JH, Katz W, Dworetzky B: On the nature of the foreign accent syndrome: A case study. *Brain Lang* 1987;31:215-244
- Blunt J: *Stage Dialects*. New York, Harper & Row Publishers Inc, 1967, pp 75-90
- Nakazima S: A comparative study of the speech developments of Japanese and American English in childhood. *Stud Phonol* 1962; 2:27-39
- de Villiers P, de Villiers J: *Language Acquisition*. Cambridge, Mass, Harvard University Press, 1978, pp 6-53
- Lawrence S, Stein DG: Concepts in recovery, in Finger S (ed): *Recovery from Brain Damage: Research and Theory*. New York, Plenum Press, 1987, p 369
- Jenkins WM, Merzenich MM, Recanzone G: Neocortical representational dynamics in adult primates: Implications for neuropsychology. *Neuropsychologia* 1990;28:573-584
- Ojemann GA, Whitaker HA: The bilingual brain. *Arch Neurol* 1978;35:409-412