

involve partial trisomy [4], deletion with pericentric inversion [5], reciprocal translocation [6], and ring chromosome [7, 8]. The incidence of epileptic seizures in patients with ring 14 chromosome is reported to be 100% [3]. Seizures in patients with chromosomal abnormalities tend to be considered as primary generalized ones, and the seizures described in the literature are mainly of the primary generalized type including the ones in patients with ring 14 chromosome [7, 9]. However, Lippe and Sparkes noted that seizures might also be associated with focal cerebral atrophy in ring 14 chromosome patients [8]; in addition, some patients actually exhibited partial onset seizures [8, 10] and unbalanced developmental subnormality [7, 9] indicating the presence of a focal disturbance in the CNS. Thus, in ring 14 chromosome patients, focal CNS disturbances can be present.

In our patient, complex partial seizures were diagnosed on the basis of EEG findings and clinical manifestations, and the CPS were considered to be a symptom of the focal lesions in the CNS. There remains the possibility that her seizures were caused not only by genetic factors, but by some disturbances during pregnancy, however, it is likely that the genetic defect does enhance the appearance of CPS. Reviewing the reports of 25 patients with ring 14 chromosome, our case report is the first one involving a patient with ring 14 chromosome and CPS and shows that focal CNS lesions can also occur in ring 14 chromosome patients.

## REFERENCES

1. Doose H, Baier W. Genetic aspects of childhood epilepsy. *Clev Clin J Med* 1989;56(suppl 1):S105-10.
2. Delgado-Escueta AV, Greenberg D. The search for epilepsies ideal for clinical and molecular genetic studies. *Ann Neurol* 1984;16(suppl):S1-11.
3. Ieshima A, Takeshita K. Chromosome abnormalities and epileptic seizures. *Jpn J Human Genet (Tokyo)* 1988;33:49-60.
4. Smith A, Dulk GD, Elliott G. A severely retarded 18-year-old boy with tertiary partial trisomy 14. *J Med Genet* 1980;17:230-2.
5. Nielsen J, Homma A, Rasmussen K, Ried E, Sorensen K, Saldana-Garcia P. Deletion 14q and pericentric inversion 14. *J Med Genet* 1978;15:236-8.
6. Hattori H, Hayashi K, Okuno T, et al. De novo reciprocal translocation t(6;14) (q27;q13,3) in a child with infantile spasms. *Epilepsia* 1985;26:310-3.
7. Howard PJ, Clark D, Dearlove J. Retinal/macular pigmentation in conjunction with ring 14 chromosome. *Hum Genet* 1988;80:140-2.
8. Lippe BM, Sparkes RS. Ring 14 chromosome: association with seizures. *Am J Med Genet* 1981;9:301-5.
9. Abe T, Misawa S, Nishioka K, Okuno T, Nakagome Y. Formation of a ring chromosome 14 subsequent to the de novo 13/14 reciprocal translocation: a new cytogenetic evidence obtained by the nucleolus-organizer staining. *Ann Genet* 1978;21:109-12.
10. Amarose AP, Dorus E, Huttenlocher PR, Cszasz S. A ring 14 chromosome with deleted short arm. *Hum Genet* 1980;54:145-7.

# **Cortical Reflex Myoclonus Associated with Mitochondrial Myopathy, Encephalopathy, Lactic Acidosis and Stroke-like Episodes (MELAS): A Case Report**

**Shinji Saitoh, MD, Shinobu Kohsaka, MD, Susumu Mizukami, MD,  
and Naofumi Kajii, MD**

---

*A 9-year-old female MELAS patient with myoclonus is reported, with emphasis on the results of electrophysiological studies of the myoclonus. At age 5 years she experienced a stroke-like episode, and a diagnosis of MELAS was made at age 6 years on the basis of muscle biopsy findings. At age 9 years spontaneous and segmental myoclonus, predominantly affecting the upper extremities, developed because of complications. Electrophysiological examination, including of somatosensory-evoked potentials (SEPs) and averaged EMG for long loop reflexes, revealed the so-called "giant SEP" and enhanced long loop reflexes reflecting cortical hyperexcitability. Jerk-locked averaging yielded no myoclonus related*

spikes, but myoclonus-contingent 4-5 Hz theta bursts appeared. These findings suggest that some types of MELAS may be associated with cortical types of myoclonus. **Key words:** MELAS, cortical reflex myoclonus, giant SEP, jerk-locked averaging, C-reflex.

Saitoh S, Kohsaka S, Mizukami S, Kajii N.  
Cortical reflex myoclonus associated with mitochondrial myopathy, encephalopathy,  
lactic acidosis and stroke-like episodes (MELAS): a case report.  
*Brain Dev* 1992; 14: 260-3

Mitochondrial encephalomyopathy is present in several syndromes, which can be mainly subdivided into three major ones: Kearns-Sayre syndrome (KSS), myoclonus epilepsy with ragged-red fibers (MERRF), and mitochondrial myopathy, encephalopathy, lactic acidosis and stroke-like episodes (MELAS) [1]. It is well known that several intermediate forms also exist [2]. Besides these three major syndromes, there are other mitochondrial encephalomyopathies, such as subacute necrotizing encephalomyelopathy, Alper's syndrome and trichopoliodystrophy. Myoclonus is one of the major manifestations of MERRF, but it is not usually associated with either MELAS or KSS. Hence, the nature of the myoclonus in MELAS has remained unclear.

In this paper, we report a 9-year-old female MELAS patient with myoclonus. On the basis of electrophysiological findings, the myoclonus was deduced to be of cortical origin.

### CASE REPORT

A Japanese girl was born to healthy and unrelated parents after a normal pregnancy and delivery at term. She first experienced loss of consciousness, vomiting and a generalized tonic clonic convulsion at age 5 years. At that time, no other manifestations were noted except for a short stature (-2.2 SD). The patient had no siblings and no family history of neuromuscular disease. Because of the recurrence of similar episodes twice within one year, she was hospitalized for further examination. Laboratory studies showed increased serum transaminase and creatine kinase levels, hyperlactatemia and metabolic acidosis. A CT scan revealed multiple, asymmetric low-density areas in the occipital, parietal and temporal lobes bilaterally. On MRI, these lesions exhibited low-intensity

in T1-weighted images and high-intensity in T2 weighted images. These neuroradiographic findings indicated multiple cerebral infarctions. A biopsy of the right quadriceps femoris muscle was performed at age 6 years. Modified Gomori trichrome staining revealed 40-50% ragged-red fibers. Biochemical studies on the muscle revealed a reduction in cytochrome *c* oxidase activity to 63.2 nmol/min/mg mitochondrial protein (normal mean  $\pm$  SD: 270  $\pm$  133.0). Other mitochondrial respiratory enzyme activities were within normal limits. Based on these findings, a diagnosis of MELAS was made. Treatment with co-enzyme Q (70 mg/day) and dichloroacetate (350 mg/day), however, failed to prevent the recurrence of the stroke-like episodes, and the patient's condition gradually deteriorated in association with complex partial seizures.

At age 9 years the existence of spontaneous myoclonus, predominantly affecting the upper extremities, but also involving the face, trunk and lower extremities, was first noted. The myoclonus did not increase with voluntary movement and almost completely disappeared during sleep. Because of the development of myoclonus, the patient was again hospitalized and electrophysiological studies were performed. On admission, physical examination revealed generalized mild muscle atrophy, proximal dominant muscle weakness and a positive Gowers' sign. The patient could walk without support, but unsteadily. Neither ataxia nor extrapyramidal signs were present. Deep tendon reflexes were normal and no pathological reflexes could be elicited, however, there was associated mild flexion contracture of the right ankle joint. The IQ was 49 (the Tanaka-Binet test). An EEG showed marked slowing of the background activity (3.5-4 Hz theta range), predominantly recorded in the parieto-occipital region, but no paroxysmal discharges were detected.

### METHODS

Somatosensory-evoked potentials (SEPs) were recorded from C3 with the reference electrode at A1 and stimulation of the right median nerve at the wrist joint, with an intensity of 10% above the threshold, while the patient was awake in the resting state (no of responses averaged: 200; band-pass filter: 15-1,500 Hz; signal processor, model 7S12, San-Ei Co, Ltd, Japan). A surface EMG was

From the Department of Pediatrics, Hokkaido University School of Medicine, Sapporo.

Received for publication: March 20, 1991.

Accepted for publication: April 26, 1992.

Correspondence address: Dr. Shinji Saitoh, Department of Pediatrics, Hokkaido University School of Medicine, N15-W7, Kita-ku, Sapporo 060, Japan.

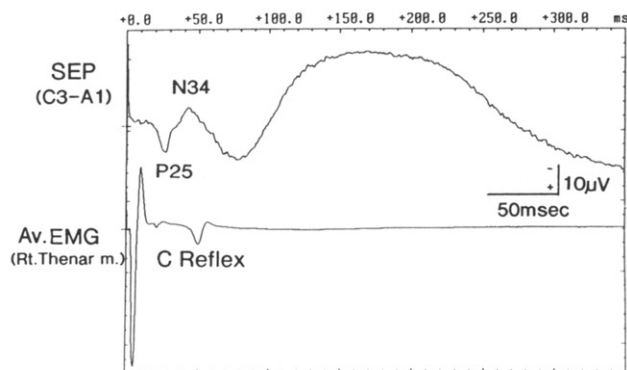


Fig 1 SEPs and averaged EMG from the right thenar muscle following right median nerve stimulation ( $n = 200$ ). Note the large amplitudes of the P25 and N34 components at the C3 electrode, and the presence of the C-reflex.

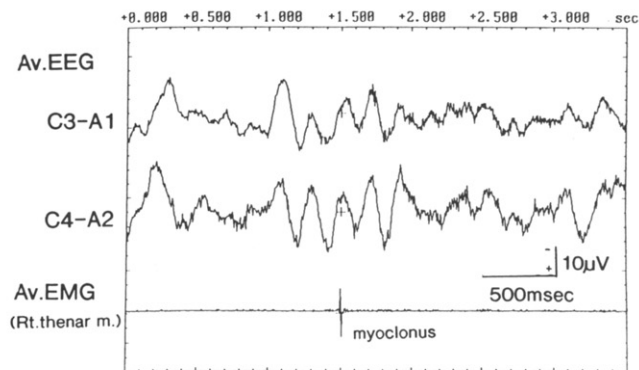


Fig 2 Jerk-locked averaging ( $n = 50$ ) of myoclonus of the right thenar muscle as a trigger. Note the 4-5 Hz theta bursts at the C3 and C4 electrodes.

simultaneously recorded from the right thenar muscle.

Two-channel EEGs (C3 with reference to A1, and C4 with reference to A2) and 1-channel surface EMGs (right thenar muscle) were recorded using an electroencephalograph (band-pass filter: 15-200 Hz; model 1A94, San-Ei Co, Ltd, Japan) and stored on magnetic tape. Jerk-locked averaging was performed with a 1-channel EMG as a trigger while reproducing and digitalizing these data (no of responses averaged: 50; sampling clock: 2 msec; personal computer model PC98XL, NEC Co, Ltd, Japan). EMG potentials longer than 100 msec were ignored.

## RESULTS

The amplitude of P25-N34, regarded as the initial segment of cortically generated SEPs, was  $16.4 \mu\text{V}$ , which was significantly enhanced (control range,  $4.5 \pm 3.8 \mu\text{V}$  (27 subjects examined)). The peak latency of the second negative component of SEPs, so-called N55, was significantly prolonged, and the later components of SEPs were not discernible, being replaced by a negatively-deflected, dome-shaped prolonged potential (Fig 1). The averaged EMG from right thenar muscle following electrical stimulation of the right median nerve revealed an enhanced long-latency potential. The latency of the long-latency potential observed on the stimulation was 47 msec, and the duration from P25 of SEPs to the long-latency potential was 20.4 msec (Fig 1).

Jerk-locked averaging revealed no myoclonus-related spikes, but 4-5 Hz theta bursts appeared at both C3 and C4 (Fig 2). These theta bursts were not observed upon random averaging.

## DISCUSSION

Myoclonus is a major symptom of MERRF, but it is usually not associated with MELAS. Until now, only a few evoked potential studies have been reported on mitochon-

drial encephalopathies including MERRF [3], therefore, the precise mechanism underlying myoclonus associated with mitochondrial encephalopathies has remained unclear. So et al [4] reported five MERRF patients with "giant SEPs," and assumed that the cortex plays an important role in the pathogenesis of myoclonus in MERRF, although it is still uncertain whether the mechanism underlying myoclonus associated with other mitochondrial encephalopathies, such as MELAS, is the same as that in the case of MERRF.

In this case, the significantly enhanced amplitude and the prolonged latency of the cortically generated SEPs are consistent with the characteristics of the so-called "giant SEP," most commonly associated with progressive myoclonus epilepsy [5]. Although the precise pathophysiological basis of the "giant SEP" has not been elucidated in detail, there is a general agreement that these characteristics reflect a state of abnormal excitability, with enhancement of the cortical reflex pathway [6]. The definition of "giant SEP" is controversial, particularly in childhood. In the case of adult patients, Shibasaki et al reported that a "giant SEP" comprises a P1-N2 amplitude of more than  $8.4 \mu\text{V}$  [7], and Obeso et al proposed  $7 \mu\text{V}$  as the threshold [5]. For childhood patients, the definition of a "giant SEP" has not yet been established. According to our experience with 27 control epilepsy patients aged from 1 to 18 years (mean  $\pm$  SD:  $8.0 \pm 5.1$ ), the average and SD of the P25-N34 amplitude were  $4.5 \mu\text{V}$  and  $3.8 \mu\text{V}$ , respectively. Other than the high amplitudes of early cortical segments of SEPs, the changes in later segments of SEPs are common to "giant SEPs." In "giant SEPs," the later cortical segments are usually difficult to recognize, being replaced by high voltage slow waves [8]. The patterns of later cortical segments in the present patient were similar to these patterns. Therefore, we think that the SEPs in this patient have sufficient characteristics of a "giant SEPs" and thus indicates cortical hyperexcitability.

The averaged EMG, recorded simultaneously with the SEPs, revealed an enhanced long-latency potential. This latency characteristics, which is believed to reflect passage through the cortical reflex pathway, implies that this potential is identical to the C-reflex described by Sutton and Mayer [9], who advocated that the C-reflex represents cortical hyperexcitability. On the basis of these findings, we concluded that the myoclonus in this patient was caused by cortical hyperexcitability and thus consistent with the cortical reflex myoclonus described by Hallett et al [10].

Shibasaki et al [11] described the myoclonus-contingent spikes on the basis of jerk-locked averaging in patients with cortical reflex myoclonus. We also performed jerk-locked averaging in the present MELAS patient and found that a theta burst was closely related to the myoclonus instead of a spike. Considering the fact that patients with cortical reflex myoclonus do not always exhibit myoclonus-related cortical spikes [11], the early examination of this patient's myoclonus might be one explanation for the unusual myoclonus-related cortical activity observed.

#### ACKNOWLEDGMENTS

The authors are grateful to Prof. Shuzo Matsumoto, Department of Pediatrics, Hokkaido University School of Medicine, for reviewing the paper.

#### REFERENCES

1. Di Mauro S, Bonilla E, Zeviani M, Nakagawa M, De Vivo DC.

Mitochondrial myopathies. *Ann Neurol* 1985;17:521-38.

2. Byrne E, Trounce I, Dennett X, Gilligan B, Morley JB, Marzuki S. Progression from MERRF to MELAS phenotype in a patient with combined respiratory complex 1 and 4 deficiencies. *J Neurol Sci* 1988;88:327-37.
3. Tsuji S, Uozumi T, Nakano S, Ohnishi A, Murai Y. Evoked potential studies in mitochondrial encephalomyopathy. *Arch Neurol* 1990;47:465-7.
4. So N, Berkovic S, Andermann F, Kuzniecky R, Gendron D, Quesney LF. Myoclonus epilepsy and ragged-red fibers (MERRF). 2. Electrophysiological studies and comparison with other progressive myoclonus epilepsies. *Brain* 1989; 112:1261-76.
5. Obeso JA, Rothwell JC, Marsden CD. Somatosensory evoked potentials in myoclonus. In: Fahn S, Marsden CD, Van Woert MH, eds. *Myoclonus. Advances in Neurology*, Vol 43. New York: Raven Press, 1986:373-84.
6. Kakigi R, Shibasaki H. Generator mechanisms of giant somatosensory evoked potentials in cortical reflex myoclonus. *Brain* 1987;110:1359-73.
7. Shibasaki H, Yamashita Y, Kuroiwa Y. Electroencephalographic studies of myoclonus. *Brain* 1978;101:447-60.
8. Yoshikawa H, Suzuki H, Kaga M, Sekuragawa N. Giant somatosensory evoked potentials in Rett syndrome (in Japanese). *No To Hattatsu (Tokyo)* 1990;22:186-8.
9. Sutton GG, Mayer RF. Focal reflex myoclonus. *J Neurol Neurosurg Psychiatry* 1974;37:207-17.
10. Hallett M, Chadwick D, Marsden CD. Cortical reflex myoclonus. *Neurology* 1979;29:1107-25.
11. Shibasaki H, Yamashita Y, Tobimatsu S, Neshige R. Electroencephalographic correlates of myoclonus. In: Fahn S, Marsden CD, Van Woert MH, eds. *Myoclonus. Advances in Neurology*, Vol 43. New York: Raven Press, 1986:357-72.

## Cerebral Aneurysms in Children

Masanori Ito, MD, Masaaki Yoshihara, MD, Minoru Ishii, MD,  
Akihiko Wachi, MD and Kiyoshi Sato, MD

---

*Childhood intracranial saccular aneurysms are rare, accounting for only 0.6–4.6% of all aneurysms. This paper presents two such cases. A 12-year-old boy developed sudden severe headaches. CT indicated subarachnoid hemorrhage in the bilateral sylvian fissure. Angiography failed to demonstrate any vascular lesions. Repeat angiography, however, revealed a 2 mm aneurysm on the right A-1. A miniclip was successfully applied to obliterate the aneurysm. The postoperative course was uneventful. In the second case, a 3-year-old boy, CT incidentally revealed a bullet-shaped high density area. Angiography demonstrated a large aneurysm arising from the insular portion of the prefrontal branch of middle cerebral artery. This large aneurysm with a broad-based neck was successfully clipped, employing the angioplastic and/or tandem clipping, despite the fact the prefrontal artery unfortunately was compromised in postoperative angiography. The patient was doing well postoperatively. Spontaneous subarachnoid hemorrhage (SAH) in childhood is uncommon. However, when children with SAH is encountered, angiography should be performed repeatedly even if the first angiogram does not demonstrate any vascular abnormality. Childhood aneurysms are increasingly being found incidentally in CT scans. The differences between child and adult aneurysms in regard to site, size, sex predominance, clinical features, and sur-*