

# Bilateral Cortical Blindness: An Unusual Presentation of Bacterial Endocarditis

From the Emergency Medicine Residency Program, Department of Emergency Medicine, Sparrow Hospital, Lansing, Michigan.

Received for publication March 9, 1992. Accepted for publication May 7, 1992.

**Daryl Lawrence-Friedl, DO**  
**Kathleen M Bauer, MD, FACEP**

We report the case of a 37-year-old woman who presented to the emergency department with the initial complaint of complete blindness. The patient was found to have bilateral ruptured occipital mycotic aneurysms as a sequela of bacterial endocarditis. This case is unique in several aspects. Although blindness may be a presenting neurologic symptom, it is exceedingly rare. To our knowledge, bilateral cortical blindness secondary to mycotic aneurysm rupture has not been reported previously.

[Lawrence-Friedl D, Bauer KM: Bilateral cortical blindness: An unusual presentation of bacterial endocarditis. *Ann Emerg Med* December 1992;21:1502-1504.]

## INTRODUCTION

Endocarditis is an insidious disease, characterized by a highly variable presentation. William Osler in the late 1800s first characterized the disease by the symptoms of fever, prostration, and a loud to-and-fro heart murmur.<sup>1</sup> Two primary forms of endocarditis are now recognized. Acute bacterial endocarditis generally occurs on previously healthy valves and represents invasion by highly virulent microorganisms such as *Staphylococcus aureus*.<sup>2</sup> The chronic form usually occurs on previously damaged valves and can be more insidious. Organisms from a variety of sources may enter the vascular compartment and seed on cardiac valves. Intracranial hemorrhage is thought to result from either bleeding secondary to septic embolization of blood vessels or from rupture of mycotic aneurysms. IV drug abuse has been recognized as a predisposing factor contributing to the development of endocarditis.

Although neurologic complications are infrequent as initial presenting complaints, when present they are severe and debilitating. The resultant morbidity and mortality in such patients are high. Neurologic sequelae of bacterial endocarditis may present with involvement of any of the cranial nerves, hemiplegia, or cortical blindness, as was seen in our patient. Vigorous treatment of these patients should begin as early as possible, preferably in the emergency department if morbidity and mortality are to be held to a minimum.

## CASE REPORT

A 37-year-old woman presented to the ED with the chief complaint of complete blindness that morning. The patient's vision had begun to deteriorate a few days before, progressing to where she was able to perceive only light and gross movement. She had a two- to three-day history of frontal and occipital headache, dizziness, difficulty in walking, and fever. Further history revealed generalized myalgias, fatigue, and arthralgias developing over the previous week. In addition, the patient had sharp retrosternal chest pain of unknown duration. She denied a history of recent head trauma, hypertension, migraine headaches, or cerebrovascular disease. Her medical history revealed a ten-year history of IV drug abuse, anemia, valvular heart disease, hepatitis B, and a recent negative HIV test. The patient was taking no prescription medications and had drug allergies to meperidine and sulfa.

Physical examination revealed a cachectic, lethargic woman who appeared older than her stated age. Vital signs were oral temperature, 38.1 C; blood pressure, 110/60 mm Hg; pulse, 90; respirations, 16. The head was atraumatic and sinuses were nontender. Pupils were 1 to 2 mm, equal, and reactive to light. Red reflexes were present bilaterally, and there were no corneal opacities or papilledema. There were no scleral or conjunctival hemorrhages, exudates, or injection. There was no nystagmus or ptosis, and the extraocular movements were intact. The remainder of the ear, nose, and throat examination was unremarkable.

The neck was slightly rigid, with anterior lymphadenopathy and no carotid bruits. Lung fields were clear. Cardiac examination revealed a regular rate and rhythm, with a grade III/VI diastolic murmur over the right aortic area. The abdomen revealed mild hepatosplenomegaly. The extremities had multiple IV "track" marks, as well as a nodule on the dorsum of the left hand. Splinter hemorrhages were present in the nailbeds. The joints were diffusely tender without swelling or erythema. Neurologic examination revealed the absence of light perception in either eye. The remainder of the cranial nerves were intact. There was full range of motion of all the extremities, with decreased strength bilaterally. Deep tendon reflexes were II/IV in the upper and lower extremities. Babinski's sign was absent. The patient had hypesthesia to light touch in all extremities. Finger-to-nose coordination was not intact. Romberg was not tested.

CBC revealed a WBC of 2,300 with 67% segments and 18% bands. Hemoglobin was 11.3 g, and hematocrit was 33.8%. Sodium was 127 mmol/L; chloride, 93 mmol/L; potassium, 3.3 mmol/L; bicarbonate, 25 mmol/L; and pH 7.27. Coagulation studies, disseminated intravascular coagulation profile, hepatic enzymes, and amylase were normal. ECG revealed a normal sinus rhythm. Chest radiograph was within normal limits. Computed tomography of the brain revealed bilateral occipital hemorrhages without evidence of cerebral edema or midline shift (Figure 1). We

thought the hemorrhages were secondary to ruptured mycotic (infectious) aneurysms and admitted the patient to the hospital, beginning antibiotic therapy with vancomycin, gentamicin, and ceftazidime. We also treated with dexamethasone and phenytoin. Blood cultures were positive for *S aureus*, sensitive to nafcillin. The patient had a brief period of clinical improvement, manifesting increased responsiveness and return of light perception. However, a sudden deterioration occurred, probably caused by a third bleeding aneurysm, which caused brain herniation and death (Figure 2).

## DISCUSSION

The significance of nervous system complications of bacterial endocarditis dates from 1885 when Osler first emphasized the clinical importance of the triad of fever, heart murmur, and hemiplegia.<sup>1</sup> The incidence of neurologic complications in patients with bacterial endocarditis is approximately 30% to 40%.<sup>1,3,4</sup> It is also unusual for a patient with bacterial endocarditis to have neurologic complaints as a presenting symptom. In a recent review of 218 patients with bacterial endocarditis, only 36 presented with a neurologic complaint as their initial symptom, and only one of these presented with cortical blindness (unilateral).<sup>1</sup>

Central nervous system complications of bacterial endocarditis carry a mortality of approximately 50% to 60%.<sup>1</sup> The most common organism underlying symptomatic intracranial hemorrhage is *Staphylococcus aureus*.<sup>5</sup> Virulent organisms, especially *S aureus* and enteric Gram-negative bacilli, are particularly common among patients with neurologic complications. These virulent organisms are the etiologic agent in a high percentage of IV drug abusers with bacterial endocarditis.<sup>6</sup> Cerebral mycotic aneurysms are present in 2% to 10% of cases of bacterial endocarditis.<sup>3,7,8</sup>

Figure 1.

Computed tomography of the brain demonstrating bilateral occipital hemorrhages

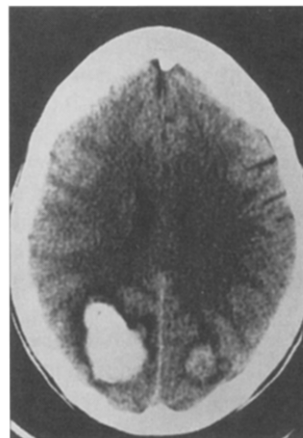
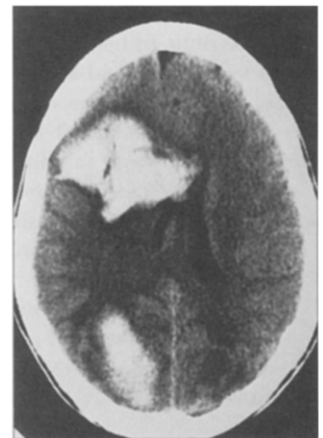


Figure 2.

Computed tomography of the brain demonstrating a third hemorrhage



---

There are presently two theories of the pathogenesis of cerebral mycotic aneurysms<sup>1</sup>: a septic cerebral embolus results in inflammatory destruction of the arterial wall beginning at the endothelial surface; and infected embolic material reaches the adventitial layers of the artery through the vasa vasorum, with inflammation disrupting the adventitia and muscularis, thus resulting in aneurysmal dilatation. Recent work by Molinari supports the second theory.<sup>1,9</sup>

---

**SUMMARY**

We discuss the case of a patient who presented to the ED with a chief complaint of sudden loss of vision. The blindness was secondary to bilateral ruptured mycotic aneurysms developing as a sequela of bacterial endocarditis. Neurologic complications may present as manifestations of bacterial endocarditis. When these complications are present, they result in a significant increase in morbidity and mortality.

**REFERENCES**

1. Bohmfalk GL, Story JL, Wissinger JP, et al: Bacterial intracranial aneurysm. *J Neurosurg* 1978;48:369-382.
2. Pankey GA: Infective endocarditis: Changing concepts. *Hosp Pract* 1986;103-110.
3. Dean RH, Waterhouse G, Megacham PW, et al: Mycotic embolism and embolomycotic aneurysm, neglected lessons of the past. *Ann Surg* 1986;204:300-307.
4. Lerner PI: Neurologic complications of infective endocarditis. *Med Clin North Am* 1985;69:385-397.
5. Pruitt AA, Rubin RH, Karchmer AW, et al: Neurologic complications of bacterial endocarditis. *Medicine* 1978;57:329-342.
6. Weinstein L: Life threatening complications of infective endocarditis and their management. *Arch Intern Med* 1986;146:953-957.
7. Hart RG, Kagen-Hallet K, Joerns SE: Mechanisms of intracranial hemorrhage in infective endocarditis. *Stroke* 1987;18:1048-1057.
8. Leipzig TJ, Brown F: Treatment of mycotic aneurysms. *Surg Neurol* 1985;23:403-407.
9. Molinari GF, Smith L, Goldstein MN, et al: Pathogenesis of cerebral mycotic aneurysms. *Neurology* 1973;23:325-332.

## Address for reprints:

Kathleen M Bauer, MD, FACEP  
Sparrow Hospital  
Emergency Department  
1215 East Michigan Avenue  
Lansing, Michigan 48909