

ICTAL BEHAVIOR DISTURBANCE AS THE ONLY MANIFESTATION OF SEIZURE DISORDER: CASE REPORT

ROBERT JAFFE, M.D.¹

There is a certain group of patients in whom convulsive disorder is present, but who may show manifestations limited to the sphere of mental function. The manifestations are characteristically episodic, but the duration of the episodes may vary from minutes to days. The degree and nature of the disturbance in thinking and general behavior is also extremely variable (10). At times the epileptic origin of the behavior disturbance is not immediately apparent, and electroencephalographic evidence, as well as clinical observation, is necessary that proper diagnosis and treatment may be achieved.

The patient reported here was a 75-year-old woman who was first seen by one of the consulting psychiatrists of the Home for the Aged and Infirm Hebrews when she was referred for psychiatric evaluation, prior to her admission to the Home, because of "episodes of memory loss" which had been reported by her family physician. After reviewing her social history and personal history, his report goes as follows: "Patient remained in the family all her life, took care of various sick members of her family and always felt that she was being a good person and thereby worthy of love herself because of this devotion. She now feels that she has done her duty and would like to be taken care of as a reward in the family here at the Home. She is in good health and denies any major emotional symptoms. She tends to be somewhat tense and excitable, with very

mild mood lability. The most striking pathological manifestation involves her 'spells.' These have occurred on the average of once every year or two and have lasted for periods ranging from a few hours to a day or two. She describes these spells as a reaction to feeling that she cannot take any more. For example, when her sick sister and sister-in-law would demand constant attention from her all day and all night and she would become increasingly tense and fatigued, things would finally come to a climax in a spell in which she would just go to bed and withdraw from everybody and everything. During these periods she pays no attention to people although she is aware of everything that is going on around her, no longer feels driven to do things, is no longer anxious, has no feelings at all. There is no memory loss during these periods, or disturbances of the level of consciousness. She has never acted in any disturbed or bizarre fashion during these periods and comes out of these without treatment.

"Diagnosis: Passive-dependent personality. The patient's "spells" certainly do not sound organic. I would characterize them as an emergency response to increased anxiety by a transient period of regressive withdrawal".

¹Department of Psychiatry and Neurology, The Home for Aged and Infirm Hebrews of New York, 121 West 105th Street, New York, N. Y. The author wishes to express appreciation to Frederic D. Zeman, M.D., Chief of Medical Services, and to Alvin I. Goldfarb, M.D., Chief of Department of Psychiatry and Neurology at The Home for Aged and Infirm Hebrews of New York, for their assistance and cooperation.

Two months later the writer first saw the patient when she was referred for neurologic examination because of an episode of altered responsivity which had occurred five days earlier. This episode was said to have occurred following the receipt of the news of the death of her sister-in-law. The patient stated that this was one of her usual "black-outs." The only unusual feature was that it had lasted only a few hours, instead of its usual duration of one to two days. She denied having lost consciousness, stating

that she had been aware of her surroundings at all times, but that she was unable to initiate any activity, or to speak. The incident had occurred in the morning, apparently beginning after she had dressed for the day's activities. Her roommate noticed that she stopped speaking and moving about, and called the doctor. The staff doctor stated that the patient had been able to walk and move normally, but did not speak or respond to questions. Upon being fed, she proceeded to feed herself, but "seemed to be doing it automatically."

Upon questioning as to whether she had ever actually lost consciousness, the patient stated that she had done so on rare occasions. On one occasion during a "blackout" she fell out of her bed and injured her right shoulder.

A detailed review of her history revealed that she had had her first attack approximately 30 years earlier. She specifically recalled that this had occurred on washday, and that she had been preparing the wash. She knew that she had behaved in an irrational manner, since she had mixed the white and colored clothes together. At that time she lost consciousness and fell to the floor. She stated that she did not injure herself, and was not seen to have any convulsive movements. Her relatives picked her up and put her to bed, and she recovered consciousness in a few hours. Following this she had spells quite frequently, as often as once or twice a week. This condition persisted for a few months, following which the spells became less and less frequent. They ultimately decreased to an incidence of one every year or two. When these spells were occurring rarely, they were often associated with emotional crises.

Additional information was obtained from one of the members of the staff of the Home, who had been the patient's next-door neighbor for many years. This staff member stated that the patient invariably had one of her attacks following the receipt of either very good or very bad news. The family

distinctly made this association, and had instructed this neighbor in how to handle the attacks if they occurred. The patient was said to invariably be found in a dazed and relatively unresponsive condition, but usually would be able to feed herself and respond to some degree. This dazed condition sometimes lasted as many as four to six days.

At the time of this examination the patient's mental status was normal, and the neurological examination was entirely negative.

On November 23, 1959, an EEG was performed, and revealed definite abnormalities. There were diffuse delta bursts, strongly accentuated in the left fronto-temporal region, and left fronto-temporal focal spike activity.

The patient was given phenobarbital 15 mg., and diphenylhydantoin 0.1 gm. t.i.d. She continued to have episodes of a similar nature, at irregular intervals.

On January 10, 1960, the patient was invited to go downtown for lunch and to the theatre on January 13th. This was an unusual and exciting event in her life. At 7:00 A.M. of January 12, she was found in her room in an unresponsive state. When first seen by the staff physician she turned her head in response to a greeting, but did not speak or obey commands. She did not feed herself, or chew food put in her mouth.

She was brought to the 105th St. branch of the Home, from Kingsbridge House in the Bronx, by ambulance. When first seen in the EEG laboratory at 10:00 A.M., she was lying quietly on a stretcher, with her eyes open. There was no response to questions or commands. She did not respond to the application of needle electrodes.

By 11:50 A.M., she still kept her eyes open but responded to some simple commands. She did not know right and left. Upon being asked her own name she stated, "I don't know." There was complete extinction of hand stimuli, on the Face-Hand test (3).

EEG recording performed between 10:30

and 11:50 showed diffuse bilateral spike-wave activity, with slow waves at a frequency of $1\frac{1}{2}$ to 2 cps. The spike activity was generally bisynchronous but showed higher voltage on the left side in frontal and anterior temporal leads, and a fairly consistent presence of double spikes and multiple spikes in the same leads (Figure 1A).

At 12 o'clock an intravenous injection of 5 per cent amobarbital sodium was started. After 150 mg. had been given, the EEG showed almost complete absence of the bisynchronous spike and spike-wave activity, but persistence of high-voltage spikes at the left frontal electrode, with synchronous low voltage spikes at the left anterior temporal

electrode. At this point she gave her name in answer to questioning.

By twelve minutes after twelve, 250 mg. of amytal had been given, and the patient was very drowsy, had nystagmus and dysarthria. With arousal she gave her name, and said she was at "1738 Andrews Ave" (her prior home address). At this time the EEG showed minimal diffuse slowing, consistent with her drowsy state, and low voltage spikes in the left frontal lead (Figure 1B, C).

By 12:16 the spike activity had again become diffuse and bisynchronous, with progressively increasing amplitude, until 12:36 (Figure 1D, E). At this time she

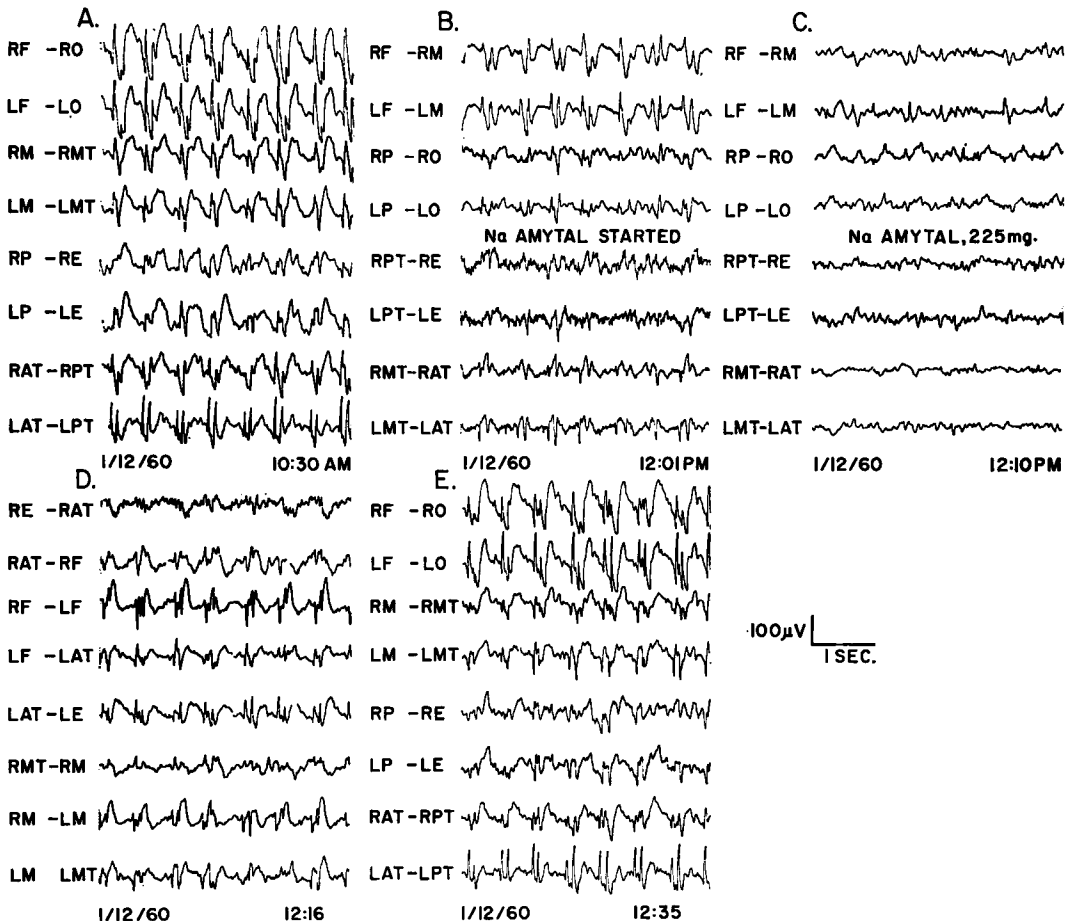


FIG. 1. Tracings performed on first day of seizure, showing changes induced by intravenous administration of amobarbital sodium.

was in about the same mental state as prior to the barbiturate injection. She denied knowing her name, confused right and left, but obeyed some simple commands. She was also able to identify simple objects.

The patient was then sent to a room, where she slept for a few hours, and then was able to eat a meal.

On examination at 10:00 A.M. of January 13 she was much more alert, spoke slowly, but more rapidly than on the previous day. She knew that she was in an attack, said that it had started "yesterday morning." On this day she greeted the writer by name, said that she recalled having come in an ambulance, recalled having seen me on the previous day but did not recognize me or know my name. She recalled on this morning that she had been planning to go out for lunch and to the theatre.

On examination of the mental status, she showed some delay in identifying the location. She was oriented for month and year, but not for day and date. She knew right and left, crossed the midline on command. She was unable to perform serial subtraction of 7s, showed skipping and reversals on serial subtraction of 2s. She read the newspaper quite readily, but with poor comprehension. The responses to Face-Hand test were normal.

At this time the EEG showed long bursts and runs of bisynchronous spike and spike-wave activity, with the same characteristics as on the previous day. There were, however, occasional brief periods of normal activity (Figure 2A). The figures show that the spike activity is most marked at the left frontal electrode, and in some runs phase reversals at this electrode were demonstrated. A further attempt at localization was made by placing additional electrodes midway between the level of the nasion and the frontal electrode. In a transverse run, along a horizontal line from the right to the left mid-temporal electrode, it can be seen that the spike activity is of highest voltage, with phase reversal, about the left pre-

frontal electrode, less about the left anterior temporal electrode (Figure 2C).

During the remainder of this day she behaved in what appeared to be a normal fashion, in the opinion of those attending her.

On examination at nine o'clock on the morning of January 14, she was quite alert, she gave the day, date and place correctly and without hesitation. Calculation was much better, but still not perfect. The EEG at this time was perfectly normal. Although it is impossible to say without continuous EEG monitoring, it is my estimate that this episode lasted approximately 36 hours.

Primidone 0.25 Gm. t.i.d. was added to the patient's medication, and she had no further seizures during a 15-month period of observation.

DISCUSSION

Clinically, this case most closely resembles some which have been described in the literature under the name "petit mal status" (4, 6, 9). These patients have periods of altered consciousness lasting from hours to days. The alteration may be so mild as to constitute only a slight "mental slowing," with complete ability to perform the person's normal daily tasks, or may be so severe as to induce almost complete withdrawal and immobility. In a number of cases there has been continuous twitching of the eyelids, or hands, similar to that seen momentarily with petit mal lapses (9). All reported instances of petit mal status with EEGs performed during the attack, have shown almost continuous diffuse and symmetrical spike-wave activity.

The clinical manifestations in this type of condition, however, show marked variation, and it is sometimes very difficult to make a specific diagnosis on clinical grounds alone. Cases of post-ictal confusion, and even pre-ictal mental slowing, may show features indistinguishable from some cases of petit mal status (5, 8). Marked similarities may also be seen in some cases of the

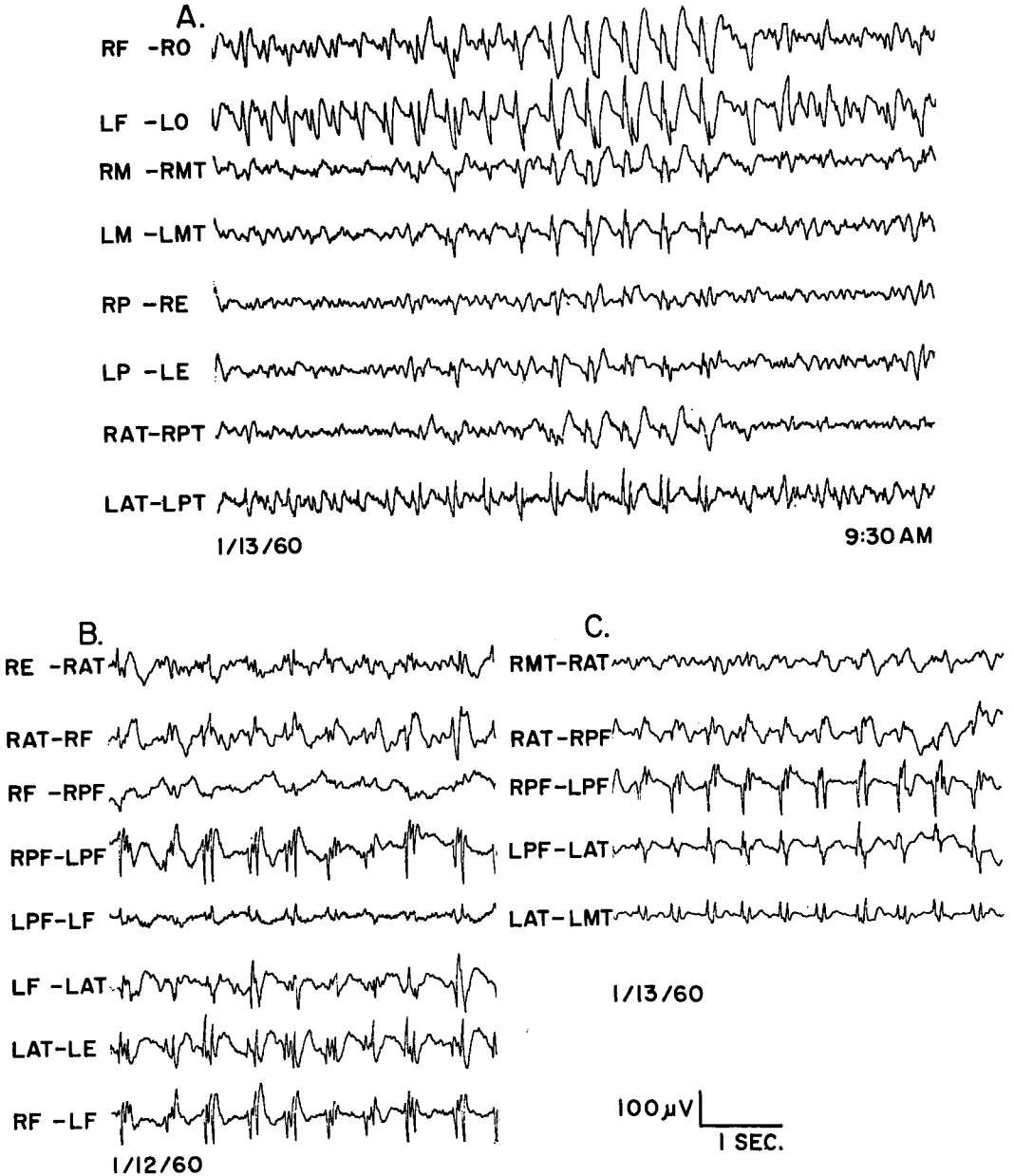


FIG. 2. Tracing performed on second day of seizure. B and C show the most pronounced focal spike activity, with phase reversal, at left prefrontal and anterior temporal electrodes.

“ictal automatisms” seen with focal temporal lobe lesions (5, 10).

The cases of verified petit mal status tend to have some common features, the most prominent of which are definite defects in

orientation and abstract thinking. Since the general behavior may appear normal, it is often necessary to elicit these defects by specific testing of the mental status. These “organic” deficits may coexist with, and

be partially masked by, disturbances in thinking which show elements suggesting conversion hysteria and even malingering (1, 6). More severely affected patients may suggest, in their behavior, catatonic stupor or depressive withdrawal. These cases must be differentiated from those described by Weil (13), Hill (7), and by Ervin *et al.* (2) in whom episodic disturbances of affect and mentation occurred in the presence of EEG abnormalities which were not diffuse or continuous.

The transient improvement with associated elimination of EEG abnormality, after injection of amobarbital sodium, was previously described in a case of petit mal status by Bornstein *et al.* (1). The beneficial effect of intravenous barbiturates on obviously convulsive behavior is well known. The results of such injections in ictal behavior disturbances must be borne in mind, however, in view of superficially similar effects which may be obtained in cases of catatonic stupor or hysterical fugue states.

In many instances the final diagnostic distinction can only be made with the aid of an EEG. In the present case the EEG was particularly revealing. Although a fronto-temporal spike focus had been demonstrated during a seizure-free interval, one could not define the probable electrophysiological basis of her periods of altered consciousness on clinical grounds alone.

The tracing during the episode, however, did show continuous diffuse bisynchronous spike-wave activity. This focally induced bisynchronous activity was described by Tukel and Jasper (12) and called "secondary bilateral synchrony." Although the clinical data in their series did not include any case similar to the one presented here, the EEG findings are essentially similar. It seems probable that, as in their surgically verified cases, there is a focal epileptogenic lesion in the frontal parasagittal region, which under certain circumstances induces bisynchronous convulsive discharges in the

deeper structures, with concomitant gross behavior disturbances.

In view of the absence of typical clinical evidence of petit mal lapses, and in the absence of bisynchronous 3/second spike-wave activity, it seems unjustifiable to make a definite diagnosis of "petit mal status" in this case, in spite of the striking clinical similarities. It seems more appropriate to use a more inclusive term, such as "ictal twilight state" (10), since this case does not fall within any of the more specifically defined categories.

SUMMARY

A case is presented of a 75-year-old woman with a 30-year history of infrequent two- to six-day episodes of withdrawn behavior. One such episode was observed, with serial EEG tracings showing continuous spike-wave abnormalities, apparently arising from a frontal parasagittal focus.

The differentiation of ictal twilight states from other epileptic and non-epileptic episodic behavior disturbances is discussed.

REFERENCES

1. BORNSTEIN, M., CODDON, D. AND SONG, S. Prolonged alterations in behavior associated with a continuous electroencephalographic (Spike and Dome) abnormality. *Neurology*, **6**: 444-448, 1956.
2. ERVIN, F., EPSTEIN, A. W. AND KING, H. E. Behavior of epileptic and non-epileptic patients with "temporal spikes." *A.M.A. Arch. Neurol. Psychiat.*, **74**: 488-497, 1955.
3. FINK, M., GREEN, M. A. AND BENDER, M. B. The face-hand test as a diagnostic of organic mental syndrome. *Neurology*, **2**: 46, 1952.
4. FRIEDLANDER, W. J. AND FEINSTEIN, G. N. Petit mal status epilepsy minoris continua. *Neurology*, **6**: 357-362, 1955.
5. GLASER, G. H. AND GOLUB, L. M. The EEG of psychomotor seizures in childhood. *Electroenceph. Clin. Neurophysiol.*, **7**: 329-340, 1955.
6. GOLDENSOHN, E. S. AND GOLD, A. P. Prolonged behavioral disturbances as ictal phenomena. *Neurology*, **10**: 1-9, 1960.
7. HILL, D. EEG in episodic psychotic and psychopathic behavior. A classification of data. *Electroenceph. Clin. Neurophysiol.*, **4**: 419-442, 1952.

8. PUTNAM, T. J. AND MERRITT, H. N. Dullness as an epileptic equivalent. *A.M.A. Arch. Neurol. Psychiat.*, **45**: 797-813, 1941.
9. SCHWAB, R. S. A case of status epilepticus in petit mal. *Electroenceph. Clin. Neurophysiol.*, **5**: 441-442, 1953.
10. STRAUSS, H. Epileptic disorders. In Arieti, S., ed. *American Handbook of Psychiatry*, pp. 1109-1143. Basic Books, New York, 1959.
11. TUCKER, W. M. AND FORSTER, F. M. Petit mal epilepsy occurring in status. *A.M.A. Arch. Neurol. Psychiat.*, **64**: 823-827, 1950.
12. TUKEL, K. AND JASPER, H. The EEG in parasagittal lesions. *Electroenceph. Clin Neurophysiol.*, **4**: 481-494, 1952.
13. WEIL, A. A. Ictal depression and anxiety in temporal lobe disorders. *Amer. J. Psychiat.*, **113**: 148-157, 1956.