

Longitudinal Analysis of Hearing Loss in a Case of Hemosiderosis of the Central Nervous System

*H. H. Weekamp, *P. L. M. Huygen, †J. L. Merx, ‡H. P. H. Kremer, and
*Cor W. R. J. Cremers

Departments of *Otorhinolaryngology, †Radiology, and ‡Neurology, University Medical Centre
St. Radboud, Nijmegen, The Netherlands.

Objective: To describe cochleovestibular aspects of superficial hemosiderosis of the central nervous system.

Background: Superficial hemosiderosis of the central nervous system is a rare disease in which cochleovestibular impairment, cerebellar ataxia, and myelopathy are the most frequent signs. Chronic recurrent subarachnoidal hemorrhage with bleeding into the cerebrospinal fluid is the cause of deposition of hemosiderin in leptomeningeal and subpial tissue, cranial nerves, and spinal cord. Removing the cause of bleeding can prevent irreversible damage to these structures. Because this is the only effective treatment, an early diagnosis is crucial.

Study Design: Retrospective case review.

Setting: Tertiary referral center.

Patient: A 72-year-old woman with superficial hemosiderosis of the central nervous system that developed when she was age 39.

Methods: Neurologic and imaging diagnostic examinations and longitudinal evaluation of cochleovestibular features were performed. Neurosurgery was not performed.

Results: Progressive bilateral sensorineural hearing loss and severe vestibular hyporeflexia developed within 15 years, which can be attributed to lesions in the cochleovestibular system. Additional pathology of the central nervous system developed later.

Conclusion: The patient demonstrated cochlear and vestibular findings that are typical of this pathologic condition. It is the first documented case with extensive serial audiometry used to precisely outline the degree of hearing deterioration during the course of the disease. **Key Words:** Annual threshold deterioration—Cochlear—Longitudinal regression analysis—Progressive hearing loss—Superficial hemosiderosis.
Otol Neurotol 24:738–742, 2003.

Superficial hemosiderosis of the central nervous system (SH-CNS) is a condition with intracellular and extracellular deposition of hemosiderin on the surface of multiple structures of the CNS, with predisposition for the leptomeninges, subpial tissue, spinal cord, and cranial nerves (1,2). It develops after recurrent or episodic bleeding into the subarachnoidal space (3). Main signs and symptoms relate to progressive sensorineural hearing impairment, ataxia, and myelopathy. It is a rare condition that is highly debilitating when progressive.

Approximately 100 cases have been reported. Most reports have focused on neurologic and radiologic aspects. This can be explained by the extensive and devastating effects on CNS structures and the fact that magnetic resonance imaging (MRI) is the current standard for the diagnosis of SH-CNS. Because one of the first symptoms is progressive bilateral hearing loss, the otolaryngologist needs to be aware of this condition so that early recognition may allow potential for therapy.

This report highlights the cochleovestibular aspects of SH-CNS. It is the first one to our knowledge that includes long-term audiological follow-up. It illustrates the rapid deterioration of hearing in this condition.

CASE HISTORY

The patient was a 72-year-old woman. At age 39, she had presented with bilateral tinnitus. During the next decade of her life, she experienced highly progressive bilateral hearing loss, eventually leading to total deafness at age 54. At age 52, progressive gait problems developed, which were slowly progressive over the next 7 years. They manifested as unsteadiness and imbalance, especially during walking and cycling. There was no dizziness. Additional problems developed in the seventh decade of her life, including urinary retention, constipation, hypothyroidism, hyposmia, transient tremor of her hands, and severe weight loss. She underwent extensive laboratory, neuro-otological, neurologic, and MRI examinations during long-term follow up. The diagnosis of SH-CNS was established on the basis of the cerebrospinal fluid and MRI findings; no surgical or medical therapy was provided.

Address correspondence and reprint requests to Dr. Cor W. R. J. Cremers, Department of Otorhinolaryngology, University Medical Centre St. Radboud, P. O. Box 9101, 6500 HB Nijmegen, The Netherlands.

Pure tone audiograms, obtained between the ages of 43 and 58 years, showed severe progression of sensorineural hearing loss, which was bilateral and fairly symmetrical (Fig. 1). Longitudinal analysis of serial audiometry data was performed. The annual threshold deterioration rate (ATD) in decibels (dB) of hearing loss per year over the period of steepest decline ranged from 12 to 24 dB/y at 0.25 to 8 kHz (Fig. 2). A conspicuous increase in ATD was seen from approximately age 45 onwards in the mid-frequency and high-frequency ranges. The ATD in the low frequencies culminated a few years later, from approximately age 50 onwards. Onset of progression tended to be later in the low-frequency range. Within approximately 5 to 8 years from the onset of clear-cut progression, she became completely deaf. At age 47, the maximum speech recognition score for the right ear was 60% at a pure tone average for 1, 2, and 4 kHz of 73 dB (Fig. 1), i.e., in accordance with purely cochlear dysfunction. There was no useful speech discrimination left in either ear from age 52 years onwards (Fig. 1). Vestibulo-ocular examination was performed at age 59, using rotatory tests (eyes open in the dark) with electronystagmography and computer analysis. There was no sign of any ocular motor dysfunction recorded. Severe vestibular hyporeflexia, with an extremely short time constant of the vestibulo-ocular reflex (3 to 4 seconds; normal >10), was found bilaterally.

At age 52, she reported gait problems that were slowly progressive over the next 7 years. The first neurologic examination at age 59 showed discrete sensory signs of the lower legs and bilateral extensor plantar responses. CT scan of the brain yielded normal results. Over the subsequent years, her gait slowly deteriorated, but climbing stairs remained possible until age 66 years. At age 62, she reported bladder disturbances. Examination disclosed gait ataxia. Anemia (Hb, 5.8 mmol/L) and an erythrocyte sedimentation rate of 108 mm in the first hour raised the suspicion of rheumatic polymyalgia. She was hospitalized and prednisone treatment was initiated.

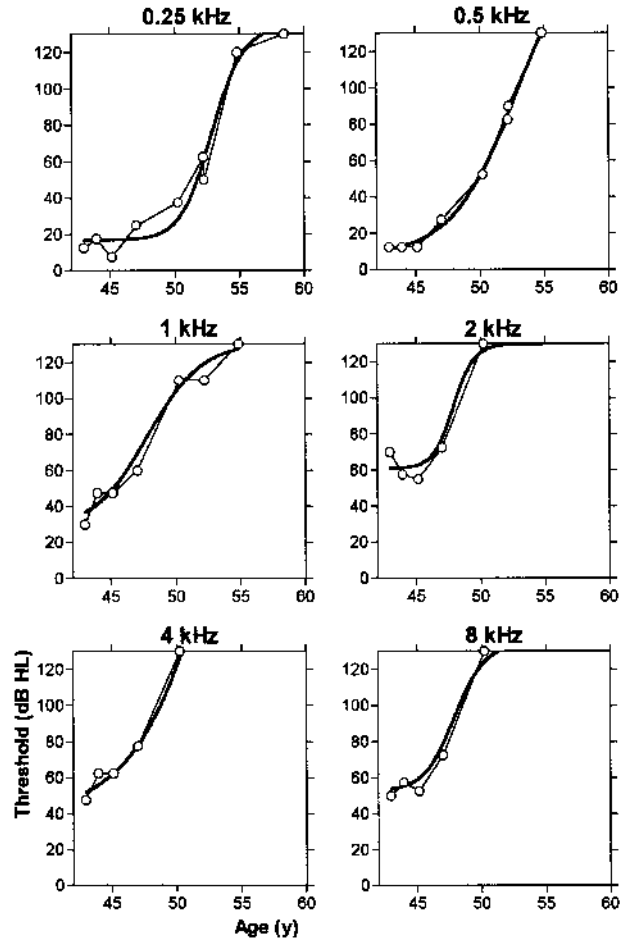


FIG. 2. Longitudinal regression analysis. A sigmoidal dose-response curve with variable slope is fitted to the (binaural mean) threshold data. Visually fitted tangents to the curve at the inflexion point (not shown) indicated average progression culminating at values of between 12 and 24 dB/y.

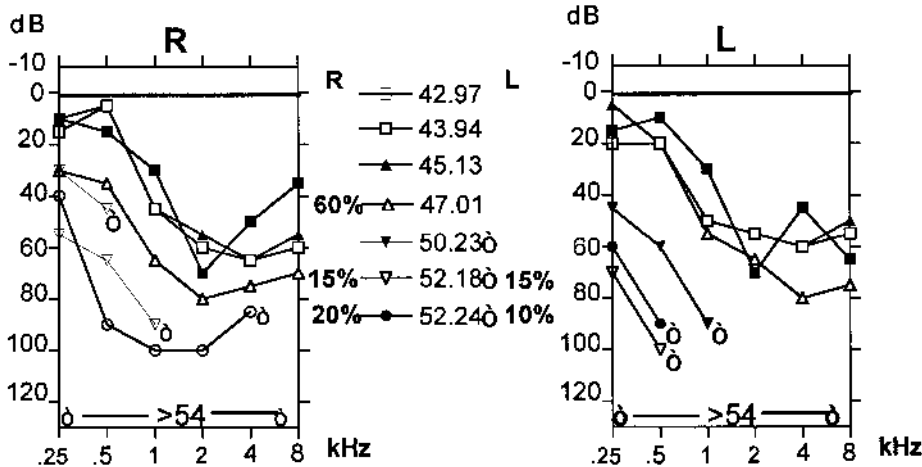


FIG. 1. Pure tone thresholds (air conduction level in decibel hearing loss) at various ages (y) in the right (R) and left (L) ears. Bilateral total deafness (downward arrows) was present at age 54. Percent correct phoneme recognition score indicated next to symbol key.

A hip fracture at age 63 necessitated internal hip fixation. In subsequent years, her gait further deteriorated. At age 66, she started to experience pain in both legs. From then on, she was unable to walk unassisted or climb stairs. Neurologic examination showed bilateral hyposmia, upward gaze palsy, bilateral gaze-evoked nystagmus, and bilateral anacusis. There was bilateral MRC grade 4 paralysis of the extensor muscles of the feet, hypertonia of the legs, leg hyperreflexia, and extensor plantar responses. She also had prominent gait ataxia, hypermetria on heel-to-shin testing, impaired vibration perception, and akinesia in the lower legs. The mini-mental state examination was unremarkable. A lumbar puncture at this time revealed 1,850/ μ L erythrocytes and 8/ μ L white cells, with increased cerebrospinal fluid levels of bilirubin (1.02 μ mol/L, normal <0.5), protein (748 mg/L, normal <550), and ferritin (103 μ g/L, normal <10). There were no oligoclonal bands.

Axial T₂-weighted MRI of the brain showed features characteristic of diffuse superficial hemosiderosis of the CNS. In addition, cerebellar atrophy and biparietal cortical hemisphere atrophy were found. No aneurysm or arteriovenous malformations were detected. Cerebral angiography was normal (Fig. 3). Spinal MRI was suspect for diffuse superficial hemosiderosis and medullar atrophy. It showed scalloping of the lumbar vertebrae, dural ectasia, and/or cysts arising from the dural roots (Fig. 4). No evident bleeding source was found.

The last visit of the patient to the ears, nose, throat outpatient clinic was 15 years ago. She is now 73 years old and needs intensive nursing because of her severe neurologic condition, which is also the reason for not considering cochlear implantation as a reasonable option.

DISCUSSION

In approximately 50% of reported cases of SH-CNS, a bleeding source could be established. Main sources of bleeding are tumor, vascular malformation, and damage to the meninges (4,5). Interestingly, there have been recent reports showing that SH-CNS can be secondary to transthyretin amyloidosis (6,7).

The clinical triad usually observed in SH-CNS consists of hearing loss, cerebellar ataxia, and spinal cord dysfunction (myelopathy). Of these features, sensorineural hearing loss is most frequently reported (95%) (5). In most cases, it has also been the first symptom to occur (8,9).

However, the appearance of clinical signs and symptoms during the siderosis process is not obligatory. Offenbacher et al. identified 13 patients with imaging evidence of SH-CNS in a consecutive series of 8,843 brain MRI studies (10). Only two of the 13 patients had clinical features indicative of SH-CNS, including progressive hearing loss, cerebellar ataxia, myelopathy, and dementia. Two more patients showed only hearing loss. These patients, and six others, showed focal neurologic deficits in association with specific MRI findings. One patient

reported "dizziness" and three had repeated episodes of headache.

Tinnitus and progressive bilateral sensorineural hearing loss were the first symptoms to occur in our patient. Audiometry, including speech audiometry, indicated primary cochlear pathology. However, because no electrocochleography or brainstem auditory-evoked potentials were evaluated, retrocochlear pathology could not be excluded. We found severe vestibular hyporeflexia bilaterally at age 59 years. This might fit in with vestibular failure of either peripheral or central origin; however, at that age she had no ocular motor disturbances. At more advanced ages, it was obvious from the deterioration in neurologic functions that the process was affecting various central pathways outside the auditory system. Over the years, ocular motor and visual features, head movement-dependent oscillopsia (HMDO), ataxia, imbalance, and gait disturbances developed, probably related to CNS (mainly cerebellar) and vestibular dysfunction. Peripheral sensory nerve dysfunction probably accounted for at least part of the gait problems. According to the review by Fearnley et al., cerebellar ataxia is seen in 88% of patients with SH-CNS (5).

HMDO is typical of vestibular areflexia. Clear-cut dizziness is usually lacking in such patients. Vestibular failure, i.e., severe hypofunction or areflexia, has been reported in SH-CNS by several authors (5,8,11–18).

The number of reports detailing hearing loss is limited (2,12,17–20). Generally, hearing loss has been reported to be fairly symmetrical (2,9,12,17,19), but asymmetry may also occur (5,14,20,21). Rapid progression in hearing loss was found in many cases (5,6,8,9,11,13–15,17,19,20,22) but was missing in others (18,21,23).

Reported audiometric data showed major loss at all frequencies, especially the high frequencies (2,5,8,11–13,17–20,22,24–26). Our patient showed an ATD of 12 to 24 dB/y. This may represent exceptionally high progression. From the limited follow-up data in previous reports, we could derive tentative ATD values in only a few cases: approximately 7 to 8 dB/y (all frequencies) in the cases reported by Kwartler et al. (19) and Castelli and Husband (9) and approximately 15 to 20 dB/y in the low-frequency range in the case described by Takasaki et al. (17). The latter case hardly showed any progression in the high-frequency range, whereas in the present case substantial progression was found for all frequencies. Our patient showed an earlier onset of progression at the higher frequencies (Fig. 2); we could not find any suggestion of differences in onset age between frequencies in any of the previously reported cases. An earlier onset of deterioration at the higher frequencies could be accordance with predominant involvement of the high frequencies (Fig. 3 and 4).

Noetzel (27) was the first to associate SH-CNS with chronic subarachnoidal hemorrhage. He attributed this to diffusion of blood pigments from the subarachnoidal space into the pial and subpial layers. It was unclear how superficial siderosis could lead to neurologic, especially cochleovestibular, dysfunction until appropriate animal

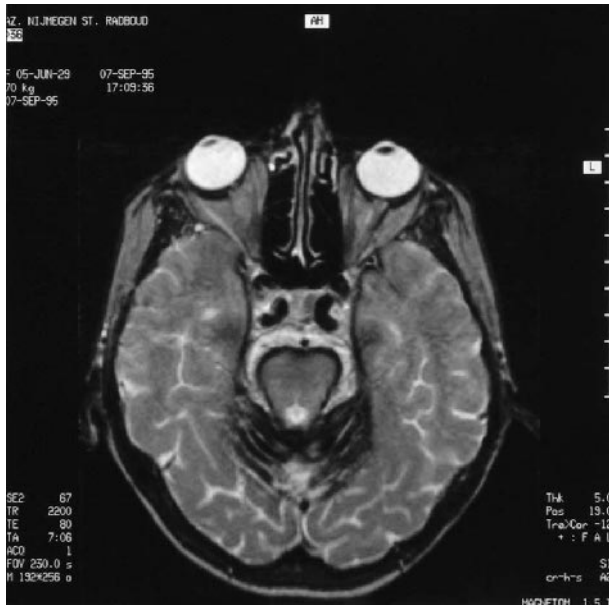

FIG. 3. Axial T₂-weighted MRI of the brain shows hypointense etching around the pons, the culmen of the cerebellum, and the medial aspect of the temporal lobes.

experimental model work was undertaken, including intracisternal injections of blood, iron, and iron-containing heme (28). The cells in the CNS that take up iron or iron-containing substance have been identified as predominantly glial cells, and the intracellular biochemical reactions that are involved in subsequent iron metabolism (ferritin biosynthesis) have been largely elucidated (3). The human body is capable of eliminating a certain

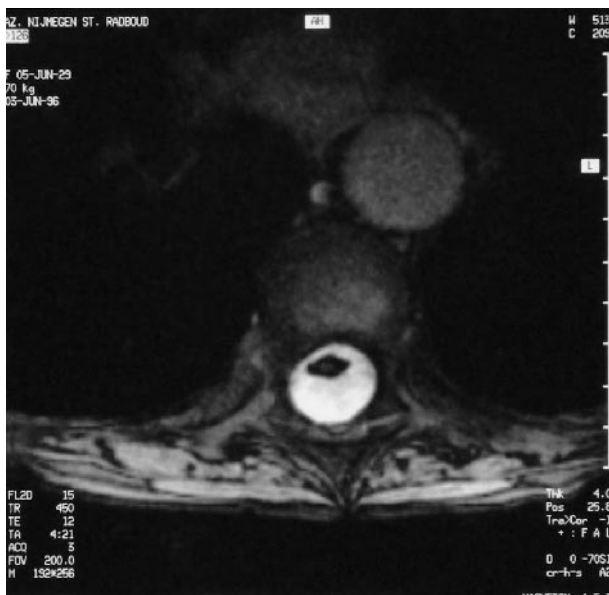

FIG. 4. Axial T₂-weighted MRI scan shows atrophy of the thoracic spinal cord with hypointense etching caused by superficial hemosiderosis.

amount of iron from intracranial spaces. Therefore, no evident SH-CNS develops until after approximately 6 months of repeated bleeding. When the iron-binding capacity is limited, the remaining iron catalyzes reactions (lipid peroxidation) releasing free radicals, which causes localized cell death and tissue necrosis (29).

Histopathologically, superficial hemosiderosis is characterized by typical light-brown staining and atrophy (1,4). Particular structures in the CNS seem to be affected far more frequently than others, such as, for example, the superior vermis of the cerebellum, the surface of the brainstem, brain tissue surrounding the Sylvian cisterns, and cranial nerves I, II, and VIII (4). Selective damage of these CNS structures may be related to the presence of cells involved in the biosynthesis of ferritin. Koeppen and Dentinger (4) demonstrated preferential immunohistochemical staining of proximal (glial) tissue compared with distal Schwann cells of cranial nerve VIII in five cases. In contrast to most other cranial nerves, the glial Schwann cell junction in nerve VIII is not located near the brainstem. It has the longest glial sheath, which makes it most vulnerable.

Hearing loss in SH-CNS has most often been attributed to retrocochlear lesions. Several authors reported interwave delay in brainstem auditory-evoked potentials, indicating retrocochlear pathology (9,18,30). Fearnley et al. (5) could not find any consistent brainstem auditory-evoked potentials. Takasaki et al. (17) found an increased threshold of cochlear microphonics on electrocochleography, attesting to cochlear pathology. An additional retrocochlear finding in their patient was that given the level of pure tone hearing impairment, she showed poor speech discrimination. Stillhard et al. (25) reported decay of stapedial reflexes bilaterally. Fearnley et al. (5) reported absence of ipsilateral and contralateral stapedial reflexes in their patient.

Two reports have appeared that suggested the existence of a cochlear deficit only, without any involvement of cranial nerve VIII (13,15). Successful cochlear implantation was mentioned in these reports and in that by Takahashi et al. (16). No satisfactory explanation was given for the absence of central neurologic lesions or the presence of selective cochlear damage. Apparently, the latter also applies to our patient at ages at which cochleovestibular impairment was documented but central deficits were not yet evident. Hypothetically, cochlear function could have deteriorated as a consequence of an altered internal cochlear environment, for example, caused by hypoxia or a change in perilymph composition. Haferkamp et al. (15) suggested the involvement of the cochlear aqueduct that connects the subarachnoidal and the perilymphatic spaces. Whether siderosis can be identified within the cochlea remains to be confirmed by MRI or related methods, if at all possible. Irving and Graham (13) reported MRI findings including a normal signal from the cochlea, but there may have been a lack of detail in the signal. Histopathologic examination of temporal bones has not yet been performed and, once performed, should preferably include immunohistochem-

ical methods. It would seem that labyrinthine dysfunction caused by hemosiderosis, if it exists, also accounts for the finding of vestibular areflexia.

Today the suspected clinical diagnosis can be confirmed by means of T₂-weighted MRI. A hypointense "etching" can be seen along the pial and arachnoid surfaces, caused by the presence of ferric ions. There is a predisposition for structures in the posterior cranial fossa and the spinal cord.

The first step in treatment of SH-CNS is to locate and eliminate the source of bleeding. Until today, medical therapy by means of iron chelation has generally not been proven to be effective. We found one report that claimed partially successful treatment with iron chelation therapy (30); however, abnormalities of brainstem auditory-evoked potentials persisted. As stipulated, cochlear implantation may be an option for symptomatic treatment of hearing loss, but it should be realized that this does not stop the underlying deterioration process.

For the otolaryngologist, it is important to note that in a case of acquired, distinctly progressive hearing deterioration with additional features attributed to CNS involvement, SH-CNS should be included in the differential diagnosis. Vestibulo-ocular examination, speech audiometry (when still possible), analysis of brainstem auditory-evoked potentials, and, most importantly, T₂-weighted MRI of the CNS should be performed.

REFERENCES

- Hughes JT, Oppenheimer DR. Superficial siderosis of the central nervous system: a report on nine cases with autopsy. *Acta Neuropathol (Berlin)* 1969;13:56-74.
- Parnes SM, Weaver SA. Superficial siderosis of the central nervous system: a neglected cause of sensorineural hearing loss. *Otolaryngol Head Neck Surg* 1992;107:69-77.
- Koeppen AH, Dickson AC, Chu RC, et al. The pathogenesis of superficial siderosis of the central nervous system. *Ann Neurol* 1993;34:646-53.
- Koeppen AH, Dentinger MP. Brain hemosiderin and superficial siderosis of the central nervous system. *J Neuropathol Exp Neurol* 1988;47:249-70.
- Fearnley JM, Stevens JM, Rudge P. Superficial siderosis of the central nervous system. *Brain* 1995;118:1051-66.
- Mascalchi M, Salvi F, Pirini MG, et al. Transthyretin amyloidosis and superficial siderosis of the CNS. *Neurology* 1999;53:1498-1503.
- Ellie E, Camou F, Vital A, et al. Recurrent subarachnoid hemorrhage associated with a new transthyretin variant (Gly53Glu). *Neurology* 2001;57:135-7.
- Longridge NS, Hashimoto S, Marotta TR, et al. Superficial siderosis—a cause of audiovestibular failure. *J Otolaryngol* 1996;25:41-3.
- Castelli ML, Husband A. Superficial siderosis of the central nervous system: an underestimated cause of hearing loss. *J Laryngol Otol* 1997;111:60-2.
- Offenbacher H, Fazekas F, Schmidt R, et al. Superficial siderosis of the central nervous system: MRI findings and clinical significance. *Neuroradiology* 1996;38:S51-6.
- Revesz T, Earl CJ, Barnard RO. Superficial siderosis of the central nervous system presenting with longstanding deafness. *J Roy Soc Med* 1988;81:479-81.
- Lai MT, Ohmichi T, Yuen K, et al. Superficial siderosis of the central nervous system: a case with an unruptured intracranial aneurysm. *J Laryngol Otol* 1995;109:549-52.
- Irving RM, Graham JM. Cochlear implantation in superficial siderosis. *J Laryngol Otol* 1996;110:1151-3.
- Durieux A, Flocard F, Ferreira A, et al. Hémosidérose du système nerveux central. *Rev Neurolog (Paris)* 1999;155:201-7.
- Haferkamp C, Schabet M, Plinkert PK. Cochlea-implant-Versorgung bei superfizieller leptomeningealer Hämosiderose. *HNO* 1999;47:642-6.
- Takahashi K, Kakoi H, Takasuka N, et al. Cochlear implant for a totally deaf patient with superficial hemosiderosis of the central nervous system. In: Kim CS, Chang SO, Lim D, eds. *Updates in cochlear implantation*. Basel: Karger; 2000;57:138-40.
- Takasaki K, Tanaka F, Shigeno K, et al. Superficial siderosis of the central nervous system. A case report on examination by ECoG and DPOAE. *Otorhinolaryngol Rel Special* 2000;62:270-3.
- Yamana T, Suzuki M, Kitano, H. Neuro-otologic findings in a case of superficial siderosis with bilateral hearing impairment. *J Otolaryngol* 2001;30:187-9.
- Kwartler JA, De La Cruz A, Lo WWM. Superficial siderosis of the central nervous system. *Ann Otol Rhinol Laryngol* 1991;100:249-50.
- Pribitkin EA, Rondinella L, Rosenberg SI, et al. Superficial siderosis of the central nervous system: an underdiagnosed cause of sensorineural hearing loss and ataxia. *Am J Otol* 1994;15:415-8.
- Li KW, Haroun RI, Clatterbuck RE, et al. Superficial siderosis associated with multiple cavernous malformations: report of three cases. *Neurosurgery* 2001;48:1147-51.
- Anderson NE, Sheffield S, Hope JKA. Superficial siderosis of the central nervous system: a late complication of cerebellar tumors. *Neurology* 1999;52:163-9.
- Iannaccone S, Golzi V, Sferrazza B, et al. Central nervous system superficial siderosis, headache, and epilepsy. *Headache* 1999;39:666-9.
- Grunshaw ND, Blanshard KS, Hussain SSM, et al. Superficial siderosis of the central nervous system—diagnosis by magnetic resonance imaging. *Clin Radiol* 1993;48:186-8.
- Stillhard G, Bont A, Huber-Gut D. Haemosiderosis superficialis cerebri: seltene Ursache einer Ataxie und Hypakusis. *Schweiz Med Wochenschr* 1993;123:1027-32.
- Hsu WC, Loevner LA, Forman MS, et al. Superficial siderosis of the CNS associated with multiple cavernous malformations. *AJNR Am J Neuroradiol* 1999;20:1245-8.
- Noetzel H. Diffusion von Blutfarbstoff in der inneren Randzone und äueren Oberfläche des Zentralnervensystems bei subarachnoidaler Blutung. *Arch Psychiatr Nervenkr* 1940;111:129-38.
- Koeppen AH, Borke RC. Experimental superficial siderosis of the central nervous system. I. Morphological observations. *J Neuropathol Exp Neurol* 1991;50:579-94.
- Koeppen AH, Hurwitz CG, Dearborn RE, et al. Experimental superficial siderosis of the central nervous system: biochemical correlates. *J Neurol Sci* 1992;112:38-45.
- River Y, Honigman S, Gomori JM, et al. Superficial hemosiderosis of the central nervous system. *Mov Disord* 1994;9:559-62.

INVITED COMMENT

The condition seems to run a standardized course, although by description this article indicates a cochlear origin and potential for use of cochlear implantation in some patients. This has potential for therapeutic benefit.

In the literature there is an assumption that it is excessive blood in the subarachnoid space that is the cause of symptoms; however, it may be that the defect is in metabolizing normal amounts of blood from the cerebrospinal fluid because of an inborn error.

Neil S. Longridge, M.D.
Vancouver BC, Canada