

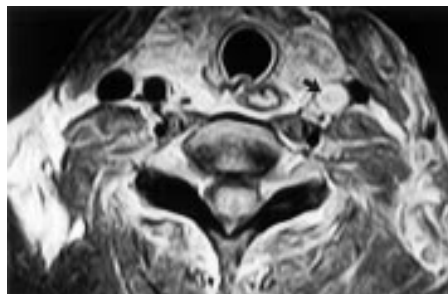
## CASE REPORT

## Accidental carotid artery injury caused by a horse rope

L Nunnink, F Abu-Zidan

*Br J Sports Med* 2003;**37**:460–461

A 37 year old woman who had bred horses for more than 20 years was leading two horses in a horse corral. One horse bolted and the lead rope wrapped around her neck. Four hours after the accident, she developed sudden aphasia, right facial palsy, and right arm weakness. Conventional and magnetic resonance angiography showed complete traumatic occlusion of the left common carotid artery due to thrombosis at the C6/7 level. There was good collateral flow from the other side. The patient was maintained on heparin followed by warfarin and recovered completely by the third day. This case shows the importance of suspecting vascular injury and thrombosis after trauma to sites of major vessels.

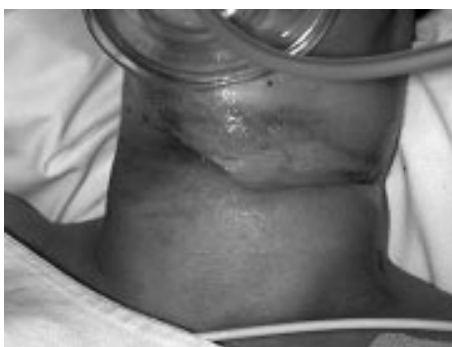

**Figure 2** T1 axial sequence magnetic resonance image of the neck showing a high signal of the left common carotid artery with thrombus in its lumen (arrow).

Most horse related injuries are mild and do not need admission to hospital, but some are severe and life threatening.<sup>1</sup> We report a case of blunt carotid artery injury caused by accidental strangulation with a horse rope.

## CASE REPORT

A 37 year old woman who had bred horses for more than 20 years was leading two horses simultaneously by their leading ropes in a horse corral. One horse bolted, and the lead rope briefly wrapped around her neck and was suddenly released. The patient recalled that she had stepped on the end of one of the two ropes. She complained of severe neck pain, difficulty in breathing, left arm weakness, and paraesthesia of both hands and feet. She drove her car to a local general practitioner who gave her 100 mg hydrocortisone intravenously and referred her to a local district hospital. Examination showed an anxious patient with a deep transverse painful laceration of a rhomboid shape on the anterior neck. There was superficial skin loss with severe surrounding oedema (fig 1). There was loss of muscle power but normal sensation in the left upper limb. Sensory and motor function were normal in the lower limbs. The patient was given morphine analgesia, had cervical spine immobilisation, and was transferred to Royal Perth Hospital.



**Figure 1** Neck laceration caused by accidental strangulation with a horse rope.

When seen at our emergency department, the left upper limb weakness had improved significantly with a return of power (4/5) in all muscle groups except shoulder abductors, which had persistently reduced power. Carotid pulses were palpable both above and below the neck laceration. Cervical spine radiographs were normal. Laryngoscopy was performed and was also normal. Four hours after the accident the patient developed sudden aphasia, right facial droop, and right arm weakness. Examination revealed right upper motor neurone facial paresis and a reduction in right upper limb power to 2/5 in all groups. Right lower limb power was normal. A working diagnosis of carotid artery occlusion was made. Prothrombin time, activated partial thromboplastin time, plasma fibrinogen, platelet count, and haemoglobin concentration were all within normal limits.

Computed tomography of the head showed no intracerebral haemorrhage or obvious ischaemic deficit. Conventional angiography showed complete occlusion of the left common carotid artery due to thrombosis at the C6/7 level. A small amount of thrombus extended into the internal carotid artery but there was good collateral flow.

The patient recovered completely after one hour of paralysis except for some weakness in shoulder abduction. Intravenous heparin was started with a target activated partial thromboplastin time of 60–80 seconds (normal range 25–35). Magnetic resonance imaging of cervical and dorsal spine on the subsequent day excluded bony, nerve root, or cord injury. It did show bruising of the soft tissues of the neck on the left side, and magnetic resonance angiography confirmed traumatic occlusion of the left common carotid artery (fig 2). A diagnosis of left upper brachial plexus (C5/C6) contusion explained her abduction weakness, which resolved completely by the third day. The patient was maintained on heparin, then started on warfarin.

## DISCUSSION

Horse related injuries are most common in young amateur female riders.<sup>2,3</sup> Our patient who had 20 years of experience in handling horses was, however, still prone to accidental injury. We have shown in a recent multivariate analysis that neither sex, age, nor profession confer any immunity from such accidents (unpublished). Those who handle horses are liable to be

kicked, bitten, stepped on, or struck by these animals. The weight, speed, power, and unpredictable behaviour of the horse can cause serious injuries to handlers and bystanders. A horse leading rope when the horse bolted injured our patient, causing severe trauma to the internal carotid artery. The young age of the patient associated with adequate collateral circulation saved her from permanent neurological deficit. It is possible that she may have avoided the accident if she had led only one horse at a time.

Blunt carotid artery injury is uncommon, with fewer than 0.4% of blunt trauma patients being admitted to hospital.<sup>4,5</sup> Recognised mechanisms of injury include cervical hyperextension with rotation, direct trauma to the neck, intraoral trauma, and basilar skull fracture.<sup>6</sup> Occlusion in our patient was probably caused by the direct trauma causing intimal injury and thrombosis. A high index of suspicion of vascular injury and thrombosis should be raised when an area bearing major vessels is traumatised.

Delay between the time of injury and the onset of neurological symptoms is common, as occurred in our patient. Cogbill *et al*<sup>7</sup> found that, in 29% of their patients, neurological symptoms occurred more than 12 hours after the injury. Screening asymptomatic high risk patients is essential for early diagnosis and prevention of thrombosis. Biffi *et al*<sup>8</sup> screened patients with the following: cervical hyperextension/rotation or hyperflexion, associated with midface or complex mandibular fracture; closed head injury consistent with diffuse axonal injury; near hanging; seat belt injury or other soft tissue injury of the anterior neck; basilar skull fracture involving the carotid canal; or cervical vertebral body fracture. By these criteria, our patient should have undergone early angiography and started anticoagulation earlier. However, screening angiography in asymptomatic patients is controversial because it is invasive and may not be necessary. The value of non-invasive duplex scan, computed tomographic angiography, and magnetic resonance angiography has yet to be proven. In two retrospective studies of blunt carotid injury, duplex scan was abnormal in five of five and 12 of 14 patients in whom it was used.<sup>4,7</sup> Magnetic resonance angiography had 95% sensitivity for the diagnosis of non-traumatic carotid dissection,<sup>8</sup> but its use in trauma patients may not be practical. Computed tomographic angiography has been reported to have 100% sensitivity in detecting arterial injury in penetrating trauma,<sup>9</sup> but its value in blunt carotid trauma remains to be proved.

Optimal treatment of blunt carotid artery injury has yet to be defined. Systemic anticoagulation, in a retrospective study, was reported to improve outcome<sup>10</sup>; however, prospective data are lacking. In summary, this case shows the importance of

### Take home message

- A high index of suspicion of carotid injury and thrombosis when the neck is traumatised is essential for its diagnosis.
- It may be safer to lead only one horse at a time.

suspecting vascular injury and thrombosis in any injury that traumatises a major vessel area.

### ACKNOWLEDGEMENTS

We thank Dr James Rippey, Department of Emergency Medicine, Royal Perth Hospital for the clinical photograph and Professor Frank Branicki, Chair of the Department of Surgery, Faculty of Medicine and Health Sciences at United Arab Emirates University for editing the manuscript.

### Authors' affiliations

**L Nunnink**, Department of Emergency Medicine, Royal Perth Hospital, Perth, Western Australia, Australia

**F Abu-Zidan**, Trauma Services, Royal Perth Hospital

Correspondence to: Associate Professor Abu-Zidan, Department of Surgery, Faculty of Medicine and Health Sciences, PO Box 17666, Al Ain, United Arab Emirates; fabuzidan@uaeu.ac.ae

Accepted 20 October 2002

### REFERENCES

- 1 **Paix BR**. Rider injury rates and emergency medical services at equestrian events. *Br J Sports Med* 1999;**33**:46–8.
- 2 **Chitnavis JP**, Gibbons CL, Hirigoyen M, *et al*. Accidents with horses: what has changed in 20 years? *Injury* 1996;**27**:103–5.
- 3 **Barber HM**. Horse-play: survey of accidents with horses. *BMJ* 1973;**3**:532–4.
- 4 **Davis JW**, Holbrook TL, Hoyt DB, *et al*. Blunt carotid artery dissection: incidence, associated injuries, screening, and treatment. *J Trauma* 1990;**30**:1514–17.
- 5 **Biffi WL**, Moore EE, Offner PJ, *et al*. Blunt carotid arterial injuries: implications of a new grading scale. *J Trauma* 1999;**47**:845–53.
- 6 **McIntyre WB**, Ballard JL. Cervicothoracic vascular injuries. *Semin Vasc Surg* 1998;**11**:232–42.
- 7 **Cogbill CD**, Moore EE, Meissner M, *et al*. The spectrum of blunt injury to the carotid artery: a multicenter perspective. *J Trauma* 1994;**37**:473–9.
- 8 **Levy C**, Laissy JP, Raveau V, *et al*. Carotid and vertebral artery dissection: three dimensional time of flight MR angiography and MR imaging versus conventional angiography. *Radiology* 1994;**190**:97–103.
- 9 **LeBlang SD**, Nunez DB Jr. Noninvasive Imaging of cervical vascular injuries. *Am J Roentgenol* 2000;**174**:1269–78.
- 10 **Fabian TC**, Patton JH, Croce MA, *et al*. Blunt carotid injury importance of early diagnosis and anticoagulant therapy. *Ann Surg* 1996;**223**:513–25.