

# Central Nervous System Lesions Associated With Hereditary Hemorrhagic Telangiectasia

## —Three Case Reports—

Kazuyuki KUWAYAMA, Kensaku TAKASE, Michiharu KASHIHARA,  
Hideki HONDO, Toshio SHIGEKIYO\*, Osamu TAKIMOTO\*\*,  
and Shunji MATSUBARA\*\*

*Departments of Neurosurgery and \*Internal Medicine, Tokushima Prefectural Central Hospital,  
Tokushima; \*\*Department of Neurological Surgery, School of Medicine,  
The University of Tokushima, Tokushima*

### Abstract

Hereditary hemorrhagic telangiectasia (HHT) is easily overlooked in patients with central nervous system (CNS) lesions. Our clinical experience of three patients with CNS lesions associated with HHT stresses the importance of considering HHT. A 23-year-old male presented with consciousness disturbance and right hemiparesis. Emergency cerebral digital subtraction angiography revealed occlusion of the left middle cerebral artery and the left anterior cerebral artery. Pulmonary arteriography showed three pulmonary arteriovenous malformations (AVMs). A 62-year-old male presented with consciousness disturbance and sensory aphasia. Magnetic resonance imaging revealed a ring-enhanced lesion in the left temporal lobe which was removed by left frontotemporal craniotomy. The diagnosis was brain abscess. Chest computed tomography (CT) revealed two pulmonary AVMs. A 32-year-old female presented with progressive mild weakness in her left hand. Initial CT showed subcortical hemorrhage in the right frontal lobe. Cerebral angiography revealed no vascular malformations, but chest CT disclosed five pulmonary AVMs. All three patients had a family history of HHT. The possibility of HHT is important to consider in patients with cerebrovascular disease (CVD) or brain abscess to prevent complications, not only in the patients but also their blood relatives. Therefore, the medical and family history of patients with CVD or brain abscess should be investigated and HHT should be considered during the physical examination.

Key words: hereditary hemorrhagic telangiectasia, cerebrovascular disease, cerebral abscess, pulmonary arteriovenous malformation

### Introduction

Hereditary hemorrhagic telangiectasia (HHT), also known as Rendu-Osler-Weber disease, is a rare autosomal-dominant disorder characterized by multiple mucocutaneous telangiectases and associated vascular malformations that can result in hemorrhagic complications in multiple organ systems. Patients with HHT frequently present with central nervous system (CNS) complications as neurological emergencies. However, the possibility of HHT is easily overlooked. We describe cases of cerebral embolus, cerebral abscess, and subcortical

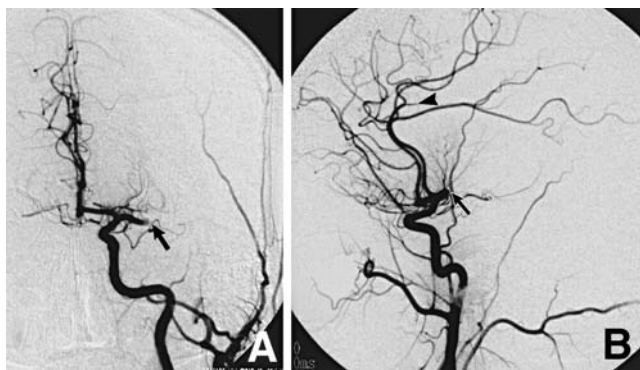hemorrhage which were associated with HHT.

### Case Reports

**Case 1:** A 23-year-old man suffered right hemiparesis followed by sudden loss of consciousness and was transferred to the emergency department of our hospital. On arrival, he was lethargic and exhibited motor aphasia and right hemiplegia. Blood analysis showed indications of polycythemia (red blood cells  $579 \times 10^4/\text{mm}^3$ , hemoglobin 17.6 g/dl). He had a history of epistaxis since childhood and had experienced migraine episodes since the age of 14

Received January 8, 2003; Accepted April 3, 2003

Author's present address: K. Kuwayama, M.D., Department of Neurosurgery, Kochi Red Cross Hospital, Kochi, Japan.



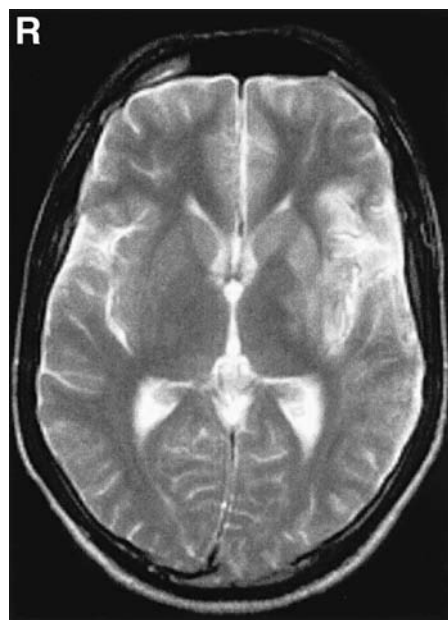
**Fig. 1** Case 1. Emergency left carotid angiograms, (A) anteroposterior view revealing occlusion of the middle cerebral artery (arrow), and (B) lateral view revealing occlusion of the middle cerebral artery (arrow) and anterior cerebral artery (arrowhead).

years. His father also suffered from recurrent epistaxis.

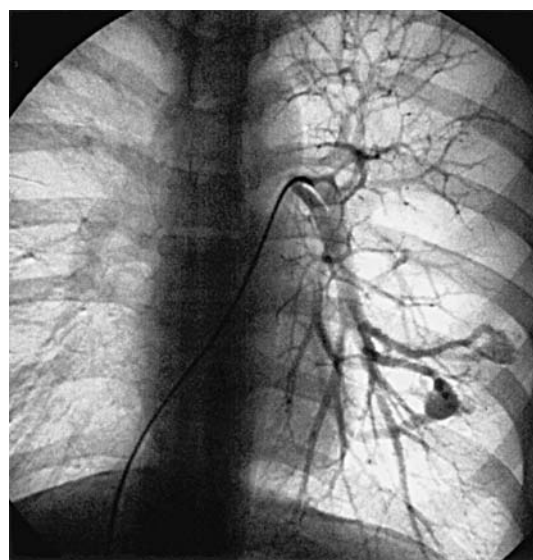
Computed tomography (CT) on admission revealed no abnormality. Emergency cerebral digital subtraction angiography (DSA) was performed. Left carotid angiography revealed occlusion of the distal horizontal segment of the middle cerebral artery ( $M_1$  distal) and the  $A_4$  segment of the callosomarginal artery (Fig. 1). Selective intra-arterial fibrinolysis with urokinase ( $54 \times 10^4$  IU) was performed. The left  $M_1$  and  $A_4$  were recanalized after 90 minutes, but not the anterior branch of the  $M_2$  segment.

Magnetic resonance (MR) imaging showed a hyperintense area in the frontal and temporal lobes around the left sylvian fissure 4 days after the onset (Fig. 2). Transthoracic echocardiography disclosed no thrombus in the heart. Systolic function in the left ventricle was normal and no valvular disease was present. Blood coagulation analysis disclosed no abnormal findings. Chest radiography revealed an abnormal shadow in the left lung, leading us to suspect HHT. This suspicion was clinically confirmed by the detection of telangiectases on the tongue and nasal mucous membrane. Chest CT and pulmonary DSA revealed three arteriovenous malformations (AVMs): 1.8 cm in diameter at  $A_8$ , and 1.4 cm and 2 cm in diameter at  $A_9$  in the left lung (Fig. 3). He was treated by transarterial embolization using detachable coils. His right hemiparesis gradually improved (upper limb manual muscle test grade 1, lower limb manual muscle test grade 3) and he was discharged 4 months after the onset.

**Case 2:** A 62-year-old man lost consciousness for a few minutes after drinking alcohol and was trans-

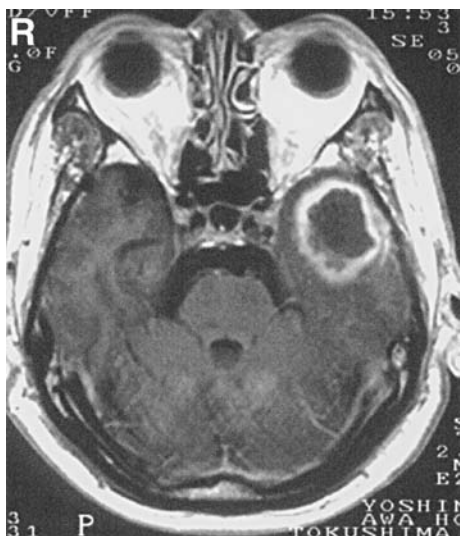


**Fig. 2** Case 1. Axial  $T_2$ -weighted magnetic resonance image obtained 4 days after onset showing a hyperintense area around the left sylvian fissure.



**Fig. 3** Case 1. Left pulmonary angiogram revealing three arteriovenous malformations.

ferred to our hospital. On arrival, he was relatively alert and as he had been drinking alcohol just prior to his transfer, he was advised to consult a local clinic. He returned to his home where his level of consciousness gradually deteriorated. On the following day he reported to a local clinic where MR imag-

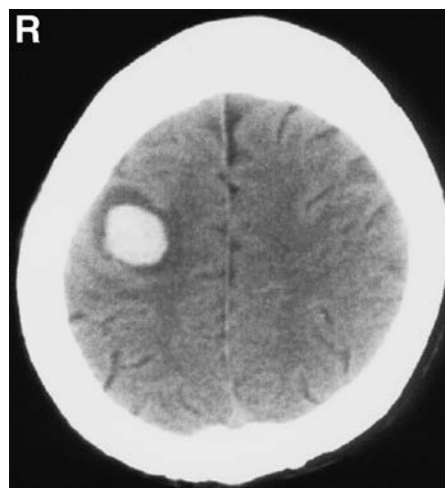


**Fig. 4** Case 2. Preoperative axial T<sub>1</sub>-weighted magnetic resonance image with gadolinium revealing a ring-enhanced lesion in the left temporal lobe.

ing showed a mass lesion. He was then referred to our hospital. He had suffered from epistaxis since childhood, and had had bone myelitis in the right tibia in December 1999. His mother had HHT and his sister had telangiectasia. He also had a 10-day history of left temporalgia.

On admission he was lethargic and confused, and manifested sensory aphasia. Blood analysis indicated mild infection (white blood cells  $9500/\text{mm}^3$ , red blood cells  $547 \times 10^4/\text{mm}^3$ , hemoglobin 15.6 g/dl, hematocrit 44.7%, platelet  $17.1 \times 10^4/\text{mm}^3$ , C-reactive protein 1.7 mg/dl). MR imaging performed at the other hospital also showed a ring-enhanced lesion in the left temporal lobe and perifocal edema (Fig. 4). Chest radiography showed right perihilar consolidation and further examination of the lung was planned after treating the intracranial lesion. He was treated with prednisolone and drip infusion of glycerol starting on the day of admission. His consciousness disturbance was improved on the day after admission and his sensory disturbance improved gradually. The differential diagnosis included glioblastoma, metastatic brain tumor, and brain abscess.

He underwent left frontotemporal craniotomy 10 days after admission. The mass contained white pus and was surrounded by a cyst wall. The medial wall of the cyst was not removed to avoid iatrogenic neurological deficits. Culture of the purulent mass content revealed *Peptostreptococcus* and *Fusobacterium*. Postoperatively, he had meningitis but re-



**Fig. 5** Case 3. Computed tomography scan obtained at initial admission revealing subcortical hemorrhage in the right frontal lobe.

covered after administration (40 days) of antibiotics.

MR imaging obtained 22 days after the onset showed an enhanced lesion around the space caused by cyst removal. He again experienced nosebleeds and we suspected HHT. Further examination showed telangiectases of the nasal, tongue, esophageal, and stomach membranes. Chest CT and three-dimensional CT angiography disclosed two AVMs: 1 cm in diameter at A<sub>2</sub> and 1.5 cm in diameter at A<sub>3</sub>. The diagnosis was HHT. He was discharged ambulatory and was hospitalized again 2 months later for the treatment of the pulmonary AVMs by transarterial embolization using detachable coils.

**Case 3:** A 32-year-old woman suffered sudden onset of gradually worsening monoparesis of her left arm. One day after the onset, she reported to the emergency department of our hospital. Neurological examination revealed monoplegia of her left arm. The results of blood analysis were within normal limits. She had suffered from epistaxis since childhood, and had undergone resection of the inferior lobe of the left lung for pulmonary AVMs at age 15 years. Her paternal relatives had a history of recurrent epistaxis.

CT revealed subcortical hemorrhage, 2 cm in diameter, in the right frontal lobe (Fig. 5). MR imaging found no abnormalities other than the subcortical hemorrhage 4 days after onset. Cerebral DSA disclosed no cerebrovascular malformations 6 days after onset. We suspected HHT on the basis of her past history and family history. The clinical diagno-

sis of HHT was based on the further finding of telangiectases on the tongue and nasal mucous membrane. Chest CT, three-dimensional CT angiography, and pulmonary DSA revealed five AVMs: 3 mm ( $n = 2$ ) and 7 mm ( $n = 1$ ) in diameter in the left lung, and 5 mm ( $n = 2$ ) in diameter in the right lung. All pulmonary AVMs were supplied by low-flow, small feeding arteries. She was referred to the department of surgery in our hospital for follow up. The monoparesis of her left arm gradually improved (manual muscle test grade 4) and she was discharged 40 days after the onset.

## Discussion

HHT is a rare autosomal-dominant hereditary disorder with an estimated prevalence of 1 in 10,000.<sup>4)</sup> There is no family history of HHT in 15–30% of cases.<sup>9)</sup> The clinical diagnosis of HHT is based on four criteria: Occurrence of spontaneous, recurrent epistaxis; presence of telangiectasia at multiple characteristic sites, including the lips, oral cavity, fingers, nose, and gastrointestinal tract; findings of visceral AVM in the lung, brain, liver, and spine; and a family history of HHT. The definitive diagnosis of HHT requires at least three of these criteria.<sup>10)</sup> Epistaxis is the most common manifestation of HHT and is usually the earliest symptom, appearing at a mean age of 12 years. As many as 95% of affected individuals eventually experience recurrent epistaxis. The age at onset is 10 years in approximately one third of patients, and by age 21 years in the remaining patients.<sup>1)</sup> Gastrointestinal bleeding occurs in one third of patients with HHT, but the age at onset tends to exceed 50 years.<sup>5)</sup>

The two main genetic forms of HHT are designated HHT1 and HHT2. HHT1 is caused by a mutation in the endoglin gene located on chromosome 9q33-q34. HHT2 is caused by a mutation in the activin receptor-like kinase-1 gene located on chromosome 12q1. HHT1 may be associated with a high incidence of AVMs.<sup>11)</sup> Arterialized veins contained endoglin-positive fibroblasts in both the adventitia and the perivascular connective tissue of patients with cerebral AVMs, suggesting that endoglin is active in vascular remodeling.<sup>7)</sup> As all of our patients manifested at least three of the criteria for the clinical diagnosis of HHT, we did not perform gene analysis. We suggest that confirmatory gene analysis is advisable if fewer than three criteria are present or in individuals with a family history of HHT.

HHT is also associated with cerebrovascular malformations. Cerebrovascular malformations occur in 12–36% of patients with HHT, of which 4.9–11% are cerebral AVMs.<sup>3,9,13)</sup> Intravenous DSA

found cerebral AVMs in 11% of 196 patients with HHT.<sup>13)</sup> The estimated bleeding risk of one AVM per year was 0.36–0.56%. Investigation of the angiographic characteristics of AVMs associated with HHT found that multiple cortical micro-AVMs are highly suggestive of HHT.<sup>8)</sup> Cerebral DSA in our Case 3 revealed no abnormality, but cryptic AVMs may have manifested as telangiectasia. Alternatively, micro-AVMs could not be detected because of compression by the hematoma. We are planning to repeat cerebral DSA in this patient.

Pulmonary AVMs are frequently encountered in patients with HHT, often accompanied by dyspnea or hemoptysis. Screening for pulmonary AVMs is usually performed by arterial blood gas analysis, chest radiography, and physical examination.<sup>2)</sup> The shunting of air, thrombi, and bacteria passing through pulmonary AVMs, bypassing the filtering capabilities of the lungs, may result in transient ischemic attacks, embolic stroke, or cerebral abscess.<sup>4,6,12)</sup> Approximately 20% of patients with HHT will develop pulmonary AVM, and 25–33% of such patients will develop cerebral ischemic symptoms. Brain abscesses will occur in 5–9% of these patients.<sup>6,12)</sup> Study of 321 patients with HHT at a single institution found pulmonary AVM in 22.1%, of whom 29.6% had a history of cerebral infarction or transient ischemic attacks, and 7% had a history of at least one cerebral abscess. AVMs with feeding vessels that exceed 3 mm in diameter require occlusion with detachable coils or surgery.<sup>6)</sup> The pulmonary AVMs in our Cases 1 and 2 could have resulted in cerebral embolism and brain abscess. Earlier treatment of these pulmonary AVMs could have prevented the CNS manifestations. All pulmonary AVMs were small and of low flow in Case 3. This patient is being followed up by the department of surgery in our hospital.

Our Case 1 presented at the emergency room and no inquiry into his past history of epistaxis was made at the time of presentation. The abnormal shadow on chest radiography was missed by neurosurgeons not trained in the detection of fine lesions. This case illustrates the importance of obtaining detailed patient and family medical histories. In the absence of the suspicion of HHT, the characteristic findings were easy to miss in this patient. In Case 2, the history of epistaxis was missed. Telangiectasia of the skin and tongue was detected but we did not immediately connect these findings with HHT. Case 3 had a history of resection of the inferior lobe of the left lung and we considered HHT because of our previous experiences with Cases 1 and 2. Therefore, the diagnosis of HHT was established early and this patient was treated

appropriately. Cerebrovascular disease (CVD) is almost always of sudden onset and most patients with CVD are first seen in the emergency room where there is insufficient time to acquire a detailed medical and family history. However, telangiectasia of the tongue and fingers is easily detected and chest radiography and blood gas analysis for hypoxia should be performed routinely even in emergency cases. Therefore, the diagnosis of HHT can be established in patients with a history of CVD or brain abscess. The medical history and physical findings should be re-evaluated in patients undergoing long-term follow up. The association of HHT is important to identify in patients with CVD or brain abscess because early diagnosis facilitates the treatment of lesions. The treatment of pulmonary AVMs is especially important to avoid progression to cerebral embolism or cerebral abscess. Furthermore, because HHT is a hereditary disease, the family of patients treated under the diagnosis of HHT should be screened for AVMs and other lesions.

Our experience with these patients with CNS lesions found to be associated with HHT suggests a detailed medical and family history should be obtained early in patients with CVD or brain abscess and the possibility of HHT should be considered at physical examination.

## References

- 1) Assar OS, Friedman CM, White RI: The natural history of epistaxis in hereditary hemorrhagic telangiectasia. *Laryngoscope* 101: 977-980, 1991
- 2) Cormac O, Maher MD, David G, Piepgras MD, Brown RD Jr, Jonathan A, Friedman MD, Pollock BE: Cerebrovascular manifestations in 321 cases of hereditary hemorrhagic telangiectasia. *Stroke* 32: 877-882, 2001
- 3) Fulbright RK, Chaloupka JC, Putman CM, Sze GK, Merriam MM, Lee GK, Fayad PB, Awad IA, White RI: MR of hereditary hemorrhagic telangiectasia: prevalence and spectrum of cerebrovascular malformations. *AJNR Am J Neuroradiol* 19: 477-484, 1998
- 4) Guttmacher AE, Marchuk DA, White RIJ: Hereditary hemorrhagic telangiectasia. *N Engl J Med* 333: 918-924, 1995
- 5) Kjeldsen AD, Kjeldsen J: Gastrointestinal bleeding in patients with hereditary hemorrhagic telangiectasia. *Am J Gastroenterol* 95: 415-418, 2000
- 6) Lee DW, White RI, Egglin TK, Pollak JS, Fayad PB, Wirth JA, Rosenblatt MM, Dickey KW, Burdge CM: Embolotherapy of large pulmonary arteriovenous malformations: long-term results. *Ann Thorac Surg* 64: 930-939, 1997
- 7) Matsubara S, Bourdeau A, ter Brugge KG, Wallace C, Letarte M: Analysis of endoglin expression in normal brain tissue and cerebral arteriovenous malformations. *Stroke* 31: 2653-2660, 2000
- 8) Matsubara S, Manzia JL, ter Brugge KG, Willinsky RA, Montanera W, Faughnan ME: Angiographic and clinical characteristics of patients with cerebral arteriovenous malformations associated with hereditary hemorrhagic telangiectasia. *AJNR Am J Neuroradiol* 21: 1016-1020, 2000
- 9) Roman G, Fisher M, Perl DP, Poser CM: Neurological manifestations of hereditary hemorrhagic telangiectasia: Report of 2 cases and a review of the literature. *Ann Neurol* 4: 130-144, 1978
- 10) Shovlin CL, Guttmacher AE, Buscarini E, Faughnan ME, Hyland RH, Westermann CJ, Kjeldsen AD, Plauchu H: Diagnostic criteria for hereditary hemorrhagic telangiectasia (Rendu-Osler-Weber syndrome). *Am J Med Genet* 91: 66-67, 2000
- 11) Shovlin CL, Hughes JMB, Scott J, Seidman CE, Seidman JG: Characterization of endoglin and identification of novel mutations in hereditary hemorrhagic telangiectasia. *Am J Hum Genet* 61: 68-79, 1997
- 12) White RI, Lynch-Nyhan A, Terry P, Buescher PC, Farmlett EJ, Charnas L, Shuman K, Kim W, Kinnison M, Mitchell SE: Pulmonary arteriovenous malformations: techniques and long-term outcome of embolotherapy. *Radiology* 169: 663-669, 1988
- 13) Willemse RB, Mager JJ, Westermann CJJ, Overtom TTC, Mauser H, Wolbers JG: Bleeding risk of cerebrovascular malformations in hereditary hemorrhagic telangiectasia. *J Neurosurg* 92: 779-784, 2000

---

Address reprint requests to: K. Kuwayama, M.D., Department of Neurosurgery, Kochi Red Cross Hospital, 2-13-51 Shinhon-machi, Kochi 780-8562, Japan.  
e-mail: kny1717@yahoo.co.jp