

- lation of MR imaging and pathologic characteristics. *AJNR* 1990;11:523-31.
15. Kalifa GL, Chiron C, Sellier N, et al. Hemimegalencephaly: MR imaging in five children. *Radiology* 1987;165:29-33.
  16. Fusco L, Ferracuti S, Fariello G, Manfredi M, Vigeveno F. Hemimegalencephaly and normal intellectual development. *J Neurol Neurosurg Psychiatry* 1992;55:720-2.
  17. Vigeveno F, Bertini E, Claps D, et al. Hemimegalencephaly: correlation between neuroimaging, neurophysiological data and clinical evolution. *Boll It Lega Epil* 1991;74:157-9.
  18. Thomas JE, Reagan J, Klass DW. Epilepsia partialis continua. A review of 32 cases. *Arch Neurol* 1977;34:266-75.
  19. Botez MI, Brossard L. Epilepsia partialis continua with well-delimited subcortical frontal tumor. *Epilepsia* 1974;15:39-43.
  20. Juul-Jensen P, Denny-Brown D. Epilepsia partialis continua. A clinical, electroencephalographic, and neuropathological study of nine cases. *Arch Neurol* 1966;15:563-78.
  21. Singh BM, Gupta DR, Strobos RJ. Nonketotic hyperglycemia and epilepsy partialis continua. *Arch Neurol* 1973;29:187-90.
  22. Bancaud J, Bonis A, Trottier, Talairach J, Dulac O. L'Epilepsie partielle continue: syndrome et maladie. *Rev Neurol (Paris)* 1982;138:803-14.
  23. Chevrie JJ, Aicardi J, Goutières F. *Epilepsy in childhood mitochondrial encephalomyopathies*. In: Wolf P, Dam M, Janz D, Dreifuss FE, eds. *Advances in Epileptology*. Vol 16. New York: Raven Press, 1987:181-4.
  24. Rasmussen T, Olszewski J, Lloyd-Smith D. Focal seizures due to chronic localized encephalitis. *Neurology* 1958;8:435-45.
  25. Bancaud J. Kojewnikow's syndrome (epilepsia partialis continua) in children. In: Roger J, Dravet C, Bureau M, Dreifuss FE, Wolf P, eds. *Epileptic syndromes in infancy, childhood and adolescence*. London-Paris: John Libbey Eurotext, 1985:286-98.
  26. Verhagen WIM, Renier WO, ter Laak H, Jaspar HJJ, Gabreels FJM. Anomalies of the cerebral cortex in a case of epilepsy partialis continua. *Epilepsia* 1988;29:57-62.
  27. Piatt JH, Hwang PA, Armstrong DC, Becker LE, Hoffman HJ. Chronic focal encephalitis (Rasmussen syndrome): six cases. *Epilepsia* 1988;29:268-79.

## Relative Hypoxia of the Extremities in Fabry Disease

**Masumi Inagaki, MD, Kousaku Ohno, MD, Ichiro Hisatome, MD,  
Yasushi Tanaka, MD and Kenzo Takeshita, MD**

---

*A purine degradation study, thermography and near infrared spectroscopy of the extremities were performed on 2 young males with Fabry disease and 2 healthy controls. Two-minute semi-ischemic forearm exercise caused a distinct increase in lactate in all subjects, but venous hypoxanthine and ammonia were greatly increased only in the Fabry patients, suggesting a relatively hypoxic state of the extremities. Limb thermograms of the patients revealed glove and stocking type disturbance at rest. Poor recovery of the skin temperature of the hands and forearms after exercise was observed in the patients, but the sharp increase in oxygenated hemoglobin after total ischemia was found to be normal on near infrared spectroscopy. Neurotropin showed an analgesic effect, i.e. a strong and selective heat-productive action on the painful lesions, and suppressed the hypoxanthine level after exercise in 1 patient. Although the pathophysiology of the pain in Fabry disease has not been clearly elucidated, a relatively hypoxic state with peripheral hypothermia might play an important role in triggering of a painful attack or chronic burning paresthesia. Key words: Fabry disease, hypoxanthine, ischemia, near infrared spectroscopy, neurotropin, thermography.*

*Inagaki M, Ohno K, Hisatome I, Tanaka Y, Takeshita K.  
Relative hypoxia of the extremities in Fabry disease.  
Brain Dev 1992;14: 328-33*

---

Fabry disease is an inborn error of glycosphingolipid metabolism resulting from a deficiency of a lysosomal enzyme,  $\alpha$ -galactosidase A. Progressive lipid accumulation

leads to narrowing and occlusion of the vascular lumen, and eventually results in ischemia and infarction in various organs of the body. The thickened walls of cutaneous and

intramuscular blood vessels have been well demonstrated microscopically [1-3]. However, there have been few reports regarding the actual ischemic state of the extremities in Fabry disease except for of a hemodynamic study [4], which revealed reduced blood flow in the peripheral limbs, and a vasoconstrictive process in vessels of the skin and skeletal muscles. In this study, we demonstrated relative hypoxia of the extremities in 2 young males with Fabry acroparesthesia, through estimation of purine metabolites after a forearm exercise test. We also demonstrated the peripheral hypothermia on thermography in the patients at rest and after ischemic exercise, but normal elevation of blood flow after a total ischemic test was observed on near infrared spectroscopy. The effect of neurotropin, a possible analgesic for the chronic burning pain in Fabry disease [5], on the peripheral hypoxia in Fabry patients was also discussed.

## SUBJECTS AND METHODS

### Subjects

Two patients with Fabry disease and 2 controls participated in this study. The clinical features of the 2 siblings with Fabry disease were reported elsewhere [5]. Their ages at the time of examination were 16 and 13 years, respectively (Fabry 1 and 2). Echocardiography revealed a mild mitral valve prolapse in Fabry 2. However, the results as to sensory tests and gross motor function were neurologically normal. Both had a burning pain of the toes induced by exercise. The fingers and toes themselves felt rather cool, but there was no Raynaud-like phenomenon. Combination therapy with neurotropin (16 units/day) and carbamazepine (600 mg/day) almost completely relieved the burning paresthesia in Fabry 1 with few side effects. Fabry 2 had orally taken a dose of neurotropin (4 units) only when an episodic painful attack on the soles occurred. The controls were 2 healthy young males of 13 and 11 years old (Control 1 and 2). Informed consent was obtained from each of the subjects and their parents before the study.

### Semi-ischemic forearm exercise

The procedure for semi-ischemia was the same as previous-

ly reported [6, 7]. Forearm exercise involved squeezing a hand dynamometer as powerfully as possible for 2 minutes with one second intervals. We collected venous blood specimens from the antecubital vein to measure plasma ammonia, blood lactate and plasma hypoxanthine before exercise, and 2, 6, 12, 30 and 60 minutes after the exercise had started. Lactate and ammonia were measured enzymatically as soon as possible. Hypoxanthine was separated and measured by high-performance liquid chromatography using a HPLC system (Waters, USA) with an Inertsil ODS-2 reversed phase column (Gasukuro Kogyo, Japan). Purine degradation analysis in Fabry 2 was carried out on two occasions: before administration and 2 weeks after treatment with oral neurotropin (4 units/day).

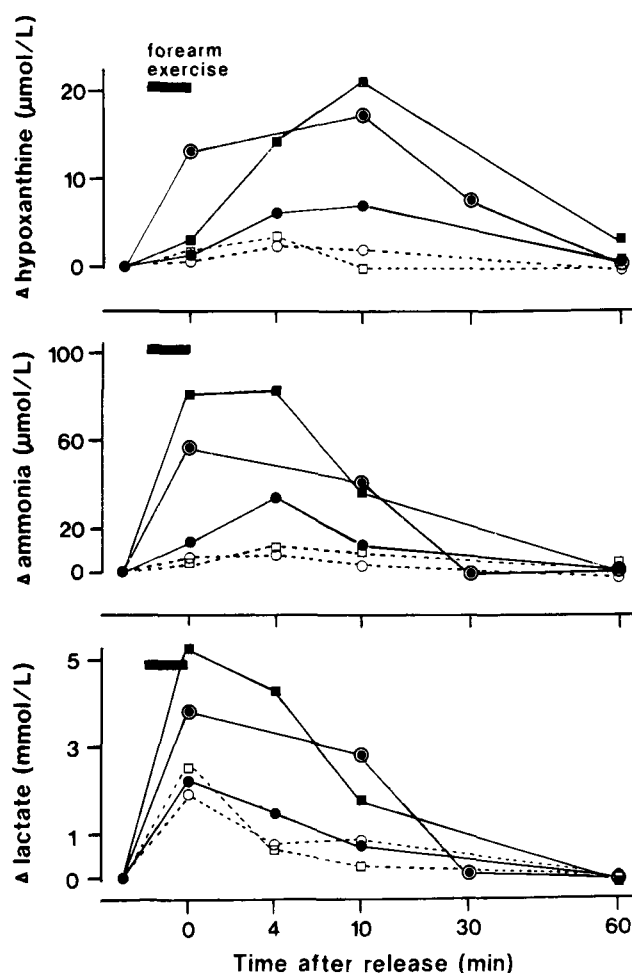


Fig 1 Increases in the venous hypoxanthine, ammonia and lactate concentrations after semi-ischemic forearm exercise. Each point represents an incremental increase above the preexercise level. The dotted lines represent the changes of the values in the control subjects (open squares, control 1; open circles, control 2). In the Fabry patients, venous hypoxanthine and ammonia were greatly increased by exercise (solid squares, Fabry 1; painted circles, Fabry 2), and neurotropin treatment suppressed the hypoxanthine levels (closed circles, Fabry 2).

From the Division of Child Neurology (MI, KO, KT), Institute of Neurological Sciences, and Department of Internal Medicine (IH, YT), Faculty of Medicine, Tottori University, Yonago.

Received for publication: May 22, 1992.

Accepted for publication: July 16, 1992.

Correspondence address: Dr. Masumi Inagaki, Division of Child Neurology, Institute of Neurological Sciences, Faculty of Medicine, Tottori University, Nishimachi 86, Yonago 683, Japan.

### Thermographical analysis

After a subject had rested quietly in the supine position for half an hour, the skin temperature of the arms, feet and head was determined in a windless room, which was maintained at a temperature of 25 to 26°C and a humidity level of 50%, according to the technical guidelines of the American Academy of Thermology with modifications [8]. A digital infrared thermograph (Infraeye 160; Fujitsu, Japan) providing a real-time display of images was used. The host computer (NEC PC9801 Vm2, Japan) provided graphic information, with the color spectrum of yellow to red representing the warmer and that of green to blue the cooler temperatures. The fronts of the ankles and knees, and the backs of the hands were displayed. Selected images were recorded on photographic film from a cathode ray tube display.

We examined thermographically the changes in skin temperature before and after a semi-ischemic forearm exercise test. Changes in the skin temperature of the hands and legs after neurotropin injection (8 units) were also evaluated in all subjects. When Fabry 1 had colicky pain of the toes due to skipping a dose of neurotropin, thermal changes after venous injection of 4 units of neurotropin were also monitored continuously for 1 hour.

### Near infrared spectroscopy

We used a commercially available prototype spectrophotometer (NIR 1000; Hamamatsu Photonics Co, Japan) [9]. The technique used depends on absorption by the chromophores, oxyhemoglobin (HbO<sub>2</sub>) and deoxyhemoglobin (Hb), of near infrared light transmitted through the tissue. In this study near infrared light was directed toward the hands and feet of the subjects. It was applied to the dorsum manus or pedis, transmitted light emerging from the opposite palmar or plantar region being picked up by the NIR 1000. Background light was excluded from the system by a black cloth wrapped around the optodes. The distance between the applied optodes was measured with slide calipers and the path-length was taken to be 5.4 times the interoptode distance, according to the previous report [10].

Near infrared spectroscopy measurements in the supine position were made every 5 seconds for a resting period of 10 minutes. A sphygmomanometer cuff on the upper arm or calf was inflated to 200 mmHg for 10 minutes and then released, measurements then being made until resting value had been reattained. A graphic display of the changes in the HbO<sub>2</sub> and Hb concentrations, and the oxidized form of cytochrome a, a<sup>3</sup> (CytO<sub>2</sub>-Cyt), could be seen in real time, selected images being recorded.

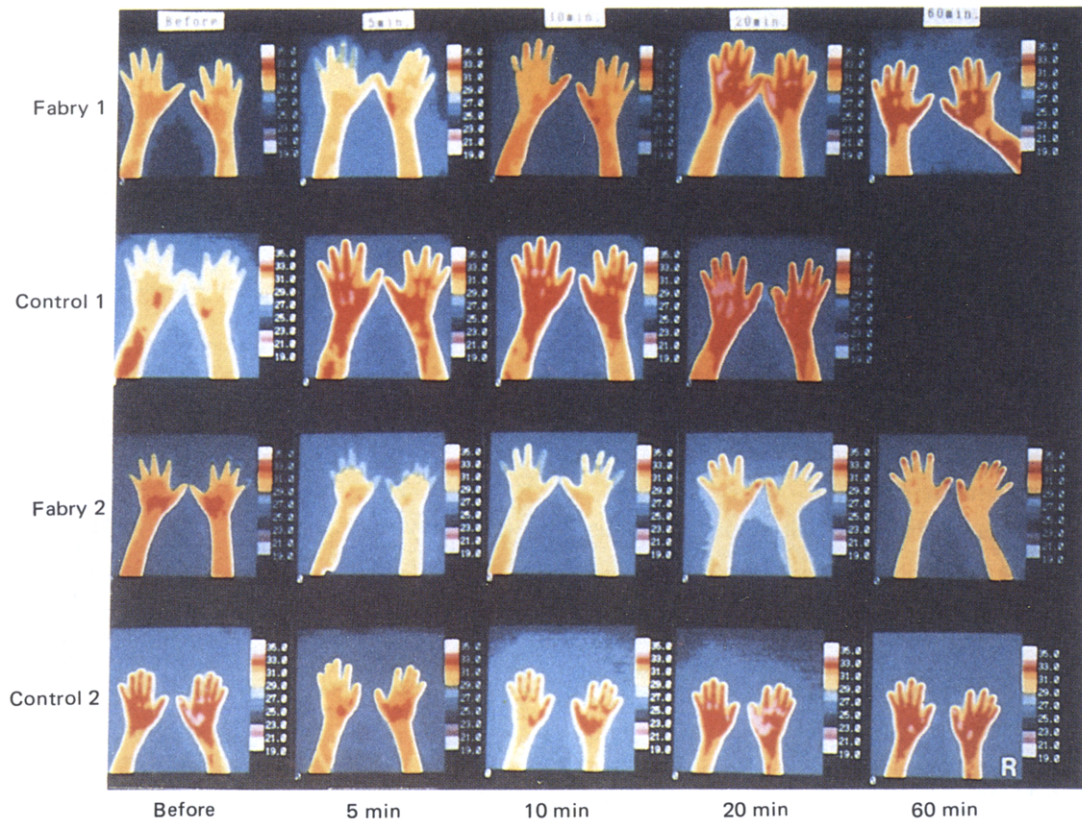


Fig 2 Thermographical changes in the hands during semi-ischemic exercise. Recovery of the skin temperature was seen 5 to 10 minutes after exercise in the controls, but was slightly delayed in the Fabry patients.

## RESULTS

### Semi-ischemic forearm exercise

The respective baseline values of blood lactate, plasma ammonia and plasma hypoxanthine were 1.08 mmol/L, 13.5  $\mu\text{mol/L}$  and 2.72  $\mu\text{mol/L}$  in Fabry 1, 0.73 mmol/L, 14.7  $\mu\text{mol/L}$  and 3.67  $\mu\text{mol/L}$  in Fabry 2, 1.21 mmol/L, 24.7  $\mu\text{mol/L}$  and 3.52  $\mu\text{mol/L}$  in control 1, and 1.16 mmol/L, 24.1  $\mu\text{mol/L}$  and 1.98  $\mu\text{mol/L}$  in control 2. There was no significant difference in the basal values between Fabry patients and controls. Fig 1 shows the changes in hypoxanthine, ammonia and lactate from the basal concentrations at rest in the present subjects. Two-min handgrip exercise caused a distinct increase in venous lactate in all subjects studied. In the Fabry patients, venous hypoxanthine and ammonia were greatly increased by semi-ischemic forearm exercise. In contrast to the sharp elevation of ammonia, the level of hypoxanthine in the patients increased gradually, the highest point being reached at 10 minutes after release. Two weeks after oral treatment with neurotropin in Fabry 2, the excess responses of hypoxanthine and ammonia were suppressed, yet remained higher than the control levels.

### Thermographical analysis

The skin temperature of the hands at rest in all subjects is presented in Figs 2–4. In the Fabry patients, the temperature of the fingertips of the hands and feet was especially low, being 24 to 25°C, in contrast to the control temperatures of 30 to 31°C. The face and head skin temperature in the Fabry patients was almost the same as in the controls (data not shown). The recovery of the skin temperature of the hands was seen 5 to 10 minutes after semi-ischemic forearm exercise in the controls, but was slightly delayed in the Fabry patients (Fig 2). Total forearm ischemia for 30 minutes caused mild tingling paresthesia in Fabry 2, but there were no complaints from Fabry 1.

A marked increase in skin temperature of the hands i.e., from 25°C to 30°C in Fabry 1 and from 24°C to 27°C in Fabry 2, respectively was observed 60 min after neurotropin injection (Fig 3). It was maintained for about 1 hour in both patients. On the other hand, a slight and transient thermal increase was seen in control 2, the change in control 1 being minimal. When Fabry 1 had episodic pain localized in the toes, there was no change in the pain after injection of a saline solution. However, intravenous injection of neurotropin brought alleviation in 30 minutes, a significant thermal increase in the feet

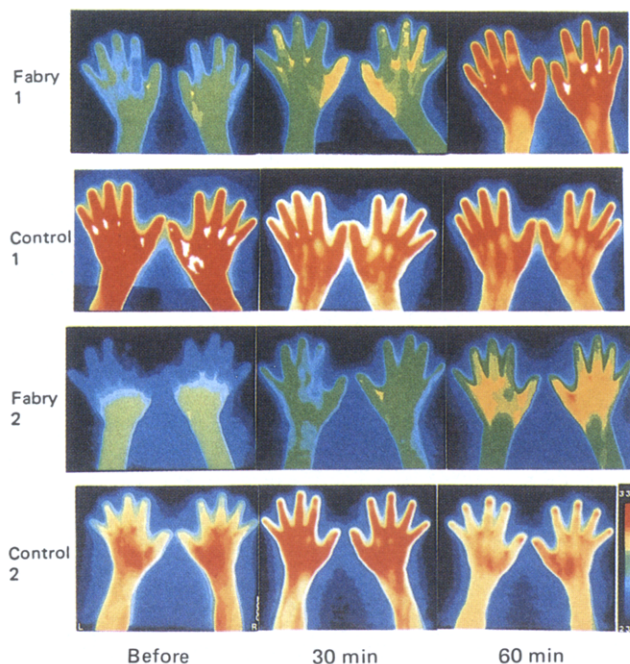


Fig 3 Changes in the skin temperature of the hands after venous injection of neurotropin (8 units). Before injection, the skin temperature of the patients was low, but a marked increase, as indicated by the color change from blue to red, was observed after the injection. The changes were little in the controls.

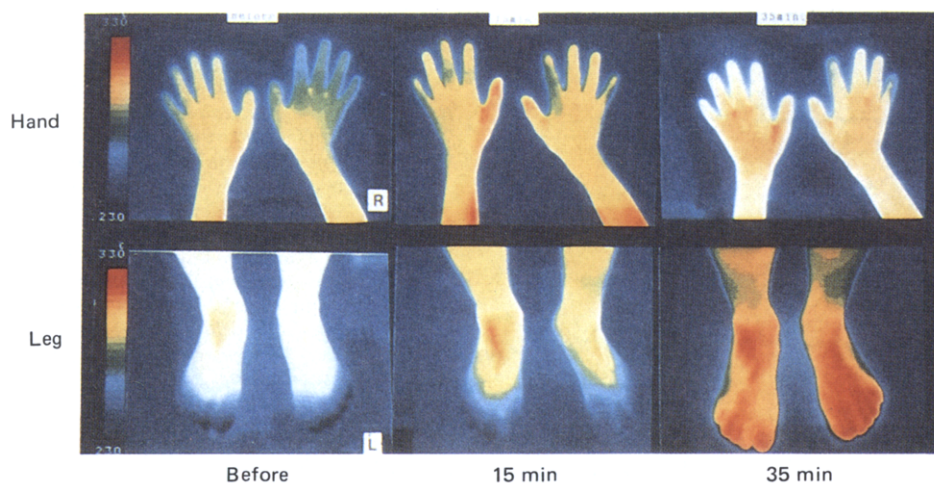


Fig 4 Changes in the skin temperature of the hands and feet after venous injection of neurotropin in Fabry 1 with painful attack in the toes. Neurotropin showed an analgesic effect with a heat productive action on the painful lesions of the feet at 35 minutes after injection, however, change of the skin temperature of the hands was minimal.

rather than the hands being observed at the same time (Fig 4).

### Near infrared spectroscopy

Changes in HbO<sub>2</sub> and Hb of the hands in Fabry 2 are shown in Fig 5. During a period of arterial occlusion of the arm of calf, HbO<sub>2</sub> fell sharply and Hb increased. A rapid increase in hemoglobin oxygenation, which indicated arterial blood inflow, was observed following release of the cuff. The process of O<sub>2</sub> consumption during arterial occlusion and the increase in HbO<sub>2</sub> after release from total ischemia were the same in the normal subjects, as in the patients. A mild increase in total tissue hemoglobin and little change in the oxidized form of cytochrome a, a<sup>3</sup> (CytO<sub>2</sub>-Cyt) were also observed following cuff release in all subjects.

### DISCUSSION

Ischemic exercise increases purine metabolites without changes in lactate in some patients with glycogen storage disease, and these phenomena result from a defect in intramuscular glycogenolysis or glycolysis and excess purine degradation via activation of the purine nucleotide cycle, i.e., absolute disturbance of the ATP supply in ischemic exercising muscles [11]. It has also been re-

ported that excess purine catabolism, as a marker for cell energy crisis, occurred in exercising muscles of patients with idiopathic hypoparathyroidism or carnitine palmityl-transferase deficiency [12, 13].

Excess purine degradation with a normal response of lactate was observed after semi-ischemic forearm exercise in our patients, whereas control subjects who had exercised at the same level showed little change in the hypoxanthine level. Abnormal elevation of hypoxanthine in the present patients would reflect "relative" disturbance of the ATP supply, i.e., the demand for ATP exceeded the ATP supply via anaerobic glycolysis, as seen in a patient with hyperthyroidism [7]. So our Fabry siblings with acroparesthesia would have experienced a disturbance of aerobic energy synthesis during the exercise. This may have been due to the relative hypoxia in exercising muscles of the extremities.

Thermography has been shown to be a non-invasive and useful method for monitoring the skin temperature and near surface blood circulation in the extremities, which are chiefly controlled by the sympathetic nervous system [8]. Limb thermograms of the present patients revealed glove and stocking type abnormality at rest, although they showed neither peripheral sensory disturbance nor weakness. Seino and others [4] found, on pneumoplethysmography, that the finger and toe blood

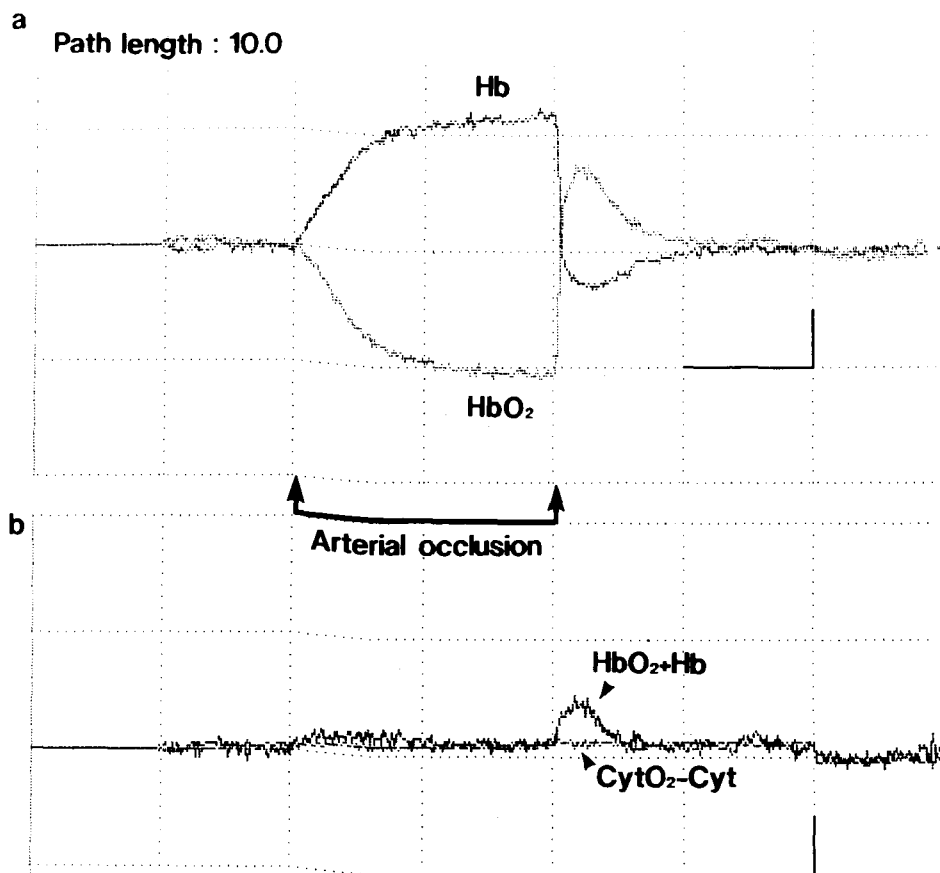


Fig 5 Changes in HbO<sub>2</sub>, Hb and cytochrome a, a<sup>3</sup>, before and after total forearm ischemia in Fabry 2, on near infrared spectroscopy. HbO<sub>2</sub> fell during the ischemia and rose rapidly following release of the occlusion (a). A mild increase in total tissue hemoglobin, lasting for about 3 minutes, and little change in cytochrome were observed (b). The process of O<sub>2</sub> consumption during arterial occlusion and reverse increase in HbO<sub>2</sub> after release from total ischemia were the same in the controls' arms and legs, as in the Fabry patients. Path length = 10.0. The horizontal and vertical bars represent 5 min and 25 μMol/L, respectively.

flow in Fabry disease was significantly less than in normal subjects. They suggested the possibility of a latent enhanced sympathoadrenal discharge.

Poor recovery of skin temperature of the hands after semi-ischemic forearm exercise was observed in our patients, but the sharp increase in oxygenated hemoglobin observed on near infrared spectroscopy indicated normal arterial blood inflow after total ischemia (post-ischemic hyperemia) to the peripheral tissue, with a possibly normal vasomotor mechanism [10]. The hypothermia after exercise in the Fabry patients may reflect a disturbance of the energy synthesis in the peripheral tissue.

Neurotropin, a safe, nonprotein agent, has been used as not only an analgesic but also a neuroimmunomodulator, and oral or venous administration of neurotropin has been reported to have an analgesic effect in patients with chronic pain, such as lumbar disc herniation and in patients with Fabry disease [5, 14]. Neurotropin injection markedly increased the skin temperature in the hands and feet of both patients under study, and reduced the cold areas which could be seen on thermography before administration, in contrast to little effect on those of controls. Neurotropin showed an analgesic effect, i.e., a strong and selective heat-productive effect on the painful lesions in Fabry 1, and suppressed the hypoxanthine levels after semi-ischemic exercise in Fabry 2. The antinociceptive action of neurotropin has not been clarified yet, however, Motomura et al suspected that the analgesic mechanisms of neurotropin in orthopedic pain involve the correction of the local hypoxic conditions and musculo-vascular spasms [14]. Hata et al and Kita et al proposed the mediation of noradrenergic and GABAergic systems from the animal experiments [15, 16]. In our patients, neurotropin may have exerted an analgesic effect through the improvement of peripheral hypothermia or hypoperfusion. Although the pathophysiology of the pain in Fabry disease has not been clearly elucidated to date, a relatively hypoxic state with peripheral hypothermia might play an important role in triggering of a painful attack or chronic burning paresthesia.

#### ACKNOWLEDGMENTS

The neurotropin® solution was provided by Nippon Zoki Pharmaceutical Co., Ltd., Osaka, Japan. The authors wish to thank Miss Mariko Ohta for her secretarial assistance. This study was supported in part by Hamamatsu Photonics KK., Japan.

#### REFERENCES

1. Desnick RJ, Bishop DF. Fabry disease:  $\alpha$ -galactosidase deficiency. In: Scriver CR, Beaudet AL, Sly WS, Valle D, eds. *The metabolic basis of inherited disease*. 6th ed. New York: McGraw-Hill 1989:1751-96.
2. Breathnach SM, Black MM, Wallace HJ. Anderson-Fabry disease: characteristic ultrastructural features in cutaneous blood vessels in a 1 year old boy. *By J Dermatol* 1980;103:81-4.
3. Tomé FMS, Fardeau M, Leoir G. Ultrastructure of muscle and sensory nerve in Fabry's disease. *Acta Neuropathol (Ber)* 1977;38:187-94.
4. Seino Y, Vyden JK, Philippart M, Rose HB, Nagasawa K. Peripheral hemodynamics in patients with Fabry's disease. *Am Heart J* 1983;105:783-7.
5. Inagaki M, Ohno K, Ohta S, Sakuraba H, Takeshita K. Relief of chronic burning pain in Fabry disease with neurotropin. *Pediatr Neurol* 1990;6:211-3.
6. Mineo I, Kono N, Shimizu T, Sumi S, Nonaka K, Tarui S. A comparative study on glucagon effect between McArdle disease and Tarui disease. *Muscle Nerve* 1984;7:552-9.
7. Hisatome I, Ishiko R, Takeuchi T, et al. Excess purine degradation in skeletal muscle with hyperthyroidism. *Muscle Nerve* 1990;13:558-9.
8. Fujimasa I, Mabuchi K, Chinzei T, Abe Y, Hyakuna Y, Atsumi K. Research on standardization for taking infrared thermograms in a clinic and selection of differential diagnosis oriented standard thermal images (in Japanese). *Biomed Therm* 1985;5:33-5.
9. Edwards AD, Wyatt JS, Richardson C, Delpy DT, Cope M, Reynolds EOR. Cotside measurement of cerebral blood flow in ill newborn infants by near infrared spectroscopy. *Lancet* 1988;ii:770-1.
10. Cheatle TR, Potter LA, Cope M, Delpy DT, Coleridge Smith PD, Scurr JH. Near-infrared spectroscopy in peripheral vascular disease. *Br J Surg* 1991;78:405-8.
11. Mineo I, Kono N, Shimizu T, et al. Excess purine degradation in exercising muscles of patients with glycogen storage disease types V and VII. *J Clin Invest* 1985;76:556-60.
12. Hara N, Mineo I, Kono N, et al. Enhanced release of ammonia and hypoxanthine from exercising muscles in patients with idiopathic hypoparathyroidism. *Muscle Nerve* 1987;10:599-602.
13. Bertorini TE, Shively V, Taylor B, Palmieri GMA, Fox IH. ATP degradation products after ischemic exercise: hereditary lack of phosphorylase or carnitine palmyltransferase. *Neurology* 1985;35:1355-7.
14. Motomura K, Mabuchi K, Chinzei T, et al. Thermographic evaluation of therapeutic effect of "neurotropin special" for orthopedic pain (in Japanese). *Biomed Therm* 1985;5:49-52.
15. Hata T, Kita T, Itoh E, Oyama R, Kawabata A. Mechanism of the analgesic effect of neurotropin. *Jpn J Pharmacol* 1988;48:165-73.
16. Kita T, Hata T, Iida J, Yoneda R, Ishida S. Decrease in pain threshold in SART stressed mice. *Jpn J Pharmacol* 1979;29:479-82.