

Conscious visual abilities in a patient with early bilateral occipital damage

Deborah Giaschi* PhD, Associate Professor, Department of Ophthalmology, University of British Columbia (UBC);
James E Jan MD FRCP(C), Professor;
Bruce Bjornson MD FRCP(C), Clinical Assistant Professor, Department of Pediatrics, UBC;
Simon Au Young MSc, Research Assistant, Department of Pediatrics, British Columbia's Children's Hospital;
Matthew Tata MSc, Graduate Student, Department of Psychology, UBC;
Christopher J Lyons MB BSc FRCS(C), Associate Professor, Department of Ophthalmology, UBC, Vancouver, British Columbia, Canada.
William V Good MD, Clinician-Scientist, Smith-Kettlewell Eye Research Institute, San Francisco, CA, USA.
Peter KH Wong BEng MD FRCP(C), Professor, Department of Paediatrics, UBC, Vancouver, British Columbia, Canada.

**Correspondence to first author at Department of Ophthalmology, BC's Children's Hospital, Room A146, 4480 Oak Street, Vancouver, BC, V6H 3V4, Canada.
 E-mail: giaschi@interchange.ubc.ca*

A 21-year-old male presented with occipital lobes that were extensively damaged by bilateral infarcts present at birth. The absence of the striate cortex was confirmed with anatomic and functional MRI and high-resolution EEG. His cortical visual impairment was severe, but he retained a remarkable ability to see fast-moving stimuli. Horizontal optokinetic nystagmus could be elicited from either eye. Resolution acuity was close to normal providing the patient was allowed to move his head and eyes. The direction of motion in random-dot patterns could be discriminated with perfect accuracy at speeds above 2 deg/s, and the patient reported that he could 'see' the motion at fast but not at slow speeds. This conscious residual vision for motion is known as Riddoch's phenomenon, but it has never been reported in the complete absence of the striate cortex. Functional neuroimaging revealed activation that was outside the motion-responsive regions of the extrastriate cortex. This case demonstrates remarkable plasticity in the human visual system and may have implications for understanding the functional organization of the motion pathways.

Damage to the striate cortex (Brodmann area 17) produces regions of blindness in the visual field. The extent and density of the visual field defects, measured with standard perimetry, reflect the site and completeness of the lesion. Conscious vision, therefore, is classically believed to require intact striate cortex. Three decades ago, it was noted that humans with damage to the striate cortex may demonstrate residual visual functions within their corresponding clinically blind visual fields, but with no acknowledged awareness (Pöppel et al. 1973, Weiskrantz et al. 1974). Weiskrantz and his colleagues termed this phenomenon 'blindsight'. When forced to guess, a variety of visual capacities have been demonstrated, including localization of targets by saccadic eye movements; pointing or reaching; detection of static, flickering, or moving targets; and discrimination of stimulus orientation, direction of motion, colour, or simple shapes (reviewed in Weiskrantz 1996, Stoerig and Cowey 1997). More recently pupillary reflexes have been used to indicate residual processing of visual stimuli in the absence of awareness (Weiskrantz et al. 1998). The possibility that blindsight could be caused by light scattered into the intact part of the visual field has been discussed (Campion et al. 1983), but this artifact was controlled for in more recent studies (reviewed in Weiskrantz 1996).

There are a number of retinal projections that could mediate vision in the absence of the striate cortex (reviewed in Stoerig and Cowey 1997). Two projections in particular have

been implicated in blindsight (Fig. 1): the projection from the superior colliculus to ipsilesional extrastriate cortex via the inferior pulvinar and the direct projection from the interlaminar regions of dorsal lateral geniculate nucleus to ipsilesional extrastriate cortical areas (Covey and Stoerig 1991). It has also been suggested that with unilateral lesions the intact contralesional hemisphere mediates blindsight via transcallosal or intertectal connections (Baseler et al. 1999, Ptito et al. 1999), particularly in cases of surgical hemispherectomy (Wessinger et al. 1996, Bittar et al. 1999). Alternatively, blindsight abilities have been attributed to intact areas of damaged striate cortex in the lesioned hemisphere (Campion et al. 1983, Fendrich et al. 1992), but there is convincing evidence that this is not so in all cases (Weiskrantz 1996, Stoerig et al. 1998, Kleiser et al. 2001). In support of a non-geniculostriate basis for blindsight, functional neuroimaging studies found activation in the superior colliculus, pulvinar, and extra-striate cortical areas V3/V3a and V5 by stimuli presented in the blind visual field (Sahraie et al. 1997, Stoerig et al. 1998, Bittar et al. 1999, Ptito et al. 1999).

Regardless of the specific pathways involved, blindsight implies that conscious awareness of visual stimuli requires an intact striate cortex and that cortical activity in other visual areas cannot sustain conscious vision. Motion perception may be the exception because some degree of awareness for rapidly moving stimuli has been reported (reviewed in Zeki and ffytche 1998). This residual vision for motion is also known as Riddoch's phenomenon after the British neurologist who first characterized it (Riddoch 1917). Riddoch examined the visual abilities of 10 soldiers with visual field defects from occipital wounds. Five of these patients could detect the presence of motion within their blind fields without being able to characterize the other attributes of the stimulus. There are several more recent reports of patients with conscious perception for various types of motion stimuli on detection (Blythe et al. 1987, Azzopardi and Covey 2001), speed discrimination (Barbur et al. 1980, Mestre et al. 1992, Morland et al. 1999), and direction discrimination (Perenin 1991, Mestre et al. 1992, Benson et al. 1998, Schoenfeld et al. 2002) tasks. Thus, it seems that activity in brain regions outside of striate cortex must be sufficient for mediating awareness of motion.

Blindsight refers to those functions occurring with no conscious awareness, but in residual vision some conscious perception is registered. Blindsight and residual vision may be expressions of similar neural mechanisms with earlier damage leading to more awareness (Blythe et al. 1987). Alternatively, blindsight and residual vision may represent independent processes (Weiskrantz et al. 1995). Residual motion perception has been attributed specifically to cortical area V5 based on the pattern of activation by moving stimuli in blind regions of the visual field (positron emission tomography: Barbur et al. 1993, electroencephalogram [EEG]: ffytche et al. 1996, magnetoencephalography: Holliday et al. 1997, functional magnetic resonance imaging [MRI]: Zeki and ffytche 1998, Schoenfeld et al. 2002) and the lack of residual motion perception in persons with a hemispherectomy who lack V5 (Perenin 1991, Azzopardi et al. 2001). One preliminary study reported a shift in activation from the superior colliculus and medial prefrontal cortex when the patient was unaware of the moving stimuli, to prestriate and dorsolateral prefrontal cortex when the patient was aware of

the moving stimuli (Sahraie et al. 1997).

In all previous cases of residual motion perception, however, there was at least some intact striate cortex in the ipsilesional or the contralesional hemisphere which could be responsible for residual visual abilities. Previous reports on patients with total bilateral destruction of area 17 indicate total permanent visual loss (Brindley et al. 1969, Celesia et al. 1991). In a study of nine patients with cortical visual impairment due to bilateral occipital lesions, residual motion perception was observed in only four patients (Celesia et al. 1991). Each of these patients had functional remnants of area 17 confirmed by CT and SPECT. The remaining five patients with no residual vision had more extensive lesions and no functionally intact regions. It was concluded that the extrageniculostriate visual system is functional in humans but is not capable of providing conscious visual perception. A recent review of blindsight results in human and non-human primates concluded that 'we must await an unequivocal demonstration of conscious vision in the absence of all striate cortex' to resolve this issue (Stoerig and Covey 1997, p 555). Here we present a case that we believe provides such a demonstration.

This case report is of a young adult whose occipital lobes were extensively damaged by infarction present at birth. His case study at age 6 years has previously been published (Jan et al. 1986). At the age of 21 years, our patient underwent extensive clinical, psychophysical, electrophysiological, and neuroimaging studies at British Columbia's Children's Hospital over a 3-day period.

Case report

HISTORY

This 21-year-old right-handed white male was born weighing 3 kg at 43.5 weeks, by dates. The pregnancy was complicated by maternal toxemia and weight gain of 21.4 kg. Labour was remarkable for fetal distress; delivery was by high forceps. The infant required initial resuscitation and had seizures within a few hours of birth. Apgar scores were 1, 4, and 9 at 1, 5, and 10 minutes respectively. He required tube feeding for a few days before discharge with a diagnosis of hypoxic brain insult. Subsequently, he has been in generally good health, except for occasional seizures treated with carbamazepine and topiramate. Early developmental milestones were age appropriate; he walked and began to speak words at 1 year of age. However, by 5 months of age his parents suspected visual impairment. At the

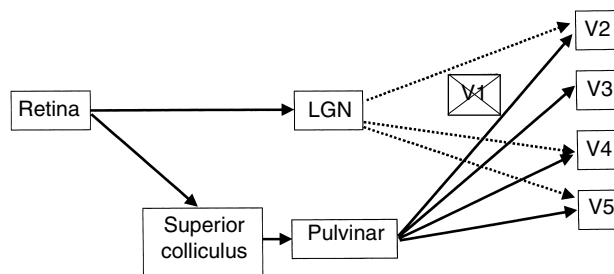


Figure 1: Projections from retina to extrastriate cortex (V2, V3, V4, V5) that survive damage to striate cortex (V1) in macaque monkeys and have been implicated in cases of blindsight in humans. LGN, lateral geniculate nucleus.

age of 2 years, he was referred to the visually impaired program and received a diagnosis of congenital cortical visual impairment (a term that is gradually replacing cortical blindness).

Electroretinograms, most recently obtained at the age of 3 years, were normal. Full-field flash visual evoked potential results obtained at the same time and more recently, however, showed no occipital responses. Repeated EEGs showed a slow posterior background without alpha rhythm, no responses on eye opening and closure, and occasional epileptiform activity.

Psychological testing was done most recently at the age of 11 years. The following verbal scaled scores were obtained on the Wechsler Intelligence Scale for Children-Revised (Wechsler 1971): Information (9), Similarities (8), Arithmetic (8), Vocabulary (7), Comprehension (5). Scores between 9 and 11 are considered average for normally sighted children. Our patient appeared to have good auditory memory skills and somewhat impaired verbal reasoning. He received his education in the mainstream school system, with supportive care for blind students, and although he was noted to have some learning difficulties, he graduated from high school.

His past eye and neurological examinations were repeatedly normal. Recognition acuity was very difficult to measure and he was considered to have minimal 'count-fingers acuity'. He was able to name a few colours; could not read, write, or sign his name; could not recognize himself or others in photographs; and appeared to have minimal visual concepts about his environment and even described his dreams without visual content. With great difficulty, he identified a few simple shapes, by scanning them repeatedly, approximately 5cm away from his eyes. He could appreciate size differences and count coins, without touch, only when they were widely separated. When asked to draw a picture of himself, he needed to touch his face and body. The resulting figure was not recognizable. In school he was taught Braille and learned to use a cane when travelling.

Since childhood, the patient behaved as profoundly visually impaired except for a remarkable ability to perceive rapid movements. He participated in various ball games and running events. He rode a bicycle and safely avoided people,

and parked and moving cars. He also played video games that were based on movement.

CURRENT CLINICAL EXAMINATION

Our patient's neurological examination at 21 years of age was essentially normal. His pupils were equal in size and responded normally to light. Cycloplegic refraction was normal and his fundi showed no abnormalities, apart from slight disc pallor. There was no indication of optic nerve atrophy or hypoplasia. During conversations his head was flexed forward and he made no eye contact. There was no blink response to threat. He could look at near objects without nystagmus, but tended to fixate on a point just below them.

Visual fields were attempted but could not be evaluated with Goldmann perimetry due to poor fixation. Kinetic perimetry with a moving target (Mohn and van Hof-van Duin 1986) suggested extensive field loss, with sparing of the central 10 degrees. When the kinetic perimetry target was held stationary, it could not be detected reliably anywhere within the visual field.

Voluntary saccades were inaccurate and smooth pursuit in all directions showed saccadic intrusions. His voluntary up-gaze was limited. In the right eye, optokinetic nystagmus to a moving stripe pattern was of equal amplitude with nasally and temporally directed movements. In the left eye the temporally directed movements resulted in diminished responses compared to nasally directed movements. Vertical optokinetic nystagmus was essentially absent. Eye movement data are based on inspection.

He had light perception, but his recognition acuity on a Snellen chart could not be determined from any viewing distance. Binocular resolution acuity for gratings was obtained by two experienced examiners using the Teller Acuity Cards (McDonald et al. 1985). The patient quickly located the stripes, while his head and eyes rapidly moved from side to side. The movements became more vigorous when the cards contained higher spatial frequencies. The resolution acuity on several occasions was 9.8 cycles/deg (20/66) at 38cm. This is within normal limits for a 3-year-old child and well above the mean newborn resolution acuity of 0.66 cycles/deg (Salomao and Ventura 1995).

The patient was able to name the colour of large red, green, and blue targets, but he made many errors in color discrimination on the Quantitative Color Vision Test (large stimuli, 16 hue; Precision Vision, IL, USA).

PSYCHOPHYSICS

Motion perception was evaluated with computer-generated movies of random dot patterns. The patterns comprised 1 pixel (0.76 arc min) white dots on a black background (32dots/deg²). The speed of the moving pattern was increased by increasing the distance each dot moved between subsequent frames of the movie. Each movie lasted for 850ms. The patient could verbally report the direction of motion (up or down) with 100% accuracy at speeds between 3.5 and 10 deg/s (Fig. 2). At speeds below 3.5deg/s his accuracy fell to chance performance. He also reported that he could 'see' the motion at the faster speeds but not at the slower speeds. Three adult volunteers (one male, two females) with normal or corrected to normal vision and a mean age of 25 years provided comparison data on this task. Comparison participants could accurately judge the direction of motion for speeds as slow as 0.05deg/s. At

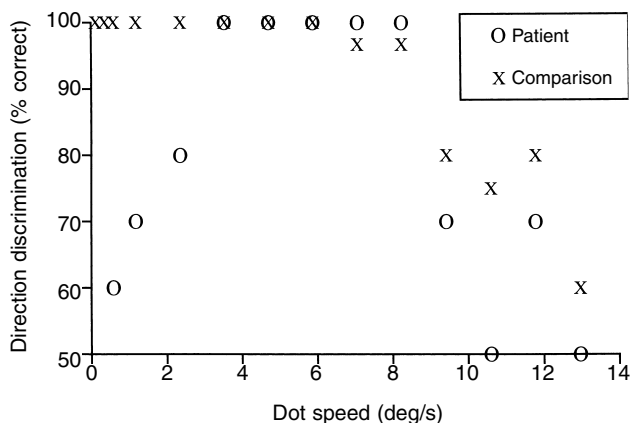


Figure 2: Percentage correct direction discrimination (up or down) for a moving dot pattern as a function of speed. Patient's performance was similar to that of comparison individuals for speeds above 3.5deg/s.

speeds above 10deg/s, the perception of motion in a single direction disappeared and accuracy decreased to chance performance. These results indicate that the patient had normal direction discrimination for moderate to fast motion. He showed no evidence of better than chance guessing at slower speeds when he became unaware of the stimuli.

ELECTROPHYSIOLOGY

Visual evoked potentials were recorded with a Manscan system (Sam Technology, San Francisco, CA) using 128 scalp electrodes applied with an elastic cap. The position of each electrode was applied in accordance to the 10–10 convention, digitized and coregistered with skull landmarks. Binocular

flash (transient EP, 1Hz rate, 2-minute duration) and checkerboard pattern-reversal visual stimuli were used (steady-state, 7.14Hz rate, 2-minute duration, full-field, 4deg square checks, both black–white and red–green check). Due to the patient’s impaired vision, there was difficulty with fixation, and numerous artifacts were present.

No reproducible response was present with flash stimuli after averaging more than 100 flashes. Black–white checkerboard pattern reversal showed a small response that was maximal in the right parietal area. This response was larger with red–green colour reversals. There was a slow positive response component at 81ms maximal over the right parietal cortex, but possibly involving central–parietal and pari-

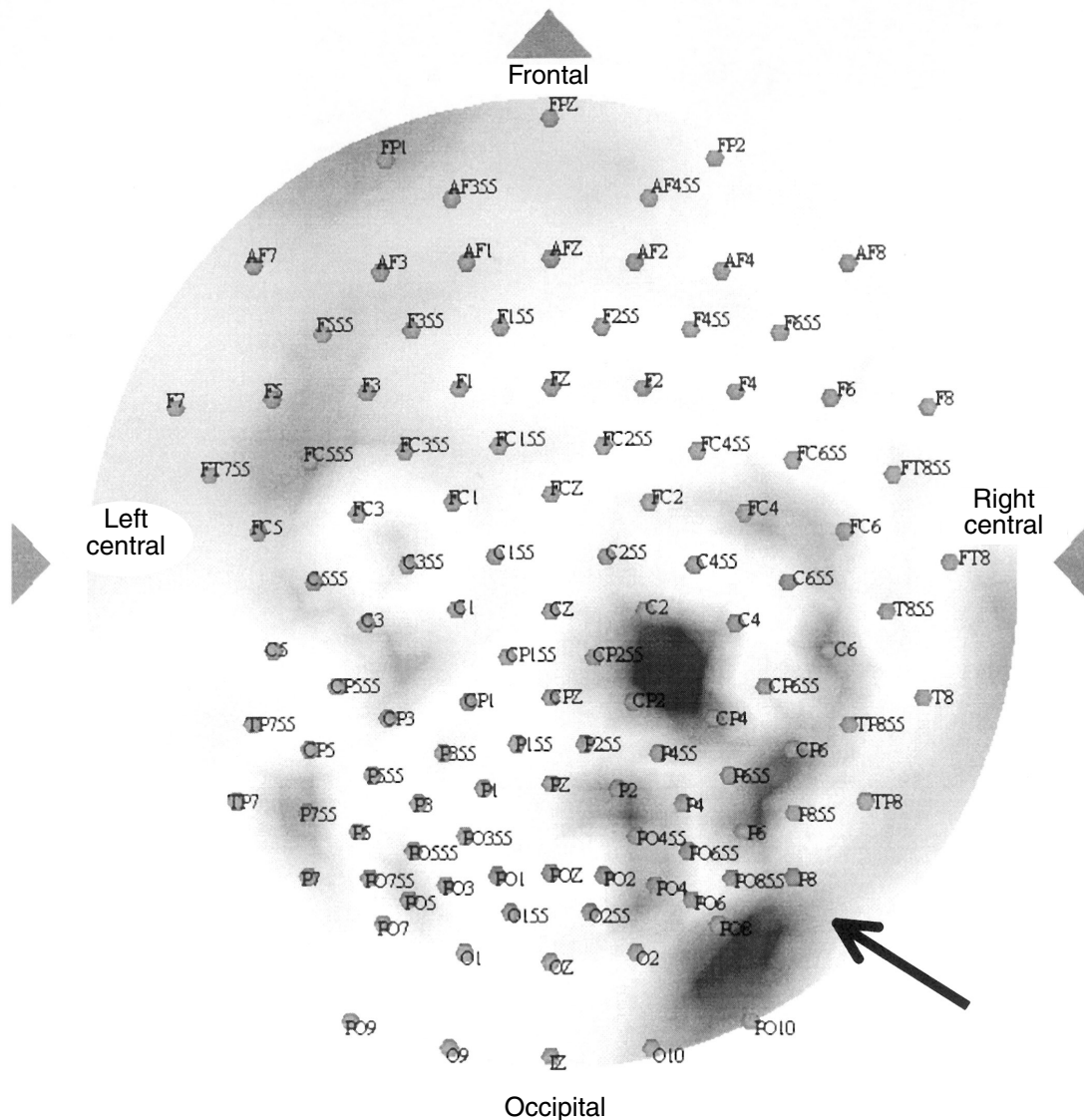


Figure 3: Topographic scalp voltage map at P6 (right parietal) electrode response peak, showing response maxima confined to right parietal and occipital-temporal areas. This probably reflects islands of functional neuronal elements and is consistent with sparing of extrastriate cortex in right relative to left hemisphere (see Figure 4). Normally, response peak should be maximal at midoccipital area, decreasing laterally and anteriorly. Black, positive; white, zero.

etal-occipital areas. There was no response over the occipital region. Figure 3 shows the scalp electrodes superimposed onto a topographic voltage map of the peak positive response at the time of the positive peak at electrode P6 (lateral right parietal). There were several maxima seen on the map rather than a single large peak though all were at the right posterior quadrant.

NEUROIMAGING

Whole brain anatomic and functional MRI data were acquired at 1.5 T on a Picker Edge PowerDrive System. Anatomic MRI showed occipital lobe destruction involving Brodmann areas 17, 18, and 19 in the left hemisphere and areas 17 and most of 18 in the right hemisphere (Fig. 4). Structures in the retinotectal pathway appeared to be intact. An additional area of infarction was identified in the left frontal lobe.

Functional MRI was used to determine the brain regions activated by slow and fast motion. A pattern of high-contrast

white dots was generated on a computer, projected onto a screen at the end of the scanner and viewed in a mirror mounted above the patient's eyes. The dots alternated every 17.5s between fast radial motion (20deg/s) in and out from the centre of the pattern, slow radial motion (2deg/s), and no motion for a total run of 262.5s. The patient reported that he could 'see' the fast motion but not the slow motion or the stationary dots. In a second run, a pattern-reversal (7.14 Hz) high-contrast checkerboard alternated with a steady grey field every 21s for a total of 252s.

Although area V5 appeared to be anatomically intact in the right hemisphere (Fig. 5), no functional activation was observed in this region. Instead, fast radial motion activated regions in right premotor cortex (Brodmann area 6), right medial posterior cingulate (Brodmann area 23), right medial precuneus (Brodmann area 31), left anterior superior temporal gyrus (Brodmann area 38), and left and right posterior superior temporal sulcus (Brodmann area 22; Fig. 6). There was no

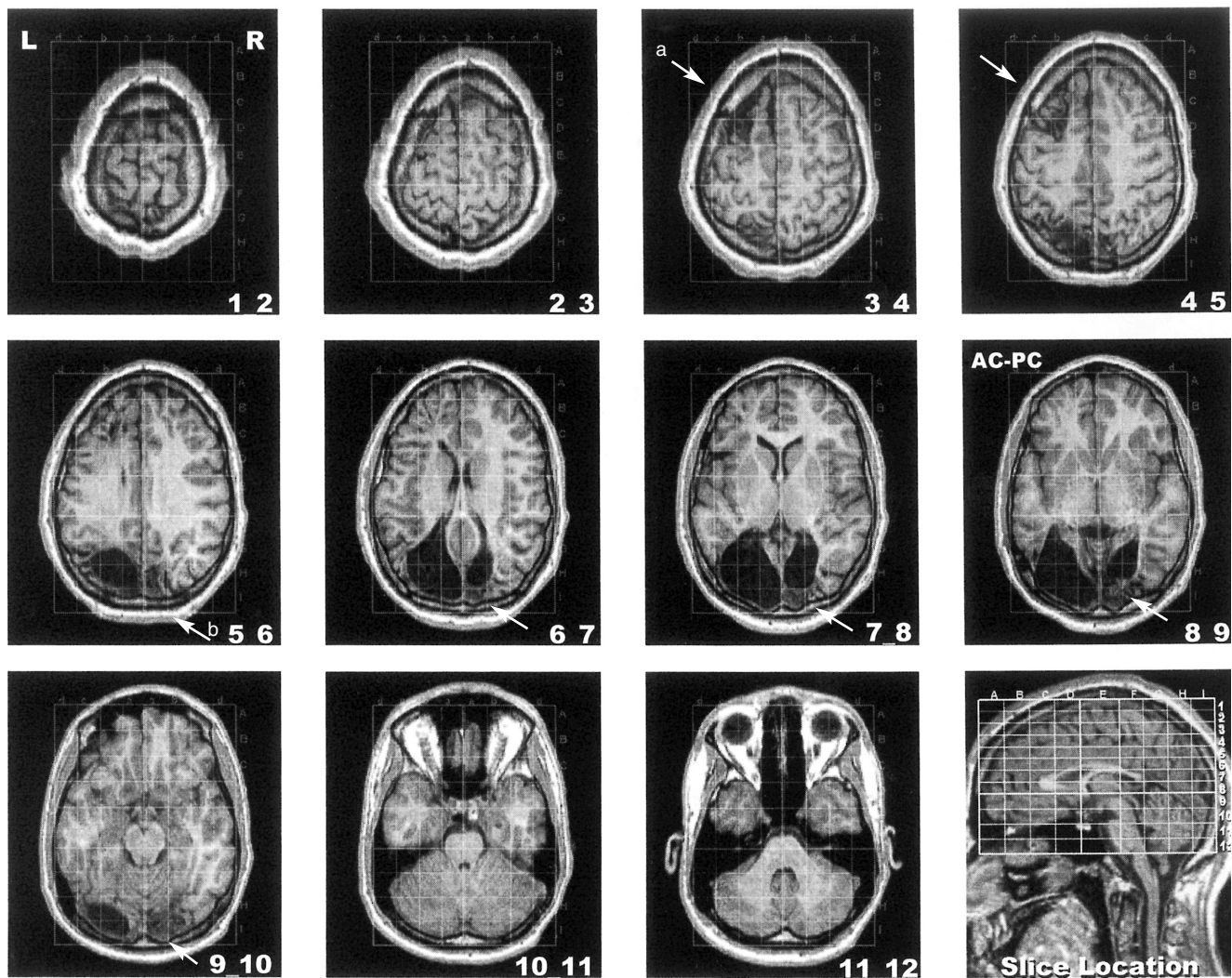


Figure 4: Anatomic MRI images showing extent of patient's lesions. There is (b) extensive gliosis in right occipital horn. Also note (a) smaller infarct involving left frontal lobe. Slice number in each frame corresponds to horizontal section defined in stereotaxic atlas of Talairach and Tournoux (1988).

activation in any cortical region by slow motion or by pattern reversal. These stimuli, however, activated posterior visual areas in comparison participants (Fig. 7). These results demonstrate a lack of functional striate cortex in our patient.

Discussion

Some aspects of this case are consistent with the complete absence of striate cortex. Normal pupillary reactions to light, normal electroretinograms, and normal appearance of the fundi are usually seen in adults with pure cortical blindness (Reese 1954, Bergman, 1957, Nepple et al. 1978) and in children with cortical visual impairment (Good et al. 1994). In non-human primates, occipital lobe ablation results in transsynaptic neuronal degeneration and eventual optic atrophy (Cowey 1974). This is rare in humans (Miller and Newman 1981) and we saw no evidence of transsynaptic degeneration in our patient, but it has been documented in a 9-year-old child with a 4-year history of visual involvement (Sachdev et al. 1990). The absence of a blink response to threat is also consistent with previous reports in humans (ter Braak et al. 1971) and in non-human primates (reviewed in Stoerig and Cowey 1997). Smooth pursuit is often severely abnormal in those with bilateral occipital lesions, particularly when extrastriate areas are damaged as well (Good et al. 1994). It has been suggested that an intact foveal representation in occipital cortex is required for the development of smooth pursuit (Rizzo and Hurtig 1989).

Other aspects of this case are unexpected and may change our understanding of the functional organization of the human visual system.

OPTOKINETIC NYSTAGMUS

The status of optokinetic nystagmus following striate cortex damage is controversial. In animals, the passive subcortical component of optokinetic nystagmus survives removal of striate cortex and shows a strong directional preponderance for movement in the temporal-nasal direction (reviewed in Heide et al. 1990). In humans, this asymmetry is normal in infants and disappears around the 20th postnatal week unless the child has a binocular impairment. Optokinetic nystagmus may be driven by indirect subcortical pathways initially until the cortical pursuit mechanisms mature (reviewed in Preston and Finocchio 1993). Following unilateral striate cortex damage, passive optokinetic nystagmus often persists and the directional asymmetry is observed with large lesions that extend to prestriate regions (Heide et al. 1990). Optokinetic nystagmus is usually absent in cases of complete bilateral cortical visual impairment (Bergman 1957, Brindley et al. 1969, Aldrich et al. 1987, Celesia et al. 1991, Perenin 1991, Dalman et al. 1997). There are a few reports of residual passive optokinetic nystagmus in bilateral cases (ter Braak et al. 1971, Mehdorn 1982, Heide et al. 1990, Celesia et al. 1991). Directional asymmetry was observed in some of these cases, but it could not be attributed exclusively to subcortical structures because the destruction of visual cortex was not complete (Mehdorn 1982, Heide et al. 1990). Smooth pursuit was severely impaired in our patient and destruction of striate cortex was complete, therefore, his residual optokinetic nystagmus is likely to be subcortical in nature. The directional asymmetry in his left eye only is consistent with the total destruction of his left occipital lobe if extrastriate cortical areas, which appear to be intact in his right hemisphere, make a

necessary input to the subcortical optokinetic nystagmus system (Mehdorn 1982, Heide et al. 1990, Perenin 1991).

COLOUR VISION

Residual colour naming has also been observed in children with cortical visual impairment (Jan et al. 1987, Good et al. 1994). Colour vision was not routinely investigated in older studies of individuals with cortical visual impairment. A few persons with unilateral striate cortex damage show good wavelength discrimination on forced-choice psychophysical tasks (Stoerig and Cowey 1992, Brent et al. 1994) and with pupillometric methods (Weiskrantz et al. 1999), but with no conscious perception of colour. Functional MRI studies have revealed activation by coloured stimuli of the superior colliculus (Barbur et al. 1998) and the posterior fusiform gyrus (Goebel et al. 2001). Our patient appears to have poorer colour perception yet better awareness than previous individuals studied, but further investigations are required.

GRATING ACUITY

Previous studies have shown that when the optic radiation and/or striate cortex are damaged by various neurological disorders, resolution acuity is impaired (Hertz et al. 1988, Birch and Bane 1991, Ipata et al. 1994). Resolution acuity, however, is usually less impaired than recognition acuity (Sokol et al. 1983, Mayer et al. 1984, Kushner et al. 1995). It is generally assumed that both resolution and recognition acuity reflect the intactness of the geniculostriate visual system. However, the exact neurological substrate needed for each type of acuity remains unclear. Damage to the geniculostriate system may have a more detrimental effect on recognition acuity that requires foveal retinal mechanisms than on resolution acuity that may use parafoveal or peripheral retinal mechanisms (Mayer et al. 1984).

There is one previous report of a patient with unilateral hemianopia and only slightly reduced resolution acuity of 15.8 cycles/deg in the blind hemifield (20 cycles/deg in the

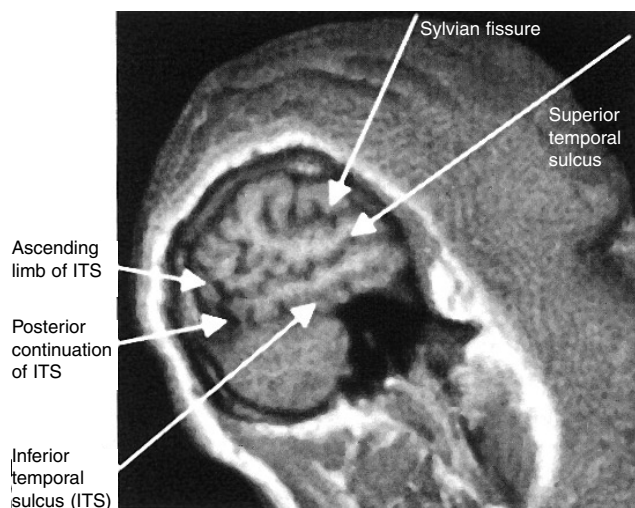


Figure 5: V5 is usually in region of ascending limb of inferior temporal sulcus (ITS) and posterior continuation of ITS (Dumoulin et al. 2000).

normal hemifield; Weiskrantz et al. 1974). This finding and our case report suggest that resolution acuity may be mediated by extra-geniculostriate pathways. These pathways may be particularly sensitive to moving stimuli given that head and eye movements, which create stimulus movement on the retina, were required for our patient to locate the stripes.

MOTION PERCEPTION

As reviewed in the opening section, there are several previous reports of residual direction discrimination, especially for fast motion (Perenin 1991, Mestre et al. 1992, Benson et al. 1998, Schoenfeld et al. 2002), and V5 has been implicated as the source. Residual motion perception is a rare finding in individuals with striate cortex lesions (Barton and Sharpe 1997), and there are conflicting reports of its occurrence within individual patients (Azzopardi and Cowey 2001). This is the first report of such strong motion perception leading to useful vision for locomotion in the total absence of striate cortex. Mestre and colleagues described an individual with cortical visual impairment who could move freely in a cluttered environment and could discriminate different speeds and directions of motion (Mestre et al. 1992). His striate lesions were not complete, however, and his vision was intact in foveal and parafoveal regions. Perenin (1991) described three cases of complete cortical visual impairment, due to bilateral lesions of striate cortex, and accurate direction discrimination on a forced-choice motion task. All three patients described a vague sensation of a shadow moving in front of them, but they could not describe what was moving. Unfortunately, we have no information on the speed tuning of this residual vision, and the completeness of the lesions was not confirmed with MRI and/or functional neuroimaging.

The speed tuning of our patient's residual motion perception is consistent with the suggestion that signals from slow moving stimuli reach V5 via the classical sequential route through striate cortex, while signals from fast moving stimuli reach V5 directly via a fast route from the pulvinar (ffytche et al. 1995, Buchner et al. 1997). This suggestion is compatible with the residual motion processing documented for slow motion in humans with V5 lesions (Hess et al. 1989) and for fast motion in humans with unilateral striate cortex lesions (Barbur et al. 1993). Other aspects of this suggestion remain controversial (Anderson et al. 1996, Azzopardi and Cowey 2001). Functional neuroimaging studies confirm that V5 remains active in the absence of V1 (Holliday et al. 1997, Zeki and ffytche 1998, Goebel et al. 2001), but in these studies V5 was activated by slow as well as fast motion.

The V5 region appeared to be intact in our patient's right hemisphere, but this region was not activated by moving dots at either speed in the functional MRI study. Fast-moving dots produced activation that was outside the early motion-responsive regions of the patient's occipital lobe. Given the congenital nature of his injury, the activation in his brain by fast motion may be due to atypical cortical functional organization. It is also possible, however, that the sites activated are part of the normal network of motion-sensitive cortex. The posterior superior temporal activation, in particular, may be of importance to his residual motion perception. In non-human primates the superior colliculus and pulvinar project to the posterior superior temporal gyrus (superior temporal polysensory area), an area with direction-selective neurons (Gross 1991). In human functional neuroimaging studies, activation has been reported in this area in persons with normal motion processing (Ahlfors et al. 1999, Sunaert et al.

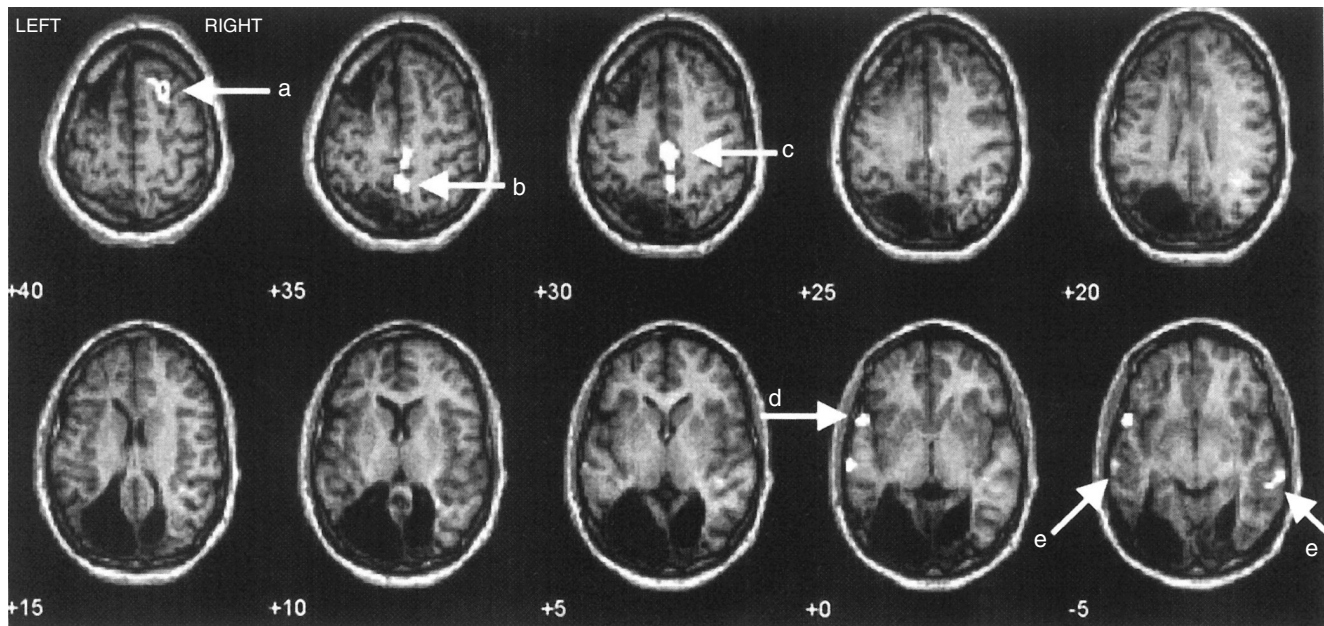


Figure 6: Functional MRI activation maps for patient. White regions are brain areas that were statistically more active ($p < 0.05$ corrected) when dots moved rapidly than when dots did not move. Arrows point to (a) right premotor cortex, (b) right medial precuneus, (c) right medial posterior cingulate, (d) left anterior superior temporal gyrus, and (e) left and right posterior superior temporal sulcus.

1999) and in two patients with residual motion perception (Zeki and ffytche 1998, Vanni et al. 2001).

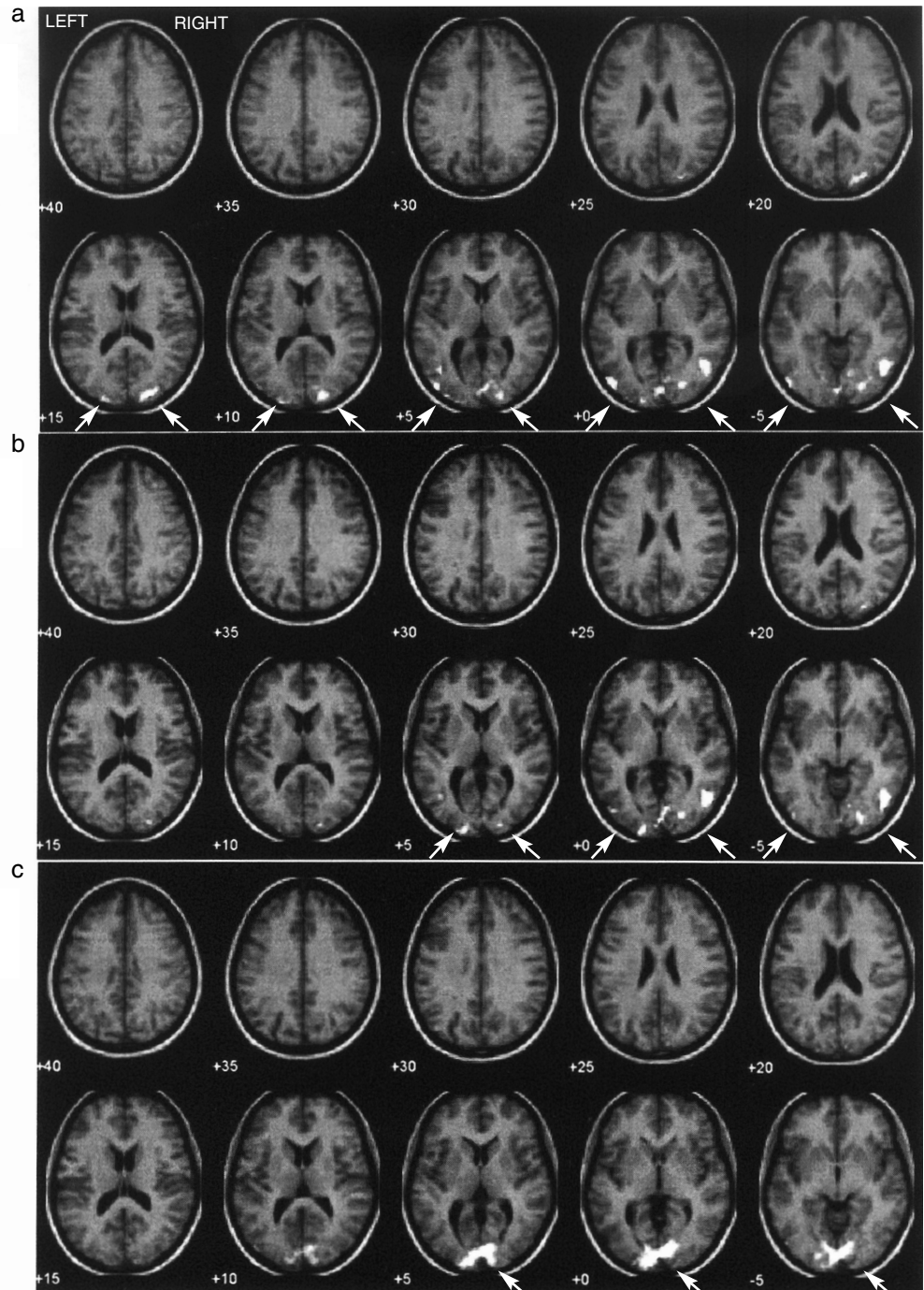
VISUAL AWARENESS

Our patient's abilities are different from those termed 'blindsight' in patients with striate cortex damage because he claims to be aware of the stimuli he can accurately discriminate. His vision may be similar to the residual vision known as Riddoch's phenomenon (Zeki and ffytche 1998), although he cannot adequately describe his visual experiences and he has no standard for 'normal' vision.

He is also different from adults with visual anosognosia (Anton syndrome) who deny blindness but are clinically blind due to acquired bilateral occipital lobe damage (Bergman 1957, Aldrich et al. 1987, Goldenberg et al. 1995). Such individuals confabulate visual experiences and bump into things. Vision often returns in those who survive (Argenta and Morgan 1998).

The fact that our patient's brain damage occurred at birth may be important. Human (Blythe et al. 1987, Payne et al. 1996) and animal studies (Spear et al. 1988, Moore et al. 1996) have shown that blindsight and visual awareness can be more developed when the damage to the striate cortex

Figure 7: Functional MRI activation maps for two representative comparison individuals with normal vision (both aged 21 years). (a) Fast radial motion versus stationary dots. (b) Slow radial motion versus stationary dots. (c) Counterphase-flickering checks versus a grey field. All three stimuli normally activate posterior visual areas.



occurs early in life. In cats, this is attributed to a pathway from the dorsal lateral geniculate nucleus to motion sensitive regions of the cortex that normally retracts in adulthood but is retained and expanded when the striate cortex is damaged in infancy (Payne et al. 1996). A similar transient extra-geniculostriate pathway may be responsible for residual vision in monkeys and humans, although no evidence for such a pathway has been found (Sorenson and Rodman 1999). It has even been hypothesized that there is a period in infancy when visual awareness is partially due to activities in the superior colliculus (Sewards and Sewards 2000).

Conclusion

Conscious vision is reportedly impossible when striate cortex is absent (Celesia et al. 1991). This is clearly not true in this particular case in which the absence of striate cortex was confirmed based on the following set of findings: lack of alpha rhythm on EEG, no flash or pattern-reversal visual evoked potentials recorded over the occipital area including the pole, no functional MRI activation by pattern reversal, and no striate cortex tissue visible on anatomic MRI. (This is the standard by which other patients have been assessed, but post-mortem examination is required to prove the absence of striate cortex.) Cortical area V5 has been implicated in residual motion perception, however, we observed no activation in this area in our patient. Instead, we suggest that the posterior superior temporal sulcus is involved in his residual motion perception. This may represent a reorganization of his visual system to compensate for the absence of striate cortex such that the functionally defined motion sensitive area V5 is no longer in the expected anatomic location. The intact network of cortical and subcortical motion-sensitive regions in this patient appears to be sufficient for conscious perception. This represents a dramatic demonstration of the plastic nature of the human brain during early development.

DOI: 10.1017/S0012162203001439

Accepted for publication 28th May 2003.

References

- Ahlfors SP, Simpson GV, Dale AM, Belliveau JW, Liu AK, Korvenoja A, Virtanen J, Huottilainen M, Tootell RB, Aronen HJ, Ilmoniemi RJ. (1999) Spatiotemporal activity of a cortical network for processing visual motion revealed by MEG and fMRI. *J Neurophysiol* **82**: 2545–2555.
- Aldrich MS, Alessi AG, Beck RW, Gilman S. (1987) Cortical blindness: etiology, diagnosis and prognosis. *Ann Neurol* **21**: 149–158.
- Anderson SJ, Holliday IE, Singh KD, Harding GFA. (1996) Localization and functional analysis of human cortical area V5 using magneto-encephalography. *Proc R Soc Lond B* **263**: 423–431.
- Argenta PA, Morgan MA. (1998) Cortical blindness and Anton syndrome in a patient with obstetric hemorrhage. *Obstet Gynecol* **91**: 810–812.
- Azzopardi P, Cowey A. (2001) Motion discrimination in cortically blind patients. *Brain* **124**: 30–46.
- Azzopardi P, King S, Cowey A. (2001) Pattern electroretinograms after cerebral hemispherectomy. *Brain* **124**: 1228–1240.
- Barbur JL, Ruddock KH, Waterfield VA. (1980) Human visual responses in the absence of the geniculocalcarine projection. *Brain* **103**: 905–928.
- Barbur JL, Sahraie A, Simmons A, Weiskrantz L, Williams SCR. (1998) Residual processing of chromatic signals in the absence of a geniculostriate projection. *Vision Res* **38**: 3447–3453.
- Barbur JL, Watson JDG, Frackowiak RSJ, Zeki S. (1993) Conscious visual perception without V1. *Brain* **116**: 1293–1302.
- Barton JS, Sharpe JA. (1997) Motion direction discrimination in blind hemifields. *Ann Neurol* **41**: 255–264.
- Baseler HA, Morland AB, Wandell BA. (1999). Topographic organization of human visual areas in the absence of input from primary cortex. *J Neurosci* **19**: 2619–2627.
- Benson PJ, Guo K, Blakemore C. (1998) Direction discrimination of moving gratings and plaids and coherence in dot displays without primary visual cortex (V1). *Eur J Neurosci* **10**: 3767–3772.
- Bergman PS. (1957) Cerebral blindness. *Arch Neurol* **78**: 568–584.
- Birch EE, Bane MC. (1991) Forced-choice preferential looking acuity of children with cortical visual impairment. *Dev Med Child Neurol* **33**: 722–729.
- Bittar RG, Ptito M, Faubert J, Dumoulin SO, Ptito A. (1999) Activation of the remaining hemisphere following stimulation of the blind hemifield in hemispherectomized subjects. *Neuroimage* **10**: 339–346.
- Blythe IM, Kennard C, Ruddock KH (1987) Residual vision in patients with retrogeniculate lesions of the visual pathways. *Brain* **110**: 887–905.
- ter Braak JWG, Schenk VWD, van Vliet AGM. (1971) Visual reactions in a case of long-lasting cortical blindness. *J Neurol Neurosurg Psychiatry* **34**: 140–147.
- Brent PJ, Kennard C, Ruddock KH. (1994) Residual colour vision in a human hemianope: spectral responses and colour discrimination. *Proc R Soc Lond B* **256**: 219–225.
- Brindley GS, Gautier-Smith PC, Lewin W. (1969) Cortical blindness and the functions of the non-geniculate fibres of the optic tract. *J Neurol Neurosurg Psychiatry* **32**: 259–264.
- Buchner H, Gobbele R, Wagner M, Fuchs M, Waberski TD, Beckmann R. (1997) Fast visual evoked potential input into human area V5. *NeuroReport* **8**: 2419–2422.
- Campion J, Latto R, Smith YM. (1983) Is blindsight an effect of scattered light, spared cortex, and near-threshold vision? *Behav Brain Sci* **6**: 423–486.
- Celesia GG, Bushnell D, Toleikis SC, Brigell MG. (1991) Cortical blindness and residual vision: is the “second” visual system in humans capable of more than rudimentary visual perception? *Neurology* **41**: 862–869.
- Cowey A. (1974) Atrophy of retinal ganglion cells after removal of striate cortex in a rhesus monkey. *Perception* **3**: 257–260.
- Cowey A, Stoerig P. (1991) The neurobiology of blindsight. *Trends Neurosci* **14**: 140–145.
- Dalman JE, Verhagen WIM, Huygen PLM. (1997) Cortical blindness. *Clin Neurol Neurosurg* **99**: 282–286.
- Dumoulin SO, Bittar RG, Kabani NJ, Baker CL, Le Goualher G, Pike GP, Evans AC. (2000) A new anatomical landmark for reliable identification of human area V5/MT: a quantitative analysis of sulcal patterning. *Cereb Cortex* **10**: 454–463.
- Fendrich R, Wessinger CM, Gazzaniga MS. (1992) Residual vision in a scotoma: implications for blindsight. *Science* **258**: 1489–1491.
- ffytche DH, Guy CN, Zeki S. (1995) The parallel visual motion inputs into areas V1 and V5 of human cerebral cortex. *Brain* **118**: 1375–1394.
- ffytche DH, Guy CN, Zeki S. (1996) Motion specific responses from a blind hemifield. *Brain* **119**: 1971–1982.
- Goebel R, Muckli L, Zaneela FE, Singer W, Stoerig P. (2001) Sustained extrastriate cortical activation without awareness revealed by fMRI studies of hemianopic patients. *Vision Res* **41**: 1459–1474.
- Goldenberg G, Müllbacher W, Nowak A. (1995) Imagery without perception - a case study of anosognosia for cortical blindness. *Neuropsychologia* **33**: 1373–1382.
- Good WV, Jan JE, Desa L, Barkovich AJ, Groenewald M, Hoyt CS. (1994) Cortical visual impairment in children. *Surv Ophthalmol* **38**: 351–364.
- Gross C. (1991) Contribution of striate cortex and the superior colliculus to visual function in area MT, the superior temporal polysensory area and inferior temporal cortex. *Neuropsychologia* **29**: 497–515.
- Heide W, Koenig E, Dichgans J. (1990) Optokinetic nystagmus, self-motion sensation and their after effects in patients with occipitoparietal lesions. *Clin Vision Sci* **5**: 145–156.
- Hertz BG, Rosenberg J, Sjo O, Warburg, M. (1988) Acuity card testing of patients with cerebral visual impairment. *Dev Med Child Neurol* **30**: 632–637.
- Hess RH, Baker CL, Zihl J. (1989) The “motion-blind” patient: low-level spatial and temporal filters. *J Neurosci* **9**: 1628–1640.

- Holliday IE, Anderson SJ, Harding GF. (1997) Magnetoencephalographic evidence for non-geniculostriate visual input to human cortical area V5. *Neuropsychologia* **35**: 1139–1146.
- Ipata AE, Cioni G, Bottai P, Fazzi B, Canapicchi R, Van Hof-van Duin J. (1994) Acuity card testing in children with cerebral palsy related to magnetic resonance images, mental levels and motor abilities. *Brain Dev* **16**: 195–203.
- Jan JE, Groenvelde M, Sykanda AM, Hoyt CS. (1987) Behavioural characteristics of children with permanent cortical visual impairment. *Dev Med Child Neurol* **29**: 571–576.
- Jan JE, Wong PKH, Groenvelde M, Flodmark O, Hoyt CS. (1986) Travel vision: 'collicular visual system'. *Pediatr Neurol* **2**: 359–362.
- Kleiser R, Wittsack J, Niedeggen M, Goebel R, Stoerig P. (2001) Is V1 necessary for conscious vision in areas of relative cortical blindness? *NeuroImage* **13**: 654–661.
- Kushner BJ, Lucchese NJ, Morton GV. (1995) Grating visual acuity with Teller Cards compared with Snellen visual acuity in literate patients. *Arch Ophthalmol* **113**: 485–493.
- Mayer DL, Fulton AB, Rodier D. (1984) Grating and recognition acuities in pediatric patients. *Ophthalmology* **91**: 947–953.
- McDonald MA, Dobson V, Sebris SL, Baitch L, Varner D, Teller DY. (1985) The acuity card procedure: a rapid test of infant acuity. *Invest Ophthalmol Vis Sci* **26**: 1158–1162.
- Mehdorn E. (1982) Nasal-temporal asymmetry of the optokinetic nystagmus after bilateral occipital infarction in man. In: Lennerstrand G, Zee DS, Keller EL, editors. *Functional Basis of Ocular Motility Disorders*. Oxford: Pergamon Press. p 321–324.
- Mestre DR, Brouchon M, Ceccaldi M, Poncet M. (1992) Perception of optical flow in cortical blindness: a case report. *Neuropsychologia* **30**: 783–795.
- Miller NR, Newman SA. (1981) Transsynaptic degeneration. *Arch Ophthalmol* **99**: 1654. (Letter)
- Mohn G, van Hof-van Duin J. (1986) Development of the binocular and monocular visual fields of human infants during the first year of life. *Clin Vision Sci* **1**: 51–64.
- Moore T, Rodman HR, Repp AB, Gross CG, Mezrich RS. (1996) Greater residual vision in monkeys after striate cortex damage in infancy. *J Neurophysiol* **76**: 3928–3933.
- Morland AB, Jones SR, Finlay AL, Deyzac E, Le S, Kemp S. (1999) Visual perception of motion, luminance and colour in a human hemianope. *Brain* **122**: 1183–1198.
- Nepple EW, Appen RE, Sackett JF. (1978) Bilateral homonymous hemianopia. *Am J Ophthalmol* **86**: 536–543.
- Payne BR, Lomber SG, Macneil MA, Cornwell P. (1996) Evidence for greater sight in blindsight following damage of primary visual cortex early in life. *Neuropsychologia* **34**: 741–774.
- Perenin MT. (1991) Discrimination of motion direction in perimetrically blind fields. *NeuroReport* **2**: 397–400.
- Pöppel E, Held R, Frost D. (1973) Residual visual function after brain wounds involving the central visual pathways in man. *Nature* **243**: 295–296.
- Preston KL, Finocchio DV. (1993) Development of the vestibuloocular and optokinetic reflexes. In: Simons K, editor. *Early Visual Development, Normal and Abnormal*. New York: Oxford University Press. p 80–88.
- Ptito M, Johansson P, Faubert J, Gjedde A. (1999) Activation of human extrageniculostriate pathways after damage to area V1. *NeuroImage* **9**: 97–107.
- Reese FM. (1954) Bilateral homonymous hemianopsia. *Am J Ophthalmol* **38**: 44–57.
- Riddoch G. (1917) Dissociation of visual perceptions due to occipital injuries, with especial reference to appreciation of movement. *Brain* **40**: 15–57.
- Rizzo M, Hurtig R. (1989) The effect of bilateral visual cortex lesions on the development of eye movements and perception. *Neurology* **39**: 406–413.
- Sachdev MS, Kumar H, Jain AK, Goulatia RK, Misra NK. (1990) Transsynaptic neuronal degeneration of optic nerves associated with bilateral occipital lesions. *Indian J Ophthalmol* **38**: 151–152.
- Sahraie A, Weiskrantz L, Barbur JL, Simmons A, Williams SCR, Brammer MJ. (1997) Pattern of neuronal activity associated with conscious and unconscious processing of visual signals. *Proc Natl Acad Sci USA* **94**: 9406–9411.
- Salomao SR, Ventura DF. (1995) Large-sample population age norms for visual acuities obtained with Vistech/Teller Acuity Cards. *Invest Ophthalmol Vis Sci* **36**: 657–670.
- Schoenfeld MA, Noesselt T, Poggel D, Tempelmann C, Hopf J-M, Woldorff MG, Heinze H-J, Hillyard SA. (2002) Analysis of pathways mediating preserved vision after striate cortex lesions. *Ann Neurol* **52**: 814–824.
- Sewards TV, Sewards MA. (2000) Visual awareness due to neuronal activities in subcortical structures: a proposal. *Conscious Cogn* **9**: 86–116.
- Sokol S, Hansen VC, Moskowitz A, Greenfield P, Towle VL. (1983) Evoked potential and preferential looking estimates of visual acuity in pediatric patients. *Ophthalmology* **90**: 552–562.
- Sorenson KM, Rodman HR. (1999) A transient geniculocortical pathway in macaques? Implications for 'blindsight'. *Neuroreport* **10**: 3295–3299.
- Spear PD, Tong L, McCall MA. (1988) Functional influence of areas 17, 18 and 19 on lateral suprasylvian cortex in kittens and adult cats: implications of compensation following early visual cortical damage. *Brain Res* **447**: 79–91.
- Stoerig P, Cowey A. (1992) Wavelength discrimination in blindsight. *Brain* **115**: 425–444.
- Stoerig P, Cowey A. (1997) Blindsight in man and monkey. *Brain* **120**: 535–559.
- Stoerig P, Kleinschmidt A, Frahm J. (1998) No visual responses in denervated V1: high resolution functional magnetic resonance imaging in a blindsight patient. *Neuroreport* **9**: 21–25.
- Sunaert S, van Hecke P, Marchal G, Orban GA. (1999) Motion-responsive regions of the human brain. *Exp Brain Res* **127**: 355–370.
- Talairach J, Tournoux P. (1988) *Co-planar Stereotaxic Atlas of the Human Brain. 3-Dimensional Proportional System: An Approach to Cerebral Imaging*. New York: Thieme Medical Publishers.
- Vanni S, Raninen A, Nasanen R, Tanskanen T, Hyvarinen L. (2001) Dynamics of cortical activation in a hemianopic patient. *NeuroReport* **12**: 861–865.
- Wechsler D. (1971) *Wechsler Intelligence Scale for Children – Revised*. San Antonio, Texas. The Psychological Corporation.
- Weiskrantz L. (1996) Blindsight revisited. *Curr Opin Neurobiol* **6**: 215–220.
- Weiskrantz L, Barbur JL, Sahraie A. (1995) Parameters affecting conscious versus unconscious visual discrimination with damage to the visual cortex (V1). *Proc Natl Acad Sci USA* **92**: 6122–6126.
- Weiskrantz L, Cowey A, Barbur JL. (1999) Differential pupillary constriction and awareness in the absence of striate cortex. *Brain* **122**: 1533–1538.
- Weiskrantz L, Cowey A, Lemare C. (1998) Learning from the pupil: a spatial visual channel in the absence of V1 in monkey and human. *Brain* **121**: 1065–1072.
- Weiskrantz L, Warrington EK, Sanders MD, Marshall J. (1974) Visual capacity in a hemianopic field following a restricted occipital ablation. *Brain* **97**: 709–728.
- Wessinger CM, Fendrich R, Ptito A, Villemure JG, Gazzaniga MS. (1996) Residual vision with awareness in the field contralateral to a partial or complete functional hemispherectomy. *Neuropsychologia* **34**: 1129–1137.
- Zeki S, fytche DH. (1998) The Riddoch syndrome: insights into the neurobiology of conscious vision. *Brain* **121**: 25–45.