

ACALCULIA: AN fMRI STUDY WITH IMPLICATIONS WITH RESPECT TO BRAIN PLASTICITY

BYRON BERNAL

Neurologist, Miami Children's Hospital
Department of Radiology
Miami, Florida, USA

ALFREDO ARDILA

Neuropsychologist, Memorial Regional Hospital
Hollywood, Florida, USA

NOLAN R. ALTMAN

Neuroradiologist, Chief, Department of Radiology
Miami Children's Hospital
Miami, Florida, USA

We report the case of a 44-year-old right-handed man with severe acalculia and 4 normal age-matched controls. The acalculia patient had magnetic resonance findings of a wedge shaped defect in the left posterior temporal-parietal cortex, involving the angular gyrus, and a lacunar infarct of the right thalamus. Functional magnetic resonance exams were performed utilizing four tasks consisting of serial subtracting by sevens, basic calculation, complex calculation, and abstract calculation. Both patient and controls showed specific task-related activation

Received 3 March 2003.

Our sincere gratitude to Dr. Mauricio Concha and Dr. Monica Rosselli for their significant contribution when studying this case and for their valuable suggestions; to Dr. Rosario Rosales for her invaluable help with the bibliography work-up and review of the article.

Address correspondence to Nolan R Altman, MD, Miami Children's Hospital, Department of Radiology, 3100 SW 62nd Avenue, Miami, Florida 33155-3009, USA. E-mail: nolan.altman@MCH.com

with some differences that may indicate brain plasticity, even though no significant recovery in calculations abilities was observed in the patient.

Keywords acalculia, brain, calculations, fMRI, functional, plasticity

Brain plasticity is defined as the ability of the circuitry of the brain to reorganize in response to a neural insult (Kaas, 1991; Simos et al., 2000). From this definition there is no causal relationship between mutability of neural tissue and recovery. Brain plasticity may involve pathway-redundancy, changes in synaptic strength, growth of new synapses, assumption of function by contralateral homologous cortex, and substitution of uncrossed pathways (Frackowiak, 1996; Lee & van Donkelaar, 1995). These brain capabilities usually occur early in immature brains, but may be observed even late in adulthood (Kennard, 1940; Nass, 1984; Vargha-Khadem et al., 1985; Chollet et al., 1991). Thus, the neuronal circuitry involved in a specific function may possibly be shifted, displaced, or relocated after an insult. Brain plasticity has been investigated by functional magnetic resonance imaging (Rossini et al., 1998; Musso et al., 1999; Thulborn et al., 1999; Cao et al., 1999) and positron emission tomography (Chollet et al., 1991; Weiller et al., 1995), in patients with brain lesions and cognitive impairments. These studies correlate changes in brain activation to recovery of the lost function. However, no studies have addressed the functional changes that can occur in the brain not related to recovery. The understanding of these “non-successful” changes can contribute to the knowledge of functional recovery.

Functional magnetic resonance (fMR), a current tool used to map brain activity related to motor, sensory, and cognitive tasks, is based on the chemical and vascular changes produced by brain cortical activity. These minute tissue changes occur locally and modify the signal of the MR images. fMRI has been utilized to study brain plasticity in patients after stroke. These studies have focused on different types of brain functions: motor (Rijntjes et al., 1994; Weiller et al., 1993; Maegaki et al., 1995; Rossini et al., 1998), sensory (Maegaki et al., 1995), and language (Weiller et al., 1995; Heiss et al., 1999; Musso et al., 1999; Cappa et al., 1997; Cao et al., 1999).

To our knowledge, no prior investigations with functional images

have addressed brain plasticity in acalculia, a term that defines the loss or impairment in computation ability. Similar to language, calculation relies on a multi-modular network involving frontal and parietal lobes of both hemispheres (Fulbright et al., 2000), with important nodes located primarily in the left posterior parietal areas (Stanescu-Cosson et al., 2000). The understanding of brain plasticity in calculation is important, as calculation is a category-specific model less dependent on language input modalities (Le Clec'h et al., 2000).

Despite recent knowledge gained from functional and lesional models, whether there is reorganization without recovery still remains an unanswered question. We present a case in which a right-handed patient, who suffered a left parietal stroke, showed right-parietal activation without significant recovery of the lost arithmetic skills. As in other reports with different cognitive deficits (Weiller et al., 1993; Weiller et al., 1995), the normal activation is assumed from results in normal volunteers, reported in the literature, and from our own service.

MATERIALS AND METHODS

The patient is a 44-year-old right-handed man, who suffered a stroke during abdominal surgery five years prior to the exam. He complains of difficulty in controlling his right hand, using numerical information, and solving arithmetic problems. Magnetic resonance imaging (MRI) demonstrated a wedge shaped defect in the left posterior temporal-parietal cortex, involving the angular gyrus, and a lacunar infarct of right thalamus (Figure 1). Neuropsychological evaluation showed no important language deficits (Table 1). Mild difficulties were found in right-left orientation and finger gnosis. Reading was normal but in writing (spontaneous and by dictation) a significant number of word omissions and, to a lesser degree, additions were noted (Figure 2).

The significant findings were limited to the mathematical domain. The patient was able to count forward, but not backward. He could perform simple one-digit additions (e.g., $5 + 3$), but failed all other mathematical tests, including serial additions and subtractions,

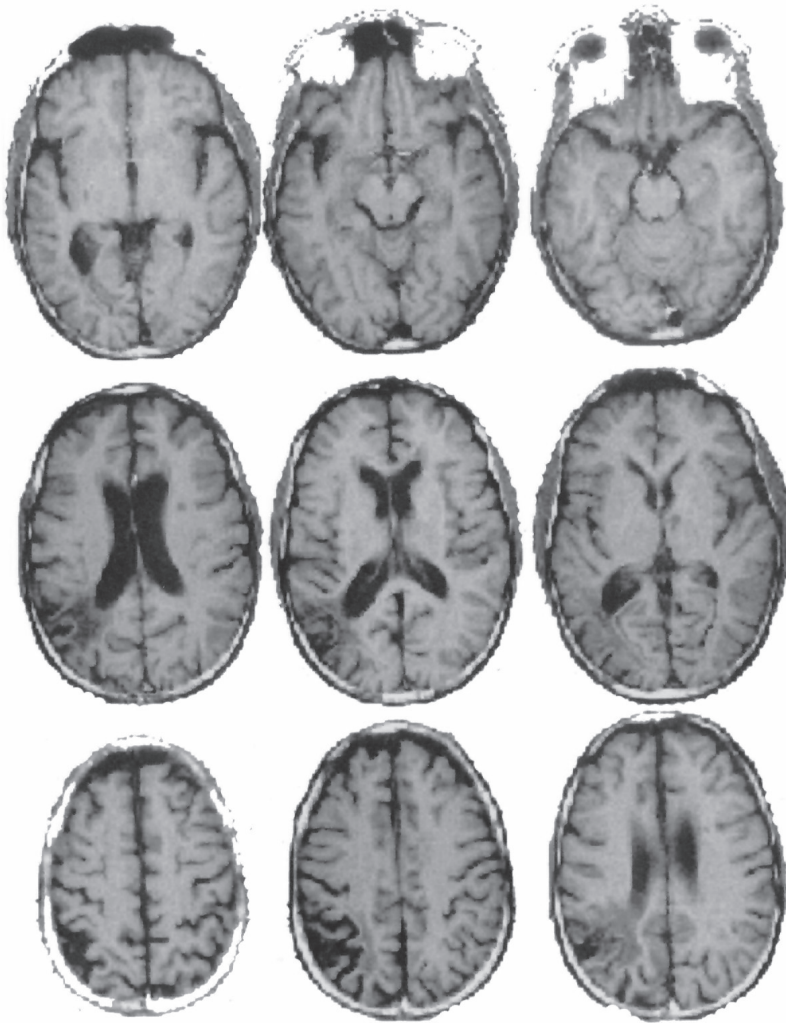


FIGURE 1. Axial T1 weighted MRI of the brain shows generalized atrophy with involvement of cortical and subcortical white matter. A chronic infarct in the left parietaloccipital junction and lacunar right thalamic infarct is seen.

multiplying, and dividing. Solving arithmetical problems (e.g., “how many books are there in two dozen and a half?”) was impossible. Similar difficulties were observed in oral and written calculations. However, he preserved the ability to calculate grossly the answer

TABLE 1. Language evaluation of the acalculia patient

Language testing	Raw score	Standard score*
Boston Naming Test	56	50
Multilingual Aphasia Examination		
Visual naming	56	64
Sentence repetition	12	43
Controlled oral word association	23	5
Token test	39	15
Reading comprehension	17	17
WAIS-III		
Vocabulary	43	9
Similarities	16	7
Digit span	14	8
Information	20	11
Comprehension	15	7

*Standard scores refer to percentiles (Boston Naming Test and Multilingual Aphasia Examination) or scaled scores (WAIS-III).

(e.g., “How much is 15 plus 12?”, “I think 25”). He had significant difficulties in halving and doubling small quantities. He failed in dividing objects (e.g., pencils) into equal groups (e.g., to separate nine pencils in three groups, each one containing the same number of pencils). He could read one and two-digit numbers, but the reading

I HOPE ELIA RODRIGUEZ CAN
 STAY IN THE UNITED STATES
 UNTILL HE GOES TO SCHOOL
 TO FINISH HIS ^{GOES} EDUCATION
 IN ANAECOUNTRY SO HE CAN
 MAKE HIS OWN DESION
 ABOUT WHERE HE WANTS TO LIVE
 WHEN HE IS AN A DULT.

FIGURE 2. Sample of spontaneous writing (“I hope Elian Rodriguez can stay in the United States until he goes to school to finish his education in a country so he can make his own decision about where he wants to live when he is an adult”).

of numbers with more than three digits was difficult. Omissions (10003 \rightarrow 1003), and inversions (4908 \rightarrow 4098) would result. There were no errors in aligning numbers in columns. He could write quantities by dictation. Digit substitutions were noted in translating from verbal to numerical (e.g., twenty-three \rightarrow 25). Omissions and additions of letters and decomposition errors (e.g., 67 \rightarrow six seven) were observed when transcoding from numerical to verbal code (Figure 3). Table 2 summarizes the results of the different calculation tests.

The patient was examined with fMRI imaging. Prior to the study, he was instructed not to move during image acquisition and avoid vocalization or sub-vocalization. He was informed that this was a test involving mathematical skills. He was trained using short paradigms to assure comprehension of the task. We were more interested in the continuation of the task rather than the answer. His performance was known beforehand, and then debriefed after the exam, and we preferred not to ask the patient to verbalize an answer because of the risk of producing head motion. Four healthy adult right-handed males volunteers (age 24–35, mean 27.7), were recruited among coworkers; a signed, written informed consent was obtained that was approved by the Institutional Review Board. The subjects were given the same tasks. This group served as a control.

Imaging was performed on a 1.5-T MR scanner (General Electric, Milwaukee, WI, USA. Signa Horizon Echospeed 5X) using

2,346 = TWO THOUSAND THREE HUNDRED SIX
 512 = FIVE TWELVE
 67 = SIX SEVEN
 739 = SEVEN THIRTY NINE
 49 = FORT NINE
 2346 TWO THOUSAND THREE HUNDRED FORT SIX

FIGURE 3. Transcoding from a numerical to a verbal code.

TABLE 2. Results of different calculation test in acalculia patient

<i>Calculation ability testing</i>	<i>Raw</i>	<i>Score interpretation</i>
WAIS-III Arithmetic	6	(Scaled score = 3) abnormal
Counting forwards (1 to 20)	20/20	normal
Backwards (30–20)	7/10	abnormal
Reading numbers	4/6	abnormal
Writing numbers	6/6	normal
Transcoding: numerical to a verbal	4/6	abnormal
Verbal to a numerical	4/6	abnormal
Multiplication tables (table of 3)	6/10	abnormal
To complete an arithmetical operation	7/8	abnormal (e.g., $23 \times 18 = 30$)
Successive arithmetical operations		
Adding (1, 4, 7?37)	7/12	abnormal
Subtracting (100, 93–86?16)	0/12	abnormal
Mental calculation (with two digits)		
Adding	0/4	abnormal
Subtracting	0/4	abnormal
Multiplying	0/4	abnormal
Dividing	0/4	abnormal
Written calculation (with two and three digits)		
Adding	0/4	adnormal
Subtracting	0/4	adnormal
Multiplying	0/4	adnormal
Dividing	0/4	adnormal
Aligning numbers in columns	5/5	normal
Fractions	3/3	normal e.g., “what is larger, one-third or one-fourth?”
General numerical knowledge	4/4	normal (e.g., “at what temperature does water boil?”)
Personal numeral knowledge	4/4	normal (e.g., “what is your social security number?”)
Numerical problems	0/5	abnormal
Halving and doubling small quantities	0/6	abnormal
Dividing objects into equal groups	0/5	abnormal

birdcage quadrature-transmit-and-receive head coil designed for whole brain imaging. A series of 16 localizer images were obtained in the sagittal plane. On the basis of these images, ten axial slices were selected to obtain the functional and the anatomic images. The slices were parallel to the plane defined by a line between the basal aspect of the frontal and occipital lobes. The anatomic series were obtained with T1-spin-echo acquisitions, time of repetition/time of echo (TR/TE) of 300/14 ms, field of view (FOV) 240 mm, matrix: 256 × 256, 6 mm slice thickness, and 2 mm gap. The functional images

with same thickness and gap were obtained using a gradient echo-single shot echo planar imaging sequence with TR/TE/Flip-angle of 3750 ms/60/60°. The FOV was 240 mm, and the matrix 64 × 64 voxels. Each voxel had a volume of 3.75 × 3.75 × 6 mm (84.375 mm³). The experiment consisted of 48 time-points (sets) of 10 images, and 2 extra sets at the beginning of the series, used to obtain the steady-state of the transverse magnetization. The 48 sets were divided in 6 epochs, 3 OFF (baseline or control condition) and 3 ON (activated condition). Starting in OFF, the experiment proceeded switching every 30 s. Thus, each slice was scanned 48 times, resulting in 240 image pairs for comparisons.

Four paradigms were applied: (1) *serial subtracting by seven*, (2) *basic calculations*, (3) *complex calculations*, and (4) *abstract calculations*. *Serial subtracting by seven* was performed starting at 100 for the first ON epoch, from 50 in the second, and from 75 in the third. *Basic calculations* consisted of simple addition and subtraction problems of one or two digits avoiding carrying over of numbers (e.g.: 7 – 5 = ?). *Complex calculations* were problems with the same type of calculations involving two digits and requiring carrying, borrowing, and handling of place values (e.g.: 15 – 7 = ?). *Abstract calculations* included problems involving rules and concepts related to logical and spatial analysis (e.g.: 2 – ¼ = ?). To prevent motion artifacts, the head was fixed with cushions and taped to the headholder of the table. Problems were displayed with a black font on one horizontal line (e.g.: 23 – 7 = ?) over a white background using a back projector and a semitransparent screen placed at the foot of the imaging table. The image was delivered to the patient by a mirror located over his eyes. Numbers were 3 × 2 cm and the screen was located 200 cm from the mirror. The numbers formed a 0.85° vertical angle with the eyes. Each problem was presented for 3 to 6 s (depending on the complexity of the task and previous experience with volunteers). Two different types of baseline (OFF) conditions were used: (1) counting forward from 1 for the serial subtracting by seven, and (2) reading strings of four elements (letter and digits), randomly mixed, for the remainder of paradigms (e.g., F 2 H 6). These OFF epochs were designed to match attention, ocular motion, visual stimulus, and verbal impute and decoding.

The fMRI data were analyzed off-line on a Sun-Ultrasparc work-

station (Sun Microsystems Inc., CA, USA) using MEDx 3.0 software (Sensor Systems, Inc., VA, USA). The functional images were first analyzed to detect motion, using the Intensity Weighted Method. The images were spatially smoothed with a Gaussian kernel of full-width-at-half-maximum (FWHM) of 10 mm to reduce the noise in the images. Intensity normalization was applied to normalize the signal at each voxel and remove the effects of signal drift. Parametrical statistical maps were obtained in each series using a *t*-test method. *z*-scores were used as activation reference maps, after thresholding them to an uncorrected $p < .0005$, corresponding to a *z*-score of 3.47. Anatomic localization was performed by superimposing the functional images on T1 weighted images at the same slice location.

RESULTS AND DISCUSSION

Table 3 summarizes the results of the control group. In the patient, the serial subtracting by sevens produced activation in the posterior

TABLE 3. fMRI results of the calculation tasks in the control group

<i>Paradigm</i>	<i>Areas of activation</i>	<i>Cases</i>
Counting backwards	Left middle-inferior frontal gyrus	3
	Right middle-inferior frontal gyrus	3
	Left posterior inferior parietal lobule (PIPL) (including angular gyrus)	3
	Left supplemental motor area (SMA)	3
	Left frontal eye field	2
Basic calculation	Right middle frontal gyrus	2
	Right caudate nucleus	2
	Right SMA	2
	Left PIPL (including angular gyrus)	2
	Left broca	1
Complex calculation	Left middle-inferior frontal gyrus	4
	Left PIPL (including angular gyrus)	3
	Right PIPL (including mirror angular gyrus)	2
	Left cuneus	2
Abstract calculation	Left PIPL (including angular gyrus)	4
	Right PIPL (including angular gyrus)	4
	Left middle-inferior frontal gyrus	3
	Left SMA	2
	Right SMA	1
	Left > right frontal eye field	3

aspect of the left temporal lobe (Brodmann's areas 22 and 37), both middle frontal gyri, left cuneus, and adjacent areas to the left angular gyrus (Figure 4). The basic calculation paradigm elicited activation in right caudate nucleus and right middle frontal gyrus (Figure 5). No significant activation was seen in the complex calculation paradigm. The abstract calculation paradigm produced activation in left middle frontal gyrus, right posterior-inferior-parietal lobule (PIPL), and left frontal eye field (Figure 6).

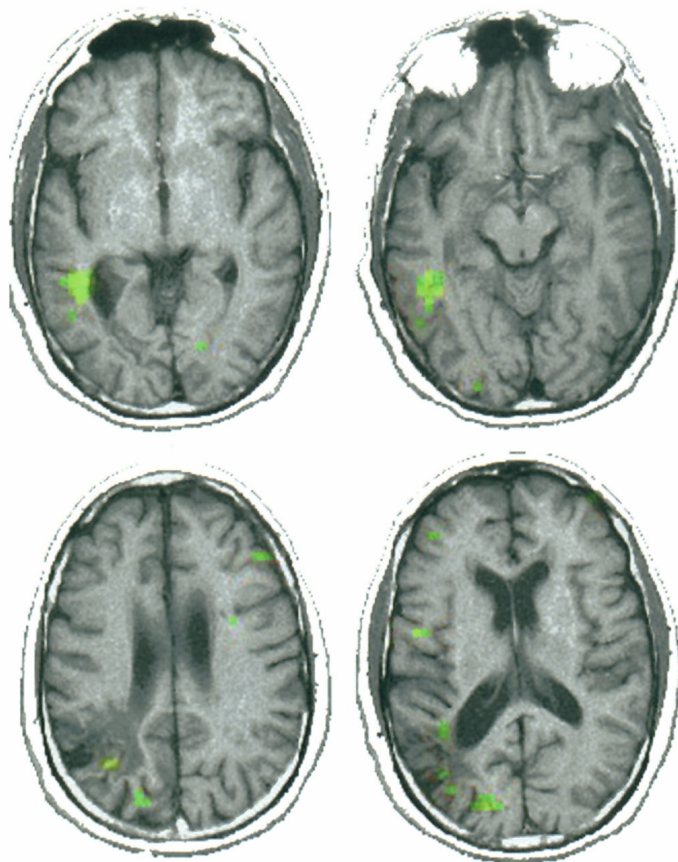


FIGURE 4. fMRI obtained with the *serial subtracting by sevens* paradigm. Areas represented in green correspond to voxels with p value less than .0005. The greatest activation is seen in the left temporal lobe along the deep portion of the superior and inferior banks of the superior temporal sulcus. These are Brodmann's area 22 and 37. There is a left side predominance. (See Color Plate I at end of issue.)

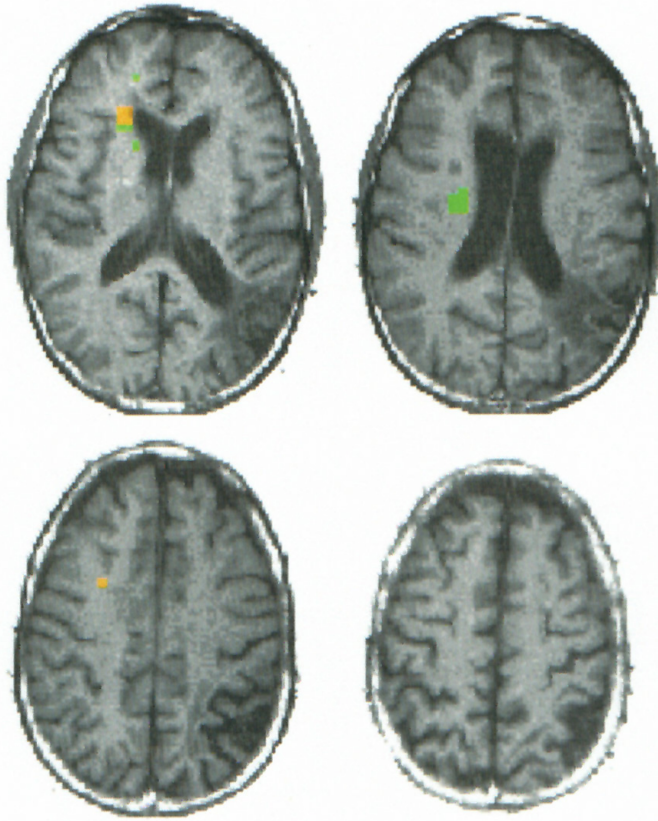


FIGURE 5. fMRI obtained with *basic calculation*. Color corresponds to activation in voxels with p value less than .0005. The main activation is seen in the right caudate nucleus. Notice the lack of activation in the left hemisphere. (See Color Plate II at end of issue.)

Variation in the pattern of brain activation was found with the different paradigms. Significant local changes were observed in the temporal, posterior parietal, and frontal lobes. These local changes we correlated with specific task demands.

Serial subtracting by seven resulted in a significant activation of Brodmann's 37 area. This area involves the region about the superior and inferior temporal sulcus. This region has also been found activated in semantic verbal tasks (Vandenberghe et al., 1996). It is related to visual representation of words (Benson & Ardila, 1996). We may assume that the patient had adopted a semantic strategy to

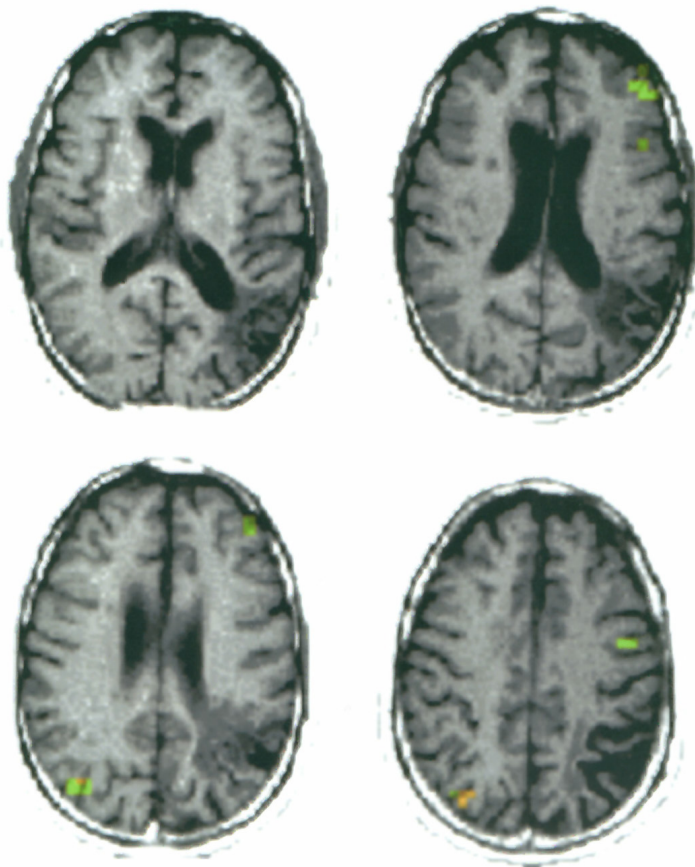


FIGURE 6. fMRI during *abstract calculation*. Color corresponds to voxels with p value less than .0005. Activation presented in yellow is located in the right PIPL. A wider cluster of activation is seen in the left middle frontal gyrus. The area of activation in the left precentral area is probably related to the left frontal eye field. The asymmetry of this finding suggests a cognitive involvement, since an underlying motor process would produce bilateral activation. (See Color Plate III at end of issue.)

solving problems, consistent with his ability to approach an answer. Thus, the search for the answer was performed as a semantic word generation, i.e., to solve the problem “ $100 - 7 = _$,” the patient’s strategy consisted of searching the nineties. Alternatively, the patient may have tried to visualize the numbers of the problems. The activation observed in the cuneus, along the transverse occipital sulcus, is interesting. Left cuneus activation has been described in sustained

visual attention (Le et al., 1998). The patient may have used visual clues to perform the task such as picturing the numbers and scanning them into a given category. Precuneus activation has been observed in aphasia patients with improvement in verbal comprehension after training (Musso et al., 1999). The previous training of the patient may also partially explain these results. Activation of the middle frontal gyri has been reported already using this paradigm. This activation is felt to be related to working memory (Rueckert et al., 1996).

The activation seen in the head of the right caudate nucleus, during *basic calculation paradigm*, was also observed in two cases in the control group. These results are in agreement with prior cases of acalculia reported in patients with subcortical strokes (Corbett et al., 1986). Basic calculations are automatic memory-related processes, which could be performed by subcortical structures. Therefore, it is understandable that our acalculia patient preserved the ability to perform simple basic calculations. Basic calculations (e.g., $5 + 2$) represent kinds of verbal automatism.

The lack of activation in the *complex paradigm* is not well understood; however, it is possible that the patient became frustrated and stopped performing the requested task.

Abstract calculation paradigm produced left middle frontal gyrus, left frontal eye field, and right PIPL activation (in absence of the normal homologous contralateral area). The left middle frontal gyrus activation, as stated before, is related to verbal working memory, although pure (nonverbal) abstract tasks may elicit activation in the same regional (Roland & Friberg, 1985). The frontal eye field activation is probably related to pursuit and saccadic eye movements (Petit et al., 1997), and spatial short-term memory (Gaymard et al., 1999). However, the activation related to eye movement was not supported in a recent study (Gitelman et al., 2000), raising the possibility of an unknown role for this area in cognitive tasks. The asymmetry of activation supports this hypothesis.

The right PIPL activation, in absence of the normal homologous contralateral area, during the abstract paradigm is the most striking finding of this case. The four normal subjects activated both PIPL, although the left PIPL was activated more strongly. Therefore, in our case, activation on the homologous contralateral area could be

anticipated. The left angular gyrus cannot be activated because of encephalomalacia. The left PIPL, although preserved, did not show activation possibly due to disconnection from input areas, as suggested by the deep extension of the hypointensity representing gliosis of the white matter (Figure 1). The contralateral right-PIPL area is activated, with the left frontal networking that is intact. This may explain the patient's abnormal performance indicating the inefficiency of this new hardwiring, or the remaining network.

Activation of contralateral-homologous areas does not necessarily mean functional recovery. Asymmetric bilateral normal representation may explain previous results dealing with the shifting type of brain plasticity. Using different techniques, bilateral activation has been found in normal subjects involving basic unilateral motor tasks, sensory stimulation (Hansson & Brismar, 1999; Babiloni et al., 1999), and language tasks (Binder, 1997; Weiller, 1997). Unilateral activation, which does occur in many cases, may be also artificially obtained as a result of high threshold levels, which are usually applied to the image post-processing. Often, statistical analysis is done using very strict p values, therefore, eliminating areas of weaker activation. Conceivably, a left hemisphere lesion may appear to have contralateral activation if the same statistical methods are applied to a smaller sample with lower absolute values, or if less conservative p values are utilized to depict activation. This could give the appearance of shifting plasticity.

There are no previous studies of brain plasticity in acalculia. Most previous reports of brain plasticity refer to language. However, language and calculation, as brain functions, share several features: they demand a network rather than a dedicated module, they are symbolic, and both are located principally in the left hemisphere. Therefore, some overlap in brain plasticity seems reasonable.

Calculation and language functions are based on bilateral networks with several levels of complexity. Understanding the reorganization of the scheme of the network is more important than replacement of a function in the study of recovery of cognitive functions (Weiller et al., 1997). This is stated by Thulborn et al. (1999): "When a key node of a large-scale cortical network is damaged network components (namely, contralateral homologous) are increasingly recruited to increase their workload" (p. 753).

Bilateral temporal lobe activation has been elicited by verbal tasks, both in normal subjects and stroke patients (Binder, 1997). However, the right hemisphere activation in stroke patients was greater in areas contralateral to those found in normal subjects (Weiller et al., 1995; Weiller, 1998). Patients with left frontal strokes present initially with global metabolic reduction of the left hemisphere and new activation in the right frontal area homologous to Broca's area, with repetition tasks. When recovery takes place, activation of the left posterior superior temporal gyrus returns, and the activation in the right frontal region (Broca's homologue) disappears (Heiss et al., 1999). Temporal lesions show activation in the right temporal lobe in the early phase (without recovery) and later when recovery occurs (Heiss et al., 1999).

The fact that right perisylvian areas in aphasic patients show stronger activation than in controls (Weiller et al., 1995) suggests the idea of a substitution role. This supports the assumption that the right hemisphere plays a crucial role in recovery, as suggested by some early PET studies (Ohyama et al., 1995; Price et al 1995). Clinical recovery is not only associated with the appearance of *new activation* in the right hemisphere, but also with the regression of functional depression in structurally unaffected regions of both hemispheres (Cappa et al., 1997). The recovery of the functional depression agrees with the demonstration that better language recovery occurs in individuals who have bilateral rather than right hemisphere-predominant activation (Cao et al., 1999). These findings were also recently reported by Heiss et al. (1999) in a PET study. This group found that complete and satisfactory recovery from aphasia can only be achieved as long as structures of the left superior temporal gyrus are preserved and can be reintegrated into language processing and production. The final answer, however, is not fully known: Patients in speech therapy improve their performance on the Token test as their right superior temporal gyrus and left precuneus show increase in blood flow measures (Musso et al., 1999). These studies performed in aphasia patients may be useful in understanding our results in calculation. Many reported cases of aphasia patients also have acalculia. We feel that theoretical conclusions from one may be applied to the other.

Our patient showed activation in the right PIPL area, the contra-

lateral homologous area involved in calculations in normal subjects. However, he did not significantly recover from his deficit. The patient succeeded in some basic calculations because they represented automatic memory-related processes, somehow mediated by the right hemisphere. Basic calculations involving small numbers (e.g., adding and subtracting one-digit numbers) have been demonstrated dissociated from other types of calculations (Stanescu-Cosson et al., 2000; Cohen et al., 2000), because of having a domain-specific representation (Dehaene et al., 1998). Therefore, this type of calculation can be spared in primary acalculia, as was the case in our stroke patient. He possibly was also performing a spontaneous “cognitive prosthesis” (i.e., he may have been using an alternative semantic category strategy to approximate the results in *serial subtracting by seven* paradigm, explaining activation of Brodmann’s area 37, otherwise not seen in the control group). Combining extrapolated information obtained from language studies, and our observations in the normal subjects, we feel that the right PIPL activation represents the remaining activation of a subsidiary circuitry. This circuitry previously did subservise calculation, but now cannot accomplish the task utilizing only the right PIPL module.

It may be assumed that the pattern of activation obtained corresponds to a redistribution of the workload over the pre-existing network, in which the right hemisphere was not crucial for calculation. This assumption has the support of previous reports in which biparietal activation was elicited in normal volunteers by calculation tasks (Chochon et al., 1999). Further investigations are needed to elucidate how redistribution is responsible for the so-called relocation and shifting phenomena, and if recovery is necessarily contingent upon these changes.

CONCLUSION

We present a case of acalculia in a patient with a left angular gyrus lesion, demonstrating on fMRI cortical activation related to mathematical tasks. The distribution of the obtained activation may be taken as brain “plasticity.” Findings taken from other functional-cognitive studies of language suggest a rewiring can occur without

significant functional recovery. In some cases, the so-called rewiring is just the redistribution of workload in a pre-existent network which may not truly be plasticity.

REFERENCES

- Babiloni, C., Carducci, F., Pizzella, V., Indovina, I., Romani, G. L., Rossini, P.M., & Babiloni, F. (1999). Bilateral neuromagnetic activation of human primary sensorimotor cortex in preparation and execution of unilateral voluntary finger movements. *Brain Research*, *827*, 234–236.
- Benson, D. F., & Ardila, A. (1996). *Aphasia: A clinical perspective*. New York: Oxford Press.
- Binder, J. (1997). Functional magnetic resonance imaging. Language mapping. *Neurosurgery Clinics of North America*, *8*, 383–392.
- Cao, Y., Vikingstand, E. M., George, K. P., Johnson, A. F., & Welch, K. M. (1999). Cortical language activation in stroke patients recovering from aphasia with functional MRI. *Stroke*, *30*, 2331–2340.
- Cappa, S. F., Perani, D., Grassi, F., Bressi, S., Alberoni, M., Franceschi, M., Bellinardi, V., Todde, S., & Fazio, F. (1997). A PET follow-up study of recovery after stroke in acute aphasics. *Brain and Language*, *56*, 55–67.
- Chochon, F., Cohen, L., van de Moortele, P. F., & Dehaene, S. (1999). Differential contributions of the left and right inferior parietal lobules to number processing. *Journal of Cognitive Neuroscience*, *11*, 617–630.
- Chollet, F., DiPiero, V., Wise, R. J., Brooks, D. J., Dolan, R. J., & Frackowiak, R. S. (1991). The functional anatomy of motor recovery after stroke in humans: A study with positron emission tomography. *Annals of Neurology*, *29*, 63–71.
- Cohen, L., Dehaene, S., Chochon, F., Lehericy, S., & Naccache L. (2000). Language and calculation within the parietal lobe: A combined cognitive, anatomical fMRI study. *Neuropsychologia*, *38*, 1426–1440.
- Corbett, A. J., McCusker, E. A., & Davidson, O. R. (1986). Acalculia following a dominant-hemisphere subcortical infarct. *Archives of Neurology*, *43*, 964–966.
- Dehaene, S., Dehaene-Lambertz, G., & Cohen, L. (1998). Abstract representations of numbers in the animal and human brain. *Trends in Neurosciences*, *21*, 355–361.
- Frackowiak, R. S. J. (1996). Plasticity and the human brain: Insights from functional imaging. *Neuroscientist*, *2*, 353–362.
- Fulbright, R. K., Molfese, D. L., Stevens, A. A., Skudlarski, P., Lacadie, C. M., & Gore, J. C. (2000). Cerebral activation during multiplication: A functional MR imaging study of number processing. *American Journal of Neuroradiology*, *21*, 1048–54.
- Gaymard, B., Ploner, C. J., Rivaud-Pechoux, S., & Pierrot-Deseilligny, C. (1999). The frontal eye field is involved in spatial short-term memory but not in reflexive saccade inhibition. *Experimental Brain Research*, *129*, 288–301.
- Gitelman, D. R., Parrish, T. B., LaBar, K. S., & Mesulam, M. M. (2000). Real-time monitoring of eye movements using infrared video-oculography during functional magnetic resonance imaging of the frontal eye fields. *Neuroimage*, *11*, 58–65.
- Hansson, T., & Brismar, T. (1999). Tactile stimulation of the hand causes bilateral cortical activation: A functional magnetic resonance study in humans. *Neuroscience Letters*, *271*, 29–32.
- Heiss, W. D., Kessler, J., Thiel, A., Ghaemi, M., & Karbe, H. (1999). Differential capacity of left and right hemispheric areas for compensation of poststroke aphasia. *Annals of Neurology*, *45*, 430–438.

- Kass, J. H. (1991). Plasticity of sensory and motor maps in adult mammals. *Annual Review of Neuroscience*, *14*, 137–167.
- Kennard, M. A. (1940). Relation of age to motor impairment in man and in subhuman primates. *Archives of Neurology and Psychiatry*, *44*, 377–397.
- Le, T. H., Pardo, J. V., & Hu, X. (1998). 4 T-fMRI study of nonspatial shifting of selective attention: Cerebellar and parietal contributions. *Journal of Neurophysiology*, *79*, 1535–1548.
- Le Clec'H, G., Dehaene, S., Cohen, L., Mehler, J., Dupoux, E., Poline, J. B., Lehericy, S., van de Moortele, P. F., & Le Bihan, D. (2000). Distinct cortical areas for names of numbers and body parts independent of language input modality. *Neuroimage*, *12*, 381–391.
- Lee, R. G., & van Donkelaar, P. (1995). Mechanisms underlying functional recovery following stroke. *Canadian Journal of Neurological Sciences*, *22*, 257–263.
- Maegaki, Y., Yamamoto, T., & Takeshita, K. (1995). Plasticity of central motor and sensory pathways in a case of unilateral extensive cortical dysplasia: Investigation of magnetic resonance imaging, transcranial magnetic stimulation, and short-latency somatosensory evoked potentials. *Neurology*, *45*, 2255–2261.
- Musso, M., Weiller, C., Kiebel, S., Müller, S. P., Bühlau, P., & Rijntjes, M. (1999). Training-induced brain plasticity in aphasia. *Brain*, *122*, 1781–1790.
- Nass, R. (1984). Case report: Recovery and reorganization after congenital unilateral brain damage. *Perceptual and Motor Skills*, *59*, 867–874.
- Ohyama, M., Senda, M., Terashi, A., Kitamura, S., Toyama, H., Ishii, K., & Mishina, M. (1995). A follow up PET activation study in aphasia due to cerebral infraction evaluates functional reorganization. *Journal of Cerebral Blood Flow and Metabolism*, *15* (Suppl.), S697.
- Petit, L., Clark, V. P., Ingeholm, J., & Haxby, J. V. (1997). Dissociation of saccade-related and pursuit-related activation in human frontal eye fields as revealed by fMRI. *Journal of Neurophysiology*, *77*, 3386–3390.
- Price, C., Warburton, E., Swinburn, K., Wise, R., & Frackowiak, R. (1995). Monitoring the recovery of aphasia using positron emission tomography. *Journal of Cerebral Blood Flow and Metabolism*, *15* (Suppl.), S696.
- Rijntjes, M., Weiller, C., Krams, M., Bauermann, H., Diener, C., & Faiss, J. (1994). Functional magnetic resonance imaging in recovery from motor stroke. *Stroke*, *25*, 60.
- Roland, P. E., & Friberg, L. (1985). Localization of cortical areas activated by thinking. *Journal of Neurophysiology*, *53*, 1219–1243.
- Rossini, P. M., Caltagirone, C., Castriota-Scanderbeg, A., Cicinelli, P., Del Gratta, C., Demartin, M., Pizzella, V., Traversa, R., & Romani, G. L. (1998). Hand motor cortical area reorganization in stroke: A study with fMRI, MEG and TCS maps. *Neuroreport*, *9*, 2141–2146.
- Rueckert, L., Lange, N., Partiot, A., Appollonio, I., Litvan, I., Le Bihan, D., & Grafman, J. (1996). Visualizing cortical activation during mental calculation with functional MRI. *Neuroimage*, *3*, 97–103.
- Simos, P. G., Papanicolaou, A. C., Breler, J. I., Fletcher, J. M., Wheless, J. W., Maggio, W. W., Gormley, W., Constantinou, J. E., & Kramer, L. (2000). Insights into brain function and neural plasticity using magnetic source imaging. *Journal of Clinical Neurophysiology*, *17*, 143–162.
- Stanesco-Cosson, R., Pinel, P., van De Moortele, P. F., Le Bihan, D., Cohen, L., & Dehaene, S. (2000). Understanding dissociations in dyscalculia: A brain imaging study of the impact of number size on the cerebral networks for exact and approximate calculation. *Brain*, *123*, 2240–2255.
- Thulborn, K. R., Carpenter, P. A., & Just, M. A. (1999). Plasticity of language-related brain function during recovery from stroke. *Stroke*, *30*, 749–754.
- Vandenberghe, R., Price, C., Wise, R., Josephs, O., & Frackowiak, R. S. (1996). Functional anatomy of a common semantic system for words and pictures. *Nature*, *383*, 254–256.

- Vargha-Khadem, F., Watters, G. V., & O’Gorman, A. M. (1985). Development of speech and language following bilateral frontal lesions. *Brain and Language*, *25*, 167–183.
- Weiller, C. (1998). Imaging recovery from stroke. *Experimental Brain Research*, *123*, 13–17.
- Weiller, C., Chollet, F., & Frackowiak, R. (1997). Physiological aspects of functional recovery from stroke. In J. Bogousslavsky, M. Ginsberg, & M. Hennerici (Eds.), *Cerebrovascular disease* (pp. 2057–2067) Oxford: Blackwell.
- Weiller, C., Isensee, C., Rijntjes, M., Huber, W., Müller, S., Bier, D., Dutschka, K., Woods, R. P., North, J., & Diener, H. C. (1995). Recovery from Wernicke’s aphasia: A positron emission tomographic study. *Annals of Neurology*, *37*, 723–732.
- Weiller C., Ramsey, S. C., Wise, R. J., Friston, K. J., & Frackowiak, R. S. J. (1993). Individual patterns of functional reorganization in the human cerebral cortex after capsular infarction. *Annals of Neurology*, *33*, 181–189.