

Visual Word Recognition in the Left and Right Hemispheres: Anatomical and Functional Correlates of Peripheral Alexias

L. Cohen^{1,2,3}, O. Martinaud^{1,2}, C. Lemer^{1,2}, S. Lehericy^{3,4}, Y. Samson⁵, M. Obadia⁵, A. Slachevsky⁶ and S. Dehaene^{2,3}

¹Institut de Neurologie, Hôpital de la Salpêtrière, AP-HP, Paris, France, ²INSERM U562, Service Hospitalier Frédéric Joliot, CEA/DSV, Orsay, France, ³IFR 49 (Institut d'Imagerie Neurofonctionnelle), France, ⁴Service de Neuroradiologie Fischgold, Hôpital de la Salpêtrière, AP-HP, Paris, France, ⁵Service des Urgences Cérébro-Vasculaires, Hôpital de la Salpêtrière, AP-HP, Paris, France and ⁶Centre d'Anatomie Cognitive, Hôpital de la Salpêtrière, AP-HP, Paris, France

According to a simple anatomical and functional model of word reading, letters displayed in one hemifield are first analysed through a cascade of contralateral retinotopic areas, which compute increasingly abstract representations. Eventually, an invariant representation of letter identities is created in the visual word form area (VWFA), reproducibly located within the left occipito-temporal sulcus. The VWFA then projects to structures involved in phonological or lexico-semantic processing. This model yields detailed predictions on the reading impairments that may follow left occipito-temporal lesions. Those predictions were confronted to behavioural, anatomical and functional MRI data gathered in normals and in patients suffering from left posterior cerebral artery infarcts. In normal subjects, alphabetic stimuli activated both the VWFA and the right-hemispheric symmetrical region (R-VWFA) relative to fixation, but only the VWFA showed a preference for alphabetic strings over simple chequerboards. The comparison of normalized brain lesions with reading-induced activations showed that the critical lesion site for the classical syndrome of pure alexia can be tightly localized to the VWFA. Reading impairments resulting from deafferentation of an intact VWFA from right- or left-hemispheric input were dissected using the same methods, shedding light on the connectivity of the VWFA. Finally, the putative role of right-hemispheric processing in the letter-by-letter reading strategy was clarified. In a letter-by-letter reader, the R-VWFA assumed some of the functional properties normally specific to the VWFA. These data corroborate our initial model of normal word perception and underline that an alternative right-hemispheric pathway can underlie functional recovery from alexia.

Introduction

The acquisition of literacy over years of education rests on the development of elaborate links between vision and language. On the one hand, the visual system learns how to identify rapidly letters and letter clusters across a wide range of shapes and viewing conditions. On the other hand, the verbal system learns how to segment explicitly the speech stream into discrete units such as syllables and phonemes (Morais and Kolinsky, 1994). Associations are established between letter strings and sounds, and between letter strings and lexical entries in memory, allowing the sounding out of newly encountered strings, and access to the stored knowledge attached to familiar words.

The efficiency of the adult reading system rests on its ability to identify rapidly and in parallel arrays of several letters. Indeed, word reading latencies are fairly constant irrespective of word length, at least within a range of ~3–6 letters (Weekes, 1997; Lavidor and Ellis, 2002). This perceptual ability takes ~5 years of instruction to develop, and an effect of word length persists at least to the age of 10 years (Aghababian and Nazir, 2000). Conversely, the breakdown of the expert visual processing of

alphabetic stimuli following brain lesions in literate adults results in impairments diversely known as pure alexia, alexia-without-agraphia, word blindness or agnosic alexia. Such patients typically have entirely preserved production and comprehension of oral language, and they can write normally either spontaneously or to dictation. However, they show various degrees of impairment of word reading. In the most severe cases, known as global alexia, they cannot identify single letters, let alone whole words (Dejerine, 1892). Other patients show preserved letter identification abilities and develop letter-by-letter reading strategies, as if only the most finely tuned mechanisms of word perception were affected, those allowing for rapid and parallel identification of letter strings.

Beyond the distinction between global and letter-by-letter alexia, cases of pure alexia may vary along several dimensions. Is the visual field entirely affected or is alexia restricted to one hemifield (Dejerine, 1892; Cohen and Dehaene, 2000)? Are there residual reading abilities in purely implicit reading tasks such as lexical decision, beyond the apparent inability to identify words (Coslett and Saffran, 1989; Coslett *et al.*, 1993)? Do patients have access to abstract letter identities, allowing them to decide that 'a' and 'A' are instances of the same grapheme (Miozzo and Caramazza, 1998; Mycroft *et al.*, 2002), etc.? Importantly, those diverse behavioural patterns all result from lesions confined to the territory of the left posterior cerebral artery. The crucial brain structures include the ventral occipito-temporal cortex, the underlying white matter and particularly the posterior interhemispheric callosal connections (Binder and Mohr, 1992).

Accounting for the diversity of behavioural patterns and for their anatomical and functional underpinnings is a benchmark for any model of word reading. The aim of this study is to confront a simple anatomical and functional model of reading with multimodal data from patients with various deficits affecting the visual stage of word processing (i.e. peripheral dyslexias). It should be clear that our model is relevant only to the visual stages of reading. It basically stops where so-called central processes start. Central processes comprise grapheme-to-phoneme mapping, lexical and semantic access, and their impairments correspond to central dyslexias such as surface and phonological dyslexias. In agreement with the scope of the model, the present study is restricted to varieties of peripheral dyslexias, and mainly to varieties of pure alexia.

We will first outline this model of visual word perception, and consider how it may account for a variety of reading impairments (Fig. 1).

Early Retinotopic Processing

The first stage of visual word processing is the analysis of letters in retinotopic areas, each half of foveal words being processed

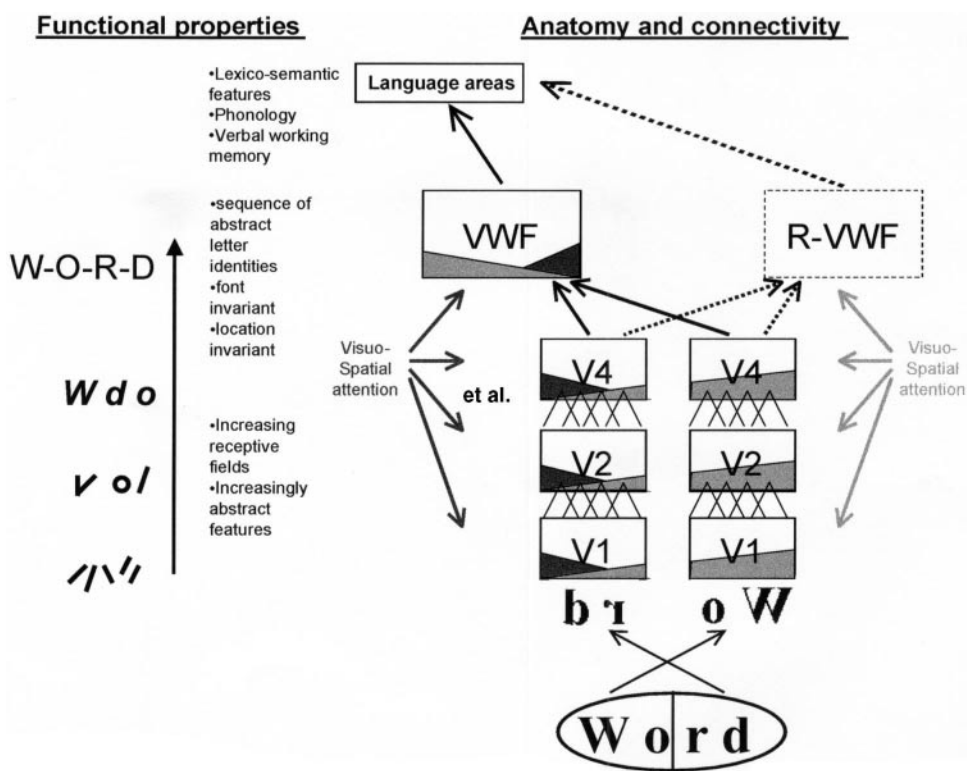


Figure 1. Model of the visual word processing system. Letters are first analysed through a cascade of contralateral areas ranging from V1 to V4, which compute increasingly abstract representations. Eventually, an invariant representation of letter identities is created in the VWFA, located within the left occipito-temporal sulcus. The VWFA then projects to structures involved in phonological or lexico-semantic processing. Spatial attention (here represented by dark and light gray gradients) modulates the operation of all levels of word processing up to the VWFA, with a right-hemispheric predominance. The right-hemispheric region symmetrical to the VWFA (R-VWFA) is thought to subtend residual letter identification in patients with letter-by-letter reading. Letter identities are then transferred to language areas across the corpus callosum.

in the contralateral hemisphere. Visual input is represented in increasingly abstract and invariant format through areas V1–V4. The activation of such areas, located between about Talairach coordinates (TC) $y = -90$ and $y = -70$, is modulated by physical parameters such as word length, visual contrast (Mechelli *et al.*, 2000), stimulus degradation (Jernigan *et al.*, 1998; Helenius *et al.*, 1999), stimulus rate and duration (Price *et al.*, 1996a; Price and Friston, 1997). Moreover, there are indications, mostly behavioural, that perceptual processing differs between the right (RH) and the left hemisphere (LH). Thus the absence of a word length effect on reading latencies is restricted to optimal viewing conditions, such as free foveal reading of horizontally displayed stimuli (Lavidor *et al.*, 2001; Lavidor and Ellis, 2002). In such conditions, the optimal gaze position for reading is left of word centre (Nazir, 2000), suggesting that parallel processing is mostly a property of the right visual field (RVF). Indeed, split-field studies show that while there is no length effect for words displayed in the RVF, such an effect emerges whenever words are displayed in the left visual field (LVF) (Lavidor and Ellis, 2002). Accordingly, when words extend across central fixation, only their left part induces a length effect (Lavidor *et al.*, 2001).

The left and right visual systems also differ in their tendency to represent alphabetic characters in a format invariant for specific case and font. A number of studies, using mostly priming tasks with split-field stimuli, have shown that alphabetic strings are encoded in a format less dependent on physical shape and case when they are viewed in the RVF than in the LVF (Marsolek *et al.*, 1992; Marsolek *et al.*, 1996; Burgund and Marsolek, 1997),

probably reflecting non-specific processing asymmetries in the visual system (Marsolek, 1995; Burgund and Marsolek, 2000). Accordingly, using a masked priming paradigm, Dehaene *et al.* (2001) have evidenced case-specific physical repetition priming in the right more than in the left extrastriate cortex. Finally, Cohen *et al.* (2002) identified left occipital activations (TC -24 – -78 – -12) distinguishing alphabetic strings from chequerboards, but only for RVF stimulations, a further correlate of the hemispheric asymmetry in word perception. In summary, there are indications that the left posterior visual system is crucial for important features of expert reading, namely the fast and parallel computation of abstract letter identities.

Left Visual Word Form Area

This process culminates in the computation of the visual word form, a representation of abstract letter identities invariant for parameters such as spatial position, size, font or case. On the basis of brain imaging evidence, we have proposed that this representation is subtended by a definite cortical region in Brodmann's area 37, the so-called visual word form area (VWFA). Note that we refer to this region as the VWFA for the sake of simplicity, although it should be clear that this denomination rests on functional hypotheses that are still open to debate (McCandliss *et al.*, 2003). This region, which activates ~ 200 ms after stimulation (Tarkiainen *et al.*, 1999), is reproducibly located within the occipito-temporal sulcus bordering the left fusiform gyrus laterally (for a review of activations, see Cohen and Dehaene, 2000). Following the scheme proposed by Malach

et al. (2002), the VWFA is a subdivision of the ventral occipito-temporal cortex devoted to high-order object perception, other subdivisions showing preferences for categories such as faces or buildings (Kanwisher *et al.*, 1997; Ishai *et al.*, 1999). Thus, the VWFA is activated by alphabetic strings relative to fixation but also relative to complex non-alphabetic stimuli such as false fonts, faces or geometrical patterns (e.g. Price *et al.*, 1996b; Puce *et al.*, 1996; Cohen *et al.*, 2002). The VWFA is activated by visual but not auditory words (Dehaene *et al.*, 2002), irrespective of their position in the visual field (Cohen and Dehaene, 2000). It represents alphabetic stimuli in an abstract graphemic format. Using the masked priming paradigm mentioned before, Dehaene *et al.* (2001) have shown a reduced activation of the VWFA whenever a target word is primed by the subliminal presentation of the same word. Importantly, this effect prevails whether the prime and the target are printed in the same or in different cases.

Those functional properties of the VWFA may result from more general features of inferotemporal (IT) neurons, already present in monkeys, such as preference for semi-complex shapes analogous to letters (Tanaka, 1996), invariance for viewing conditions (Booth and Rolls, 1998; Grill-Spector *et al.*, 1999), or preference for foveal stimuli (Levy *et al.*, 2001). One may even speculate that the equivalence between upper- and lower-case letters is afforded by the property of IT neurons to establish links between stimuli with arbitrary but cognitively meaningful connections (Sakai and Miyashita, 1991). In the same vein, the binding of letters into words might be related to the representation of complex objects in IT cortex through the coactivation of neurons tuned to their elementary parts (Tsunoda *et al.*, 2001).

Afferents and Efferents of the VWFA

The transfer of visual information from lower-order retinotopic cortices to the VWFA takes place within the LH for stimuli displayed in the RVF. For LVF stimuli, information is conveyed from the right to the left ventral occipito-temporal cortex through interhemispheric fibre tracts that course in the splenium of the corpus callosum and over the posterior horns of the lateral ventricles (Binder and Mohr, 1992; Molko *et al.*, 2002). The output projections of the VWFA to systems involved in lexical, semantic, motor or phonological processes are less clearly defined. Following the observation of cases of alexia-with-agraphia, Dejerine (1892) suggested that the next step following visual word processing would be the angular gyrus, which he postulated to be the 'visual center of letters' (Fig. 2). Indeed, the angular gyrus is among the regions that may be activated during reading tasks (Price, 1997), and there are indications of a functional connectivity between the angular gyrus and the left fusiform gyrus at coordinates matching the VWFA (Horwitz *et al.*, 1998). There is also a correlated activity in the region of the VWFA and in left inferior frontal areas (Bokde *et al.*, 2001). A further potential output pathway is to temporal regions anterior to the VWFA. These regions, which are difficult to image with functional magnetic resonance imaging (fMRI) due to magnetic susceptibility artifacts, are probably involved in supramodal semantic processing (for a review, see Giraud and Price, 2001; see also Kreiman *et al.*, 2000; Lambon Ralph *et al.*, 2001).

Top-down Influences

One should remember that the operation of ventral visual regions depends not only on the features of external stimuli, but

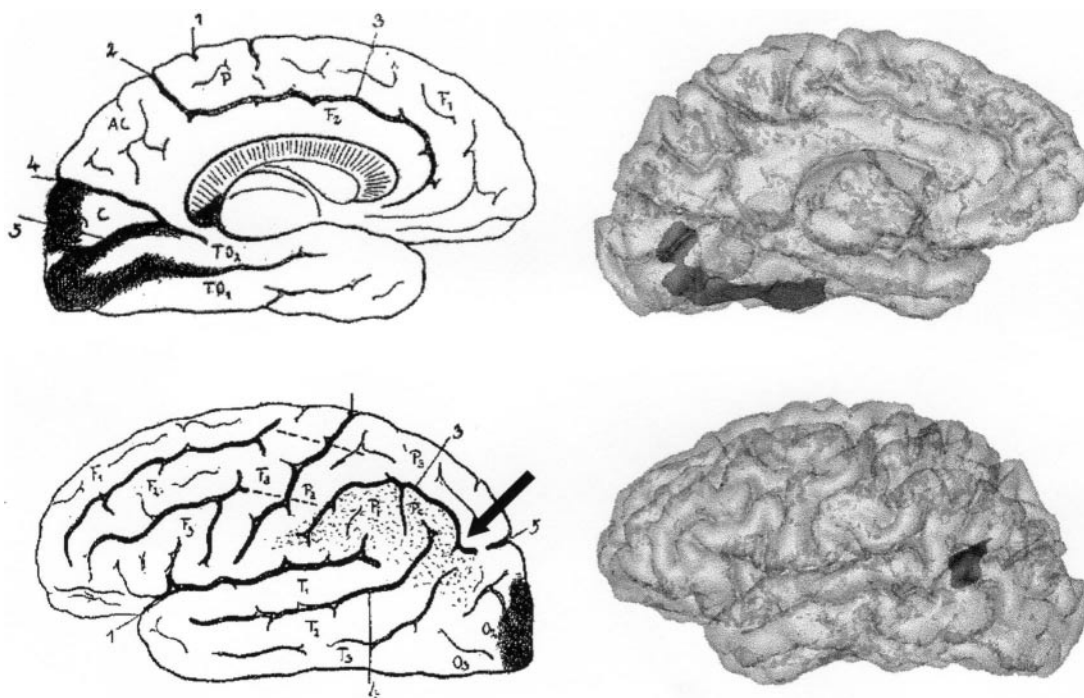


Figure 2. Confrontation of Dejerine's (1892) original lesion drawings (left column) with fMRI activations in control subjects from the present study (right column). Top row: ventral occipito-temporal lesion responsible for pure alexia, and activations by alphabetic stimuli versus chequerboards. Bottom row: left angular lesion responsible for alexia-with-agraphia (dotted), and activations by real words versus consonant strings.

also on top-down attentional influences that may impinge on all processing levels, from striate cortex (Chawla *et al.*, 1999; Somers *et al.*, 1999) to the ventral occipito-temporal cortex. Indeed, an increased activation of the VWFA during the perception of written words, probably triggered by frontal control, predicts a better storage of those words in memory (Wagner *et al.*, 1998). Finally, as word representations are spatially organized in the visual system, special reference should be made to spatial attention (Corbetta and Shulman, 1998; Gitelman *et al.*, 1999). Thus, Hillis and Caramazza (1995) suggested that the varieties of neglect dyslexia may be attributed to spatial attentional biases acting on one or more of the successive word representations ranging from peripheral viewer-centred representations to the abstract visual word form (Fig. 1) (for a review of supportive data see Haywood and Coltheart, 2000). There is a right parietal predominance in the control of spatial attention: The RH regulates the distribution of attention across the entire extrapersonal space, while the LH's influence is predominantly affected to the contralateral right hemispace (Gitelman *et al.*, 1999; Vallar, 2001).

Predictions

This framework generates explicit behavioural, anatomical and functional predictions on the varieties of reading impairment that may follow left posterior cerebral artery (PCA) infarcts. In line with Warrington and Shallice's hypotheses (Warrington and Shallice, 1980), the clearest prediction is that the destruction of the VWFA should result in pure alexia. Indeed, despite Dejerine's interpretation of pure alexia as a disconnection syndrome, cases exist of pure alexia following cortical lesions (e.g. Beversdorf *et al.*, 1997). We describe a similar case (patient F).

A second prediction is that a complete loss of input to or output from the VWFA should also yield pure alexia. The anatomical case reported by Greenblatt (1973) may be an instance of deafferentation of an intact fusiform cortex. Conversely, the so-called subangular alexia may correspond to the output variant of pure alexia, due to disrupted projections to lateral language areas during their course in the parietal white matter (Greenblatt, 1976; Pirozzolo *et al.*, 1981; Iragui and Krichevsky, 1991). Another prediction is that partial lesions to the input pathways to the VWFA should lead to alexia restricted to part of the visual field. Indeed, alexia restricted to the LVF results from interhemispheric lesions disconnecting the VWFA from RH visual regions (Cohen and Dehaene, 2000). Similarly, the few reported cases of alexia restricted to the RVF may be due to left intrahemispheric lesions deafferenting the VWFA but sparing low-level visual regions (Castro-Caldas and Salgado, 1984). Here, we describe two new cases, one with left alexia (patient D), the other with right hemianopic alexia (patient M).

In cases where the VWFA is spared, right hemianopia by itself should not yield pure alexia. Nevertheless, lesions affecting left occipital regions may disrupt the fast and parallel analysis of letter strings specific to the right hemifield, and induce some degree of length effect in word reading (Leff *et al.*, 2001), analogous to the moderate length effect observed in normal subjects reading LVF words (Lavidor and Ellis, 2002). We test this prediction by contrasting the reading speed of our patients D and M.

Among the still unspecified features of the model, one should mention the role of the right-hemispheric region symmetrical to the VWFA, which we will call the R-VWFA for the sake of

brevity. This region is activated by visual words relative to fixation, although less strongly and less reproducibly across subjects than the VWFA proper (Puce *et al.*, 1996; Cohen *et al.*, 2002). It does not show the same preference for alphabetic stimuli over geometric shapes as the VWFA (Cohen *et al.*, 2002), and may not represent letters in a case invariant format (Dehaene *et al.*, 2001). The fact that right occipito-temporal lesions do not induce alexia also indicates that the R-VWFA does not play a necessary role in the reading network. However, it is plausible that the R-VWFA contributes to residual reading abilities in pure alexic patients. Bartolomeo *et al.* (1998) studied a patient with letter-by-letter reading due to a left PCA infarct. Following a symmetrical right occipito-temporal infarct, she subsequently lost most of her residual reading abilities. This observation agrees with a classical account of letter-by-letter reading according to which letters would be identified by the intact right hemisphere and their identity sequentially transferred to left-hemispheric language areas, in a kind of internal spelling process (Binder and Mohr, 1992). There are also indications that residual implicit reading abilities, apparent, for instance, in lexical or semantic decision tasks, may also rest on right-hemispheric word identification (Coslett and Monsul, 1994; Coslett and Saffran, 1998). These issues are still open, but a tentative prediction may be that, in case of lesion of the VWFA, its right-hemispheric homologue assumes at least part of its functional role. We tested this hypothesis in patient F.

In summary, we studied the reading abilities of three patients suffering from left PCA infarcts, and showing different patterns of reading impairment, presumably resulting from deafferentation or disruption of the visual word form: left alexia following interhemispheric disconnection (patient D); alexia resulting from right hemianopia (patient M); and pure alexia with letter-by-letter reading (patient F). To clarify the underlying mechanisms we gathered anatomical and functional imaging data, in addition to behavioural observations. Complementary anatomical data from three further patients with callosal alexia, letter-by-letter reading and global alexia will be included. These multimodal data were confronted to the anatomical and functional model outlined above. The analysis of activation data concentrated on the VWFA, which is at the core of the model, and on its symmetrical region in the RH, whose role in residual reading we attempted to clarify. We also report a similar fMRI study of reading in a group of control subjects.

General Methods

Subjects

Three right-handed patients suffering from an infarct in the territory of their left PCA were studied. Their medical history will be described in detail below. Nine healthy subjects (seven females), aged between 42 and 68 years (mean 60 years), participated in the study as controls. They were all right-handed according to the Edinburgh Inventory, except for one ambidextrous man (Oldfield, 1971). Their vision was corrected to normal. All were drug free, had no neurological or psychiatric history, and had normal anatomical MRIs. All controls and patients gave their written informed consent and the project was approved by the Ethical Committee of the Hôpital de Bicêtre.

Behavioural Assessment

Acquired dyslexias resulting from a disruption of visual word processing are characterized by a contrast between impaired

processing of printed stimuli and normal performance in non-visual language tasks. Therefore patients were assessed using (i) reading tasks, which were expected to be impaired (timed word and letter reading, story reading); (ii) non-visual tasks involving alphabetic stimuli, which were expected to be generally spared (word dictation, identification of orally spelled-out words); (iii) tests of oral language production and comprehension, which were also expected to be spared; and (iv) two additional tasks evaluating the access to abstract letter identities from upper- and lower-case letters, which may be impaired in some pure alexic patients.

Word Reading

Stimuli consisted of 165 lower-case familiar nouns (mean \log_{10} frequency per million = 2.4), 3–9 letters and 1–4 syllables in length. They were presented centrally on a computer screen, subtending a maximum angle of 4° on each side of fixation. Subjects were asked to read each word aloud rapidly, while minimizing errors. Stimuli remained visible until a response was produced. Latencies were measured using a voice key, and sessions were recorded for subsequent scoring of errors.

Other Language Tasks

Subjects were asked to read aloud a short story of ~15 lines, to write to dictation a subset of 36 items from the word reading list, and to identify another subset of 36 words orally spelled-out by the examiner. Subjects were also asked to name 52 letters (all upper-case and lower-case letters in random order), using the same procedure as for word reading.

The access to abstract graphemes was assessed using two further tasks. First, subjects were presented with 10 upper-case and 10 lower-case letters and were asked to write down each letter in the opposite case. Second, they were presented with 80 pairs of letters horizontally displayed on a computer screen. The two letters in a pair were printed in different cases, and subjects had to decide whether the two letters corresponded to the same grapheme (e.g. a A) or not (e.g. a B), and to respond using one of two keys. In those two tests, only letters with widely different upper- and lower-case shapes were used.

A short evaluation of oral language was also performed. Subjects were asked to describe the Cookie Theft picture from the Boston Diagnostic Aphasia Examination, to perform the sentence comprehension subtest no. 6 from the Token Test, and to name a set of 80 line drawings.

Brain Imaging

Procedure

Subjects were presented with four types of stimuli: a fixation point, real words, consonant strings, and chequerboards covering approximately the same field as letter strings. The 128 words were a subset of the list used for the behavioural assessment. Consonant strings were matched one-to-one to real words in number of letters. The frequency distribution of consonants was the same in consonant strings as in words. Stimuli were presented centrally for 1700 ms, followed by a 800 ms fixation point. Subjects were instructed to pay attention equally to all types of stimuli and to read real words covertly.

Subjects received four fMRI sequences, each comprising 16 experimental blocks, i.e. four blocks of each condition. Each block comprised eight trials. Blocks were presented in pseudo-random order within sequences, so as to maximize the variety of

transitions between conditions while avoiding any repetition of the same condition in successive blocks. Trials were presented in random order within blocks. The order of blocks within sequences and the order of trials within blocks differed across the four sequences, but were identical for all subjects.

Imaging Parameters

Each sequence consisted of 10 s of initial fixation, followed by 16 stimulation blocks of 20 s each, as described before. In each sequence, 132 functional volumes sensitive to blood oxygen level dependent (BOLD) contrast were acquired with a T2-weighted gradient echo, echo planar imaging sequence on a 1.5 T Signa Imager [T_R (relaxation time) = 2500 ms, α (flip angle) = 90° , T_E (echo time) = 60 ms, field of view = 240×240 mm, in plane resolution = 3.75×3.75 mm²]. Each volume comprised 17 axial slices of 5 mm thickness covering most of the brain. The first four volumes were discarded to reach signal equilibrium. High-resolution T1-weighted images [3-D fast gradient-echo inversion recovery sequence, TI (inversion time) = 400 ms, T_R = 11 ms, T_E = 2 ms, α = 20° , field of view = 240×240 mm, slice thickness = 1.5 mm, in-plane resolution = 0.94×0.94 mm²] were also acquired for anatomical localization, as well as T2-weighted fast spin echo and FLAIR axial slices.

Analysis of MRI data

Functional images were analysed with the Statistical Parametric Mapping software (SPM99). To correct for motion, functional scans were realigned using the first image as a reference. The anatomical image was linearly transformed to TC (Talairach and Tournoux, 1988) using the standard template of the Montreal Neurological Institute. In patients, we checked that masking the lesion and using non-linear normalization parameters did not improve the eventual match with the template (Brett *et al.*, 2001). The functional scans were then normalized using the same transformation. Functional images were smoothed with a Gaussian spatial filter (5 mm FWHM). The resulting images had cubic voxels of $3 \times 3 \times 3$ mm³. For single-subject analyses, activation on each of the four types of trials was modelled by a combination of the standard SPM haemodynamic function and its temporal derivative. Only the former function was used for statistical contrasts. Four additional variables of non-interest modelled constant differences across the four sequences. Long-term signal variations were eliminated with a high-pass filter set at 240 s. Low-pass filtering was achieved by convolution with the haemodynamic response function. Data from the group of normal subjects were submitted to a random-effect group analysis with subjects as random variable (voxelwise threshold $P < 0.005$; cluster-level $P < 0.05$ corrected). In analyses of individual patients we used a voxelwise threshold of $P < 0.001$ and cluster-level $P < 0.05$ corrected, unless stated otherwise.

The patients' lesions were drawn manually on the basis of the anatomical MRIs using the MRicro software (<http://www.psychology.nottingham.ac.uk/staff/cr1/micro.html>), then smoothed (4 mm FWHM filter), thresholded (>0.5), and normalized with the same matrix as anatomical images.

Results in Normal Subjects

Behavioural Assessment

As expected, performance was essentially at ceiling on all subtests (Table 1). In particular, subjects made no errors in the story, word and single letter reading tasks. The mean reading

latency for words was 534 ms, and increased by an average 6 ms per letter (Fig. 3). Actually, latencies were exactly constant for words of 3–6 letters, and then increased by 12 ms per additional letter ($P < 0.05$).

fMRI Study

In order to identify the brain areas involved in alphabetic processing, we first contrasted alphabetic stimuli (i.e. words and consonant strings) relative to fixation, revealing a large bilateral network (Fig. 3 and Table 2). In both hemispheres, the highest peaks of the parieto-occipito-temporal cluster were ventral occipital [left: TC -21 -90 -3; $t(8) = 9.4$; right: TC 48 -75 -12; $t(8) = 12.3$] and fusiform [left: TC -42 -63 -15; $t(8) = 8.7$; right: TC 36 -63 -18; $t(8) = 13.1$]. Note that the left fusiform cluster peaking at TC -42 -63 -15, and extending anteriorly to about $y = -42$, matched very closely the coordinates of the VWFA as identified in a number of previous studies. Note also that the activation of the symmetrical right-hemispheric region (R-VWFA) was comparable to the VWFA itself, with t -values of 13.1 versus 8.7.

In order to identify activations more specific to reading, we contrasted alphabetic stimuli versus chequerboards. This comparison revealed a strongly left-lateralized frontal, parietal, occipital and temporal network (Fig. 3 and Table 2). Contrary to what prevailed when alphabetic stimuli were contrasted with fixation, occipital and temporal activations were now restricted to the left hemisphere. The left occipito-temporal cluster peaked at TC -36 -75 -12 [$t(8) = 10.1$], extended anteriorly to $y = -33$,

and included the region of the VWFA ($P < 0.01$ at the peak voxel TC -42 -63 -15). In the right hemisphere, there was no significant occipito-temporal activation. Note however a small right occipital cluster that did not reach the threshold for cluster extent [TC 45 -78 -12; $t(8) = 8.4$; 55 voxels]. In particular, the R-VWFA, despite its very strong activation by alphabetic stimuli versus fixation, did not differ between alphabetic stimuli and chequerboards ($P > 0.05$ at the peak voxel TC 36 -63 -18).

We then examined the influence of lexical status on brain activations (Table 2 and Fig. 3). The contrast of words versus consonant strings activated a left angular region [TC -45 -63 27; $t(8) = 5.7$], and a midline cluster in the bilateral posterior cingulate gyri [TC -3 -33 33; $t(8) = 8.40$]. Note that for both these regions, this difference reflected a deactivation by consonant strings relative to fixation, with no significant change in activation for real words. For instance at the peak of the angular cluster, $t(8) < 1$ for words versus fixation, and $t(8) = 4.96$ ($P = 0.001$) for fixation versus consonants.

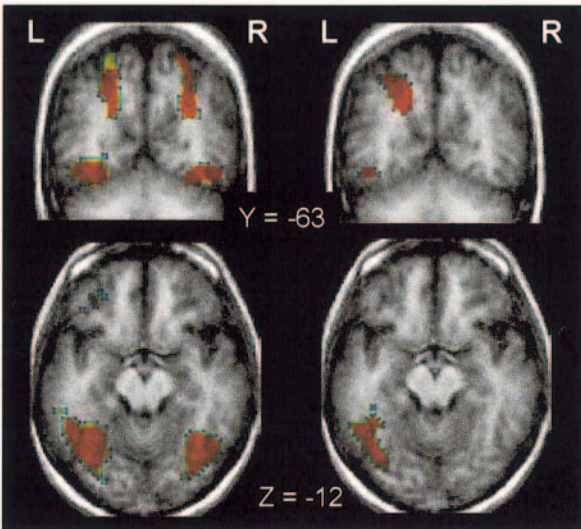
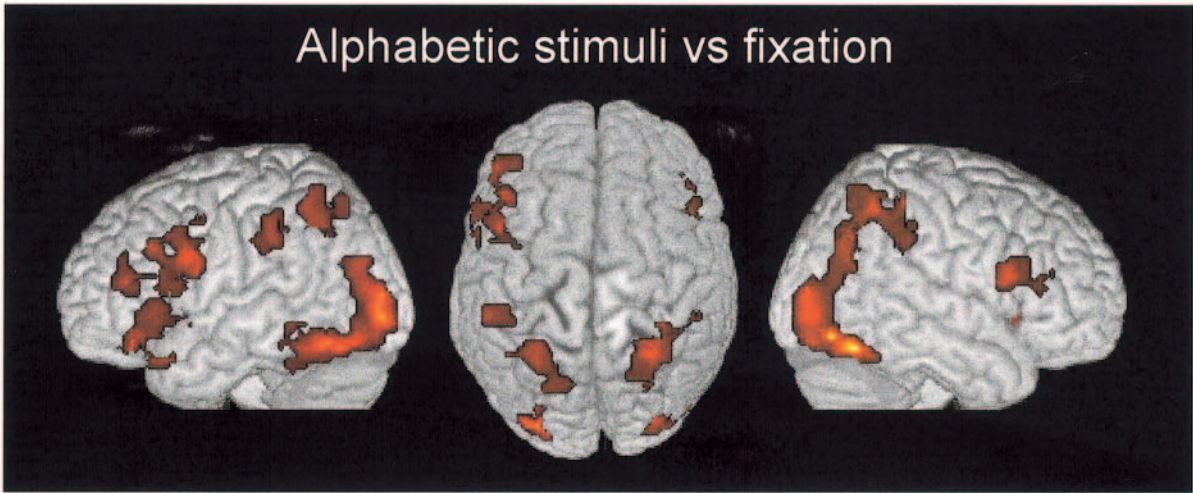
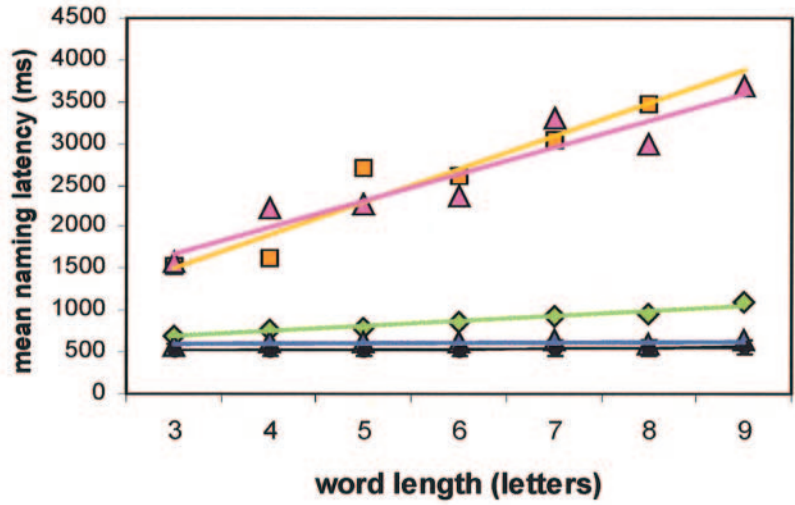
Conversely, bilateral posterior occipito-parietal regions were activated by consonant strings relative to real words (left: TC -33 -87 12 and TC -21 -51 63; right 27 -72 12 and TC 21 -60 63; Table 2). There was also right postcentral and right lateral frontal clusters. Note that at a low statistical threshold, the region of the VWFA and its right-hemispheric counterpart appeared to be activated by consonant strings more than by real words (voxelwise $P < 0.05$; $P < 0.05$ for cluster extent corrected within a 12 mm sphere centred on the peak voxels as identified with the contrast of alphabetic stimuli versus fixation).

Table 1

Performance of patients and control subjects in language tasks (% correct responses)

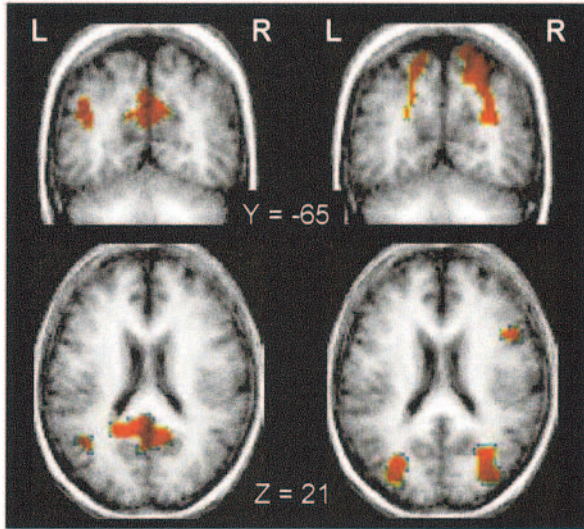
	Patient D	Patient M	Patient F	Normal subjects (mean)
Cookie theft description	normal	normal	normal	normal
Picture naming	79/80 (99%)	79/80 (100%)	78/80 (97%)	99%
Token test (VI)	12/13 (92%)	12/13 (92%)	10/13 (77%)	87%
Timed story reading (duration)	40 s	52 s	4 min 09 s	35 s
Writing words to dictation	36/36 (100%)	36/36 (100%)	34/36 (94%)	98%
Identification of spelled out words	33/36 (92%)	33/36 (92%)	34/36 (94%)	95%
Cross-case letter matching	77/80 (96%)	79/80 (99%)	76/80 (95%)	96%
Cross-case letter conversion	20/20 (100%)	20/20 (100%)	20/20 (100%)	97%
Free-field word reading				
No. correct (%)	165/165 (100%)	165/165 (100%)	158/165 (96%)	100%
Mean latency (ms)	607	849	2547	539
Free-field letter reading				
No. correct (%)	52/52 (100%)	52/52 (100%)	52/52 (100%)	100%
Mean latency (ms)	663	640	817	558

Figure 3. Behavioural and fMRI correlates of normal reading. Top: normal controls (black) showed no influence of word length on reading latencies. Patient D, who had an intact VWFA and no hemianopia showed a normal pattern (blue). Patient M, who had an intact VWFA and right hemianopia, showed a moderate length effect (green). Patients F (magenta) and A (yellow), whose VWFA was lesioned, read words letter-by-letter, with a slope of over 300 ms per letter. Middle: cortical network activated by alphabetic stimuli relative to fixation in normal subjects, including bilateral ventral temporal areas (voxelwise $P < 0.005$; corrected $P < 0.05$ for cluster extent). Bottom left: bilateral ventral temporal areas activated by alphabetic stimuli relative to fixation. When contrasting alphabetic stimuli versus chequerboards, activations were restricted to the left-hemispheric VWFA. Bottom right: left angular and posterior cingulate activations induced by real words relative to consonant strings. The opposite contrast revealed bilateral posterior parieto-occipital activations.



Alphabetic vs fixation

Alphabetic vs chequerboards



Words vs consonants

Consonants vs words

Table 2
Group analysis of the fMRI word reading experiment in nine normal subjects

Side	Area	Cluster		Peak voxel	
		<i>P</i> corrected	No. of voxels	Z score	TC
Alphabetic stimuli versus fixation					
Right	Fusiform gyrus	<0.001	1058	4.87	36 –63 –18
Right	Ventral occipital			4.78	48 –75 –12
Left	Ventral occipital	<0.001	1062	4.35	–21 –90 –3
Left	Fusiform gyrus			4.23	–42 –63 –15
Left	Thalamus	0.007	97	4.14	–24 –18 3
Left	Lenticular nucleus	<0.001	364	3.92	–24 0 –3
Left	Inf. Frontal sulcus	<0.001	254	3.78	–45 9 27
Right	Inf. Frontal sulcus	0.005	102	3.65	45 15 18
Left	Dorsolateral prefrontal	0.010	90	3.49	–48 39 15
Right	Lenticular nucleus	0.019	80	3.41	24 18 –6
Left	Supramarginal gyrus	<0.001	143	3.34	–51 –33 39
Alphabetic stimuli versus chequerboards					
Left	Ventral occipital	<0.001	340	4.48	–36 –75 –12
Left	Fusiform gyrus			3.44	–36 –45 –27
Left	Inf. Frontal sulcus	<0.001	708	4.33	–36 12 18
Left	Cingulate sulcus	<0.001	160	3.70	–12 27 33
Right	Inf. Frontal sulcus	<0.001	213	3.45	45 36 21
Left	Intraparietal sulcus	<0.001	190	3.41	–18 –60 30
Right	Lenticular nucleus	0.042	76	3.20	24 6 –3
Words versus consonant strings					
Bilateral	Posterior cingulate	<0.001	761	4.17	–3 –33 33
Left	Angular gyrus	0.043	62	3.50	–45 –63 27
Consonant strings versus words					
Left	Occipito-parietal	<0.001	602	4.25	–33 –87 12
				3.75	–21 –51 63
Right	Occipito-parietal	<0.001	747	3.87	27 –72 12
				3.52	21 –60 63
Right	Post-central	0.050	60	3.66	48 –21 54
Right	Inferior frontal gyrus	0.006	89	3.54	51 9 12

Discussion

Relative to fixation, the processing of alphabetic stimuli activated a bilateral network, with a left-sided predominance mostly visible in the frontal lobes. This network included activations in the left ventral occipito-temporal cortex precisely corresponding to the coordinates of the VWFA. There was a right-sided symmetrical activation, but the functional properties of those symmetrical regions appeared quite different: the VWFA was activated by alphabetic stimuli relative to chequerboards, while the R-VWFA reacted identically to both, confirming that the VWFA has some degree of specialization for alphabetic processing. We also observed a more posterior left occipital activation for alphabetic stimuli versus chequerboards. In our previous study (Cohen *et al.*, 2002) this region was associated exclusively with the processing of RVF stimuli. In the present study however, its properties appeared indistinguishable from

those of the VWFA in the present study, as stimuli were spread over both hemifields.

The VWFA was slightly more activated by consonant strings than by real words. This could appear as a surprise, as previous studies have shown the opposite pattern in both blocked-design and event-related experiments (Price *et al.*, 1996b; Büchel *et al.*, 1998; Xu *et al.*, 2001; Cohen *et al.*, 2002). However, this discrepancy likely results from systematic differences in the experimental paradigms. In our previous study (Cohen *et al.*, 2002), stimuli were displayed very briefly (200 ms) in a lateral position (beyond 2° of eccentricity). In such conditions, the fast identification of familiar words was possible, but meaningless consonant strings were impossible to scan and their components letters were difficult to identify. In contrast, the present task setting emphasized the processing of consonant strings, by providing a long (1700 ms) and central display. As instructions

encouraged subjects to pay as much attention to consonant strings as to real words, it is likely that subjects attentively scanned the stimuli, enhancing the activation of the ventral regions involved in visual processing. This hypothesis is supported by the major activations elicited by consonant strings versus words in the bilateral superior parietal lobules. Those activations fell at coordinates virtually identical to those observed in tasks of spatial attentional control (Gitelman *et al.*, 1999; Simon *et al.*, 2002). Tagamets *et al.* (2000) observed a pattern very similar to the present one: Activation of the VWFA did not differ between consonant strings and words, while consonant strings induced an increased parietal activation relative to words, again at coordinates close to ours. Thus, it appears that the VWFA is activated by essentially any orthographic string, with significant modulations that depend both on the experimental task, and on the orthographic legality of the string.

Despite the strong attentional demands entailed by the processing of consonant strings, we expected that some language-related areas should still be activated more strongly by real words. Indeed, the left angular gyrus showed such a lexicality effect. The angular cortex has long been recognized as a core supramodal language area. Its central role in reading and writing has been advocated by Dejerine in his seminal studies (Dejerine, 1891, 1892). Observing that angular lesions yielded alexia-with-agraphia, he surmised that the angular gyrus could be the repository of 'visual images' of words, involved in both reading and writing. Beyond this precise hypothesis, data from patients and from brain imaging in normals are consistent with the more general idea that the angular gyrus is a crucial transmodal interface between auditory or visual word forms and stored lexico-semantic knowledge (Mesulam, 1998). Naturally, such processes would not be relevant to the perception of consonant strings, which have no lexical content and do not even bear a resemblance to real words, explaining the difference in activation levels.

We noted that the left angular gyrus was activated at similar levels during word reading and during simple fixation, while its activation was significantly lower during inspection of consonant strings. This observation does not undermine the reality of the lexicality effect, but may give further clues on the functional properties of the angular gyrus. Recent imaging studies and meta-analyses have shown that a number of cortical areas often have a higher level of activation during the so-called 'rest conditions' than during attention-demanding cognitive tasks (Binder *et al.*, 1999; Gusnard and Raichle, 2001; Mazoyer *et al.*, 2001; Raichle *et al.*, 2001). It has been suggested that this may reflect tonic cognitive processes occupying the 'rest' periods; such processes would be interrupted or inhibited by more attention-demanding tasks. Although the exact cognitive content of this 'default brain state' is still largely unknown, the set of concerned areas seems relatively well defined. Foremost among them appear the two areas that were activated by words versus consonant strings, i.e. the angular gyrus and the posterior cingulate cortex. A favourite hypothesis concerning the posterior cingulate emphasizes its role in the continuous monitoring of the peripersonal world, an activity which may be interrupted whenever focused attention is required (Vogt *et al.*, 1992; Gusnard and Raichle, 2001), which is the case during the processing of consonant string. Regarding the left angular gyrus, one may speculate that it is involved in some inner speech or conceptual activity, ongoing both during fixation and during the passive recognition of familiar words. Only when scanning consonant

strings would subjects inhibit this basic tonic language process. Binder *et al.* (1999) have observed results closely similar to ours in the auditory modality. Relative to a resting state, the left angular gyrus was deactivated during an auditory perceptual task or a phonological task with non-words, while a semantic retrieval task maintained the activation at the same level as during rest.

To conclude with a historical point, one may note that the present activation data converge nicely with Dejerine's anatomical observations, in pointing to the left fusiform and angular gyri as key structures for the visual and linguistic processing of written words, respectively (Fig. 2).

We now turn to the study of patients suffering from an infarct of the left PCA. Depending on their precise topography, such lesions should affect to various degrees the left ventral occipito-temporal regions whose activations were evidenced in normal subjects. Within this area, the VWFA is thought to play a key role in reading, and its disruption is expected to yield pure alexia.

Left Hemialexia: Patient D

Medical History and Lesion Description

Patient D was a 63-year-old retired male computer engineer. One year before the present study, he suffered from an infarct in the territory of the left PCA, revealed by mild right-sided hemiparesis, a right homonymous visual scotoma and transient word-finding difficulties.

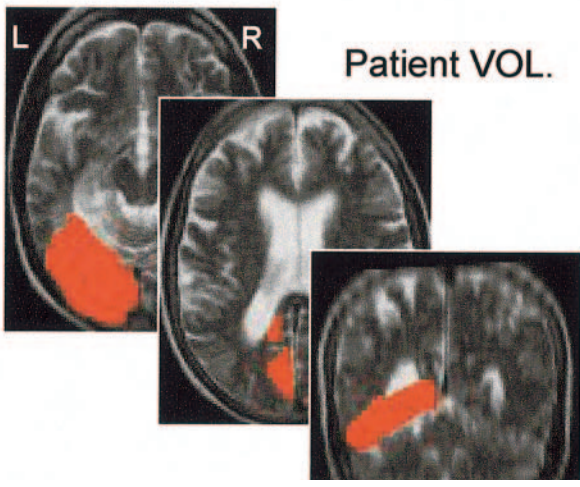
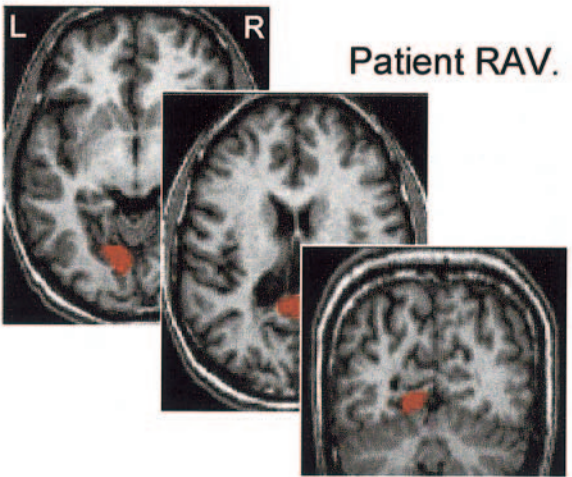
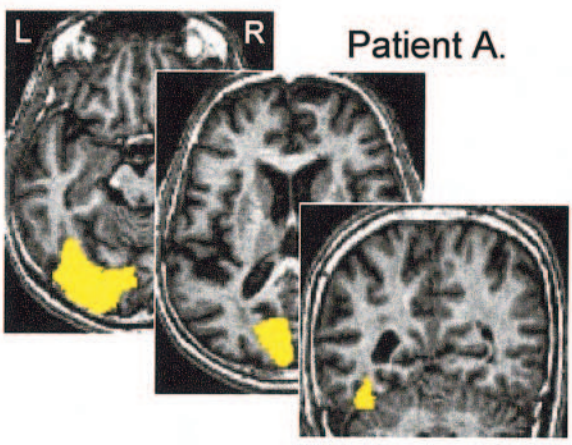
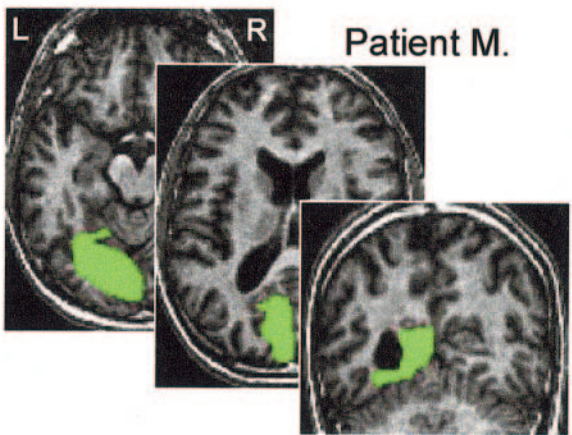
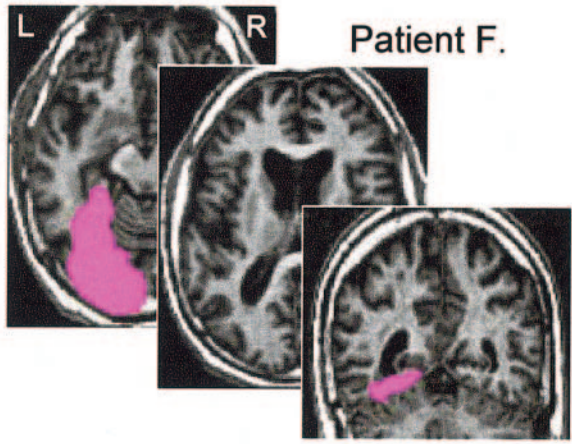
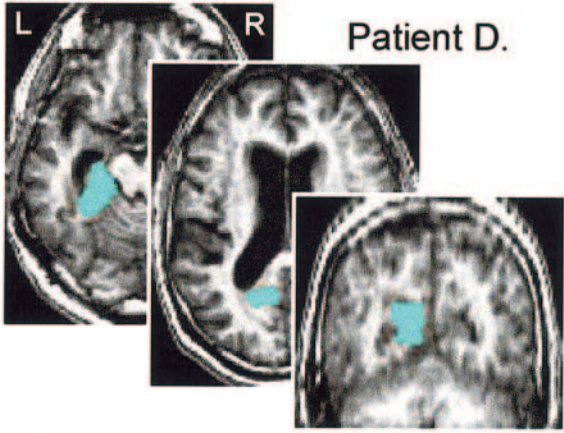
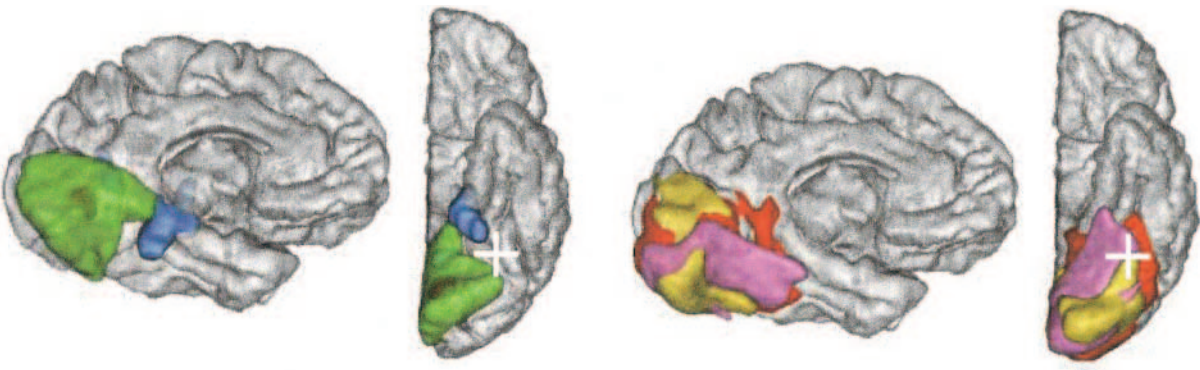
The anatomical MRI showed three small lesions in the territory of the left PCA (Fig. 4), affecting the anterior mesial temporal lobe, the thalamus and the white matter of the forceps major, just contiguous to the splenium of the corpus callosum (approximately centred on TC -18 -33 -17; TC -12 -25 0; and TC -8 -59 16, respectively). The peak of the VWFA in normal subjects fell in a region of intact cerebral tissue, posterior and lateral to the temporal lesion (Fig. 4).

Behaviour

Goldmann perimetry showed a right superior homonymous peripheral scotoma completely sparing central vision. Oral language production and comprehension, picture naming, story reading, writing to dictation, identification of spelled-out words, and graphemic processing were normal (Table 1). The patient named flawlessly and rapidly centrally presented words and single letters. On average, word reading latencies increased by a marginal 7 ms per additional letter [$r(159) = 0.15$; $P = 0.052$], thus showing a normal pattern.

As his visual field was largely intact, the patient and 15 control subjects were submitted to a split-field word reading task. Stimuli consisted of 40 lower-case familiar words, 3–6 letters and 1–2 syllables in length. They were presented once in the LVF and once in the RVF, extending from 2° to a maximum of 6° away from fixation. Subjects were asked to fixate a permanent central fixation point, while stimuli were flashed during 200 ms. The patient named flawlessly and rapidly RVF words (0/40 errors; mean latency = 623 ms). With LVF words, he made significantly more errors [16/40 errors; Yates corrected $\chi^2(1) = 17.6$; $P < 0.001$] and responded more slowly [mean correct latency = 723 ms; $t(57) = 2.8$; $P = 0.007$]. The patient's asymmetry in error rates far exceeded the average 6.3% RVF reading advantage observed in controls [Fig. 5; $t(14) = 4.16$; $P < 0.001$].

In sum, the patient considered his reading skills as unimpaired and the experimental assessment of central reading perform-



ance was normal. Nevertheless, split-field reading revealed a reduced performance with words displayed in the LVF.

fMRI Study of Central Word Reading

The patient participated in the fMRI reading protocol described in the General Methods section. We first identified a bilateral fronto-parieto-temporo-occipital network activated by alphabetic stimuli relative to fixation. It included large bilateral occipitotemporal activations, with bilateral main peaks in the ventral occipital lobes (left: TC -18 -93 -12; right: TC 21 -84 -12), extending anteriorly to about $y = -40$, and encompassing the normal location of the VWFA and of the R-VWFA.

In order to isolate the VWFA, we contrasted alphabetic stimuli versus chequerboards (voxelwise $P < 10^{-4}$; cluster-level $P < 0.05$ corrected). This revealed left parietal, temporal and rolandic activations, including a left fusiform peak [TC -39 -51 -18; $t(197) = 5.39$; $P < 10^{-6}$] at coordinates matching the normal position of the VWFA (Fig. 6). At the peak voxel, the activation was stronger for consonant strings than for real words [$t(197) = 2.25$; $P < 0.05$]. Note that like in normal subjects, the contrast of words versus consonant strings yielded strong activations in the left angular gyrus [TC -39 -69 33; $t(197) = 6.65$] and in the left posterior cingulate [TC -6 -54 36; $t(197) = 5.19$].

The contrast of alphabetic stimuli versus chequerboards revealed no significant activation in the right temporal region. However, as mentioned before, the comparison of alphabetic stimuli versus fixation showed large bilateral ventral occipitotemporal activations. In the right hemisphere these activations comprised three peaks roughly symmetrical to the VWFA (Fig. 6) [TC 42 -54 -12; $t(197) = 5.37$; TC 33 -66 -18; $t(197) = 8.08$; 48 -45 -15; $t(197) = 5.20$; all $P < 10^{-6}$]. In contrast with the VWFA, the three peaks were activated by chequerboards to similar levels as by alphabetic stimuli, relative to fixation [$t(197) = 4.95$; 7.19; and 4.34 respectively; all $P < 10^{-4}$], with no significant difference between alphabetic stimuli and chequerboards (all $P > 0.05$).

In summary, as expected on the basis of lesion topography, central reading elicited a normal pattern of activation. The VWFA was preserved and responsive to alphabetic stimuli more than to chequerboards. Conversely, the symmetrical R-VWFA was equally activated by both types of stimuli. However, this experiment did not allow us to study the differences between activations induced by LVF and RVF stimuli, or to study the mechanism of the patient's left hemialexia.

fMRI Study of Lateralized Word Reading

Patient D was submitted to an event-related lateralized reading protocol fully described in Cohen *et al.* (2002). In summary, he was presented with randomly mixed words, consonant strings and chequerboards displayed in the LVF or in the RVF. In order to assess the comparability with the central reading experiment, we first run global analyses ignoring the hemifield parameter. We then study separately the activations induced by RVF and LVF stimuli. Finally, we assess the significance of the observed asymmetries.

The global contrast of alphabetic stimuli versus chequerboards showed the VWFA peaking at coordinates virtually identical to the central reading experiment [TC -39 -48 -18; $t(290) = 3.81$; voxelwise $P < 0.001$; cluster-level $P < 0.05$ corrected within a 12 mm sphere centred on the VWFA as identified in the central reading experiment]. The activation did not differ significantly between real words and consonant strings [$t(290) = 0.29$]. In agreement with the central reading experiment, this contrast showed no right temporal activations. These results were thus closely similar to those of the central reading experiment. We then turned to separate analyses of the activations induced by RVF and LVF stimuli, expecting to observe an abnormal pattern in the latter case, underlying the behavioural asymmetry.

For RVF stimuli, the VWFA was activated by alphabetic stimuli versus chequerboards, and separately for words versus chequerboards (voxelwise $P < 0.001$; cluster-level $P < 0.05$ corrected within a 12 mm sphere centred on the VWFA as identified in the central reading experiment). Activation by consonant strings was not significant ($P < 0.05$ at the peak voxel). The tendency for a stronger activation by words than by consonants did not reach significance [$t(290) = 1.47$ at the peak voxel]. This pattern could be considered as normal, with a clear advantage of alphabetic stimuli over chequerboards, and a weaker advantage of real words over consonants. Note that in normal subjects, the lexicality effect emerged in group analyses, and was generally not significant in individual subjects (Cohen *et al.*, 2002).

LVF alphabetic stimuli, LVF words and LVF consonants did not significantly activate the VWFA relative to chequerboards at the usual threshold. At a lower voxelwise threshold, the peak voxel was activated by consonant strings [$t(290) = 2.35$], but not by words [$t(290) = 1.30$]. This pattern was clearly abnormal, as it showed no activation of the VWFA by words relative to chequerboards.

Before concluding that the difference in the activations induced in the VWFA by RVF versus LVF words was indeed abnormal, the patient was compared with a group of nine normal subjects, with subjects considered as a random factor (Cohen *et al.*, 2002). At its peak (TC -39 -48 -18), patient D's VWFA was more strongly activated by RVF words than by LVF words [$t(290) = 2.67$; $P < 0.01$]. The random effect analysis showed that this difference was significantly larger in the patient than in normals [$t(8) = 2.89$; $P = 0.02$] (Fig. 5). In this analysis, the VWFA appeared as a cluster peaking at TC -45 -51 -15 [$t(8) = 7.22$; voxelwise $P < 0.01$; cluster-level $P = 0.002$ corrected within a 12 mm sphere centred on the patient's VWFA]. Thus, it may be safely concluded that the weak activation of the VWFA induced by LVF words as compared with RVF words was significantly abnormal in the patient.

Summary and Discussion

The case of patient D lends itself to a straightforward account within the framework that was proposed before. First, reading performance in ecological conditions was normal, i.e. rapid and with no significant effect of word length, attesting to the integrity of the core reading pathway, leading from left V1 to the

Figure 4. Reconstruction of the lesions of six patients in Talairach space, compared with the average normal location of the VWFA (white cross). Left column: the lesions of patients without pure alexia did not affect the critical VWFA region. Right column: the lesions of patients who showed letter-by-letter reading (patients A and F) or global alexia (patient VOL), encroached on the VWFA, in the lateral occipito-temporal sulcus. The additional callosal lesion may be responsible for the left hemialexia in patient D, and for the lack of letter-by-letter reading abilities in patient VOL. Slices are at TC $z = -14$, $z = 17$, and $y = -60$ (for patient RAV $z = -6$, $z = 17$, $y = -66$).

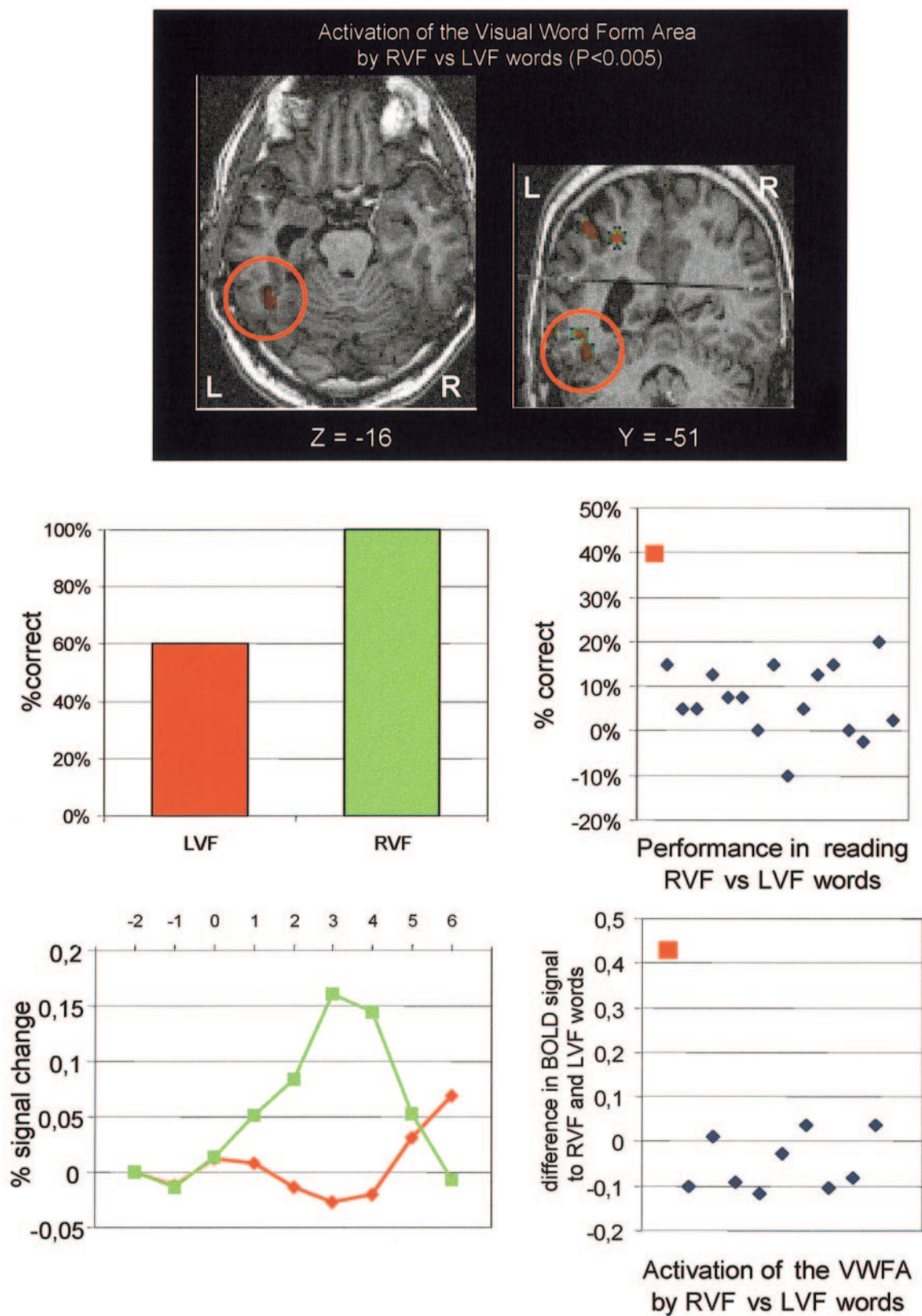


Figure 5. Lateralized word reading in patient D. Top row: the VWFA was activated more strongly by RVF words than by LVF words ($P < 0.005$). Middle left: per cent correct responses in the lateralized reading task, showing flawless performance for RVF words (green), and a high error rate for LVF words (red). Middle right: the RVF advantage in lateralized reading was larger for the patient (red square) than in 15 controls (blue diamonds). Bottom left: plot of the percent change in BOLD signal for RVF words (green curve) and LVF words (red curve) (TC -39 -48 -18). Bottom right: the difference between the percent signal change observed to words presented in the RVF and in the LVF was larger in patient D (red square) than in nine controls (blue diamonds) (TC -45 -51 -15). The patient thus showed an abnormal asymmetry in both his behavioural and his activation pattern.

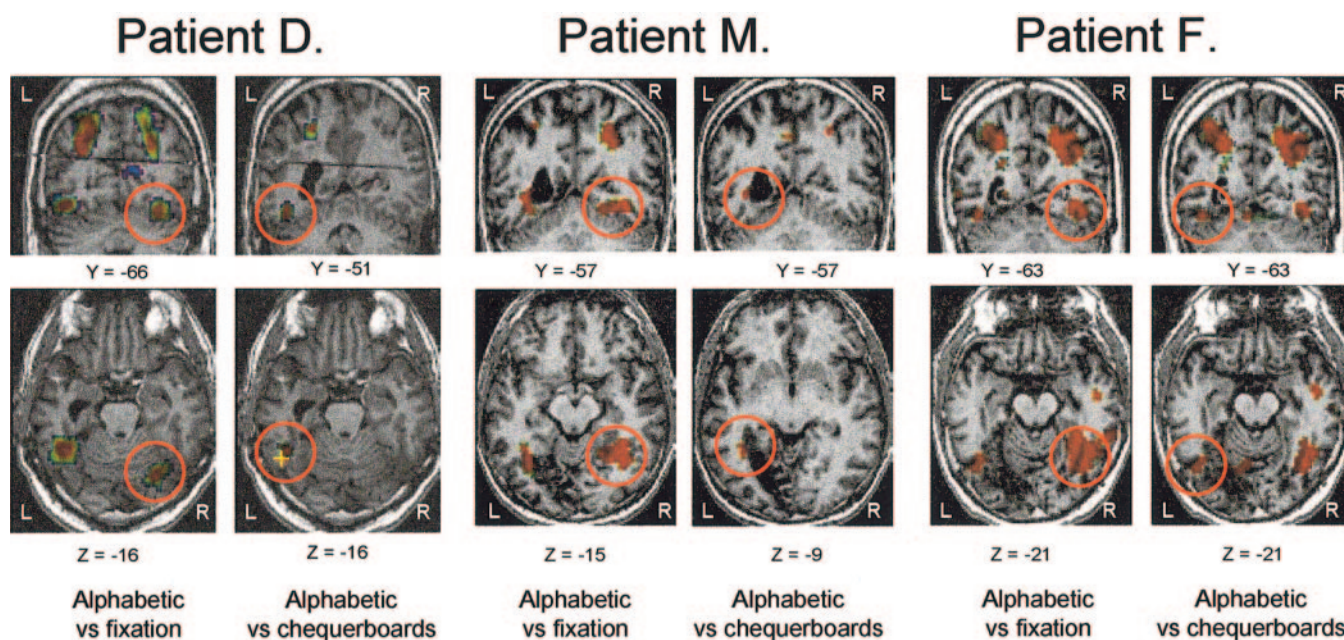


Figure 6. Ventral occipito-temporal activations in patients. The left column shows the contrast of alphabetic stimuli versus fixation, and the right column shows the contrast of alphabetic stimuli versus chequerboards ($P < 0.001$). In the two patients without pure alexia (D and M) the VWFA was activated by letter strings relative to chequerboards while both types of stimuli yielded an equivalent activation of the symmetrical R-VWFA. In the letter-by-letter reader (patient F) the VWFA was partially disrupted, while the R-VWFA discriminated alphabetic stimuli versus chequerboards, thus assuming functional properties generally specific to the VWFA.

VWFA and thence to subsequent language areas. Accordingly, the temporal lesion was anterior and mesial to the VWFA, which was activated during reading. Secondly, patient D's partial impairment in reading LVF words can be attributed to a partial interhemispheric disconnection due to a left-sided lesion of the splenium of the corpus callosum. We have shown previously using diffusion tensor imaging, albeit in a patient with much larger lesions, that the fibre tract critically affected by such lesions connects right and left ventral occipitotemporal regions, including probably connections from the right V4 area to the VWFA (Molko *et al.*, 2002). Accordingly, patient D showed an abnormally weak activation of the VWFA by LVF versus RVF words. According to our hypotheses, we may assume that the activations induced by both alphabetic stimuli and chequerboards in the R-VWFA did not play a crucial role in the patient's reading abilities.

Right Hemianopic Alexia: Patient M

Medical History and Lesion Description

Patient M was a 54-year-old right-handed male building engineer. Eight months before the present study, he suffered from an infarct in the territory of the left PCA, revealed by sudden right homonymous hemianopia.

The anatomical MRI showed a left ventral and mesial occipito-temporal lesion, destroying both banks of the calcarine sulcus and the lingual gyrus, and extending to the mesial part of the fusiform gyrus. The peak of the normal VWFA fell in a region of intact cerebral tissue, lateral to the ischaemic lesion and to the enlarged lateral ventricle (Fig. 4).

Behaviour

Goldmann perimetry showed a complete right homonymous hemianopia with no sparing of the macula. Oral language

production and comprehension, picture naming, writing to dictation, identification of spelled-out words and graphemic processing were normal (Table 1). Story reading was flawless but slower than in normals [52 s in the patient versus a mean of 35 s in normals; $t(8) = 3.5$; $P < 0.01$]. The patient named flawlessly centrally presented words and single letters. However, word reading latencies increased by 64 ms per letter [$r(162) = 0.57$; $P < 0.001$], a slope significantly steeper than in normal subjects [$t(8) = 12$; $P < 0.001$].

As the patient had a complete right hemianopia, we compared this pattern to the performance of the 15 control subjects reading words displayed in one hemifield, as reported in the study of patient D. We computed the slope of the patient's word length effect restricted to words of 3–6 letters, in order to insure comparability with the controls. The patient's slope (53 ms per letter) did not differ from the slope observed in controls for LVF words [mean = 22 ms per letter; $t(14) = 1.6$; $P > 0.1$], while it was significantly steeper than the normal slope for RVF words [mean = 9 ms per letter; $t(14) = 3.4$; $P = 0.005$].

In sum, the word length effect exhibited by patient M when reading stimuli in free-field could be considered as a consequence of his hemianopia, with an otherwise essentially intact reading system.

fMRI Study of Word Reading

The patient participated in the fMRI reading protocol described in the General Methods section. We first identified a bilateral fronto-parieto-temporo-occipital network activated by alphabetic stimuli relative to fixation. It included bilateral occipito-temporal activations, with bilateral main peaks in the ventral occipital lobes (left: TC -24 -81 0; right: TC 33 -75 -6), and at the normal coordinates of the VWFA (TC -39 -57 -9). There was a strong and precisely symmetrical right-sided activation corresponding to the R-VWFA [TC 39 -57 -15; $t(197) = 6.24$].

In order to isolate the VWFA, we contrasted alphabetic stimuli versus chequerboards. This revealed left parietal, temporal and Rolandic activations, including a VWFA cluster too small to reach cluster-level significance with a whole-brain correction [TC -39 -54 -9; $t(197) = 3.83$; 10 voxels] (Fig. 6). Importantly, the VWFA was not activated by chequerboards relative to fixation [$t(197) = 1.59$; NS]. The activation did not differ significantly between consonant strings and real words [$t(197) = 0.86$; NS].

The contrast of alphabetic stimuli versus chequerboards revealed no significant cluster in the right temporal region. However, as mentioned before, the comparison of alphabetic stimuli versus fixation showed bilateral ventral occipitotemporal activations. In contrast with the VWFA, the R-VWFA was also activated by chequerboards relative to fixation [TC 30 -54 -18; $t(197) = 5.46$]. Like in the VWFA proper, the activation did not differ between consonant strings and real words.

Summary and Discussion

Despite a large cortical lesion and the resulting hemianopia, patient M had no subjective reading difficulties. Nevertheless, the study of his reading latencies suggests that those were abnormally dependent on word length, and hence that the mechanisms that normally compute the identities of letter arrays in parallel were disrupted by the cortical lesion. As suggested in the introduction, those mechanisms may be specific to the left-hemispheric visual system, explaining why in normals only RVF words are read with no appreciable effect of word length, while there is such an effect with LVF words (Lavidor and Ellis, 2002). Leaving aside this subtle deviation from optimal performance, it is tempting to relate the sparing of patient M's reading abilities to the spared activation of the VWFA by words entering through the intact LVF. Like in normals and in patient D, we assume that the activations induced by both alphabetic stimuli and chequerboards in the R-VWFA did not play a crucial role in patient M's reading abilities. In short, we suggest that this patient read roughly like normal subjects read words displayed in their LVF.

Letter-by-letter Reading via the Right Hemisphere: Patient F

Medical History and Lesion Description

Patient F was a 68-year-old right-handed retired male manager. He suffered from an infarct in the territory of the left PCA, revealed by sudden right homonymous hemianopia and reading difficulties. Eight months after the infarct, word reading was still slow and effortful. When reading a list of 133 words 3–9 letters long, the patient made 22 errors (16%). Reading latencies on correct trials, as measured with a manual chronometer, had a mean of 9200 ms, and showed a major effect of word length, with a slope of 1140 ms per letter. The patient received rehabilitation by a speech therapist and reading partially improved over the following months. The present study was carried out 20 months after the stroke.

The anatomical MRI showed a left ventral occipito-temporal lesion. It affected the inferior occipital cortex and the lingual gyrus, with no extension dorsal to the calcarine sulcus. It extended anteriorly to the fusiform and parahippocampal gyri. There was an additional small right inferior occipital lesion, probably resulting from a previous overlooked CVA. The region of normal VWFA activation overlapped substantially with the left fusiform lesion (Fig. 4).

Behavioural Assessment

Goldmann perimeter showed right superior homonymous quadrantanopia without foveal sparing, plus an additional right inferior scotoma in the left eye. Oral language production and comprehension, picture naming, writing to dictation, identification of spelled-out words and graphemic processing were essentially normal (Table 1).

Story reading, although correct, was still slow (>4 min). The patient made few errors (7/165 errors), but responded slowly (mean latency = 2547 ms) when reading single words. Furthermore, there was a major effect of word length on latencies, with a slope of 311 ms per letter [$r(137) = 0.42$; $P < 0.001$]. This slope was much steeper than in normal subjects, but also than in patient M. In summary, patient F qualified as a typical pure alexic with an efficient letter-by-letter reading strategy.

fMRI Study of Word Reading

The patient participated in the fMRI reading protocol described in the General Methods section. We first identified a bilateral fronto-parieto-temporo-occipital network activated by alphabetic stimuli relative to fixation. It included strong right ventral occipitotemporal activations at the coordinates of the R-VWFA [TC 39 -60 -18; $t(197) = 11.7$]. In the left hemisphere, there was a smaller cluster peaking at TC -45 -69 -21 and extending anteriorly to a group of voxels surrounded by the lesion, at about the normal coordinates of the VWFA [TC -42 -63 -24; $t(197) = 5.17$].

The contrast of alphabetic stimuli versus chequerboards elicited a similar pattern. In particular a posterior left-hemispheric cluster [main peak: TC -24 -72 12; $t(197) = 12.9$] encompassed the residual VWFA region identified with the previous contrast [at TC -42 -63 -24, $t(197) = 4.65$]. At the peak voxel, this region was not activated by chequerboards relative to fixation [$t(197) = 0.49$]. Finally, the activation was marginally stronger for real words than for consonant strings [$t(197) = 1.74$; $P < 0.1$]. Thus, it was possible to pick out a small residual region, contiguous to the lesion, with coordinates and functional properties analogous to those of the VWFA.

Using the contrast of alphabetic stimuli versus chequerboards, the R-VWFA appeared as a high peak [TC 39 -63 -18; $t(197) = 8.47$] within a posterior cluster [main peak: TC 21 -69 42; $t(197) = 12.5$]. It was also activated by chequerboards relative to fixation, although weakly [$t(197) = 2.34$]. Moreover, the activation was stronger for real words than for consonants [$t(197) = 2.39$]. Thus in patient F, the major part of the normal VWFA was disrupted, while the right-hemispheric symmetrical region showed the general functional properties usually attached to the VWFA.

Finally, we checked that this pattern of R-VWFA activation deviated significantly from the normal pattern. In an analysis with subjects as random factor, the activation at the peak voxel (TC 39 -63 -18) by alphabetic strings and by words relative to chequerboards was stronger in patient F than in the group of normal controls [$t(8) = 2.87$, $P < 0.05$; and $t(8) = 4.31$, $P < 0.005$, respectively]. We also searched for excessive activations in patient F, which may reflect the effortful word identification based on serial letter identification. Indeed, a large part of the language-related network was activated more strongly by words versus consonant strings in patient F as compared with normal subjects (voxelwise $P < 0.001$, cluster-level $P < 0.05$ corrected): left anterior insula/Broca's area (TC -36 15 3) and supramarginal gyrus (TC -42 -51 33), but also left-predominant prefrontal

cortex, bilateral rolandic cortex, posterior middle temporal gyrus and occipital cortex (TC -27 -69 3 and TC 27 -72 12).

Summary and Discussion

Contrary to the previous patients, patient F was substantially impaired in his daily command of reading, in the absence of other relevant language deficit, including writing. In the proposed framework, this pattern is suggestive of an impaired visual word form. As suggested before, letter-by-letter reading may result from a kind of serial spelling of stimuli by the right hemisphere to the left-hemispheric language system. Anatomical and functional data are compatible with this hypothesis (Figs 4 and 6): first, patient F's lesion overlapped with the normal region of the VWFA, explaining the reading deficit. Secondly, callosal connections appeared to be intact, allowing for interhemispheric transfer of letter identities. Thirdly, the right-hemispheric R-VWFA activations showed a strong preference for alphabetic stimuli over chequerboards, a pattern normally specific to the VWFA, in normals as well as in patients D and M. This suggests that indeed the right-sided visual system assumed a function in reading normally devoted to the VWFA. Still, some residual activations were observed around the VWFA, suggesting that this structure was partially spared. However, it is unclear what role, if any, the residual activation of the VWFA played in the patient's behaviour, considering that they were closely surrounded by lesioned cerebral tissue, and possibly deprived of some of their connections. Finally, letter-by-letter word reading induced a stronger than normal activation of language related areas, particularly in a network repeatedly associated with verbal working memory, including Broca's area (BA 44), dorsolateral prefrontal cortex (BA 9), and left supramarginal gyrus (BA 40) (for a review see Cabeza and Nyberg, 2000).

Additional Cases and Study of Lesion Overlap

Before studying anatomical-behavioural correlations across patients, we will enrich our database with three additional cases, including two previously published ones. Those patients' behaviour and imaging data will be shortly described.

Letter-by-letter Reading: Patient A

Patient A was a 63-year-old right-handed man, who suffered from a left PCA infarct responsible for right hemianopia, without macular sparing, and reading difficulties. Oral language production and comprehension, picture naming, writing to dictation, identification of spelled-out words and graphemic processing were normal. The patient read centrally displayed words flawlessly but slowly (mean latency = 2463 ms), with a marked length effect of 397 ms per letter ($P < 0.001$). He was also accurate but slow when reading single letters (mean latency = 894 ms). In brief, patient A showed pure alexia with effective letter-by-letter reading, and was thus closely similar to patient F.

The anatomical MRI showed a left ventral occipito-temporal lesion. It affected the inferior cortex of the occipital lobe and extended to most of its mesial aspect, including both banks of the calcarine sulcus. It extended anteriorly precisely within the occipito-temporal sulcus to about TC $y = -60$. There was no visible callosal lesion. There was also a small left thalamic lesion. The region of normal VWFA activation overlapped substantially with the left fusiform lesion (Fig. 4).

Complete Left Hemialexia: Patient RAV

Patient RAV was a 30-year-old right-handed woman who suffered from a left PCA infarct yielding an isolated interhemispheric disconnection syndrome in the visual, haptic, and auditory modalities (Cohen and Dehaene, 1996, 1998, 2000). There was a right superior homonymous scotoma sparing central vision. Oral language production and comprehension, and writing to dictation, were entirely normal. The patient did not report subjective reading difficulties. However she was almost unable to read a single word displayed tachistoscopically in her LVF, while she performed normally with RVF words. With fMRI, patient RAV's VWFA was normally activated by RVF words relative to fixation, while LVF words induced no significant activation. She thus displayed a left hemialexia qualitatively similar to patient D, albeit more severe (Cohen and Dehaene, 2000).

Her lesion affected the left half of the posterior half of the corpus callosum, extending from TC $y = 0$ anteriorly to the posterior end of the splenium at TC $y = -50$. There was a small additional lesion in the left occipital cortex, ventral to the anterior part of the calcarine sulcus.

Global Alexia: Patient VOL

Patient VOL was a 66-year-old right-handed woman who suffered from a left PCA infarct responsible for right hemianopia with macular sparing, severe alexia and some degree of associative agnosia for objects (Cohen and Dehaene, 2000). She made as much as 31% errors when trying to name isolated upper-case letters. She often reached the correct response by outlining the target letter with her finger. She was almost completely unable to read any word aloud. She tried to resort to an effortful and distressing letter-by-letter reading strategy, but made many letter naming errors, and testing had to be discontinued after the first few items. In contrast, she did not make a single error in naming the same words when they were spelled out orally to her. She could write letters, words and sentences normally, either spontaneously or to dictation.

VOL's residual word processing abilities were assessed using lexical decision, language decision and semantic classification tasks. In summary, the results suggested above chance performance in several lexical decision and language decision tasks, but no evidence for access to word meaning was found (Cohen and Dehaene, 2000). There was also ample evidence that she could accurately access the quantitative meaning of Arabic numerals, even when she was unable to read those numbers aloud.

A T2-weighted anatomical MRI showed an extensive ventral occipitotemporal lesion, also affecting the mesial occipital lobe both below and above the calcarine sulcus (Fig. 4). The infarct encompassed the left part of the splenium of the corpus callosum. After normalization in Talairach space, the anterior boundary of the temporal lesion reached about $y = -20$. In summary, patient VOL had global alexia; her lesion included the VWFA and beyond, and affected interhemispheric connections.

Study of Lesion Overlap

The normalized lesions from the six patients were smoothed (5 mm Gaussian filter) and then added, with a positive weight for the three patients with pure alexia (F, A and VOL) and an equal negative weight for the three patients without pure alexia (D, M and RAV). The resulting image (Fig. 7, top) is proportional to the log likelihood ratio, $\log[P(\text{pure alexia}|\text{lesion})/P(\text{no pure alexia}|\text{lesion})]$, which expresses for each voxel the conditional link between the existence of a lesion and the occurrence

of pure alexia. The critical area follows closely the left occipito-temporal sulcus and overlaps with the VWFA, as identified with fMRI in normal subjects by contrasting alphabetic stimuli versus checkerboards (Fig. 7, bottom).

General Discussion

According to a simple anatomical and functional model of word reading, letters displayed in one hemifield are first analysed through a cascade of contralateral retinotopic areas, which compute increasingly abstract representations. Eventually, an invariant representation of letter identities is created in the VWFA, reproducibly located within the left occipito-temporal sulcus. The VWFA then projects to structures involved in phonological or lexico-semantic processing. This model yields detailed predictions on the reading impairments that may follow left occipitotemporal lesions. Those predictions were confronted to behavioural, anatomical and fMRI data gathered from normals and from patients suffering from left posterior cerebral artery infarcts.

Critical Lesions and the VWFA

Our first aim was to assess the hypothesis that a necessary and sufficient condition for the apparition of pure alexia is that the

VWFA should be destroyed or non-functional. This hypothesis is directly supported by the spatial congruence of the critical lesion site, as identified by combining the normalized lesions from six patients with the activation of the VWFA in normal subjects (Fig. 7). However, the normalized coordinates of brain lesions may not always be sufficient to predict accurately whether pure alexia should be expected in a given patient. There is some variability in the coordinates of the VWFA even in normal subjects, and the geometric normalization process is not flawless, particularly when processing lesioned brains (Brett *et al.*, 2001). In addition to the Talairach coordinates of the lesion, an injury to the cortex buried in the occipito-temporal sulcus may be a useful predictor of pure alexia. Indeed, in spite of the variability in sulcal anatomy, the normal VWFA activation is reproducibly located in the depths of the sulcus across subjects (Cohen *et al.*, 2000, 2002). For instance, this criterion can be used to contrast the cases of patient M, who had hemianopia without pure alexia, and patients F and A, who had pure alexia with letter-by-letter reading. As visible on the coronal images in Figure 4, which cut through the normal position of the VWFA, the lesions of patients F and A affected the cortex within the occipito-temporal sulcus, while in patient M it was confined to the mesial part of the fusiform gyrus.

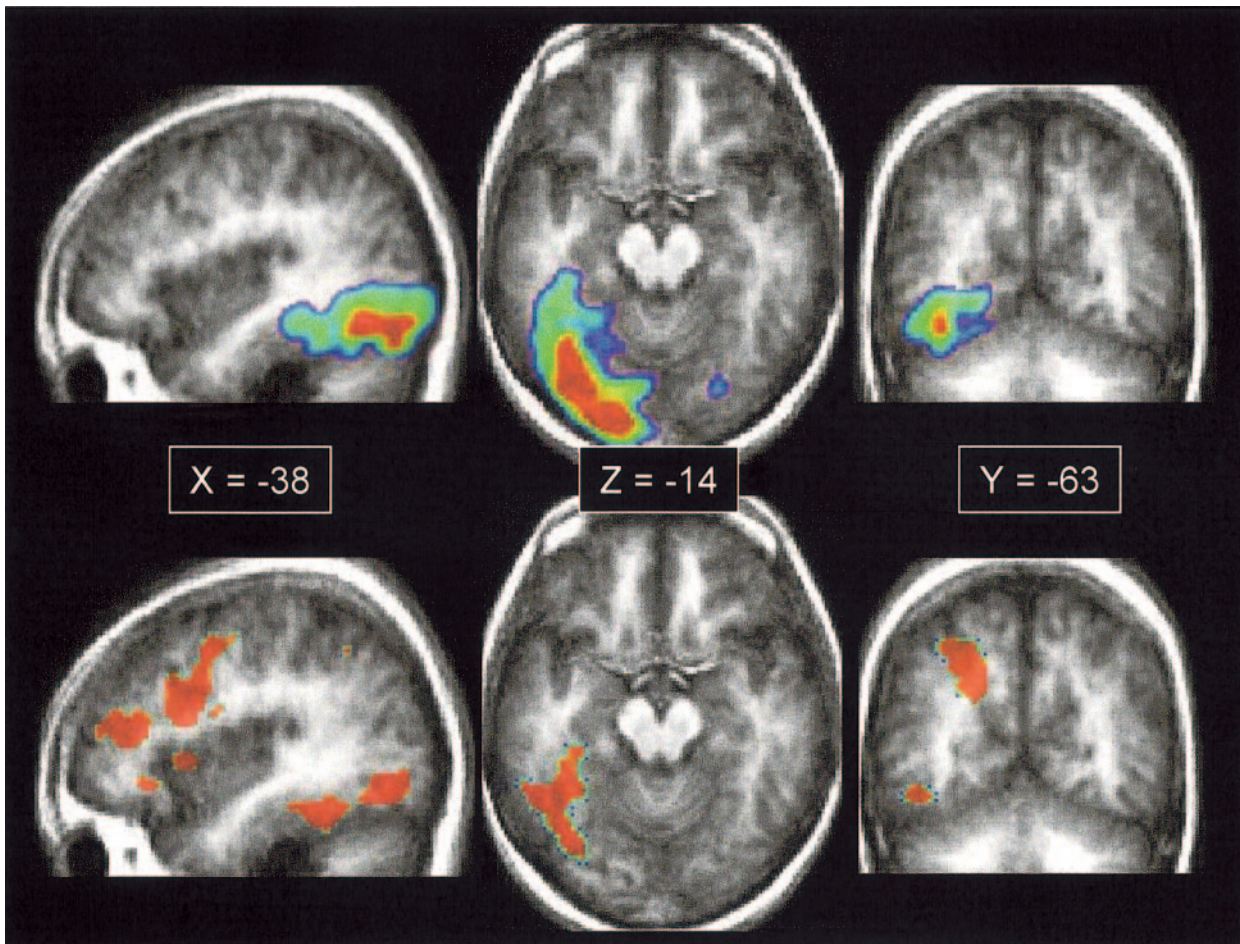


Figure 7. Correlation between the lesion site associated with pure alexia (top) and the left occipito-temporal activation during normal reading (bottom). The normalized lesions from six patients were combined, to compute for each voxel an index proportional to the log likelihood ratio, expressing the conditional link between the existence of a lesion and the occurrence of pure alexia. The critical area follows the left occipito-temporal sulcus, and overlaps neatly with the VWFA, as identified with fMRI in normal subjects by contrasting alphabetic stimuli versus checkerboards.

The pattern of activation is also compatible with our hypothesis: the VWFA was activated in patient M, and partially preserved in patient F. The comparison of F and A may suggest a further source of variability between patients. In patient A, the lesion destroyed entirely the VWFA cortex, while in patient F, a small region of cortex was apparently spared, and could be activated. However, this patch was bordered on its mesial, anterior and posterior flanks by lesioned tissue, and probably did not fulfil the normal functions of the VWFA, despite some degree of activation.

Our approach is similar to that put forward by Leff *et al.* (2001). During PET scanning, they proposed a word reading task to normal subjects, hemianopic patients with or without macular sparing, and to a pure alexic patient with letter-by-letter reading. The study was focused on a ventral occipito-temporal region, isolated by virtue of its approximately linear increase of activation with the rate of stimulus presentation. This functional criterion was thus correlated with simple physical parameters such as the amount of visual stimulation, but had no specificity for alphabetic stimuli. Indeed, the peak coordinates were TC -42 -72 -16, which is somewhat posterior to the VWFA, and closer to occipital regions sensitive to presentation rate (Price *et al.*, 1996a; Price and Friston, 1997) and other physical parameters (Mechelli *et al.*, 2000). Actually, the coordinates reported by Leff *et al.* (2001) are close to the main peak of the cluster isolated in the present study by contrasting alphabetic stimuli versus chequerboards in normals (TC -36 -75 -12). However, at this position, which is posterior to the VWFA, previous studies have shown that alphabetic stimuli have not yet reached a level of representation invariant for position or case (Cohen *et al.*, 2000; Dehaene *et al.*, 2001). Importantly, the lesion of the pure alexic patient AR (reported in Leff *et al.*, 2001) was large, extended more anteriorly than the normal activation focus picked out by Leff *et al.* (2001), and apparently encompassed the VWFA as defined here. Conversely, the mean image computed on the basis of the anatomical MRIs of hemianopic patients suggests that lesions in those patients did not extend anteriorly to TC $y = -70$, and hence spared the VWFA. In summary, we suggest that the activation studied by Leff *et al.* (2001) differs from the VWFA and may not be critical to the genesis of pure alexia, but that their anatomical data are compatible with the account proposed here.

Damasio and Damasio (1983) distinguished three lesion patterns associated with pure alexia. Type I results from extensive PCA infarcts affecting the mesial and ventral occipito-temporal cortex and the underlying white matter, probably including the VWFA. Our patient VOL seems to be representative of this pattern. Type II results from right hemianopia, due to a lesion of the calcarine cortex or of the optic radiations, associated with an interhemispheric disconnection. According to our framework, this would yield a complete deafferentation of the VWFA. Type III seems to result from ventral occipito-temporal cortex lesions smaller than in type I, with partial or complete sparing of the visual field. Although matching Damasio and Damasio's templates with our normalized data can only be approximate, the critical lesion in type III patients overlaps nicely with the VWFA as defined here. Binder and Mohr (1992) went a step further in delineating the critical region, by comparing the lesions of alexic patients with the lesions of patients with a left PCA infarct but with no reading impairment. The critical ventral occipito-temporal cortex region appears to be slightly more anterior and mesial than the VWFA. However,

methodological differences in the reconstruction of lesions may be sufficient to account for this discrepancy.

Beside the ventral occipito-temporal cortex, the corpus callosum is the main structure invoked in most accounts of pure alexia. In normal subjects, we postulate that its only role in reading is to convey visual information about letters displayed in the LVF from the right visual cortex to the VWFA. As a consequence, an isolated callosal lesion only induces pure alexia restricted to the LVF (Cohen and Dehaene, 2000; Molko *et al.*, 2002). The case of patient D illustrates this pattern of deficit: as a result of a small lesion of the left forceps major, patient D's VWFA was not normally activated by LVF words. Patient D's lesion was similar to that reported by Suzuki *et al.* (1998) in a patient with left hemialexia but without anomia for LVF pictures. A review of published cases of callosal alexia suggests that the ventroposterior part of the splenium is responsible for the transfer of visual information about alphabetic stimuli (Suzuki *et al.*, 1998). In order to induce clinically detectable pure alexia, a callosal lesion must be associated with right hemianopia, corresponding to a type II lesion, following the typology of Damasio and Damasio (1983). In non-alexia hemianopic patients, such as patient M, the callosal route is indeed vital to reading, as it provides the only input to the VWFA and subsequent stages of reading, and an additional callosal lesion would be sufficient to yield pure alexia.

However, if we consider only patients who do have pure alexia, the role of the corpus callosum may go beyond this normal contribution to reading. If we assume that residual reading abilities, including letter-by-letter reading and implicit lexical access (Coslett and Saffran, 1998; Friedman and Nitzberg Lott, 2000), result from right-hemispheric word processing, the intervention of the corpus callosum is required whenever the output of those right-hemispheric computations must be made available to the left-hemispheric verbal system. This issue will be addressed in the next sections.

In summary, our main finding is that the VWFA, as defined by its functional properties in normal subjects, is indeed the critical lesion locus for pure alexia, an observation which agrees with previous anatomical studies.

Letter-by-letter Reading

Letter-by-letter reading implies that the normal ability to identify letter strings in a quasi-parallel fashion is lost. This impairment is tantamount to pure alexia, and we proposed that it results from the destruction of the VWFA, from its deprivation of input from both hemifields, or possibly from disrupted projections from the VWFA to subsequent language areas. Why, then, do some pure alexic patients enjoy effective letter-by-letter reading abilities, while others suffer from global alexia? What are the brain mechanisms that underlie letter-by-letter reading? Clarification on these questions should be gained by reducing the emergence of letter-by-letter reading to two basic conditions, which will be discussed in turn.

A first condition to letter-by-letter reading is the existence of residual abilities to identify individual letters, even if with some inaccuracy and slowness. There is converging evidence that alphabetic identification is within the reach of the right-hemispheric visual system, even if this process is not needed for normal reading (for a review see Coslett and Saffran, 1998). Such evidence comes from studies of split brains (Baynes and Eliassen, 1998), left-hemispherectomized patients (Patterson *et al.*, 1989), deep dyslexic patients with extensive LH lesions

(Coltheart, 1980) and patients with pure alexia. We mentioned the case of a pure alexic patient who lost her letter-by-letter reading abilities following a contralateral RH infarct (Bartolomeo *et al.*, 1998). Similarly, Coslett and Monsul (1994) transiently disrupted the residual reading abilities of a pure alexic patient by means of transcranial magnetic stimulation. There is similar evidence on the identification of Arabic digits by the RH (Cohen and Dehaene, 1995, 1996; Gazzaniga and Hillyard, 1971; Gazzaniga and Smylie, 1984; Seymour *et al.*, 1994). The RH thus appears as a plausible source of alphabetic identification in letter-by-letter reading. Our imaging results support this hypothesis and clarify its anatomical foundations by suggesting an involvement of the R-VWFA. First, the right ventral occipito-temporal cortex is strongly activated by alphabetic stimuli even in normal subjects. Although this activation is not stronger than for chequerboards, it demonstrates that letters are indeed processed in the RH up to high-order visual cortices devoted to object recognition (Gauthier, 2000; Ishai *et al.*, 2000; Malach *et al.*, 2002). This supports the idea that letters can be identified in those structures, even if not with the same degree of invariance as in the VWFA. Secondly, the left ventral occipito-temporal activation by alphabetic stimuli was severely reduced in patient F. This implies that in those patients, letter-by-letter reading was not achieved by the LH ventral visual system, although it cannot be excluded that the residual LH activation in patient F had some contribution in his behaviour. Moreover, in patient F, the right-hemispheric ventral occipito-temporal cortex showed functional properties usually characteristic of the VWFA, i.e. stronger activation by alphabetic stimuli than by chequerboards.

The existence of alphabetic activations in the R-VWFA in alexic patients might depend on premorbid functional dispositions. There is indeed some variability among normal subjects in the functional properties of the R-VWFA. For instance, Cohen *et al.* (2002) found in two out of seven subjects an R-VWFA activation for alphabetic stimuli versus chequerboards, invariant for position in the visual field, although this activation was always weaker than in the VWFA proper. One may speculate that such an RH activation pattern could be a predisposition to the emergence of letter-by-letter reading in case of LH lesion. A related question is whether the improvement of letter-by-letter reading over time, as occurred in patient F, could result from changes in the operation of the R-VWFA. Such adaptations could reflect changes in the intrinsic properties of the R-VWFA following the stroke. Alternatively, patients who read letter-by-letter may merely learn to rely more heavily on their R-VWFA during reading than do normal subjects. These issues could be tackled through longitudinal studies of alexic patients during the course of functional recovery (Behrmann *et al.*, 1990; Small *et al.*, 1998).

A second precondition to letter-by-letter reading is the ability to combine the serially identified letters, in order to access the lexicon and other language-dependent processes. By default, one may assume that the central mechanisms of letter combination are the same as those involved in recognizing orally spelled-out words, and that they are based on verbal and working memory processes. Indeed, patient F showed increased activation during letter-by-letter reading relative to normal controls in areas subtending language and verbal working memory. This additional processing may reflect the stepwise recovery of word identity in letter-by-letter readers. However, for those mechanisms to receive as input the series of letters presumably identified in the right hemisphere, direct or indirect links must exist

between the right ventral occipito-temporal cortex and speech areas. Di Virgilio and Clarke (1997) studied the brain of a patient with a right ventral occipito-temporal cortex lesion extending from TC $y = 5$ to $y = -52$ along the antero-posterior axis, overlapping with the putative R-VWFA. By staining anterogradely degenerating axons, they evidenced monosynaptic projections from the lesioned area to left-hemispheric language areas, including Broca's and Wernicke's areas and the inferior parietal lobule. Such data help to flesh out the interhemispheric pathways that might be involved in letter-by-letter reading. In this context, an interhemispheric disconnection should be sufficient to shift a patient from letter-by-letter reading to global alexia. Accordingly, the global alexic patient VOL had a callosal lesion, while interhemispheric connections were apparently intact in letter-by-letter readers F and A (Fig. 4). Similarly, Binder and Mohr (1992) concluded that the only area which is lesioned in global alexics as compared with letter-by-letter readers includes the left forceps major, and extends into the left hemispheric white matter above the posterior ventricular horn. As an aside, if we assume that the interhemispheric pathways involved in letter-by-letter reading project from the R-VWFA to language areas, they should differ from those normally involved in reading of LVF words, which are thought to project from RH visual cortex to the VWFA (Molko *et al.*, 2002). The callosal lesions that induce left hemialexia (patient D) and those that prevent letter-by-letter reading in alexic patients (patient VOL) appear to be similar. Whether two anatomically distinct transcallosal pathways can actually be identified remains an open question.

Brain Lesions and Brain Imaging: A Revision of the Model

We may now summarize the two main conclusions of this study. First, we propose that, apart from cases of pure disconnection, the critical brain lesion for pure alexia can be tightly localized to the VWFA, as defined in normal subjects on the basis of its anatomical location and functional properties (Fig. 7). Secondly, we show that when the VWFA is destroyed, letter-by-letter readers show activations in the right-hemispheric counterpart of the VWFA, consonant with the idea that letters are identified in this region. This latter point prompts a revision of the model of reading proposed in the introduction, in order to insert an alternative pathway subtending letter-by-letter reading (Fig. 1). This pathway includes the R-VWFA and its putative projections to left-sided language areas.

Even with this improvement, the model fails to explain the residual implicit reading abilities observed in some pure alexic patients such as patient VOL. Implicit reading can be elicited in tasks with no overt verbal component, such as lexical or semantic decision (Coslett *et al.*, 1993). Its emergence requires that explicit reading, particularly through letter-by-letter strategies, be absent or prevented, e.g. through the rapid presentation of masked stimuli. Coslett and Saffran have put forward a number of arguments supporting the hypothesis that implicit reading would reflect a lexical and semantic access within the RH, capable of driving non-verbal responses, and impeded by concurrent attempts of the LH to engage in verbal strategies (Coslett and Saffran, 1998). In some patients, implicit word identification may eventually be made available to overt verbal output, yielding deep dyslexic phenomena, such as fast reading of short highly imageable words (Buxbaum and Coslett, 1996). Endorsing the right-hemispheric hypothesis, such deep dyslexic phenomena also require that semantic information be trans-

ferred to the LH. Sidtis *et al.* (1981) studied a patient who underwent a two-stage callosotomy. When only the posterior half of his corpus callosum was severed, the patient could not read aloud words presented in his LVF. However, he could still verbally approach their meaning, presumably owing to the transfer of semantic information through the intact anterior callosum. This suggests that beside the transhemispheric pathway subtending letter-by-letter reading, a more anterior semantic route, perhaps available only in a few subjects with a strong premorbid contribution of the right-hemisphere to reading, may help some patients to circumvent their pure alexia. Indeed, letter-by-letter reading (Behrmann *et al.*, 1990; Greenwald and Gonzalez Rothi, 1998) and making implicit reading explicit (Friedman and Nitzberg Lott, 2000) are the two main rehabilitation methods that can be applied in pure alexia. By delineating such alternative routes (Price and Friston, 2002), our work may ultimately support rehabilitation strategies tailored to individual alexic patients.

Notes

This work was supported by a 'Cognitique' grant from the French Ministry of Research.

Address correspondence to Laurent Cohen, MD, PhD, Service de Neurologie 1, Hôpital de la Salpêtrière, 47/83 Bd de l'Hôpital, 75651 Paris Cedex 13, France. Email: laurent.cohen@psl.ap-hop-paris.fr.

References

Aghababian V, Nazir TA (2000) Developing normal reading skills: aspects of the visual processes underlying word recognition. *J Exp Child Psychol* 76:123–150.

Bartolomeo P, Bachoud-Levi AC, Degos JD, Boller F (1998) Disruption of residual reading capacity in a pure alexic patient after a mirror-image right-hemispheric lesion. *Neurology* 50:286–288.

Baynes K, Eliassen JC (1998) The visual lexicon: its access and organization in commissurotomy patients. In: *Right hemisphere language comprehension* (Beeman M, Chiarello C, eds), pp. 79–104. Mahwah, NJ: Lawrence Erlbaum Associates.

Behrmann M, Black SE, Bub D (1990) The evolution of pure alexia: a longitudinal study of recovery. *Brain Lang* 39:405–427.

Beversdorf DQ, Ratcliffe NR, Rhodes CH, Reeves AG (1997) Pure alexia: clinical-pathologic evidence for a lateralized visual language association cortex. *Clin Neuropathol* 16:328–331.

Binder JR, Mohr JP (1992) The topography of callosal reading pathways. A case-control analysis. *Brain* 115:1807–1826.

Binder JR, Frost JA, Hammeke TA, Bellgowan PS, Rao SM, Cox RW (1999) Conceptual processing during the conscious resting state. A functional MRI study. *J Cogn Neurosci* 11:80–95.

Bokde AL, Tagamets MA, Friedman RB, Horwitz B (2001) Functional interactions of the inferior frontal cortex during the processing of words and word-like stimuli. *Neuron* 30:609–617.

Booth MC, Rolls ET (1998) View-invariant representations of familiar objects by neurons in the inferior temporal visual cortex. *Cereb Cortex* 8:510–523.

Brett M, Leff AP, Rorden C, Ashburner J (2001) Spatial normalization of brain images with focal lesions using cost function masking. *Neuroimage* 14:486–500.

Büchel C, Price C, Friston K (1998) A multimodal language region in the ventral visual pathway. *Nature* 394:274–277.

Burgund ED, Marsolek CJ (1997) Letter-case-specific priming in the right cerebral hemisphere with a form-specific perceptual identification task. *Brain Cogn* 35:239–258.

Burgund ED, Marsolek CJ (2000) Viewpoint-invariant and viewpoint-dependent object recognition in dissociable neural subsystems. *Psychon Bull Rev* 7:480–489.

Buxbaum LJ, Coslett HB (1996) Deep dyslexic phenomena in a letter-by-letter reader. *Brain Lang* 54:136–167.

Cabeza R, Nyberg L (2000) Imaging cognition. II. An empirical review of 275 PET and fMRI studies. *J Cogn Neurosci* 12:1–47.

Castro-Caldas A, Salgado V (1984) Right hemifield alexia without hemianopia. *Arch Neurol* 41:84–87.

Chawla D, Rees G, Friston KJ (1999) The physiological basis of attentional modulation in extrastriate visual areas. *Nat Neurosci* 2:671–676.

Cohen L, Dehaene S (1995) Number processing in pure alexia: the effect of hemispheric asymmetries and task demands. *Neurocase* 1:121–137.

Cohen L, Dehaene S (1996) Cerebral networks for number processing: evidence from a case of posterior callosal lesion. *Neurocase* 2:155–174.

Cohen L, Dehaene S (1998) Competition between past and present: assessment and interpretation of verbal perseverations. *Brain* 121:1641–1659.

Cohen L, Dehaene S (2000) Calculating without reading: unsuspected residual abilities in pure alexia. *Cogn Neuropsychol* 17:563–583.

Cohen L, Dehaene S, Naccache L, Lehéricy S, Dehaene-Lambertz G, Hénaff MA, *et al.* (2000) The visual word form area: spatial and temporal characterization of an initial stage of reading in normal subjects and posterior split-brain patients. *Brain* 123:291–307.

Cohen L, Lehericy S, Chochon F, Lemer C, Rivaud S, Dehaene S (2002) Language-specific tuning of visual cortex? Functional properties of the visual word form area. *Brain* 125:1054–69.

Coltheart M (1980) Deep dyslexia: a right-hemisphere hypothesis. In: *Deep dyslexia* (Coltheart M, Patterson K, Marshall JC, eds), pp. 326–380. London: Routledge.

Corbetta M, Shulman GL (1998) Human cortical mechanisms of visual attention during orienting and search. *Phil Trans R Soc Lond B Biol Sci* 353:1353–1362.

Coslett HB, Monsul N (1994) Reading with the right hemisphere: evidence from transcranial magnetic stimulation. *Brain Lang* 46:198–211.

Coslett HB, Saffran EM (1989) Evidence for preserved reading in 'pure alexia'. *Brain* 112:327–359.

Coslett HB, Saffran EM (1998) Reading and the right hemisphere: evidence from acquired dyslexia. In: *Right hemisphere language comprehension* (Beeman M and Chiarello C, eds), pp. 105–132. Mahwah, NJ: Lawrence Erlbaum Associates.

Coslett HB, Saffran EM, Greenbaum S, Schwartz H (1993) Reading in pure alexia: the effect of strategy. *Brain* 116:21–37.

Damasio AR, Damasio H (1983) The anatomic basis of pure alexia. *Neurology* 33:1573–1583.

Dehaene S, Naccache L, Cohen L, Bihan DL, Mangin JF, Poline JB, *et al.* (2001) Cerebral mechanisms of word masking and unconscious repetition priming. *Nat Neurosci* 4:752–8.

Dehaene S, Le Clec'H G, Poline JB, Le Bihan D, Cohen L (2002) The visual word form area: a prelexical representation of visual words in the fusiform gyrus. *Neuroreport* 13:321–325.

Dejerine J (1891) Sur un cas de cécité verbale avec agraphie suivie d'autopsie. *Mém Soc Biol* 3:197–201.

Dejerine J (1892) Contribution à l'étude anatomo-pathologique et clinique des différentes variétés de cécité verbale. *Mém Soc Biol* 4:61–90.

Di Virgilio G, Clarke S (1997) Direct interhemispheric visual input to human speech areas. *Hum Brain Mapp* 5:347–354.

Friedman RB, Nitzberg Lott S (2000) Rapid word identification in pure alexia is lexical but not semantic. *Brain Lang* 00:000–000.

Gauthier II (2000) What constrains the organization of the ventral temporal cortex? *Trends Cogn Sci* 4:1–2.

Gazzaniga MS, Hillyard SA (1971) Language and speech capacity of the right hemisphere. *Neuropsychologia* 9:273–280.

Gazzaniga MS, Smylie CE (1984) Dissociation of language and cognition: a psychological profile of two disconnected right hemispheres. *Brain* 107:145–153.

Giraud AL, Price CJ (2001) The constraints functional neuroanatomy places on classical models of auditory word processing. *J Cogn Neurosci* 13:754–765.

Gitelman DR, Nobre AC, Parrish TB, LaBar KS, Kim YH, Meyer JR, *et al.* (1999) A large-scale distributed network for covert spatial attention:

- further anatomical delineation based on stringent behavioural and cognitive controls. *Brain* 122:1093–1106.
- Greenblatt SH (1973) Alexia without agraphia or hemianopsia. Anatomical analysis of an autopsied case. *Brain* 96:307–316.
- Greenblatt SH (1976) Subangular alexia without agraphia or hemianopsia. *Brain Lang* 3:229–245.
- Greenwald ML, Gonzalez Rothi LJ (1998) Lexical access via letter naming in a profoundly alexic and anomic patient: a treatment study. *J Int Neuropsychol Soc* 4:595–607.
- Grill-Spector K, Kushnir T, Edelman S, Avidan G, Itzchak Y, Malach R (1999) Differential processing of objects under various viewing conditions in the human lateral occipital complex. *Neuron* 24:187–203.
- Gusnard DA, Raichle ME (2001) Searching for a baseline: functional imaging and the resting human brain. *Nat Rev Neurosci* 2:685–694.
- Haywood M, Coltheart M (2000) Neglect dyslexia and the early stages of visual word recognition. *Neurocase* 6:33–44.
- Helenius P, Tarkiainen A, Cornelissen P, Hansen PC, Salmelin R (1999) Dissociation of normal feature analysis and deficient processing of letter-strings in dyslexic adults. *Cereb Cortex* 9:476–483.
- Hillis AE, Caramazza A (1995) A framework for interpreting distinct patterns of hemispatial neglect. *Neurocase* 1:189–207.
- Horwitz B, Rumsey JM, Donohue BC (1998) Functional connectivity of the angular gyrus in normal reading and dyslexia. *Proc Natl Acad Sci USA* 95:8939–8944.
- Iragui VJ, Kritchinsky M (1991) Alexia without agraphia or hemianopia in parietal infarction. *J Neurol Neurosurg Psychiatry* 54:841–842.
- Ishai A, Ungerleider LG, Martin A, Schouten JL, Haxby JV (1999) Distributed representation of objects in the human ventral visual pathway. *Proc Natl Acad Sci USA* 96:9379–9384.
- Ishai A, Ungerleider LG, Haxby JV (2000) Distributed neural systems for the generation of visual images. *Neuron* 28:979–990.
- Jernigan TL, Ostergaard AL, Law I, Svarer C, Gerlach C, Paulson OB (1998) Brain activation during word identification and word recognition. *Neuroimage* 8:93–105.
- Kanwisher N, McDermott J, Chun MM (1997) The fusiform face area: a module in human extrastriate cortex specialized for face perception. *J Neurosci* 17:4302–4311.
- Kreiman G, Koch C, Fried I (2000) Category-specific visual responses of single neurons in the human medial temporal lobe. *Nat Neurosci* 3:946–953.
- Lambon Ralph MA, McClelland JL, Patterson K, Galton CJ, Hodges JR (2001) No right to speak? The relationship between object naming and semantic impairment: neuropsychological evidence and a computational model. *J Cogn Neurosci* 13:341–356.
- Lavidor M, Ellis AW (2002) Word length and orthographic neighborhood size effects in the left and right cerebral hemispheres. *Brain Lang* 80:45–62.
- Lavidor M, Ellis AW, Shillcock R, Bland T (2001) Evaluating a split processing model of visual word recognition: effects of word length. *Brain Res Cogn Brain Res* 12:265–272.
- Leff AP, Crewes H, Plant GT, Scott SK, Kennard C, Wise RJ (2001) The functional anatomy of single-word reading in patients with hemianopic and pure alexia. *Brain* 124:510–521.
- Levy I, Hasson U, Avidan G, Hendler T, Malach R (2001) Center-periphery organization of human object areas. *Nat Neurosci* 4:533–539.
- Malach R, Levy I, Hasson U (2002) The topography of high-order human object areas. *Trends Cogn Sci* 6:176–184.
- Marsolek CJ (1995) Abstract visual-form representations in the left cerebral hemisphere. *J Exp Psychol Hum Percept Perform* 21:375–386.
- Marsolek CJ, Kosslyn SM, Squire LR (1992) Form-specific visual priming in the right cerebral hemisphere. *J Exp Psychol Learn Mem Cogn* 18:492–508.
- Marsolek CJ, Schacter DL, Nicholas CD (1996) Form-specific visual priming for new associations in the right cerebral hemisphere. *Mem Cognit* 24:539–556.
- Mazoyer B, Zago L, Mellet E, Bricogne S, Etard O, Houde O, *et al.* (2001) Cortical networks for working memory and executive functions sustain the conscious resting state in man. *Brain Res Bull* 54:287–298.
- McCandliss BD, Cohen L, Dehaene S (2003) The visual word form area: expertise for reading in the fusiform gyrus. *Trends Cogn Sci* 7:293–299.
- Mechelli A, Humphreys GW, Mayall K, Olson A, Price CJ (2000) Differential effects of word length and visual contrast in the fusiform and lingual gyri during reading. *Proc R Soc Lond B Biol Sci* 267:1909–1913.
- Mesulam MM (1998) From sensation to cognition. *Brain* 121:1013–1052.
- Miozzo M, Caramazza A (1998) Varieties of pure alexia: the case of failure to access graphemic representations. *Cogn Neuropsychol* 15:203–238.
- Molko N, Cohen L, Mangin JF, Chochon F, Lehéricy S, Le Bihan D, *et al.* (2002) Visualizing the neural bases of a disconnection syndrome with diffusion tensor imaging. *J Cogn Neurosci* 14:629–636.
- Morais J, Kolinsky R (1994) Perception and awareness in phonological processing: the case of the phoneme. *Cognition* 50:287–297.
- Mycroft R, Hanley JR, Kay J (2002) Preserved access to abstract letter identities despite abolished letter naming in a case of pure alexia. *J Neuroling* 15:99–108.
- Nazir TA (2000) Traces of print along the visual pathway. In: *Reading as a perceptual process* (Kennedy A, Radach R, Heller D, Pynte J, eds), pp. 3–22. Amsterdam: Elsevier.
- Oldfield RC (1971) The assessment and analysis of handedness: the Edinburgh inventory. *Neuropsychologia* 9:97–113.
- Patterson K, Vargha-Khadem F, Polkey CE (1989) Reading with one hemisphere. *Brain* 112:39–63.
- Pirozzolo FJ, Kerr KL, Obrzut JE, Morley GK, Haxby JV, Lundgren S (1981) Neurolinguistic analysis of the language abilities of a patient with a 'double disconnection syndrome': a case of subangular alexia in the presence of mixed transcortical aphasia. *J Neurol Neurosurg Psychiatry* 44:152–155.
- Price CJ (1997) Functional anatomy of reading. In: *Human brain function* (Frackowiak RSJ, Friston KJ, Frith CD, Dolan RJ, Mazziotta JC, eds), pp. 301–328. San Diego, CA: Academic Press.
- Price CJ, Friston KJ (1997) The temporal dynamics of reading: a PET study. *Proc R Soc Lond B Biol Sci* 264:1785–1791.
- Price CJ, Friston KJ (2002) Degeneracy and cognitive anatomy. *Trends Cogn Sci* 6:416–421.
- Price CJ, Moore CJ, Frackowiak RS (1996a) The effect of varying stimulus rate and duration on brain activity during reading. *Neuroimage* 3:40–52.
- Price CJ, Wise RJS, Frackowiak RSJ (1996b) Demonstrating the implicit processing of visually presented words and pseudowords. *Cereb Cortex* 6:62–70.
- Puce A, Allison T, Asgari M, Gore JC, McCarthy G (1996) Differential sensitivity of human visual cortex to faces, letterstrings, and textures: a functional magnetic resonance imaging study. *J Neurosci* 16:5205–5215.
- Raichle ME, MacLeod AM, Snyder AZ, Powers WJ, Gusnard DA, Shulman GL (2001) A default mode of brain function. *Proc Natl Acad Sci USA* 98:676–682.
- Sakai K, Miyashita Y (1991) Neural organization for the long-term memory of paired associates. *Nature* 354:152–155.
- Seymour SE, Reuter-Lorenz PA, Gazzaniga MS (1994) The disconnection syndrome: basic findings reaffirmed. *Brain* 117:105–115.
- Sidtis JJ, Volpe BT, Holtzman JD, Wilson DH, Gazzaniga MS (1981) Cognitive interaction after staged callosal section: evidence for transfer of semantic activation. *Science* 212:344–346.
- Simon O, Mangin JF, Cohen L, Le Bihan D, Dehaene S (2002) Topographical layout of hand, eye, calculation, and language-related areas in the human parietal lobe. *Neuron* 33:475–487.
- Small SL, Flores DK, Noll DC (1998) Different neural circuits subserve reading before and after therapy for acquired dyslexia. *Brain Lang* 62:298–308.
- Somers DC, Dale AM, Seiffert AE, Tootell RBH (1999) Functional MRI reveals spatially specific attentional modulation in human primary visual cortex. *Proc Natl Acad Sci USA* 96:1663–1668.
- Suzuki K, Yamadori A, Endo K, Fujii T, Ezura M, Takahashi A (1998) Dissociation of letter and picture naming resulting from callosal disconnection. *Neurology* 51:1390–1394.

- Tagamets MA, Novick JM, Chalmers ML, Friedman RB (2000) A parametric approach to orthographic processing in the brain: an fMRI study. *J Cogn Neurosci* 12:281–297.
- Talairach J, Tournoux P (1988) Co-planar stereotaxic atlas of the human brain. 3-Dimensional proportional system: an approach to cerebral imaging (Mark Rayport, trans.). New York: Thieme Medical Publishers/Stuttgart: George Thieme Verlag.
- Tanaka K (1996) Inferotemporal cortex and object vision. *Annu Rev Neurosci* 19:109–139.
- Tarkiainen A, Helenius P, Hansen PC, Cornelissen PL, Salmelin R (1999) Dynamics of letter string perception in the human occipitotemporal cortex. *Brain* 122:2119–2132.
- Tsunoda K, Yamane Y, Nishizaki M, Tanifuji M (2001) Complex objects are represented in macaque inferotemporal cortex by the combination of feature columns. *Nat Neurosci* 4:832–838.
- Vallar G (2001) Extrapersonal visual unilateral spatial neglect and its neuroanatomy. *Neuroimage* 14:S52–S58.
- Vogt BA, Finch DM, Olson CR (1992) Functional heterogeneity in cingulate cortex: the anterior executive and posterior evaluative regions. *Cereb Cortex* 2:435–443.
- Wagner AD, Schacter DL, Rotte M, Koutstaal W, Maril A, Dale AM, *et al.* (1998) Building memories: remembering and forgetting of verbal experiences as predicted by brain activity. *Science* 281:1188–1191.
- Warrington EK, Shallice T (1980) Word-form dyslexia. *Brain* 103:99–112.
- Weekes BS (1997) Differential effects of number of letters on word and non-word naming latency. *Q J Exp Psychol* 50A:439–456.
- Xu B, Grafman J, Gaillard WD, Ishii K, Vega-Bermudez F, Pietrini P, *et al.* (2001) Conjoint and extended neural networks for the computation of speech codes: the neural basis of selective impairment in reading words and pseudowords. *Cereb Cortex* 11:267–277.