

Subarachnoid haemorrhage due to cervical spinal cord haemangioblastomas in a patient with von Hippel-Lindau disease

A. Berlis¹, M. Schumacher¹, J. Spreer¹, H. P. H. Neumann², and V. van Velthoven³

¹ Section of Neuroradiology, University of Freiburg, Freiburg, Germany

² Department of Nephrology and Hypertension, University of Freiburg, Freiburg, Germany

³ Department of Neurosurgery, University of Freiburg, Freiburg, Germany

Summary

A case is presented with severe infra- and supratentorial subarachnoid haemorrhage (SAH) caused by intramedullary haemangioblastomas of the cervical spinal cord. The patient initially had a typical SAH symptomatology without neurological deficit. The cerebral angiogram was nondiagnostic. After admission the patient developed slightly progressive right sensorimotor paresis. Angiography of the cervical spine and MRI delineated three intramedullary haemangioblastomas. Retrospectively the diagnosis of von Hippel-Lindau (VHL) disease was made by multiple haemangioblastomas and a positive family history. The three lesions were surgically completely removed.

Introduction

The incidence of SAH is about six cases per 100 000 people annually [14]. The reason for SAH is predominantly a ruptured aneurysm in about 85% of cases. Non-aneurysmal perimesencephalic haemorrhage is found in 10% and other rare conditions in 5% [14]. SAH of spinal origin is rare and accounts for less than 1% of cases [3]. Common sources are arteriovenous malformations and tumours predominantly neurinomas and ependymomas. In the literature only nine cases of spinal haemangioblastomas with SAH have been reported [3, 4, 6, 8–11]. We present a case of three haemangioblastomas of the cervical spine causing intracranial SAH associated with a positive family history for von Hippel-Lindau disease (VHL).

Case report

This previously healthy 47 year old woman suddenly collapsed during shopping in March 2001. After a few minutes she recovered spontaneously and complained of severe headache, nuchal pain, nausea, and pronounced neck rigidity (Hunt + Hess Grading I, GCS 14). Initially no other abnormalities were found on neurological examination. After admission the patient developed a slightly progressive right hemihypesthesia and a paresis of the right arm.

Examination

Cranial CT showed severe infra- and supratentorial as well as cervical SAH at level C0/1 SAH Fisher-Grading 3 (Fig. 1). Initial cerebral angiography showed no pathological findings. Three days later an additional cervical spinal angiography revealed three tumours: one with a diameter of about 10 mm at level C1/2 and the others at level C3/4 to C5 and C5 to C6 with a total length of about 45 mm (Fig. 2). MRI of the whole spine and head confirmed the three intramedullary tumours, one of them reaching the cord's surface at level C5. There was an extraordinarily severe swelling of the medulla oblongata, the cervical and upper thoracic spinal cord (Fig. 3). Other haemangioblastomas could be detected at level D3 and in the left cerebellar hemisphere, both with a diameter of about 3 mm.

Family history and genetic analysis

A few years ago the son of the patient was found to have multiple haemangioblastomas and a cerebellar

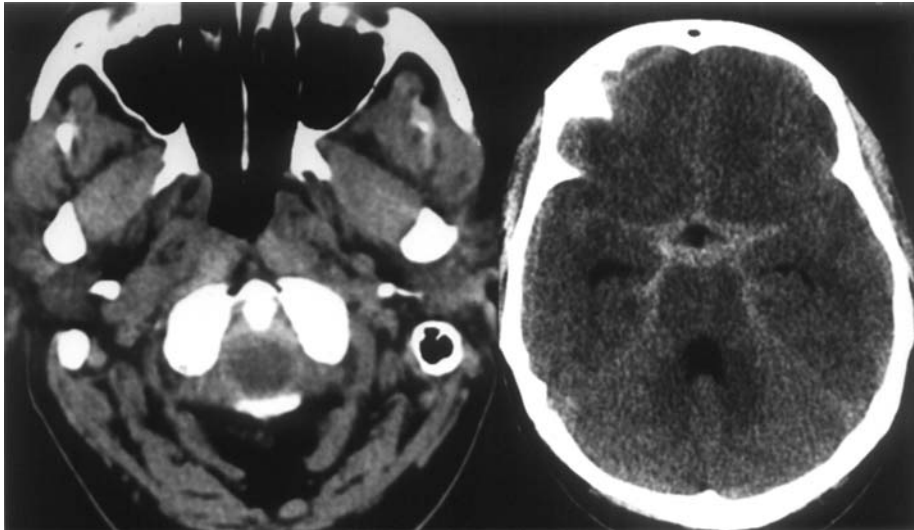


Fig. 1. Initial plain CT with infra- and supratentorial SAH

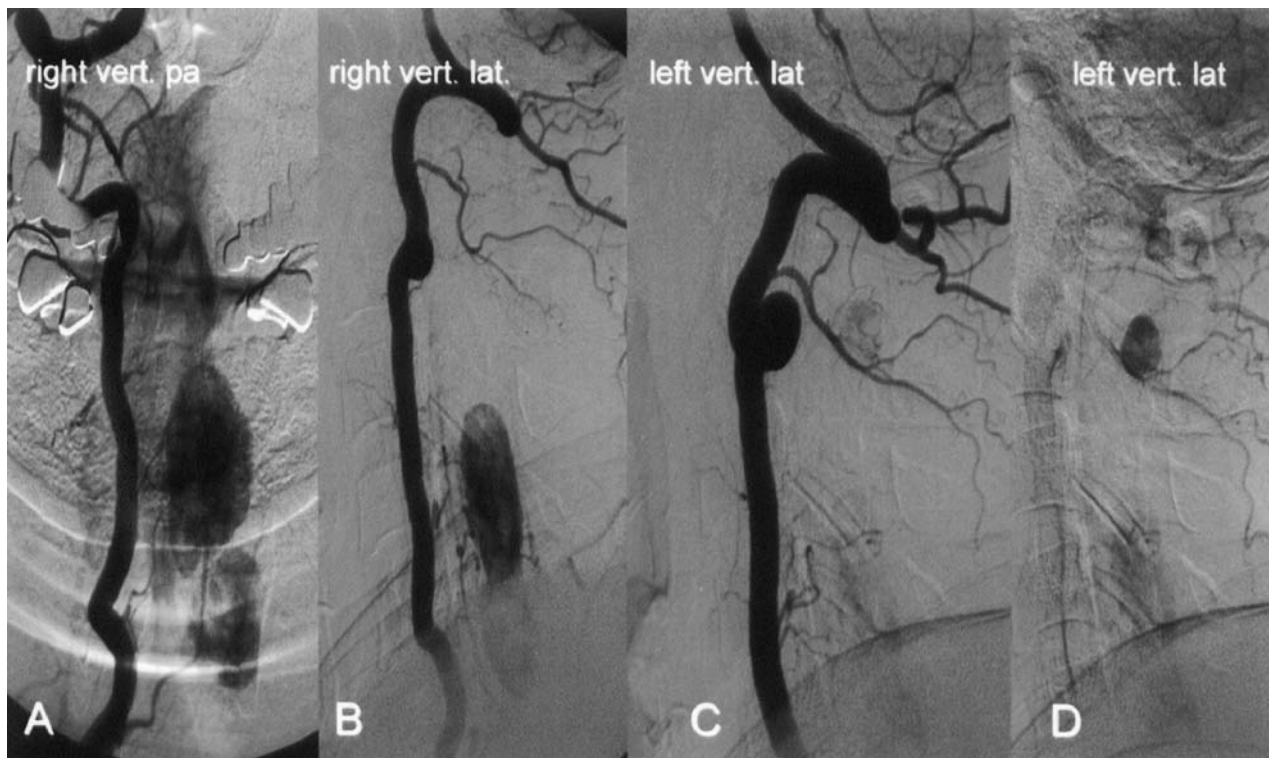


Fig. 2. Angiogram of right vertebral artery with intense tumour stain at C3–C6 (A, B) and lateral view of left vertebral artery with tumour stain at C1/2 (C, D). Typical tumour vascularization via segmental arteries C4–6 on the right side and C2, C4–5 on the left side to pial branches of the spinal arteries

haemangioblastoma was operated on. In the genetic analysis no VHL-tumour suppressor gene was detected. Other family members including the patient presented refused further examinations such as MRI and genetic screening. Following the actual detection of the multiple haemangioblastomas the genetic analysis was neg-

ative in the whole family. Consecutive MRI of the family showed multiple haemangioblastomas in a daughter of the patient.

In order to detect germline mutations of the VHL gene, molecular genetic analysis of constitutional DNA was performed. The DNA was extracted from peripheral

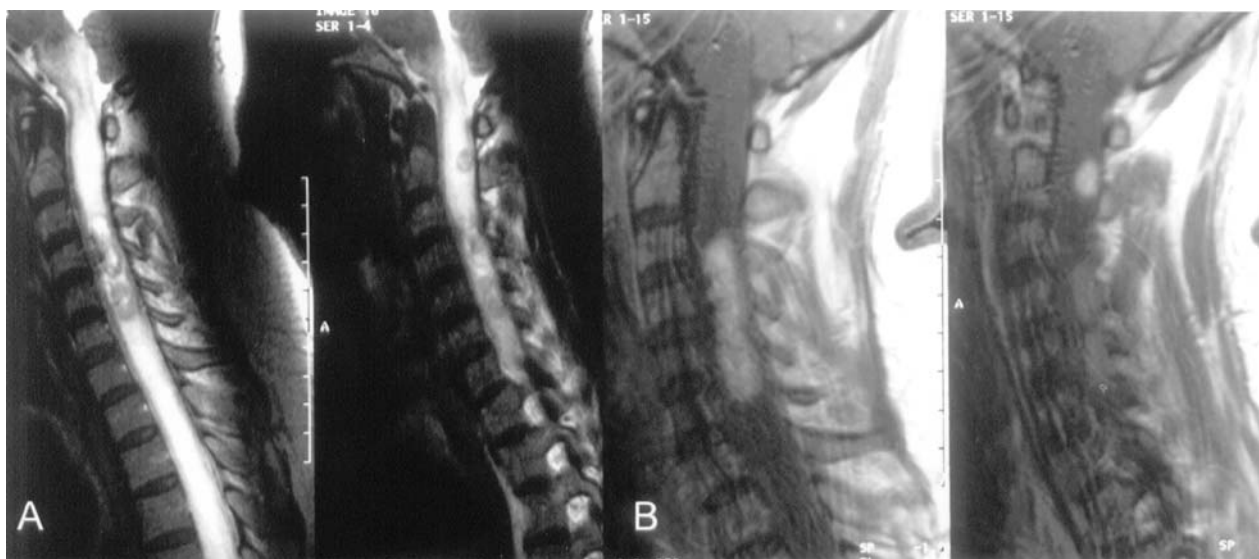


Fig. 3. Initial MRI with high signal of medulla oblongata, cervical and upper thoracic spinal cord caused by severe cord swelling (T2-weighted images – A). Delineation of intramedullary haemangioblastomas after contrast (T1-weighted images – B)

blood leucocytes by standard protocols. In order to detect point mutations and small deletions and insertions, we performed PCR followed SSCP as recently published [7]. To detect large germline deletions and insertions, we used southern analysis. This method has also been previously described [7].

Operation

The cervical lesions were approached by laminotomy C2 to C6 and total removal was achieved. Because of

severe swelling of the cord the laminotomy block was not replaced instantly but frozen for subsequent re-implantation. Typical haemangioblastomas were found intraoperatively and confirmed histopathologically.

Postoperative course

Early postoperative MRI revealed a small subdural bleeding and swelling of the cervical spinal cord without pathological contrast enhancement. Neurological examination showed severe sensory ataxia, hyperhidrosis,

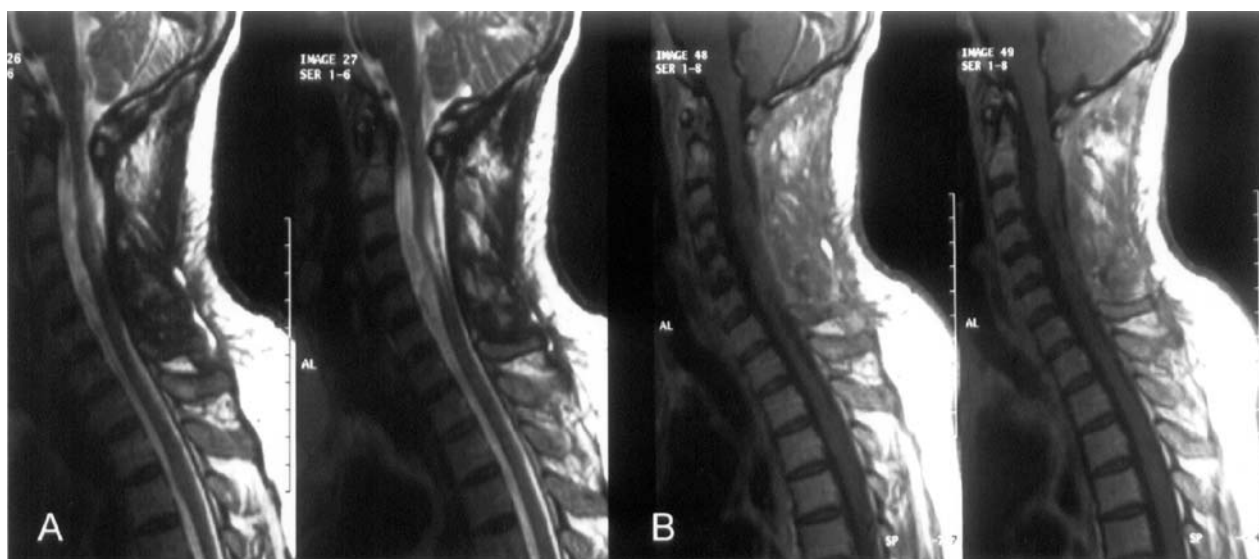


Fig. 4. MRI three months after complete tumour resection with complete restitution of cord swelling, but with postoperative spinal cord defect at level C3–C5 (T2-weighted images – A). T1-weighted images (B) revealed no pathological contrast enhancement in the cervical spinal cord but cord adhesions at level C5 and C6

disturbance of the epicritic sensory system as well as impaired skilled movements of both hands and a slight paresis of the right arm. Three months later the neurological impairment of the patient had improved with a residual slight impairment of skilled movement of the right hand, a slight ataxia and minor paresis of the right arm. MRI revealed complete restitution of cord swelling, a residual cyst at level C3 to C5 and the complete resection of the cervical spinal cord tumours (Fig. 4). In a second operation three months later frozen laminae C2–C6 were re-implanted and the cord adhesions at level C5 and C6 were detached. The further postoperative course was uneventful with finally recovery of the neurological deficits ten months after SAH.

Discussion

Haemangioblastomas of the spinal cord are benign tumours representing 1.6%–6.4% of spinal cord tumours [5] and are the third most frequent intramedullary spinal cord tumour besides ependymoma and astrocytoma [1]. About 60% of spinal haemangioblastomas are intramedullary, 11% are combined intramedullary and extramedullary tumours, 21% are intradural extramedullary, and 8% are extradural [5]. Most frequently, spinal cord haemangioblastomas occur in the thoracic region (50%), followed by the cervical region in 40% [10]. Up to now only nine cases with SAH due to a spinal haemangioblastoma have been published, one patient without description of tumour site [3, 4, 6, 8–11]. Including the case presented the lesion sites were the cervical spine in seven of nine patients, the thoracic and lumbar spine in one patient each. The tumours were located intramedullarily in five of nine cases and extramedullary in four cases.

Approximately 25% of haemangioblastomas are associated with VHL disease (incidence of VHL: 1:36000–45500) [2]. The diagnostic criteria of VHL are based on presence of haemangioblastoma in the CNS or retina, and the presence of one of the typical VHL-associated tumours like clear cell renal carcinoma, pheochromocytoma, pancreatic and inner ear tumours or a positive family history. Multiple haemangioblastomas are almost exclusively found in VHL patients [13]. The syndrome is caused by germline mutations of the VHL tumour suppressor gene located on chromosome 3p25–26. In VHL disease germline VHL mutations were identified in 86% [7]. In the present patient the diagnosis of VHL was proved by multiple haemangioblastomas in the spinal cord and cerebellum, and a positive family history in two of three children

with detection of multiple haemangioblastomas. It is of major interest that a mutation of the VHL-tumour suppressor gene could not be detected in this family. This was the reason not to insist on a refused MRI-examination of the whole family even though haemangioblastomas in the son of the patient were known. An early family examination with MRI could have proved the VHL-disease and the multiple asymptomatic tumours of the mother could have been detected earlier.

Regular MRI screenings can detect changes in tumour size. In our institution tumour growth in MRI follow up is considered as an indication for operation. In the case described here there is a chance that applying this strategy the operation would have been performed before SAH occurred. The indication for operation is debatable. In our experience tumour progression justifies the surgical removal also in asymptomatic patients. Even without tumour progression the knowledge of the existence of the tumours in this patient would have had resulted in earlier diagnostic steps after detection of SAH with the possibility to avoid the aggravation of the neurological condition.

Complete removal of spinal cord haemangioblastomas is possible in most cases with a low rate of surgical complications and good prognosis [11, 12]. In our case the large cervical tumours were excised totally with finally recovery of neurological deficits.

This case points out that a SAH, particularly if the posterior fossa is involved, requires angiography of the supra-aortic cervical vessels when the cerebral angiogram is nondiagnostic. Furthermore in patients with haemangioblastomas negative for VHL tumour suppressor gene a thorough investigation should be performed. Current recommendation is to search for constitutional mutations of the VHL gene. However, in a certain fraction (about 14%) the mutation could not be detected in our center [7]. A recent report has now detected 100% of mutations in VHL patients by improved detection methods [13]. The methodological innovation of this report is a quantitative Southern blot, which will also be established in our center. Finally, all cases with hereditary haemangioblastomas should undergo a screening program including MRI of the brain, spinal cord, kidney, pancreas and adrenal glands as well as measurement of catecholamines in order to detect further tumours in time.

Acknowledgments

The authors thank Ralf Kubalek, M.D., Peter Reinacher, M.D., and Sven Gläsker, M.D. for reviewing and thoughtful contributions to the manuscript.

References

1. Baleriaux DL (1999) Spinal cord tumors. *Eur Radiol* 9: 1252–1258
2. Böhlting T, Plate KH, Maltia M, Alitalo K, Neumann HPH (2000) Von Hippel-Lindau disease and capillary haemangioblastoma. Pathology and genetics of tumours of the nervous system, 2nd edn, chapter 14. In: Kleihues P, Cawenee WK (eds) International agency for research on cancer. World Health Organization, Lyon, pp 223–226
3. Cerejo A, Vaz R, Foyo PB, Cruz C (1990) Spinal cord hemangioblastoma with subarachnoid hemorrhage. *Neurosurgery* 28: 991–993
4. Cervoni L, Franco C, Celli P, Fortuna A (1995) Spinal tumors and subarachnoid hemorrhage: pathogenetic and diagnostic aspects in 5 cases. *Neurosurg. Rev.* 18: 159–162
5. Chu B-C, Terae S, Hida K, Furukawa M, Abe S, Miyasaka K (2001) MR findings in spinal hemangioblastoma: Correlation with symptoms and with angiographic and surgical findings. *AJNR Am J Neurorad* 22: 206–217
6. Djindjian M, Djindjian R, Houdart R, Hurth M (1978) Subarachnoid hemorrhage due to intraspinal tumors. *Surg Neurol* 9: 223–229
7. Gläsker S, Bender BU, Apel TW, van Velthoven V, Mulligan LM, Zentner J, Neumann HP (2001) Reconsideration of biallelic inactivation of the VHL tumour suppressor gene in hemangioblastomas of the central nervous system. *J Neurol Neurosurg Psychiatry* 70: 644–648
8. Irie K, Kuyama H, Nagao S (1998) Spinal cord hemangioblastoma presenting with subarachnoid hemorrhage. *Neurol Med Chir* 38: 355–358
9. Kormos RL, Tucker WS, Bilbao JM, Gladstone RM, Bass AG (1980) Subarachnoid hemorrhage due to a spinal hemangioblastoma: case report. *Neurosurgery* 6: 657–660
10. Minami M, Hanakita J, Suwa H, Suzui H, Fujita K, Nakamura T (1998) Cervical hemangioblastoma with a past history of subarachnoid hemorrhage. *Surg Neurol* 49: 278–281
11. Neumann HPH, Eggert HR, Weigel K, Friedburg H, Wiestler OD, Schollmeyer P (1989) Hemangioblastomas of the central nervous system. *J Neurosurg* 70: 24–30
12. Roonprapunt C, Silvera VM, Setton A, Freed D, Epstein FJ, Jallo G (2001) Surgical management of isolated hemangioblastomas of the spinal cord. *Neurosurgery* 49: 321–327
13. Stolle C, Glenn G, Zbar B, Humphrey JS, Choyke P, Walther M, Pack S, Hurley K, Andrey C, Klausner R, Linehan WM (1998) Improved detection of germline mutations in the von Hippel-Lindau disease tumor suppressor gene. *Hum Mutat* 12: 417–423
14. van Gijn J, Rinkel GJE (2001) Subarachnoid haemorrhage: diagnosis, causes and management. *Brain* 124: 249–278

Comment

This manuscript reports a rare case of spinal haemangioblastomas causing Subarachnoid haemorrhage (SAH) with a family history of von Hippel Lindau disease. Although this is an interesting article that shows the importance of cervical evaluation in SAH patients with negative conventional angiograms, nine cases of spinal haemangioblastoma with SAH have already been reported. Thus, this report does not provide remarkable contributions on diagnosis and treatment of spinal cord haemangioblastomas. Another important point of this article is negative gene analysis in a patient with typical VHL-disease. Inactivation of the VHL tumor suppressor gene at 3p25–26 is considered to be a common oncogenic mechanism in VHL-associated tumors, and germline mutations of this gene are reported to be present in 63 to 100% of VHL-related haemangioblastomas. Improved detection of germline mutation in the VHL tumor suppressor gene was previously reported using sophisticated methods [1].

Reference

1. Stolle C, Glenn G, Humphrey JS *et al* (1998) Improved detection of germline mutations in the von Hippel-Lindau disease tumor suppressor gene. *Hum Mutat* 12: 417–423

S. Nagao
Kagawa

Correspondence: Dr. Ansgar Berlis, Section of Neuroradiology, University of Freiburg, Breisacherstr. 64, D-79106 Freiburg. e-mail: BERLIS@nz.ukl.uni-freiburg.de