

SHORT COMMUNICATION

Left internal carotid artery dissection presenting with headache, Collet-Sicard syndrome and sustained hypertension

S. Walker^a, M. O. McCarron^a, P. A. Flynn^b and M. Watt^a

^aDepartments of Neurology and ^bNeuroradiology, Royal Victoria Hospital, Belfast, UK

Keywords:

hypertension, internal carotid artery dissection

The baroreflex maintains blood pressure through the glossopharyngeal (IX) cranial nerve. We report a 54-year-old man who developed a left sided headache, hoarseness, dysarthria, dysphagia, and sustained hypertension from a left internal carotid artery dissection. We hypothesise that interruption of the left IX nerve caused hypertension in this patient.

Received 9 April 2002

Accepted 4 May 2003

Introduction

Pain on one side of the head, face or neck accompanied by a partial Horner's syndrome and cerebral or retinal ischaemia is found in less than one third of patients with dissection of the internal carotid artery (ICA) (Schievink, 2001). Presentations with lower cranial nerve palsies are recognized and usually, but not always (McCarron *et al.*, 2000) involve cranial nerve XII.

The baroreflex and medulla are important components in blood pressure regulation. Microvascular decompression of the left ventrolateral medulla has improved control of hypertension in some patients (Geiger *et al.*, 1998). Interruption of cranial nerve IX demonstrates the role of the baroreflex in the maintenance of blood pressure and sectioning of this cranial nerve in humans has produced sustained hypertension (Ripley *et al.*, 1977).

Case report

A 54-year-old man, had a gradual onset of a severe left parieto-occipital headache. Two days later he developed dysarthria, hoarseness and swallowing problems. His blood pressure increased from 160/100 to 170/110 mmHg. No previous blood pressure recordings were available, but he had no evidence of organ damage either in the form of left ventricular hypertrophy or retinopathy. He had deviation of the uvula to the right, reduced palatal movement, and weakness of left upper trapezius and sternocleidomastoid. He had left vocal cord weakness and his tongue deviated to the left. He had no taste disturbance and no Horner's syndrome. Clinical assessment suggested cranial nerve IX, X, XI, and XII palsies or a left Collet-Sicard syndrome.

A T1-weighted axial MRI scan of brain suggested left ICA dissection (Fig. 1a). A subtle but definite contour irregularity on conventional angiography confirmed this (Fig. 1b). The patient was treated with amlodipine and bisoprolol for increasing hypertension (180/140 mmHg). He was also given aspirin. His headache, dysarthria and swallowing gradually improved. At follow-up 4 months later, he had returned to work as a teacher, normotensive with a mild dysarthria and left hypoglossus weakness.

At 1 year follow-up his blood pressure was well controlled. The patient was weaned off both his anti-hypertensive medications. Weekly monitoring of his blood pressure revealed that he then had mild hypertension (140/96 mmHg), which was successfully controlled with just bisoprolol. A follow-up MRI and MRA scan demonstrated loss of the hyperintense signal within the ICA wall, consistent with resolution of the haematoma, and a normal calibre distal ICA.

Discussion

This patient experienced headache, increasing hypertension and progressive left lower cranial nerve palsies in the setting of a left ICA dissection. Like many patients with cranial nerve palsies from ICA dissection, he had no central focal ischaemic lesions (Baumgartner *et al.*, 2001). He had only one of the classic triad of features of ICA dissection – pain, which is often the initial manifestation. Lower cranial nerve palsies are increasingly recognized as the sole presenting feature of ICA dissection (Mokri *et al.*, 1996). The Collet-Sicard syndrome (cranial nerve palsies IX, X, XI and XII) has been described in patients with ICA dissection, (Heckman *et al.*, 2000) but co-existent and sustained hypertension in the absence of ischaemic brain disease has seldom been documented. There is one case report of paroxysmal hypertension in a patient with a right ICA dissection 5 years after a left ICA dissection (Laing *et al.*, 2000). This patient had bilateral Horner's syndrome with no

Correspondence: Dr Mark McCarron, Department of Neurology, Royal Victoria Hospital, Belfast, BT12 6BA, UK (fax: +44 (0)28 9023 5258; e-mail: markmccarron@doctors.org.uk).

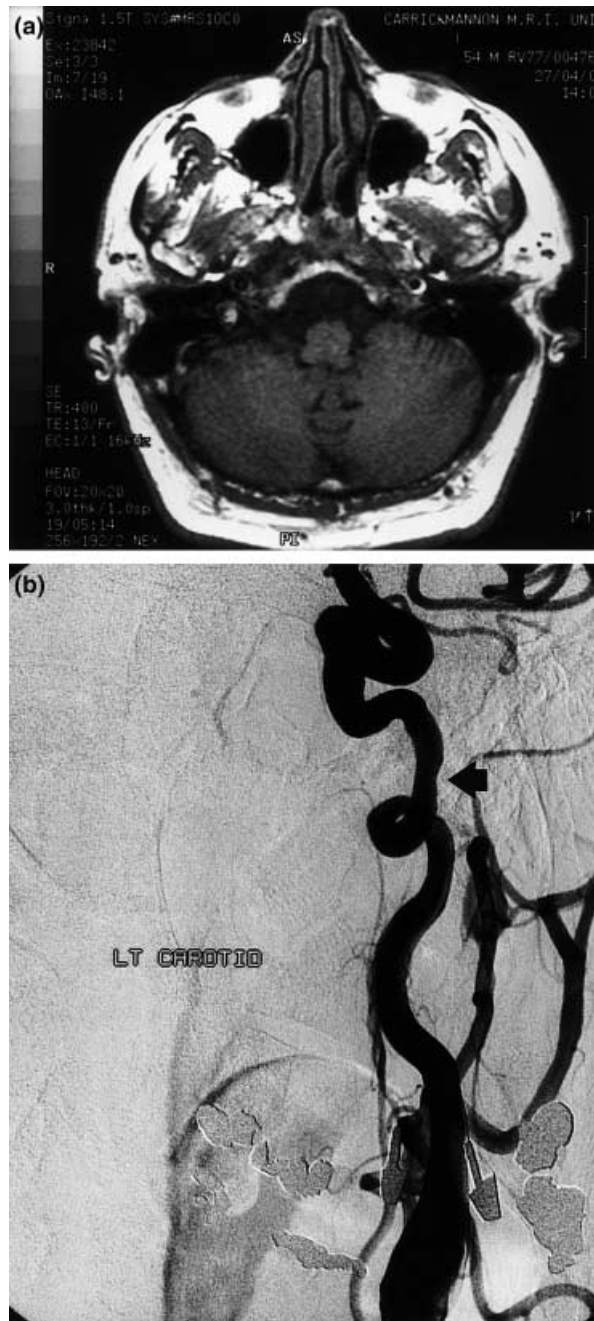


Figure 1 Axial T1-weighted MR scan shows a hyperintense signal consistent with expansion of the wall of the left ICA (a) and at angiography there is an irregular contour of the ICA lumen (arrow) at the level of the dissection (b).

cranial nerve palsies and demonstrated labile hypertension, characteristic of true baroreflex failure (Robertson *et al.*, 1993). Transient elevation of blood pressure also

occurs following carotid endarterectomy, which may also be secondary to baroreceptor deafferentation (Fagius and Wallin, 1983). Our patient had residual mild hypertension. This may have corresponded to his blood pressure before the ICA dissection or it may have reflected a re-setting of his blood pressure control after the dissection, a feature previously documented after glossopharyngeal nerve palsy (Ripley *et al.*, 1977).

Diagnosis of cranial nerve IX palsy is not easy and may not be associated with loss of taste or other sensory or motor impairment. As cranial nerve IX plays a prominent role in blood pressure regulation, we hypothesize that the sustained hypertension in our patient resulted from damage to his left cranial nerve IX. This is supported by the evidence that vascular decompression of the ventrolateral medulla to treat hypertension is usually performed on the left side (Jannetta *et al.*, 1985; Geiger *et al.*, 1998).

References

- Baumgartner RW, Arnold M, Baumgartner I *et al.* (2001). Carotid dissection with and without ischemic events: local symptoms and cerebral artery findings. *Neurology* **57**:827–832.
- Fagius J, Wallin BG (1983). Microneurographic evidence of excessive sympathetic outflow in the Guillain-Barre syndrome. *Brain* **106**:589–600.
- Geiger H, Naraghi R, Schobel HP, Frank H, Sterzel RB, Fahlbusch R (1998). Decrease of blood pressure by ventrolateral medullary decompression in essential hypertension. *Lancet* **352**:446–449.
- Heckman JG, Tomandl B, Duhm C, Stefan H, Neundorfer B (2000). Collet-Sicard syndrome due to coiling and dissection of the internal carotid artery. *Cerebrovasc Dis* **10**:487–488.
- Jannetta PJ, Segal R, Wolfson SK Jr. (1985). Neurogenic hypertension: etiology and surgical treatment. I. Observations in 53 patients. *Ann Surg* **201**:391–398.
- Laing C, Thomas DJ, Mathias CJ, Uuwin RJ (2000). Headache, hypertension and Horner's syndrome. *J R Soc Med* **93**:535–536.
- McCarron MO, Metcalfe RA, Muir KW (2000). Facial nerve palsy secondary to internal carotid artery dissection. *Eur J Neurol* **7**:723–725.
- Mokri B, Silbert PL, Schievink WI, Piepgras DG (1996). Cranial nerve palsy in spontaneous dissection of the extracranial internal carotid artery. *Neurology* **46**:356–359.
- Ripley RC, Hollifield JW, Nies AS (1977). Sustained hypertension after section of the glossopharyngeal nerve. *Am J Med* **62**:297–302.
- Robertson D, Hollister AS, Biaggioni I, Netteville JL, Mosqueda-Garcia R, Robertson RM (1993). The diagnosis and treatment of baroreflex failure. *N Engl J Med* **329**:1449–1455.
- Schievink WI (2001). Spontaneous dissection of the carotid and vertebral arteries. *N Engl J Med* **344**:898–906.