

Case report

# Yawning despite trismus in a patient with locked-in syndrome caused by a thrombosed megadolichobasilar artery

Michael Krasnianski<sup>a,b</sup>, Charly Gaul<sup>a,\*</sup>, Stephan Neudecker<sup>a</sup>, Curd Behrmann<sup>b</sup>,  
Andreas Schlüter<sup>b</sup>, Martin Winterholler<sup>a</sup>

<sup>a</sup> Department of Neurology, Martin-Luther-University Halle-Wittenberg, Ernst-Grube-Str. 40, D-06097 Halle (Saale), Germany

<sup>b</sup> Department of Radiology, Martin-Luther-University Halle-Wittenberg, D-06097 Halle (Saale), Germany

Received 27 March 2003; accepted 17 April 2003

## Abstract

We report a 62-year-old woman with a locked-in syndrome with bilateral masticatory spasms and persistent trismus, who was still able to yawn. A vascular malformation of the basilar artery–megadolichobasilar artery (fusiform aneurysm, vertebrobasilar dolichoectasia) was determined to be the underlying cause of this rare combination of symptoms. A thrombus in the megadolichobasilaris as well as an almost total pontine infarction were demonstrated on CT- and MRI-scans. Thus, trismus may be associated with locked-in syndrome due to megadolichobasilar artery thrombus, although yawning is still possible.

© 2003 Elsevier B.V. All rights reserved.

**Keywords:** Locked-in syndrome; Megadolichobasilar artery; Yawning

## 1. Introduction

The term “locked-in syndrome” was proposed in 1966 by Plum and Posner [1]. Nevertheless, this condition was first described by Alexandre Dumas with the figure of the totally paralysed M. Noirtier de Villefort in his book “Le comte de Monte-Cristo”, edited 1844–1845, over 100 years before. M. Noirtier de Villefort was alert and oriented, but he could communicate only with his eyes [2]. In this novel, Noirtier de Villefort dictates his last will to an advocate by using eye movements, blinking and a letter list. The clinical criteria of complete locked-in syndrome are tetraplegia and paralysis of cranial nerves except vertical eye movements and preserved consciousness [1].

We describe a patient with a locked-in syndrome due to a vascular malformation of the basilar artery–megadolichobasilar artery (fusiform aneurysm, vertebrobasilar dolichoectasia) with bilateral masticatory spasms and persistent trismus. Yawning with complete opening of the mouth despite to trismus as a voluntary–involuntary dissociation was present.

## 2. Case report

A 62-year-old woman presented with sudden onset of weakness of right side limbs. On admission, the patient was alert and orientated. She had deviation of both eyes to the right side with gaze palsy to the left side. Other cranial nerves were spared. The patient had a moderate right hemiparesis involving equally the arm and the leg with minimal flaccidity in the paretic limbs. The deep tendon reflexes were absent. She had a right Babinski response. No cerebellar ataxia was observed and no sensory deficits could be detected. CT performed on the first hospital day demonstrated an extremely dilated basilar artery with small thrombus in the tip of the basilar artery (Fig. 1), and MRI demonstrated left pontine infarction, and a megadolichobasilaris (Fig. 2).

The patient was treated with 20 000 units heparin intravenously daily and all the symptoms except right leg paresis were transient. One week after the ictus, the right hemiparesis occurred again and it was progressive to tetraplegia for several hours. However, she was still alert and orientated. Contact by using of vertical eye movements and blinking was preserved. The patient had bilateral paresis of abducens nerve. She had a prominent hypomimia, but no lagophthalmus. She had bilateral masticatory spasms with trismus, but a frequent yawning (ca. every 5 min) with a

\* Corresponding author. Tel.: +49-345-557-2858;

fax: +49-345-557-2020.

E-mail address: sekretariat.neurologie@medizin.uni-halle.de (C. Gaul).

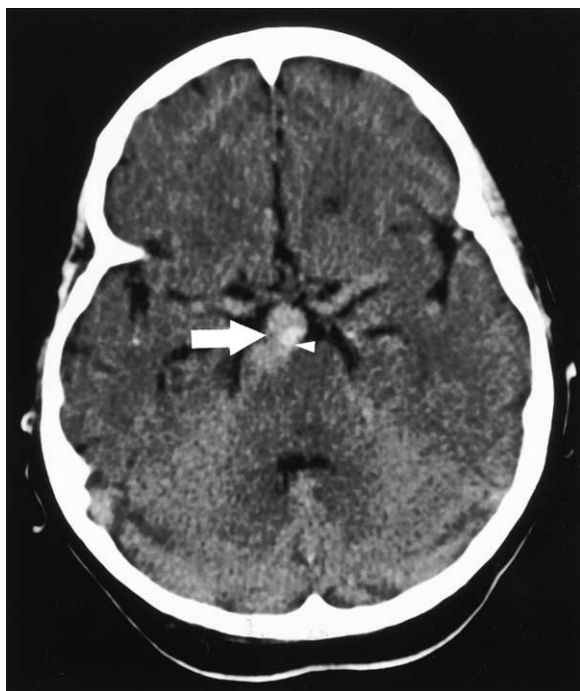

Fig. 1. Native CT scan showing an extremely dilated basilar artery (white arrow) with a small thrombus (white arrowhead) in the tip of the basilar artery.

complete opening of the mouth was possible. There were anarthria and severe dysphagia. She had soft palate paresis, and brisk gag reflexes. Masseter reflex was also very brisk. It was flaccid tetraplegia with bilateral Babinski signs and

extremely brisk deep tendon reflexes. No sensory deficits could be detected. MRI demonstrated massive and bilateral pontine infarction (Fig. 3).

### 3. Discussion

The clinical picture in our patient was corresponding to classical locked-in syndrome due to bilateral affection of pontine cranial nerves nuclei, lateral corticospinal tract and supranuclear affection of bulbar nuclei (pseudobulbar syndrome). The most common lesion underlying the locked-in syndrome is an occlusion of the basilar artery with destruction of the pontine base [3]. Other causes are bilateral midbrain stroke [4], bilateral capsula interna stroke [5], pontine gliomas [6], tentorial herniation [7], trauma [8], encephalitis [9], and peripheral causes as the Guillain–Barre syndrome [10].

Locked-in syndrome is often caused by pontine infarction, and pontine infarction is often associated with megadolichobasilaris [3,11,12]. However, the classical locked-in syndrome caused by the thrombosed megadolichobasilar artery is unusual [13].

Trismus due to irritation of the motor trigeminal area has been observed in patients with brainstem lesions as tumours [15], vascular lesions with pseudobulbar syndrome [16], multiple sclerosis [17], progressive supranuclear palsy [18], cerebral deep venous thrombosis [19], and motoneuron disease [20].

Unilateral trismus caused by vertebrobasilar dolichoectasia with truncal irritation of the motor root of the trigeminal

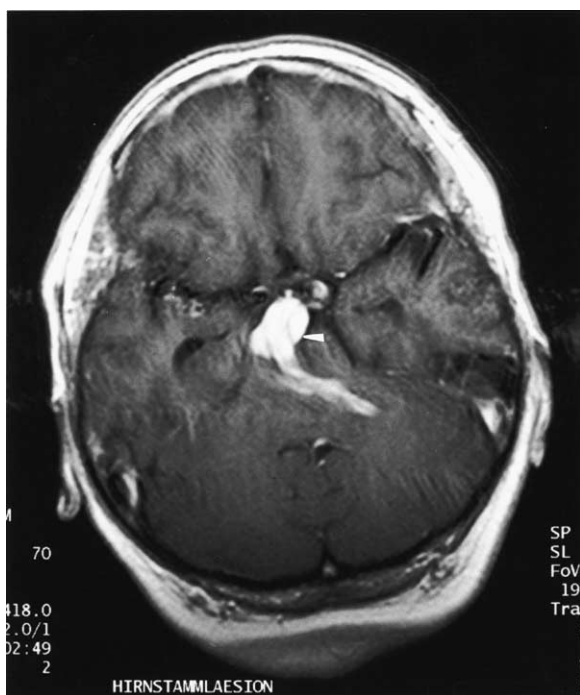


Fig. 2. Gadolinium-enhanced T1-weighted axial MRI sequence demonstrates a megadolichobasilaris (white arrowhead).

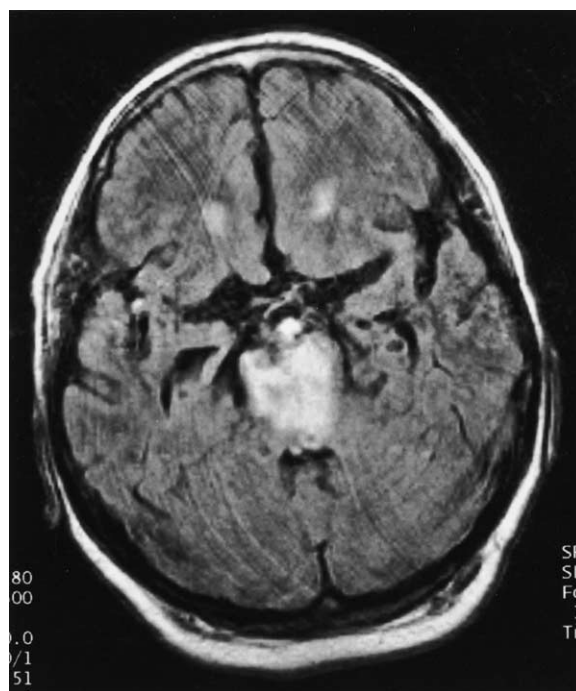


Fig. 3. T2-weighted axial MRI showing massive and bilateral pontine infarction.

nerve is a rare disease that has been described only once [14]. In contrast to an irritation of the trigeminal nerve in this patient, we presume that rather an irritation of the trigeminal nuclear area was the cause of trismus in our patient, because MRI could not demonstrate a contact of the megadolichobasilaris to both trigeminal roots.

Yawning is also a very unusual sign in patients with locked-in syndrome. A single description of yawning in locked-in syndrome was published in 1977 [21]. This patient with pontine glioma and locked-in syndrome could not open or close the mouth, but he was able to yawn. The author concluded that the motivation of yawning stems from the sleep inducting system in the region of the raphe-nuclei and is projected directly to the nuclei of the caudal brainstem nerves [21]. Nevertheless, the brainstem mechanisms of yawning are not completely understood, but it seemed that the question of Wimalaratna and Capildeo “Is yawning a brainstem phenomenon?” [22] can be answered partially. Respiratory neurons, motor nuclei of the 5, 7, 10 and 12th cranial nerve, phrenic nerve and accessory respiratory muscles, parasympathetic terminals of the lacrimal glands and the frontal cortex must be involved in yawning [23]. Anatomic centre of this complex neuronal network can be presumed in the lower brain stem nearby the brainstem reticular formation. The impetus of physiological yawning is not really clear. Abnormal frequent yawning can be caused by intoxication, by drug side effects, postencephalitic state, apallic syndrome, CNS tumours and some other conditions [24]. There must be a functional anatomic way to initiate and execute yawning as an involuntary motor phenomenon despite destruction of voluntary movements of facial and trigeminal motor functions like our patient shows.

To our knowledge, our publication is the first description of combined megadolichobasilaris, locked-in syndrome, trismus and frequent yawning in the same patient.

## References

- [1] Plum F, Posner JB. The diagnosis of stupor and coma. Philadelphia: Davis, 1980:377.
- [2] Dumas A. Le comte de Monte-Cristo. Paris: Langenscheidt-Hachette, 1993:1186.
- [3] Patterson JR, Grabis M. Locked-in syndrome: a review of 139 cases. *Stroke* 1980;17:758–64.
- [4] Park SA, Sohn YH, Kim WC. Locked-in syndrome with bilateral peduncular infarct. *J Neuroimaging* 1997;7:126–8.
- [5] Chia LG. Locked-in state with bilateral internal capsule infarcts. *Neurology* 1984;34:1365–7.
- [6] Masuzawa H, Sato J, Kamitani H, Kamikura T, Aoki N. Pontine gliomas causing locked-in syndrome. *Child’s Nerv Syst* 1993;9:256–9.
- [7] Keane JR, Itabashi HH. Locked-in syndrome due to tentorial herniation. *Neurology* 1985;35:1647–9.
- [8] Fitzgerald LF, Simpson RK, Trask T. Locked-in syndrome resulting from cervical spine gunshot wound. *J Trauma* 1997;42:147–9.
- [9] Thadani VM, Rimm DL, Urquhart L, et al. Locked-in syndrome for 27 years following a viral illness: clinical and pathologic finding. *Neurology* 1991;41:498–500.
- [10] Tan AK, Chee MW. Fulminant Guillain–Barre syndrome with quadriplegia and total paresis of motor cranial nerves as a result of segmental demyelination. *J Neurol Sci* 1995;134:203–6.
- [11] D’Andrea F, Maiuri F, Gangemi M, Iaconetta G. Megadolichobasilar anomaly. Clinical and diagnostic considerations on 30 cases. *Acta Neurol* 1992;46:611–9.
- [12] Schoenmaker RT. Locked-in syndrome caused by a megadolicho vascular malformation of the basilar artery. *Clin Neurol Neurosurg* 1984;86:159–62.
- [13] Kobayashi N, Nakagawa Y, Sakugari M, et al. Two cases of giant fusiform aneurysm presenting ischemic attacks. *No Shinkei Geka* 1985;13:919–25.
- [14] Bettioni L, Bortone E, Dascola I, Pavesi G, Lechi A. Unilateral trismus caused by vertebrobasilar dolichoectasia. *Eur Neurol* 1993;33:382–6.
- [15] Jelasik F, Freitag V. Trismus als Symptom motorischer trigeminaler Dyssynergie bei Hirnstammprozessen. *J Neurol* 1975;209:287–96.
- [16] Lai MM, Howard RS. Pseudobulbar palsy associated with trismus. *Postgrad Med J* 1994;70:823–4.
- [17] D’Costa DF, Vania AK, Millac PA. Multiple sclerosis associated with trismus. *Postgrad Med J* 1990;66:853–4.
- [18] Warwick JP, Popat M. Progressive supranuclear palsy: an unusual cause of trismus. *Anaesthesia* 1997;52:1236.
- [19] Alescu C, De Bray JM, Penisson-Besnier I, Pasco-Papon A, Dubas F. Trismus, syndrome pseudobulbaire et thrombose veineuse profonde cerebrale. *Rev Neurol* 2001;157:309–14.
- [20] Winterholler MG, Heckmann JG, Hecht M, Erbguth FJ. Recurrent trismus and stridor in an ALS patient: successful treatment with botulinum toxin. *Neurology* 2002;58:502–3.
- [21] Gschwend J. Gähnen als einziges Verhaltensmuster der Gesichts- und Kiefermuskulatur bei einem Patienten mit Ponsgliom. *Fortschr Neurol Psychiatr Grenzgeb* 1977;45:652–5.
- [22] Wimalaratna HS, Capildeo R. Is yawning a brainstem phenomenon. *Lancet* 1988;1(8580):300.
- [23] Argiolas A, Melis MR. The neuropharmacology of yawning. *Eur J Pharmacol* 1998;343:1–16.
- [24] Alóe F. Yawning. *Arq Neuro-Psiquiatr* 1994;52:273–6.