

◆ CASE REPORT ◆

Transient Ischemic Attack Due to Early Carotid Stent Thrombosis: Successful Rescue With Rheolytic Thrombectomy and Systemic Abciximab

Ruth L. Bush, MD; Jay K. Bhama, MD; Peter H. Lin, MD; and Alan B. Lumsden, MD

Division of Vascular Surgery & Endovascular Therapy, Michael E. DeBakey Department of Surgery, Baylor College of Medicine and The Methodist Hospital, Houston, Texas, USA

◆ ————— ◆
Purpose: To describe a successful neurorescue technique in a patient with generalized seizures followed by hemiparesis immediately after carotid artery stenting (CAS) for a postsurgical restenosis.

Case Report: A 65-year-old man with a symptomatic recurrent high-grade carotid stenosis after carotid endarterectomy was treated with CAS. The procedure was complicated by sudden transient ischemic attack caused by acute carotid stent thrombosis with clot propagation into the cerebral circulation. Percutaneous mechanical thrombectomy was performed with adjunctive infusion of intravenous abciximab, resulting in complete thrombus dissolution and resolution of neurological symptoms.

Conclusions: Access to a mechanical thrombectomy device was essential for rapid thrombus extraction, and adjunctive abciximab aided in residual clot dissolution. As a result of this combined method of clot removal, a disastrous outcome was averted.

J Endovasc Ther 2003;10:870-874

Key words: internal carotid artery, stent, complication, thrombosis, transient ischemic attack, rheolytic thrombectomy, abciximab

◆ ————— ◆
CAS is a safe and effective method of treating both primary and recurrent carotid stenosis, as several large series have demonstrated.¹⁻³ It has emerged as a popular therapeutic alternative that does not carry identical surgical risks of carotid endarterectomy (CEA). However, until more clinical evidence becomes available from prospective trials, CAS presently is restricted to certain indications: namely, severe synchronous carotid and coronary artery disease, prior neck operation or irradiation, postendarterectomy restenosis, high distal lesions, and pre-existing cranial nerve palsy.

Carotid artery thrombosis is an infrequent

but potentially devastating complication of CAS. In this report, we describe a patient in whom a symptomatic recurrent carotid artery stenosis developed <1 year following routine CEA. After successful CAS, acute carotid stent thrombosis occurred. The prompt use of percutaneous rheolytic thrombectomy with adjunctive abciximab infusion effectively restored arterial patency, with reversal of the neurological symptoms.

CASE REPORT

A 68-year-old asymptomatic man with high-grade right internal carotid artery (ICA) ste-

Address for correspondence and reprints: Ruth L. Bush, MD, Michael E. DeBakey Department of Surgery, Baylor College of Medicine, 6550 Fannin, Ste. 1661, Houston, TX 77030 USA. Fax: 1-713-794-7352; E-mail: rbush@bcm.tmc.edu

nosis and an occluded left ICA underwent right eversion carotid endarterectomy under local anesthesia. He had an unremarkable postoperative course and was discharged on aspirin (81 mg/d) therapy. Eight months later, he presented with symptoms of dizziness and transient left-sided weakness. Duplex ultrasonography revealed recurrent right ICA stenosis.

The patient was prepared for carotid artery angioplasty and stenting with clopidogrel (75 mg/d) and aspirin (81 mg/d) administered 3 days prior to the procedure. CAS was performed in a standard surgical operating room using a mobile C-arm unit (Phillips BV Pulsera, New York, NY, USA). On the day of the procedure, intravenous antibiotic (1-g cefazolin) was given 30 minutes before the procedure. Arterial access was via the right common femoral artery. Following the placement of a 6-F introducer sheath (Boston Scientific/Medi-tech, Natick, MA, USA), an aortic arch angiogram was performed in the left anterior oblique projection using a pigtail catheter (Boston Scientific/Medi-tech) with power injection. Selective cannulation of the right common carotid artery (CCA) was performed using a 5-F diagnostic catheter (JB2, Boston Scientific/Medi-tech). Carotid angiography confirmed a high-grade (>90%) restenosis of the right ICA (Fig. 1A).

At this point, intravenous heparin (100 U/kg) was given, and systemic anticoagulation was maintained throughout the procedure. A guidewire exchange was performed, with a 0.035-inch Amplatz Super Stiff guidewire (Boston Scientific/Medi-tech) placed in the CCA without traversing the carotid stenosis. The groin introducer sheath and diagnostic catheter were then removed and replaced by a 7-F, 90-cm Shuttle sheath (Cook Inc., Bloomington, IN, USA) in the distal CCA by tracking over the Amplatz guidewire. Selective digital carotid angiography was performed via the sideport of the sheath to delineate the anatomy of the common, internal, and external carotid arteries. Biplanar intracranial injections were also performed to document the cerebral vasculature. The Amplatz guidewire was then replaced with a 0.018-inch guidewire system with distal embolization device (PercuSurge GuardWire; Medtronic Vascular,

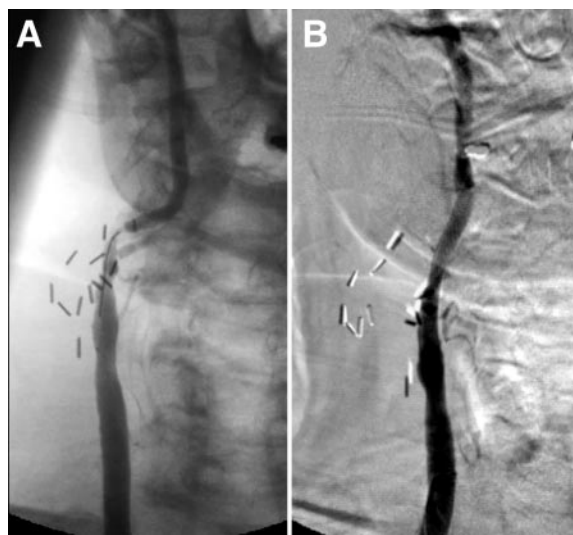


Figure 1 ♦ (A) Preprocedural selective right carotid angiogram. Note the absence of the external carotid artery and the presence of a high-grade stenosis of distal internal carotid artery. (B) Poststent completion study.

Santa Rosa, CA, USA), which was used to cross the ICA lesion. Following activation of the embolization device, a 4×20-mm angioplasty balloon (Boston Scientific/Medi-tech) was used to predilate the carotid lesion. The patient remained neurologically stable during balloon occlusion of the right ICA.

An 8×28-mm self-expanding stent (Dyna-link; Guidant, Indianapolis, IN, USA) was then deployed across the ICA stenosis with proximal attachment in the distal CCA. Poststenting dilation was performed using a 5×20-mm angioplasty balloon (Boston Scientific/Medi-tech). The ICA between the stent and the cerebral embolization protection device was then aspirated to remove any embolic material. Completion angiography, which included biplanar carotid and cerebral views, revealed resolution of the stenosis (Fig. 1B) and excellent flow through the intracranial vessel. All catheters and guidewires were removed, and the groin puncture site was closed with a 6-F Closer Suture Mediated Closure System (Abbott Vascular, Redwood City, CA, USA). The patient tolerated the procedure well and was transferred to the recovery room.

Within 15 minutes after his arrival in the recovery room, the patient became acutely un-

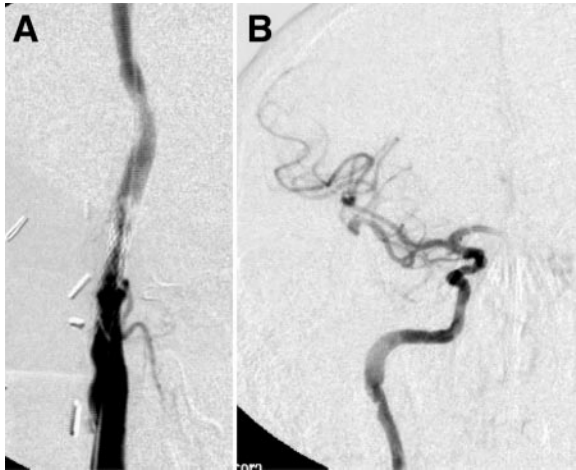

Figure 2 ♦ (A) The filling defects within the ICA stent indicate the presence of acute thrombus. (B) Intracranial angiography demonstrated sluggish flow, multiple filling defects, and very minimal opacification of the anterior cerebral artery.

responsive, hypotensive, and experienced generalized seizures followed by hemiparesis. He was immediately intubated and resuscitated with intravenous fluid, and a dopamine infusion ($5 \mu\text{g}/\text{kg}/\text{min}$) was begun. Bedside duplex ultrasonography of the right ICA revealed in-stent thrombosis with minimal

flow beyond the stent. The patient was taken back to the operating room, where the right common femoral artery was cannulated, and a 6-F introducer sheath (Boston Scientific/Medi-tech) was placed. Carotid angiography (Fig. 2A) showed in-stent nonoccluding thrombus and slow contrast transit within the stent, distal right ICA, and cerebral circulation (Fig. 2B). Percutaneous mechanical thrombectomy (AngioJet Rheolytic Thrombectomy System; Possis Medical Inc., Minneapolis, MN, USA) was performed with a 0.018-inch system (Fig. 3A). Intravenous abciximab (Reopro; Eli Lilly, Indianapolis, IN, USA) was begun during the procedure ($0.25 \text{ mg}/\text{kg}$ bolus over 20 minutes), and the patient was given another bolus of heparin ($100 \text{ U}/\text{kg}$) prior to thrombectomy. Postprocedure angiography (Fig. 3B) revealed brisk flow through the carotid artery stent, distal ICA, and cerebral circulation (Fig. 3C). The groin sheath was removed, and a Closer device was used to achieve groin hemostasis. The patient was transferred to the intensive care unit, where he was extubated at 2 hours. Physical examination at that time revealed grossly intact neurological function except for a mild left arm weakness. Abciximab infusion ($0.125 \mu\text{g}/$

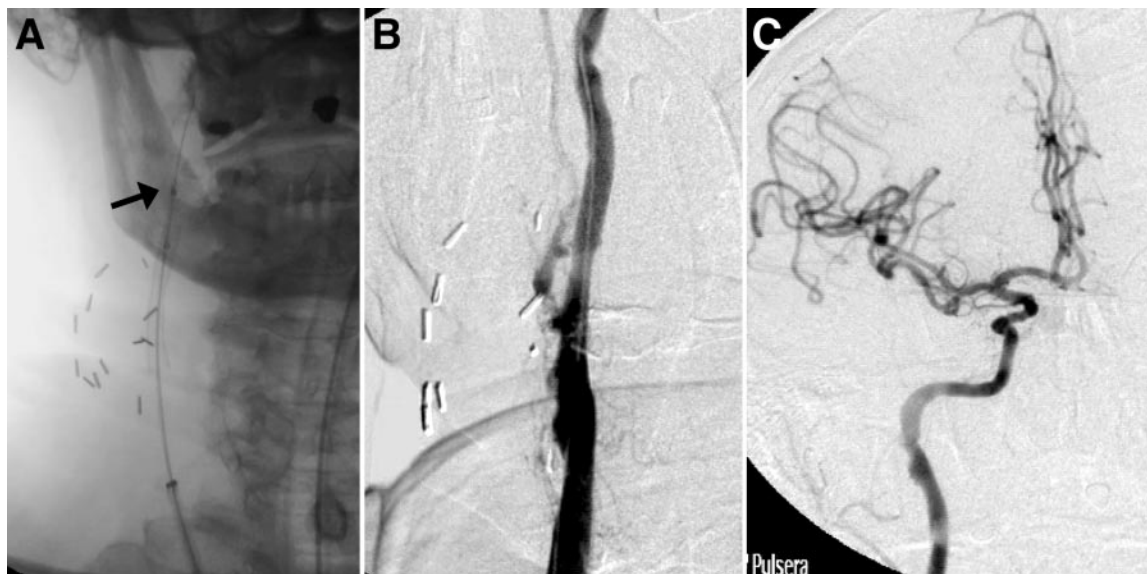

Figure 3 ♦ (A) Distal marker (arrow) indicates the tip of the AngioJet catheter within the ICA beyond the stent. (B) Angiography after mechanical thrombectomy of the ICA stent, with complete thrombus resolution. (C) Complete and brisk filling of both the middle and anterior cerebral arteries after percutaneous mechanical thrombectomy and abciximab bolus.

kg/min) was continued for 12 hours. He was discharged to his home 3 days later; he began outpatient physical therapy 3 times a week. His neurological deficit was completely resolved 2 weeks later. At his 6-month follow-up, the patient had normal velocities on duplex and remained asymptomatic.

DISCUSSION

Following conventional CEA, carotid artery thrombosis is a rare but potentially devastating complication that may be manifested by significant postoperative neurological changes. Traditional treatment of this complication involves urgent return to the operating room for neck exploration. Few reports exist concerning thrombosis after CAS.⁴⁻⁹ To our knowledge, there have been no other reports of acute carotid stent thrombosis treated successfully with combination therapy using percutaneous mechanical thrombectomy and adjunctive intravenous abciximab.

Similar to CEA, postprocedural evidence of cerebral ischemia following CAS should prompt immediate imaging of the carotid artery via color duplex scanning or arteriography to assess ICA patency. The evaluation and treatment of acute thrombosis must be prompt and aggressive. Arteriography offers an opportunity to both localize and document the site of thrombosis or embolism; in addition, percutaneous methods are available for rapid clot extraction.

We chose to perform thrombus removal with a percutaneous rheolytic thrombectomy system because of its efficiency in removing intra-arterial thrombus in occluded lower leg and coronary saphenous vein bypass grafts.^{10,11} The theoretical principle of this device is based on the Venturi effect. Rapidly flowing saline jets (8000 psi) are directed backward from the tip of the device, rather than outward to the vessel wall, to reduce intimal injury. The thrombus is drawn into the vacuum created by these rapidly flowing jets and then out the catheter to a collection bag. We effectively removed the nonoccluding thrombus from within the carotid stent using a 140-cm catheter over a 0.018-inch guide-wire.

To complement thrombectomy, we chose to

intravenously administer abciximab, a monoclonal antibody fragment, as a rescue attempt to dissolve residual clot. As acute thrombus is known to be platelet-rich, abciximab was selected because of its potent platelet-receptor blockade property, which prevents platelet cross-linking and aggregation. Within minutes of thrombectomy with adjuvant abciximab, removal and dissolution of the thrombus was demonstrated via arteriography. Moreover, flow was restored in the entire carotid artery as well as the ipsilateral anterior and middle cerebral circulation. In addition to its thrombolytic properties, abciximab also continues to redistribute itself among circulating platelets for up to 10 days following infusion. Thus, it may prevent platelet adhesion in the immediate period following CAS, when both the stent and adjacent intima are thrombogenic and have platelet-reactive surfaces from intervention.

The use of abciximab as a routine adjunct to CAS has been recommended, albeit with limited experience.^{7,12,13} Two prospective series have found the addition of abciximab to standard heparin therapy to be safe, with no increase in intracranial hemorrhage.^{12,13} Both authors reported a very low risk of ischemic complications and no episodes of stent thrombosis. Though the reports describe only a few patients, perhaps the addition of abciximab may reduce procedurally related neurological events. Furthermore, in a prospective, randomized trial comparing abciximab to placebo for the treatment of ischemic stroke, abciximab was associated with a slight improvement in functional outcome.¹⁴

Additionally, the use of abciximab as a rescue agent has been described for acute thrombotic events in the cerebral circulation.^{6,15} We previously reported a case of transient ischemic attack complicating an intra-arterial thrombin injection of a thoracic aortic pseudoaneurysm, which was successfully rescued with immediate abciximab infusion.¹⁵ The agent effectively dissolved the innominate and carotid artery thrombus, with full resolution of the neurological symptoms. Another similar report also documented the efficacy of immediate systemic abciximab in dissolving thrombus in a complete carotid ar-

tery occlusion secondary to carotid stent thrombosis.⁶

In our patient, systemic infusion of abciximab was a valuable adjunctive pharmacological agent to mechanical thrombectomy. While the thrombectomy device rapidly removed the majority of the thrombus burden within a few seconds, the abciximab may have dissolved any remaining thrombus in the intracranial cerebral circulation. As a result, the contralateral hemiplegia resolved.

In summary, our case underscores the continued therapeutic challenges of CAS procedures. The interventionist performing the procedures must be facile not only with the primary procedure, but also be familiar with neurorescue techniques and have necessary equipment at hand. Despite a technically faultless CAS procedure with full systemic anticoagulation, acute carotid stent thrombosis can occur. Fortunately, in our patient, the complication was identified immediately, allowing rapid re-intervention. Access to a mechanical thrombectomy device was essential in promptly extracting the thrombus, and adjunctive abciximab aided in residual clot dissolution. As a result of this combined method of clot removal, we were fortunate in our patient's outcome.

REFERENCES

1. Shawl F. Carotid artery stenting: acute and long-term results. *Curr Opin Cardiol*. 2002;17:671-676.
2. New G, Roubin GS, Iyer SS, et al. Safety, efficacy, and durability of carotid artery stenting for restenosis following carotid endarterectomy: a multicenter study. *J Endovasc Ther*. 2000;7:345-352.
3. Wholey MH, Wholey M, Mathias K, et al. Global experience in cervical carotid artery stent placement. *Catheter Cardiovasc Interv*. 2000;50:160-167.
4. Bergeron P, Rudondy P, Benichou H, et al. Transluminal angioplasty for recurrent stenosis after carotid endarterectomy. *Int Angiol*. 1993;12:256-259.
5. Ammar AD. Concerns regarding carotid artery angioplasty and stenting. *Stroke*. 1996;27:2143-2144.
6. Tong FC, Cloft HJ, Joseph GJ, et al. Abciximab rescue in acute carotid stent thrombosis. *AJNR Am J Neuroradiol*. 2000;21:1750-1752.
7. Schneiderman J, Morag B, Gerniak A, et al. Abciximab in carotid stenting for postsurgical carotid restenosis: intermediate results. *J Endovasc Ther*. 2000;7:263-272.
8. Chaturvedi S, Sohrab S, Tselis A. Carotid stent thrombosis: report of 2 fatal cases. *Stroke*. 2001;32:2700-2702.
9. Hamann GF, Liebetrau M, Pfefferkorn T, et al. Successful systemic thrombolysis for carotid stent thrombosis. *Eur Neurol*. 2002;48:37-39.
10. Kasirajan K, Gray B, Beavers F, et al. Rheolytic thrombectomy in the management of acute and subacute limb-threatening ischemia. *J Vasc Interv Radiol*. 2001;12:413-421.
11. Silva JA, White CJ, Ramee SR, et al. Treatment of coronary stent thrombosis with rheolytic thrombectomy: results from a multicenter experience. *Catheter Cardiovasc Interv*. 2003;58:11-17.
12. Bhatt DL, Kapadia SR, Bajzer CT, et al. Dual antiplatelet therapy with clopidogrel and aspirin after carotid artery stenting. *J Invasive Cardiol*. 2001;13:767-771.
13. Kapadia SR, Bajzer CT, Ziada KM, et al. Initial experience of platelet glycoprotein IIb/IIIa inhibition with abciximab during carotid stenting: a safe and effective adjunctive therapy. *Stroke*. 2001;32:2328-2332.
14. Abciximab in acute ischemic stroke: a randomized, double-blind, placebo-controlled, dose-escalation study. The Abciximab in Ischemic Stroke Investigators. *Stroke*. 2000;31:601-609.
15. Lin PH, Bush RL, Tong FC, et al. Intra-arterial thrombin injection of an ascending aortic pseudoaneurysm complicated by transient ischemic attack and rescued with systemic abciximab. *J Vasc Surg*. 2001;34:939-942.