



ELSEVIER

www.elsevierhealth.com/journals/jinf

Cerebral venous and dural sinus thrombosis in severe falciparum malaria

A. Krishnan^a, D.R. Karnad^{a,*}, U. Limaye^b, W. Siddharth^b

^aMedical Neurology Neurosurgery Intensive Care Unit, Department of Medicine, King Edward Memorial Hospital, Parel, Mumbai 400 012, India

^bDepartment of Radiology, King Edward Memorial Hospital, Parel, Mumbai 400 012, India

Accepted 1 July 2003

KEYWORDS

Plasmodium falciparum;
Cerebral malaria;
Cortical venous
thrombosis; Superior
sagittal sinus;
Coagulation;
Hypercoagulable state;
Cerebral infarction;
Cerebral haemorrhage

Summary Common causes of coma in falciparum malaria are cerebral malaria, hypoglycaemia and electrolyte disturbances. Focal deficits due to arterial infarcts may sometimes occur in children, but are rare in adults. Three adults with falciparum malaria who had fever, altered consciousness and focal neurological deficits (one of whom also had seizures) are being reported here. CT scan of the brain revealed haemorrhagic infarction of the cerebral cortex and subcortical white matter with surrounding oedema suggestive of venous infarction in all three patients. The diagnosis of cerebral venous thrombosis was missed in the first patient, and was detected only at autopsy. In the next two patients, superior sagittal sinus thrombosis was confirmed angiographically. Only one patient survived; the other two died of increased intracranial pressure. Two of the three patients also had *Plasmodium vivax* co-infection. A hypercoagulable state resulting from severe malaria may be responsible for this rare and potentially fatal complication. Cerebral malaria may be associated with raised intracranial pressure due to cerebral oedema. Cerebral venous thrombosis may worsen this and adversely affect outcome. This diagnosis should be suspected in patients with severe malaria who develop focal neurological deficits and confirmed by appropriate imaging; judicious use of local thrombolytic therapy may help improve outcome.

© 2003 The British Infection Society. Published by Elsevier Ltd. All rights reserved.

Cerebral venous and dural sinus thrombosis in severe falciparum malaria

Cerebral venous thrombosis can complicate several intracranial infections like bacterial meningitis, subdural empyema and suppurative otitis media.¹ It may also occur in conditions that increase blood viscosity like dehydration, polycythaemia vera and thrombocytosis.¹ Hypercoagulable states like antithrombin III, protein C or protein S deficiency

may be present in some patients with cerebral venous thrombosis.¹ In women, it may also complicate the course of pregnancy or puerperium.¹

A hypercoagulable state has been demonstrated in patients with falciparum malaria.^{2–8} Excess activation of platelets and the coagulation cascade may give rise to disseminated intravascular coagulation or thrombocytopenia. Studies on brain imaging in cerebral malaria have shown cerebral oedema, bithalamic and cerebellar hypodensities, small areas of haemorrhagic cortical infarcts and diffuse white matter changes.^{9–11} However, intracranial venous thrombosis has not been reported in

*Corresponding author.

E-mail address: karnad@vsnl.net

patients with malaria. Of the 497 patients with severe falciparum malaria admitted to the medical intensive care unit during a 3-year period; three patients had cortical venous thrombosis and are reported in this paper.

Case 1

A 45-year-old man was admitted to another hospital for intermittent fever with chills and rigors. Peripheral blood smear showed trophozoites of *Plasmodium vivax*. He was treated with oral chloroquine but continued to remain febrile. Two days later he developed sudden onset of unconsciousness and left hemiparesis for which he was transferred to our hospital. On admission he was febrile, had mild splenomegaly and was unconscious (Glasgow Coma Scale (GCS) = 6) with dense left hemiplegia. Deep tendon reflexes were absent in the left limbs and the left plantar reflex was extensor. Laboratory tests revealed a haematocrit of 32%, total leukocyte count of $5.6 \times 10^9/L$ and platelet count was $1.81 \times 10^9/L$. Peripheral blood smear revealed mixed infection with *P. vivax* as well as *Plasmodium falciparum*. BUN was 18 mg% and serum electrolytes, prothrombin time (PT) and activated partial thromboplastin time (aPTT) were normal. CT scan revealed a haematoma in the right parietal lobe with surrounding oedema, midline shift and subfalcine herniation (Fig. 1(A)). Central venous pressure (CVP) was recorded to be 4–6 cm of water. Intravenous quinine was administered and mannitol was also added in view of raised intracranial pressure. His consciousness deteriorated progressively to GCS 3, and he developed signs of transtentorial herniation; neurosurgical evacuation of the clot was done. After initial transient improvement he worsened and died of brainstem dysfunction due to raised intracranial pressure 6 h later. Post-mortem examination revealed extensive thrombosis of the cerebral cortical veins, posterior part of the superior sagittal sinus (SSS) and the superficial cerebral veins with haemorrhagic infarction of the right parietal lobe. This diagnosis was missed ante mortem.

Case 2

This 48-year-old male had intermittent high grade fever since 2 days and three episodes of left focal to secondary generalized seizures followed by unconsciousness 2 h before admission. On examination, GCS was 6 and he had left hemiplegia with left

upper motor neuron facial palsy. The haematocrit was 40%, total leukocyte count $8.7 \times 10^9/L$ and the platelet count was $0.8 \times 10^9/L$. PT, aPTT and blood glucose levels were normal. Peripheral blood smear showed trophozoites of *P. falciparum* with a parasitic index of 2%. BUN was 12 mg%, uric acid 4.0 mg% and electrolytes were within normal range. CVP on admission was 6–8 cm of water. Intravenous quinine was started. CT scan showed right frontal haemorrhagic infarction and absence of contrast in the posterior end of the SSS (Fig. 1(B)). Digital subtraction angiography (DSA) confirmed thrombosis of the SSS along its entire extent (Fig. 2). Transcatheter thrombolytic therapy was initiated with urokinase. This was continued for 36 h, followed by anticoagulation with heparin. He gradually improved and 4 days later GCS was 13 and power in left limbs was grade 2/5. A repeat DSA showed recanalisation of almost the entire SSS except a small segment in the middle third. He was discharged after 17 days in hospital on oral anticoagulation. One year later, there was mild stiffness in the left side of the body and the CT scan showed gliotic changes in the right frontal area.

Case 3

This 35-year-old man was treated for mixed infection with *P. vivax* and *P. falciparum* with oral chloroquine and intramuscular artesunate. He became afebrile with this treatment but 48 h later he became drowsy and developed right hemiparesis. On examination, vital signs were normal. Power in the right upper limb was grade 3/5 and grade 4/5 in the right lower limb with upper motor neuron right facial paresis. The haematocrit was 45% with normal platelet and leukocyte counts, PT and aPTT. Blood urea nitrogen was 14 mg% and electrolytes normal. CT scan showed haemorrhagic infarction in the left frontoparietal region with surrounding oedema. DSA showed extensive thrombosis of the SSS and transverse sinus. However, as an angiography catheter could not be negotiated to the site of thrombosis, local thrombolysis was not feasible. Intravenous quinine and mannitol were given, but the patient developed progressive signs of transtentorial herniation with brainstem dysfunction and died 24 h after the onset of focal deficits.

Discussion

Activation of the intrinsic coagulation cascade

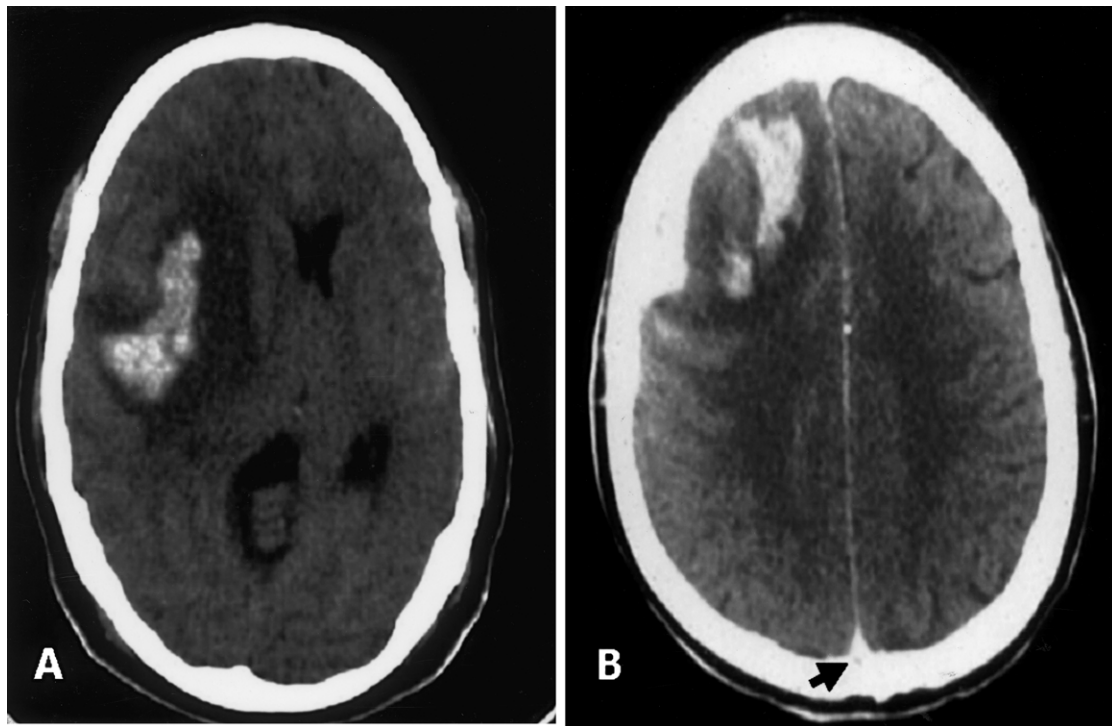


Figure 1 Non-enhanced CT scan of the brain of patient 1 (Panel A) showing a large right temporoparietal haemorrhagic infarct with surrounding cerebral oedema, midline shift and brain stem compression. Contrast enhanced CT scan (brain) of patient 2 (Panel B) showing a large area of hemorrhagic infarction in the right frontoparietal cortex with surrounding oedema. Absence of contrast is seen as a hypodense area in the posterior aspect of the superior sagittal sinus—the 'empty delta' sign (arrow).

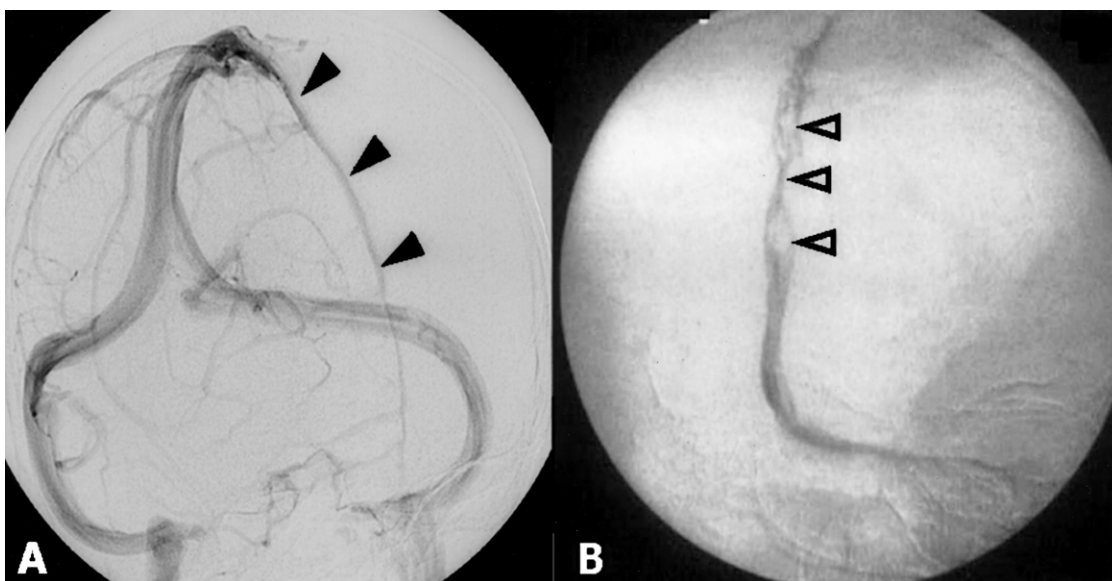


Figure 2 Venous phase of digital subtraction angiogram in right anterior oblique view. Note the normal filling of the entire length of the superior sagittal sinus (solid arrowheads) in Panel A. The angiogram of patient 2 (Panel B) showing absence of opacification of the anterior portion of the superior sagittal sinus (SSS) and multiple irregular filling defects (open arrowheads) in the posterior part of the SSS. The superficial cerebral veins that drain the anterior part of the SSS too are not opacified unlike the posterior veins that are clearly seen.

may occur in falciparum malaria as a result of endothelial damage resulting from adhesion of parasitized RBCs and marginated mononuclear cells to the walls of capillaries and venules.^{2,3} Release of tissue factor from monocytes and changes in the lipid structure of the cell membrane of infected erythrocytes activate the extrinsic coagulation pathway as well.⁴⁻⁶ Simultaneously, there is activation of the antithrombotic systems with increased levels of circulating thrombin-antithrombin III complexes.^{2,4,7,8,12} Ultimately, there is depletion of antithrombotic plasma proteins like antithrombin III, protein C and protein S while levels of fibrinogen and other clotting factors may remain unchanged.^{4,7,8} Circulating levels of fibrin degradation products, fibrinopeptide-A and D-dimer are increased in many patients with severe malaria due to fibrinolytic activity^{4,14,15} which may explain why fibrin clots are demonstrable in only some but not all patients dying of cerebral malaria.^{15,16} A recent study has shown that tissue plasminogen activator in blood is severely depleted while plasminogen activator inhibitor (PAI-1) level is increased with increasing severity of malaria.⁴ The net effect of these abnormalities is a hypercoagulable state, which manifests as disseminated intravascular coagulation in 16–26% of patients with severe falciparum malaria, although overt bleeding is seen in only 5% of patients.¹³ Thrombocytopenia due to intravascular platelet activation too may add to the capillary clogging as well as to the bleeding diathesis.^{2,17} While several studies have demonstrated that coagulopathy increases in parallel with the severity of *P. falciparum* infection,² coagulation disturbances are extremely rare in vivax malaria.^{4,18,19} Hence, the significance of *P. vivax* co-infection in two of our three patients is unclear.

While microvascular thrombosis in the cerebral capillaries and venules is an important mechanism of neurological affection in cerebral malaria,^{3,20} thrombosis in larger vessels is rare. Brewster et al.²¹ found cerebral infarction due to arterial occlusion in five out of 11 African children with severe malaria. Obama et al.²² found that cerebral malaria was responsible for 14% of all strokes in children in Cameroon. Seven patients with gangrene of the extremities and digits have been reported to date, one of whom was successfully treated with thrombolytic therapy.²³⁻²⁵ However, intracranial venous thrombosis has not been reported before. It is not clear as to why thrombosis should occur in the intracerebral venous system. During the later phases of the lifecycle of *P. falciparum*, adhesion of parasitized RBCs to capillary and post-capillary venular endothelium seems to be essential.^{19,20} This sequestration of RBCs is maximum in the brain

and MacPherson et al.²⁶ have shown that 45% of RBCs in the smaller cerebral vessels are parasitized compared to 4–19% in other organs. It is therefore possible that the resulting derangement of coagulation may be most pronounced in cerebral venules and could result in spontaneous thrombosis in the veins and dural sinuses, which drain these vascular beds. Further studies are needed to investigate this hypothesis.

Thus, cerebral venous and dural sinus thrombosis may rarely complicate the course of severe falciparum malaria. As the hypercoagulable state can persist for 7–10 days after initiation of antimalarial therapy⁴ venous thrombosis could occur even after clearance of parasitaemia (as in our patient 3). The major cause of convulsions and coma in patients with falciparum infection is cerebral malaria itself.²⁷ Hypoglycaemia, which occurs in 20–32% of patients with severe malaria, may also cause coma and seizures.^{15,16} However, neither of these causes focal neurological deficits. Cerebral venous and dural sinus thrombosis should be suspected if a focal neurological deficit develops in a patient with cerebral malaria and the CT scan reveals haemorrhagic cerebral infarction. The diagnosis was missed in Patient 1. However, past experience led to prompt diagnosis in patients 2 and 3. Intracranial venous thrombosis may substantially increase mortality in cerebral malaria by further increasing intracranial pressure due mass effect caused by parenchymal haemorrhage and perilesional oedema as well as by impeding the venous drainage.

Acknowledgements

The authors are grateful to Dr Tufail Patankar for providing imaging and clinical details of patient 1.

References

1. Enevoldson TP, Russel RW. Cerebral venous thrombosis. New causes for an old syndrome? *Q J Med* 1990;**77**:1255–1275.
2. Ghosh K. Abnormalities in haemostasis caused by falciparum malaria. *Platelets* 1992;**3**:307–310.
3. Patnaik JK, Das BS, Mishra SK, Mohanty S, Satpathy SK, Mohanty D. Vascular clogging, mononuclear cell margination and enhanced vascular permeability in the pathogenesis of cerebral edema. *Am J Trop Med Hyg* 1994;**51**(5):642–647.
4. Mohanty D, Ghosh K, Nandwani SK, et al. Fibrinolysis, inhibitors of blood coagulation and monocyte derived coagulant activity in acute malaria. *Am J Hematol* 1997;**54**:23–29.
5. Mohanty D, Marwaha N, Ghosh K, et al. Vascular occlusion and disseminated intravascular coagulation in falciparum malaria. *Br Med J* 1985;**290**:115–116.
6. Penrod G, Polack B, Peyron F, et al. Monocyte tissue factor

- expression induced by *Plasmodium falciparum*-infected erythrocytes. *Thromb Hemost* 1992;**68**(2):111–114.
7. Clemens R, Pramoolsinsap C, Lorenz R, Pukrittayakamee S, Bock HL, White NJ. Activation of the coagulation cascade in severe falciparum malaria through the intrinsic pathway. *Br J Hematol* 1994;**87**:100–105.
 8. Hemmer CJ, Kern P, Holst FG, et al. Activation of the host response in human *Plasmodium falciparum* malaria. Relation of parasitemia to tumor necrosis factor/cachectin, thrombin–antithrombin III and protein C levels. *Am J Med* 1991;**91**:37–44.
 9. Cordoliani YS, Sarrazin JL, Felten D, Caumes E, Leveque C, Fisch A. MR of cerebral malaria. *Am J Neuroradiol* 1998;**19**: 871–874.
 10. Patankar T, Karnad DR, Shetty PG, Desai AP, Prasad SR. Adult cerebral malaria: prognostic importance of radiologic findings and correlation with post mortem findings. *Radiology* 2002;**224**(3):811–816.
 11. Pham-Hung G, Truffert A, Delvallee G, Michel G, Laporte JP, Duval G. Cerebral infarction in pernicious malaria. Diagnostic value of computed tomography. *Ann Fr Anesth Reanim* 1990;**9**(2):185–187.
 12. Pukrittayakamee S, White NJ, Clemens R, et al. Activation of the coagulation cascade in falciparum malaria. *Trans R Soc Trop Med Hyg* 1989;**83**:762–766.
 13. Jimmy EQ, Saliu I, Okpala I, et al. Effect of *Plasmodium falciparum* malaria on plasma fibrinogen A concentration. *Cent Afr J Med* 1995;**41**:124–127.
 14. Phillips RE, Looaresuwan S, Warrell DA, et al. The importance of anaemia in cerebral and uncomplicated falciparum malaria: role of complications, dyserythropoiesis and iron sequestration. *Q J Med* 1986;**58**:305–323.
 15. World Health Organisation, Severe and complicated malaria. *Trans R Soc Trop Med Hyg* 1990;**84**(Suppl. 2):1–65.
 16. Bradley D, Newbold CI, Warrell DA. Malaria. In: Weatherall DJ, Ledingham JGG, Warrell DA, editors. *Oxford Textbook of Medicine*, 3rd edn. New York: Oxford University Press; 1996. p. 835–863.
 17. Lee SH, Looaresuwan S, Chan J, et al. Plasma macrophage colony-stimulating factor and P-selectin levels in malaria-associated thrombocytopenia. *Thromb Haemost* 1997;**77**: 289–293.
 18. Lakhar BB, Babu S, Shenoy V. DIC in vivax malaria. *Indian Pediatr* 1996;**33**:971–972.
 19. Islam N, Qamruddin K. Unusual complications in benign tertian malaria. *Trop Geogr Med* 1995;**47**:141–143.
 20. SenGupta SK, Naraqi S. The brain in cerebral malaria: a pathological study of 24 fatal cases in Papua New Guinea. *PN G Med J* 1992;**35**(4):270–274.
 21. Brewster DR, Kwiatkowski D, White NJ. Neurological sequelae of cerebral malaria in children. *Lancet* 1990;**336**: 1039–1043.
 22. Obama MA, Dongmo L, Nkemayim C, Mbede J, Hagbe P. Stroke in children in Yaounde, Cameroon. *Indian Pediatr* 1994;**31**:791–795.
 23. Edwards IR. Malaria with disseminated intravascular coagulation and peripheral tissue necrosis successfully treated with streptokinase. *Br Med J* 1980;**280**:1252–1253.
 24. Anuradha S, Prabhash K, Shome DK, et al. Symmetric peripheral gangrene and falciparum malaria—an interesting association. *J Assoc Physicians India* 1999;**47**:733–735.
 25. Chittichai P, Chierakul N, Davis TM. Peripheral gangrene in nonfatal pediatric cerebral malaria: a report of two cases. *Southeast Asian J Trop Med Public Health* 1991;**22**:190–194.
 26. MacPherson GG, Warrell MJ, White NJ, Looaresuwan S, Warrell DA. Human cerebral malaria: a quantitative ultrastructural analysis of parasitized erythrocyte sequestration. *Am J Pathol* 1985;**119**(3):385–401.
 27. Newton CR, Hien TT, White N. Cerebral malaria. *J Neurol Neurosurg Psychiatry* 2000;**69**:433–441.