



## Dystonia in AIDS: Report of Four Cases

Stewart A. Factor, DO,<sup>1\*</sup> Michelle Troche-Panetto, MD,<sup>2</sup> and Susan A. Weaver, MD<sup>1</sup>

<sup>1</sup>Albany Medical Center, Department of Neurology, Albany, New York, USA

<sup>2</sup>Albany Medical Center, Department of Psychiatry, Albany, New York, USA

**Abstract:** Dystonia is a rare complication of acquired immune deficiency syndrome (AIDS). We report four such cases related to three different causes. Cases 1 and 2 both developed dystonia secondary to biopsy-proven progressive multifocal leukoencephalopathy. One had left arm dystonia, whereas the other had bilateral upper limb dystonia. One patient had associated akinesia and rigidity. Imaging demonstrated frontal and/or parietal white matter lesions but no basal ganglia abnormalities. Case 3 developed hemidystonia and cervical dystonia from biopsy-proven toxoplasmosis with a lesion in the thalamus. Case 4

suffered from AIDS dementia complex and developed cervical dystonia while taking risperidone therapy. We also review previously reported cases of dystonia in AIDS patients with the same causes and discuss the issue of increased vulnerability of the basal ganglia to HIV infection which, in turn, leads to increased sensitivity to neuroleptics. When dystonia is seen in AIDS patients, its pattern may be a clue to the ultimate cause. © 2003 Movement Disorder Society

**Key words:** dystonia, AIDS, toxoplasmosis; progressive multifocal leukoencephalopathy; neuroleptics

Neurological symptoms are common in patients with acquired immunodeficiency syndrome (AIDS), although less so than in the 1980s because of antiretroviral therapy. Small portions of these symptoms consist of movement disorders. The types of movement disorders commonly reported include hemiballism, chorea, tremor, and parkinsonism, which may be associated with primary or secondary (opportunistic) infection.<sup>1</sup> Dystonia has only rarely been reported. Here, we present four cases that were seen at our institution over the past decade resulting from three different causes.

### CASE 1

The patient was a 34-year-old man diagnosed with HIV infection in 1990. He was apparently well until February 1995 when he developed *Pneumocystis carinii* pneumonia. In March 1995, he noted the onset of weak-

ness and incoordination of his left arm followed by episodes of numbness and “spasms” marching up the left arm. A magnetic resonance imaging (MRI) scan revealed a nonenhancing lesion in the right frontal premotor subcortical white matter (Fig. 1). A brain biopsy performed in June 1995 revealed progressive multifocal leukoencephalopathy (PML). He received therapy for PML with Ara-C and antiretroviral agents, and some improvement in his symptoms was noted.

He was examined neurologically in April 1996, and findings included increased tone in the left upper extremity associated with dystonic posturing. The fingers and thumb were held flexed, and he had little control of their movements. The fingers could be passively opened, indicating a lack of contracture. His arm was internally rotated. There also was mild weakness of the left arm, hyperreflexia on the left side, but down-going toes. Episodic clonic spasms of the left side with elevation and external rotation of the left arm and elevation of the left leg were observed (see Videotape, Segment 1).

Dystonia was treated with baclofen, trihexyphenidyl, and clonazepam but was unresponsive. Subsequently, the spasms were diagnosed as left focal motor seizures, documented by electroencephalogram. Follow-up exam-

A videotape accompanies this article.

\*Correspondence to: Stewart A. Factor, DO, Parkinson's Disease and Movement Disorders Center of Albany Medical Center, 215 Washington Ave Ext, Albany, NY 12205. E-mail: factors@mail.amc.edu

Received 10 January 2003; Revised 22 April 2003; Accepted 10 June 2003

DOI 10.1002/mds.10602

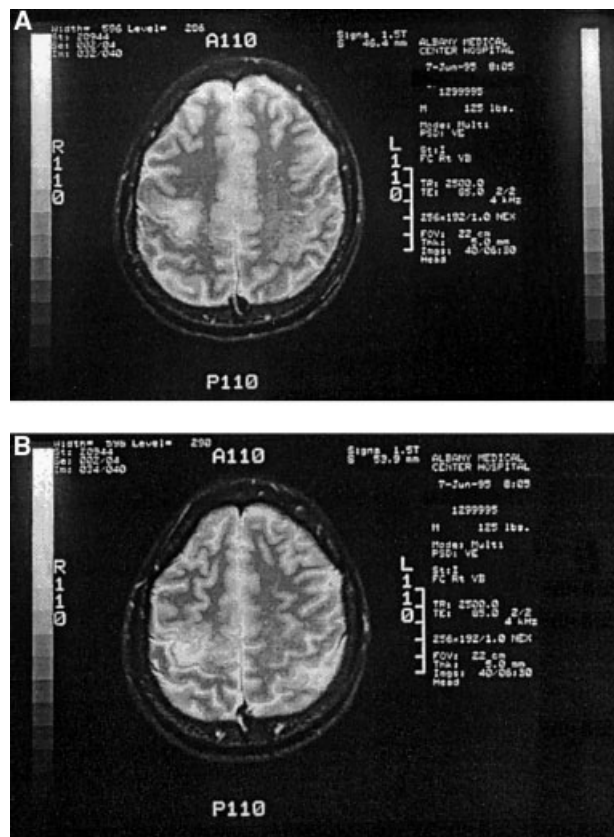


FIG. 1. Magnetic resonance scan from Patient 1 demonstrates a non-enhancing lesion in the right frontal premotor subcortical white matter.

ination at 15 months revealed stable PML but continuing seizures and dystonia.

### CASE 2

The patient was a 43-year-old man diagnosed with HIV infection in 1989. He developed thoracic herpes zoster and oral candidiasis in May 1995. In December 1995, he was observed to have slurred speech, swallowing difficulties, incoordination of arm movements, and unsteady gait.

Physical examination revealed masked, astonished facial expression, saccadic pursuits, and dysphagia. Speech had qualities of dysarthria and pseudobulbar speech. His neck was shifted anteriorly and held flexed. He had bilateral upper limb dystonia, left worse than right. He also manifested bilateral limb rigidity, moderate to severe bradykinesia, hyperreflexia, akinetic and ataxic gait, stooping of his posture, and postural instability (see Videotape, Segment 2).

MRI scan revealed bilateral nonenhancing lesions in the deep frontal and parietal–occipital white matter (Fig.

2) and cerebellar white matter change was also seen. A brain biopsy performed in February 1996 revealed PML. Treatment for PML was started with Ara-C and antiretrovirals, but due to progressive dysphagia and aspiration, it was discontinued. The dystonia persisted until his death 6 months after diagnosis (July 1996).

### CASE 3

The patient was a 44-year-old man diagnosed with HIV infection in February 1988. He presented in February 1991 with a 3-day history of fever (40°C), gait difficulty, mental status changes, and agitation followed by unresponsiveness. A head computed tomography (CT) scan performed 2 days earlier at another hospital was reportedly negative. He also was anemic, had oral thrush, and chronic hepatitis. In the past, he had been

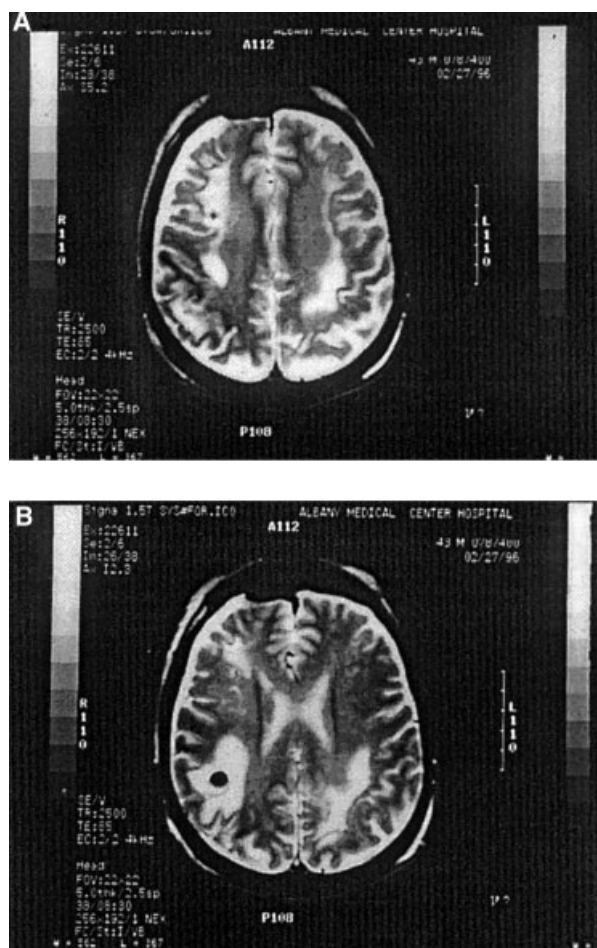


FIG. 2. Magnetic resonance scan of Patient 2 demonstrates bilateral nonenhancing lesions in the deep frontal and parietal–occipital white matter.

treated with AZT and had no prior AIDS defining illnesses.

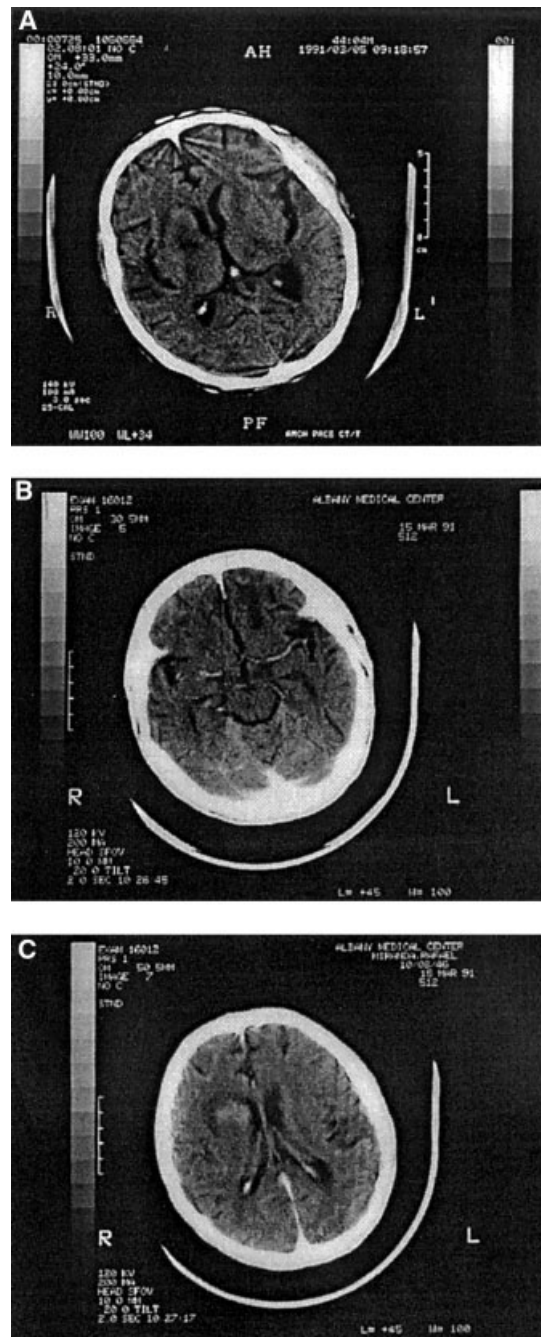
On physical examination he was in stupor, had right CN-III palsy, papilledema, and nuchal and extremity rigidity. CT scan revealed a nonenhancing mass lesion in the right caudate nucleus, left thalamus, and left frontal lobe (Fig. 3), initially with a midline shift. Treatment was started with dexamethasone, pyrimethamine, and sulfadiazine.

Days 3 to 8 after admission, he started to open his eyes and follow commands. On day 10, his muscle tone was increased in all extremities and had bilateral Babinski signs. The next day he showed upper extremity tremor at rest. On day 12, a follow-up neurological exam demonstrated CN III palsy, myoclonus, right-turning cervical dystonia with head tremor, and hypertrophy of the left sternocleidomastoid, right hemidystonia, right hemiparesis, and increased tone bilaterally (see Videotape, Segment 3).

A brain biopsy of the right caudate on day 19 was performed and revealed toxoplasmosis. Treatment with the above-noted medications was continued with no improvement of the dystonia after approximately 1 month. He was discharged after 1 month and not seen in follow-up.

#### CASE 4

The patient was a 40-year-old woman with an 8-year history of HIV infection and a CD4 count of 81 in August 1997. Her AIDS was associated with recent AIDS dementia complex, hepatitis C, oral thrush, and recurrent trichomonas infection. In addition, she had a history of presumed cerebral toxoplasmosis, which led to admission in June 1997 with complaints of headache, nausea, and vomiting lasting 3 weeks followed by gait difficulty. Examination at that time revealed a mild left hemiparesis and wide-based gait. No involuntary movements were reported. A CT scan from the other hospital demonstrated a right-sided mass lesion with surrounding edema. She was treated with pyrimethamine, sulfadiazine, and dexamethasone with notable improvement. A repeat CT scan before discharge demonstrated a 2-cm lesion in the right basal ganglia with residual edema but significant shrinkage of the mass and improvement of the mass effect. Diagnosis of toxoplasmosis was presumed based on the nature of the lesion in the imaging, response to appropriate medications, and elevated toxo IgG. Other past medical problems included bipolar disorder, anemia, and cholestatic liver disease. Repeat MRI of the head 7 weeks later during another hospitalization showed no



**FIG. 3.** Computed tomography scan of Patient 3 demonstrates initially a nonenhancing mass lesion in the right caudate nucleus (a) and left thalamus (a) and 10 days later left frontal lobe (b) with a hemorrhagic mass in the right caudate nucleus c (the region that was ultimately biopsied).

change in her old toxoplasmosis lesion but also showed severe cerebral atrophy.

She was readmitted again 6 weeks later for gastrointestinal symptoms and worsening encephalopathy. Her

medications on admission included risperidone 2 mg t.i.d. She had been on 3 mg t.i.d. as recently as a few weeks before and had been on the drug "off and on" for approximately 5 months for psychotic symptoms associated with AIDS dementia complex. There was a history of noncompliance. Other medications included fluoxetine, bupropion, diazepam, and pyrimethamine maintenance. She was not on antiretroviral agents. In October, she developed left neck pain and rotation of the head to the right. Risperidone was reduced to 2 mg b.i.d. and benztropine was added 2 mg b.i.d., but this treatment had no effect. A repeat MRI imaging study was unchanged. A neurology consultation was performed 3 days later. Examination demonstrated a severely ill, cachectic woman who had limited speech output but was not aphasic. She was clearly encephalopathic. Regarding cranial nerves, she had right central facial weakness, moderate torticollis to the right with some laterocollis left, and hypertrophy of the left sternocleidomastoid muscle. She had limited range of motion with attempting to turn to the left (see Videotape, Segment 4). On motor examination she had a left hemiparesis and bilateral leg muscle atrophy and weakness from a peripheral neuropathy. Her reflexes were absent in the lower extremities but had bilateral clonus. Plantar reflexes were downgoing, and she had no apparent ataxia. She could not walk. It was believed that the dystonia was neuroleptic-induced, and the risperidone was discontinued. When seen again in 3 days, there was no change in status. Within the next few weeks, she developed orofacial dyskinesia and died November 1997.

### DISCUSSION

These cases indicate that, although dystonia is a rare manifestation of AIDS, it can occur as the result of several causes. Lesions in the putamen, caudate, or thalamus are usually implicated in the presentation of symptomatic dystonia.<sup>2</sup> Keeping this in mind, one would expect that toxoplasmosis would be the most likely cause of this movement disorder, because it is common in AIDS, occurring in approximately 30% of patients, and because of its predilection for these deep brain regions.<sup>3</sup> While we report such a case, it is clear that primary HIV infection in conjunction with neuroleptic therapy and PML are other possibilities. The dystonia seen in these disorders has a different pattern, and this pattern might represent a clue for the underlying diagnosis.

Patients 1 and 2 had biopsy-proven PML. PML is a common opportunistic infection of JC virus and is seen in approximately 5% of AIDS patients<sup>4</sup> as well as others with immune compromise.<sup>5</sup> The infection attacks the

oligodendroglia, causing white matter lesions with intact axons. The clinical symptoms depend on the location of the lesion but most commonly include cognitive symptoms, focal, segmental or hemiweakness, and visual deficits due to the parieto-occipital lesions that occur. Extraparallel disease, including parkinsonism and dystonia, do occur but are rare. Whereas a figure of 1 to 2% exists for parkinsonism,<sup>6,7</sup> there are no estimates for dystonia. The prognosis despite symptomatic treatment is poor, with greater than 80% of patients dying within 1 year.<sup>4</sup> Diagnosis requires brain biopsy.

One of our patients with PML had bilateral upper limb dystonia combined with akinetic rigid symptoms and the other had unilateral limb dystonia. Similar phenomena have been described in several previous case reports. Singer and colleagues<sup>8</sup> reported a 13-year-old girl with AIDS and PML who had a rapidly progressive akinetic rigid syndrome, including postural instability, associated with dystonic facial grimacing. She died after 10 months. de Toffol and coworkers<sup>9</sup> described a 31-year-old man who presented with an akinetic rigid syndrome and, after 7 months, developed upper limb dystonia (bilateral and asymmetric), myoclonus, and apraxia (unilateral). This finding was followed by postural instability and alien limb, and he ultimately died after 13 months. Two other cases of dystonia without akinesia have also been reported. One case developed left hemiparesis and foot dystonia,<sup>10</sup> and the other case demonstrated right hyperreflexia and intermittent hemidystonia.<sup>11</sup> These patients died after 6 and 12 weeks, respectively. There have been three other cases of PML-related dystonia in patients who did not have AIDS. One patient had leukemia and was immune-suppressed from his chemotherapy. He presented with upper limb hypokinesia but no rigidity and progressed over 10 months to have unilateral rest tremor, head tremor, bilateral hypokinesia, apraxia, freezing gait, and facial and right arm dystonia.<sup>7</sup> The other 2 patients were not immune-suppressed (so-called primary PML). One had a 5-year history of parkinsonism with all the cardinal features, including freezing gait and memory impairment before developing dystonia of the left foot. With progression, she developed cognitive decline, including psychosis, apraxia, and generalized dystonia and died after 10 years of illness (unusual for the length of survival for PML).<sup>6</sup> The last case was a 24-year-old woman who presented with myoclonic jerks and several months later developed tremor and dystonia of the left hand. Weakness came 4 months later, and she died after 1 year of further progression.<sup>5</sup> In some cases, the movement disorder was the presenting feature of PML,<sup>5,7,8</sup> whereas others had the symptoms come on later. The

combination of parkinsonism, dystonia, myoclonus, and apraxia are reminiscent of corticobasal ganglionic degeneration, and the diagnosis was entertained in some, but the course is generally too fast. However, that combination of features should make one consider the diagnosis of PML.

The dystonia occurred in some of these patients because of basal ganglia infiltration of the JC virus, and this infiltration was demonstrated by MRI and postmortem evaluation.<sup>4,8,10,11</sup> However, several cases demonstrated no lesions in this region by pathological examination,<sup>6,9</sup> indicating that this finding is not required but makes it difficult to explain the presence of dystonia. One had parietal lesions and the other had frontal, temporal, and occipital lesions, including the cortical gray matter. Our patients did not have basal ganglia involvement by MRI scan; however, they did have extensive white matter lesions in the frontal, parietal, temporal, and occipital regions. Without confirmation by postmortem examination, we will not know definitively if the JC virus spread to the deep gray matter, but dystonia apparently can occur in either case.

Our third patient had right-turning cervical dystonia and right hemidystonia secondary to biopsy proven toxoplasmosis. This finding was probably secondary to the left thalamic lesion, but he also had left frontal and right caudate nucleus lesions on CT scan. Toxoplasmosis is the most common central nervous system opportunistic infection.<sup>3</sup> The clinical features are protean with focal or generalized or mixed neurological syndromes, depending on the number, size, and location of the encephalitic regions.<sup>3</sup> The symptoms are not only the result of encephalitis but also edema, vasculitis, and hemorrhage. The onset can be insidious, subacute, or acute in nature. Our patient presented initially with the generalized findings of lethargy and stupor but then developed focal findings. The movement disorder most commonly associated with toxoplasmosis is hemichorea/hemiballism, which has been reported in several cases.<sup>12</sup> It is usually associated with an abscess in the subthalamic nucleus. Other syndromes reported include parkinsonism from bilateral basal ganglia disease, chorea, rubral tremor, and akathisia.<sup>10,12</sup> Dystonia is rare. We are aware of one other case, reported by Tolge and Factor in 1991.<sup>13</sup> That patient had a presumed diagnosis based on an elevated toxoplasmosis titer, presence of multifocal subcortical lesions, and response of those lesions to typical toxoplasmosis therapy. The patient had a focal arm and hand dystonia secondary to lenticular nucleus and thalamic abscesses. It was irreversible, despite appropriate therapy.

Cervical dystonia is rarely the result of focal lesions. Meltzer<sup>14</sup> reported another case of AIDS and cervical dystonia but the CT scan was normal. A small number of cases with various diagnoses causing focal lesions such as stroke, arteriovenous malformation, traumatic infarction, and traumatic cerebral hemorrhage<sup>2,15-18</sup> have been implicated in symptomatic cervical dystonia. Usually, the lesion is in the striatum contralateral to the direction of turning. For our patient, the largest lesion was in the ipsilateral striatum (caudate nucleus) but contralateral thalamic or frontal lobe lesions may have played a role.

The fourth patient had AIDS dementia complex (also referred to as HIV-associated dementia, or HAD) and cervical dystonia presumed to be secondary to antipsychotic therapy. Evidence suggesting that included chronic treatment with a neuroleptic for the previous 5 months, the occurrence of associated orofacial dyskinesia after withdrawal, and the occurrence of the toxoplasma lesion on the incorrect side (indicating noncausality). There are two key issues that relate to this patient. First is the notion that HIV patients have an increased susceptibility to extrapyramidal symptoms from neuroleptics. Second is that this patient developed dystonia while being treated with an atypical antipsychotic.

There have been numerous case reports of acute-onset parkinsonism and dystonia from dopamine antagonist agents in AIDS.<sup>10,19-24</sup> In these cases, the doses of neuroleptics used were at a low or standard level, onset of the movement disorder was often abrupt and progression was rapid. The clinical features were often severe, some were even life-threatening.<sup>22,23</sup> They typically improved with drug withdrawal; however, rechallenge led to recurrence, and in some cases, the disorder was persistent. These cases suggested that there was an increased risk for extrapyramidal symptoms in HAD patients treated with dopamine-blocking agents, and this suggestion was confirmed later by Hriso and colleagues.<sup>25</sup> They retrospectively reviewed the medical records of 31 AIDS patients and 32 non-AIDS psychiatric patients, all of whom were treated with neuroleptics. The AIDS patients had an estimated 2.4 times higher likelihood of experiencing parkinsonism or dystonia. This rate occurred despite the use of lower doses in the AIDS group.

There is increasing evidence supporting the notion that this increased susceptibility is more than just an increased sensitivity to drug actions but is actually due to selective vulnerability of the basal ganglia and, in particular, the dopaminergic system to the HIV infection.<sup>22,26-28</sup> That evidence is demonstrated by clinical, neuroimaging, and neuropathology studies. Clinically, approximately 15% of patients presenting with HAD are

parkinsonian.<sup>26</sup> With regard to neuroimaging, MRI volumetric studies demonstrate reduction of the basal ganglia volume out of proportion to generalized atrophy. Fluorodopa positron emission tomography demonstrates hypermetabolism of basal ganglia early in the course and hypometabolism late when compared to cortical regions. Proton MRI spectroscopy demonstrates decreased NAA/choline ratio in the lenticular nucleus.<sup>26,28</sup>

Pathological studies demonstrate that basal ganglia bear the brunt of infection with the findings of multinucleated giant cells, microglial nodules, and HIV-infected microglia and macrophages being most prominent in the caudate nucleus and putamen.<sup>26–28</sup> In addition, there is a greater neuronal loss in the globus pallidus<sup>23</sup> and substantia nigra.<sup>26</sup> Immunohistochemistry studies have demonstrated high concentrations of certain structural envelope proteins (gp41 and gp120) and core proteins (p24 and Tat) of the HIV in the globus pallidus, striatum, midbrain, thalamus, and dentate nucleus of the cerebellum.<sup>26–28</sup> Neurochemical studies have shown a decrease in dopamine and homovanillic acid levels in the cerebrospinal fluid and striatum with normal levels of monoamines such as serotonin.<sup>26,28</sup> Finally, it has been shown that HIV RNA is not distributed uniformly in the brain in patients with HAD. The basal ganglia represent one region that is selectively infected by the HIV virus.<sup>29</sup> Thus, the increased susceptibility to neuroleptics likely relates to neuronal dysfunction and loss in the basal ganglia, including substantia nigra, which causes an increased reaction to the dopamine receptor blockade caused by the drugs.

The mechanism of neuronal death in these regions remains an active area of investigation. The virus does not infect the neurons directly, so the injury is likely precipitated by indirect means. Several cellular toxins released by infected macrophages, astrocytes, and microglia have been implicated, including cytokines (tumor necrosis factor- $\alpha$ , interleukin-6), arachidonic acids, quinolinic acid, and nitric oxide. In addition, several structural and regulatory proteins of the HIV virus (gp41, gp120, Tat, and Rev) have neurotoxic properties, which could work independently or in tandem with the cellular toxins. The evidence thus far points to a final common pathway of excitotoxicity and possibly apoptosis as the mechanisms of cell death.<sup>26,27</sup>

Our Patient 4 developed cervical dystonia while taking the atypical antipsychotic risperidone. Previous cases of drug-induced rigidity or dystonia were treated with standard neuroleptics or metoclopramide.<sup>10,19–24</sup> It would be expected that atypical agents would be less likely to cause this problem. However, in the case of risperidone,

that may not be true. Although often considered atypical because of its high affinity for 5HT receptors compared to D2, it behaves pharmacologically like a typical agent.<sup>30</sup> Its propensity to worsen motor features of Parkinson's disease supports this finding.<sup>31</sup> There are no data on olanzapine and quetiapine to this point in AIDS patients. Because olanzapine worsens motor features of PD in a manner similar to risperidone,<sup>31,32</sup> it probably should be avoided. Quetiapine may hold some promise because it is relatively well tolerated in PD; however, one must be cautious because it is suggested to worsen parkinsonism in PD patients with dementia.<sup>33</sup> One small study of clozapine has demonstrated that patients can tolerate it without developing parkinsonism, but we must exercise caution because of its propensity to lower white blood cell count, especially in a group already immune-suppressed.<sup>34</sup>

In conclusion, dystonia can occur as the result of several causes in AIDS patients. The pattern of dystonia seen may be a clue to the cause. With PML, dystonia occurs in association with parkinsonism, myoclonus, apraxia, and pyramidal tract signs reminiscent of corticobasal ganglionic degeneration. When toxoplasmosis is the cause, the more common presentation is segmental or hemidystonia most commonly affecting the limbs. And with neuroleptics, one is more likely to see focal or generalized dystonia.

## LEGENDS TO THE VIDEO

**Segment 1.** Patient 1 is a 34-year-old man with dystonia of the left arm and hand. The fingers and thumb are flexed. He has difficulty opening and closing the left fist and performing other dexterous maneuvers and has increased tone. His left arm is internally rotated and has no arm swing seen with walking.

**Segment 2.** Patient 2 is a 43-year-old man with masked, astonished facial expression, bradykinesia, and rigidity of the upper limbs and neck. His neck is anteriorly shifted. He has bilateral arm and hand dystonia, worse on the left.

**Segment 3.** Patient 3 is a 44-year-old man with a right CN III palsy, bilateral increased tone, right hemiparesis, and myoclonus. He has cervical dystonia with right-turning torticollis and limited range of motion. Note the hypertrophied left sternocleidomastoid. He also has right hemidystonia.

**Segment 4.** Patient 4 is a 40-year-old woman with late-stage AIDS dementia complex who developed cervical dystonia from risperidone. The videotaped examination demonstrates moderate torticollis and laterocollis

to the right, hypertrophy of the left sternocleidomastoid muscle, and decreased range of motion.

**Acknowledgments:** This work was supported by the Albany Medical Center Parkinson's Research Fund and the Riley Family Chair of Parkinson's Disease (S.A.F.).

## REFERENCES

- Nath A, Jankovic J, Pettigrew LC. Movement disorders and AIDS. *Neurology* 1987;37:37-41.
- Marsden CD, Obeso JA, Zarranz JJ, Lang AE. The anatomic basis of symptomatic hemidystonia. *Brain* 1985;108:463-483.
- Maiuz P, Bosler E, Luft BJ. Toxoplasmosis. In: Berger JR, Levy RM, editors. *AIDS and the nervous system*. 2nd ed. Philadelphia: Lippincott-Raven; 1997. p 641-659.
- Berger JR, Gallo BV, Concha M. Progressive multifocal leukoencephalopathy. In: Berger JR, Levy RM, editors. *AIDS and the nervous system*. 2nd ed. Philadelphia: Lippincott-Raven; 1997. p 569-594.
- Stockhammer G, Poewe W, Wissel J, Kiechl U, Maier H, Felber S. Progressive multifocal leukoencephalopathy presenting with an isolated focal movement disorder. *Mov Disord* 2000;15:1006-1009.
- Bhatia KP, Morris JH, Frackowiak RSJ. Primary progressive multifocal leukoencephalopathy presenting as an extrapyramidal syndrome. *J Neurol* 1996;243:91-95.
- Van Zanducke M, DeHanene I. A "cortico-basal degeneration"-like syndrome as first sign of progressive multifocal leukoencephalopathy. *Acta Neurol Belg* 2000;100:242-245.
- Singer C, Berger JR, Bowen BC, Bruce JH, Weiner WJ. Akinetic-rigid syndrome in a 13-year-old girl with HIV related progressive multifocal leukoencephalopathy. *Mov Disord* 1993;8:113-116.
- de Toffol B, Vidailhet M, Gray F, Besnier JM, Menage P, Lescs MC, Choutet P, Autret A. Isolated motor control dysfunction related to progressive multifocal leukoencephalopathy during AIDS with normal MRI. *Neurology* 1994;44:2352-2355.
- Manji H, Sweeney B, Connolly S, Hughes A, Miller RF, Harrison MJG. Movement disorders in AIDS: infective, neoplastic and iatrogenic causes. *Parkinsonism Relat Disord* 1995;1:13-19.
- Ledoux S, Libman I, Robert F, Just N. Progressive multifocal leukoencephalopathy with gray matter involvement. *Can J Neurol Sci* 1989;16:200-202.
- Nath A, Hobson DE, Russell A. Movement disorders with cerebral toxoplasmosis and AIDS. *Mov Disord* 1993;8:107-112.
- Tolge C, Factor SA. Focal dystonia secondary to cerebral toxoplasmosis in a patient with acquired immunodeficiency syndrome. *Mov Disord* 1991;6:69-72.
- Meltzer WS. Movement disorders with AIDS encephalopathy: case report. *Neurology* 1987;37:1438.
- Molho ES, Factor SA. Basal ganglia infarction as a possible cause of cervical dystonia. *Mov Disord* 1993;8:213-216.
- Maki Y, Akimoto H, Enomoto T. Injuries of the basal ganglia following head trauma in children. *Childs Brain* 1980;7:113-123.
- Isaac K, Cohen JA. Post-traumatic torticollis. *Neurology* 1989;39:1642-1643.
- LeDoux MS, Brady KA. Secondary cervical dystonia associated with structural lesions of the central nervous system. *Mov Disord* 2003;18:60-69.
- Hollander H, Golden J, Mendelson T, Cortland D. Extrapyramidal symptoms in AIDS patients given low dose metoclopramide or chlorpromazine. *Lancet* 1985;2:1186.
- Edelstein H, Knight RT. Severe parkinsonism in two AIDS patients taking prochlorperazine. *Lancet* 1987;1:341-342.
- Maccario M, Scharre DW. HIV and the acute onset of psychosis. *Lancet* 1987;1:342.
- Kieburzt KD, Epstein LG, Gelbard HA, Greenamyre T. Excitotoxicity and dopaminergic dysfunction in the acquired immunodeficiency syndrome dementia complex: therapeutic implications. *Arch Neurol* 1991;48:1281-1284.
- Factor SA, Podskalny GD, Barron KD. Persistent neuroleptic induced rigidity and dystonia in AIDS dementia complex: a clinico-pathological case report. *J Neurol Sci* 1994;127:114-120.
- van der Kleij FGH, de Vries PAM, Stassen PM, Sprenger HG, Gans ROB. Acute dystonia due to metoclopramide: increased risk in AIDS. *Arch Intern Med* 2002;162:398-399.
- Hriso E, Kuhn T, Masdeu JC, Grundman M. Extrapyramidal symptoms due to dopamine blocking agents in patients with AIDS encephalopathy. *Am J Psychiatry* 1991;148:1558-1561.
- Berger JR, Nath A. HIV dementia and the basal ganglia. *Intervirology* 1997;40:122-131.
- Nath A, Anderson C, Jones M, Maragos W, Booze R, Mactutus C, Bell J, Hauser KF, Mattson M. Neurotoxicity and dysfunction of dopamine systems associated with AIDS dementia. *J Psychopharmacol* 2000;14:222-227.
- Lopez OL, Smith G, Meltzer CC, Becker JT. Dopamine systems in human immunodeficiency virus-associated dementia. *Neuropsychiatry Neuropsychol Behav Neurol* 1999;12:184-192.
- Wiley CA, Soontornniyomkij V, Radhakrishnan L, Masliah E, Mellors J, Hermann SA, Dailey P, Achim CL. Distribution of brain HIV load in AIDS. *Brain Pathol* 1998;8:277-284.
- Factor SA. Pharmacology of atypical antipsychotics. *Clin Neuropharmacol* 2002;25:153-157.
- Friedman JH, Factor SA. Atypical antipsychotics in the treatment of drug-induced psychosis in Parkinson's disease. *Mov Disord* 2000;15:201-211.
- Goetz CG, Blasucci LM, Leurgans S, Pappert EJ. Olanzapine and clozapine: comparative effects on motor function in hallucinating patients. *Neurology* 2000;55:789-794.
- Reddy S, Factor SA, Molho ES, Feustel PJ. The effect of quetiapine on psychosis and motor function in parkinsonian patients with and without dementia. *Mov Disord* 2002;17:676-681.
- Lera G, Ziruľnik J. Pilot study with clozapine in patients with HIV associated psychosis and drug-induced parkinsonism. *Mov Disord* 1999;14:128-131.