

BIVALIRUDIN FOR ENDOVASCULAR INTERVENTION IN ACUTE ISCHEMIC STROKE: CASE REPORT

Mark R. Harrigan, M.D.

Department of Neurosurgery and Toshiba Stroke Research Center, School of Medicine and Biomedical Sciences, University at Buffalo, The State University of New York, Buffalo, New York

Elad I. Levy, M.D.

Department of Neurosurgery and Toshiba Stroke Research Center, School of Medicine and Biomedical Sciences, University at Buffalo, The State University of New York, Buffalo, New York

Bernard R. Bendok, M.D.

Department of Neurosurgery and Toshiba Stroke Research Center, School of Medicine and Biomedical Sciences, University at Buffalo, The State University of New York, Buffalo, New York

L. Nelson Hopkins, M.D.

Department of Neurosurgery and Toshiba Stroke Research Center, School of Medicine and Biomedical Sciences, University at Buffalo, The State University of New York, Buffalo, New York

Reprint requests:

L. Nelson Hopkins, M.D.,
Department of Neurosurgery,
University at Buffalo, Kaleida
Health, 3 Gates Circle, Buffalo, NY
14209-1194.
Email: mharrigan@buffns.com

Received, March 13, 2003.

Accepted, May 21, 2003.

OBJECTIVE AND IMPORTANCE: Intra-arterial thrombolysis has been demonstrated to improve recanalization and outcomes among patients with acute ischemic stroke. However, thrombolytic agents have limited effectiveness and are associated with a significant risk of bleeding. Bivalirudin is a direct thrombin inhibitor that has been demonstrated in the cardiology literature to have a more favorable efficacy and bleeding profile than other antithrombotic medications. We report the use of bivalirudin during endovascular treatment of acute stroke, when hemorrhagic complications are not uncommon.

CLINICAL PRESENTATION: A 71-year-old woman with atrial fibrillation presented with right hemiparesis and aphasia and was found to have a National Institutes of Health Stroke Scale score of 10. Computed tomographic scans revealed no evidence of intracranial hemorrhage, aneurysm, or ischemic stroke. Cerebral angiography revealed thromboembolic occlusion of the superior division of the left middle cerebral artery.

INTERVENTION: For anticoagulation, a loading dose of bivalirudin was intravenously administered before the interventional procedure, followed by continuous infusion. Attempts to remove the clot with an endovascular snare failed to induce recanalization of the vessel. Bivalirudin was then administered intra-arterially. Immediate postprocedural angiography demonstrated restoration of flow in the left middle cerebral artery. Repeat computed tomographic scans demonstrated no intracranial hemorrhage. The patient's hemiparesis and aphasia were nearly resolved and her National Institutes of Health Stroke Scale score was 2 at the time of her discharge 5 days later.

CONCLUSION: To our knowledge, this is the first report of the use of bivalirudin for treatment of acute ischemic stroke. Bivalirudin may be a useful agent for intravenous anticoagulation and intra-arterial thrombolysis in this setting.

KEY WORDS: Acute stroke, Bivalirudin, Endovascular, Intra-arterial thrombolysis

Neurosurgery 54:218-223, 2004

DOI: 10.1227/01.NEU.0000097556.08044.1F

www.neurosurgery-online.com

Intra-arterial thrombolytic therapy for acute ischemic stroke has been demonstrated in randomized controlled studies to be effective for selected patients (10, 13). However, recanalization with intra-arterial thrombolysis is unsuccessful for up to 25 to 40% of arterial occlusions (1, 5), and intra-arterial thrombolytic therapy carries a significant risk of bleeding complications. Symptomatic intracerebral hemorrhage occurs for approximately 10 to 15% of patients who undergo intra-arterial thrombolytic therapy for stroke (10, 14), and mortality rates in this setting can reach 83% (14). Alternative approaches are needed.

Bivalirudin (Angiomax; The Medicines Company, Cambridge, MA) is a synthetic di-

rect thrombin inhibitor that has been extensively used as an alternative to heparin in coronary interventions. Bivalirudin has several advantages over heparin, including a higher specificity for thrombin inhibition and a shorter half-life (3). In a clinical trial comparing bivalirudin with heparin for use in coronary angioplasty, bivalirudin was associated with a lower risk of bleeding complications than was heparin (4). Unlike heparin, bivalirudin inhibits both circulating and fibrin-bound thrombin (29), suggesting that bivalirudin might have thrombolytic activity. We report a case in which bivalirudin was administered intravenously, instead of heparin, during an endovascular intervention for treatment of acute stroke and was administered intra-

arterially for thrombolysis of a clot that was resistant to mechanical thrombolysis.

CASE REPORT

History and Examination Findings

A 71-year-old woman with a history of chronic atrial fibrillation that required warfarin treatment underwent a colon polypectomy. The warfarin therapy had been discontinued for 1 week before the surgical procedure, which was performed without incident. Ten days after surgery, while the patient was recovering at home and before she resumed taking warfarin, she developed dense right hemiplegia and expressive aphasia. She was brought to the emergency room at our facility, and an examination revealed aphasia and right hemiparesis. The patient's National Institutes of Health Stroke Scale score was 10. Computed tomographic scans demonstrated no evidence of intracranial hemorrhage, aneurysm, or ischemic stroke (Fig. 1). Cerebral angiography demonstrated occlusion of the superior division of the left middle cerebral artery (MCA) (Fig. 2). Because of the patient's significant neurological impairment and because her symptoms began approximately 4 hours before an arterial occlusion was identified in the angiographic study, we elected to treat the lesion with intra-arterial thrombolysis. The patient met all published criteria for the use of intra-arterial thrombolytic therapy (10, 13).

Procedure

Angiographic assessment of the left common carotid artery, with local anesthesia, demonstrated occlusion of the superior division of the left MCA. Bivalirudin (a bolus loading dose of 0.5 mg/kg, followed by continuous infusion at 1.75 mg/kg/h for the duration of the procedure) was intravenously administered for systemic anticoagulation. The activated coagulation time was 368 seconds after administration of the loading dose. A Prowler-Plus microcatheter (Cordis Neurovascular, Miami Lakes, FL) with a 0.014-inch microwire (PVS-35; Precision Vascular Systems, West Valley City, UT) was advanced through a guide catheter into the left MCA.

An Amplatz Goose Neck microsnare (Microvena, White Bear Lake, MN) was then guided through the microcatheter and into the MCA thrombus. An attempt was made to remove the thrombus with the snare, but the follow-up microcatheter angiogram demonstrated a persistent filling defect (Fig. 3). The microwire and microcatheter were then advanced as a unit through the catheter and into the thrombus.

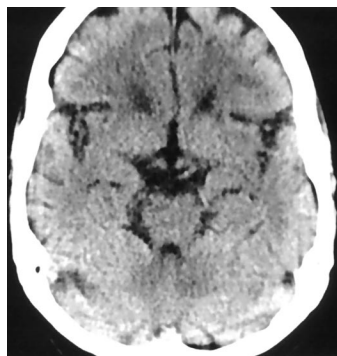

FIGURE 1. Initial computed tomographic scan, demonstrating no evidence of acute infarction, intracerebral hemorrhage, or aneurysm.

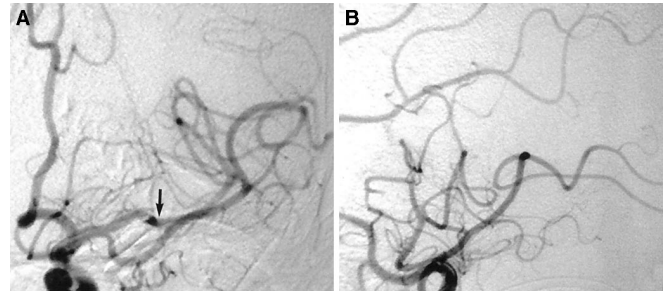


FIGURE 2. Initial angiogram. Anteroposterior (A) and lateral (B) digital subtraction images demonstrate abrupt occlusion of the superior division of the MCA (arrow). A large anterior temporal branch and the inferior division of the MCA bifurcation can be observed. A paucity of distal MCA branch filling can be observed in the lateral view (B).

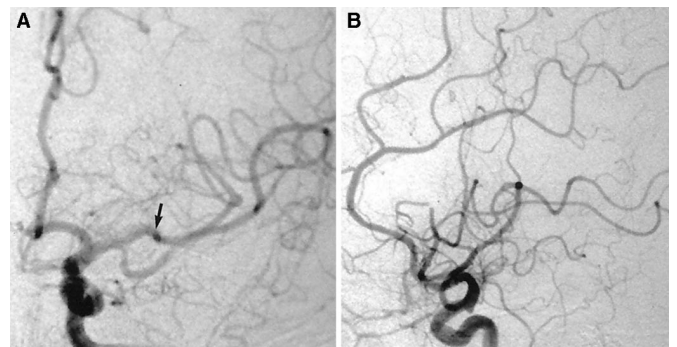


FIGURE 3. Angiogram obtained after an attempt at mechanical thrombolysis. Anteroposterior (A) and lateral (B) digital subtraction images demonstrate persistent occlusion of the superior division of the MCA (arrow), with scant filling of the MCA distal branches.

The microwire was removed, and an intra-arterial infusion of bivalirudin (15 mg in 10 ml of heparinized saline solution) was administered through the microcatheter, as the tip of the microcatheter was slowly withdrawn to the proximal portion of the thrombus. The microcatheter was then removed, and the microcatheter angiogram demonstrated recanalization of the superior division of the left MCA (Fig. 4). The catheter was removed.

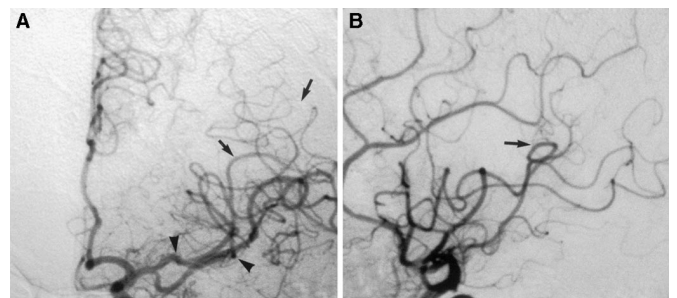


FIGURE 4. Final angiogram, demonstrating the patent MCA. Anteroposterior (A) and lateral (B) images demonstrate restoration of flow in the MCA. There is overlap of the proximal portion of the superior division of the MCA (arrowheads) with distal filling of the MCA branches (arrows).

Postprocedural Course

After completion of the procedure, the patient underwent computed tomographic scanning, which excluded the presence of intracerebral hemorrhage, and was then admitted to the neurosurgical intensive care unit for observation. Because of the patient's atrial fibrillation, heparin was intravenously administered to maintain the activated partial thromboplastin time between 50 and 70 seconds until the prothrombin time was within the therapeutic range with warfarin treatment. The patient's neurological status gradually improved in the subsequent several days, and she was discharged 5 days after admission, with warfarin therapy. Her hemiparesis had resolved except for the presence of partial facial palsy, and her aphasia had improved significantly. Her National Institutes of Health Stroke Scale score at the time of discharge was 2.

DISCUSSION

Thrombin occupies a central role in the regulation of blood coagulation, and its inhibition is a primary means of achieving an antithrombotic and anticoagulant state. Thrombin converts fibrinogen to fibrin by cleaving off fibrinopeptides A and B and binds to fibrin via interaction with its fibrinogen recognition site (11). Thrombin promotes its own production by activating Factors V and VIII (9). Thrombin also activates Factor XIII, which promotes clot stability (9). In addition, thrombin promotes platelet activation and aggregation via thrombin-mediated signaling through protease-activated receptors (12, 18, 27).

Heparin, the standard anticoagulant for neurointerventional procedures, is a glycosaminoglycan that indirectly inhibits thrombin via activation of antithrombin III, a native anticoagulant. The effects of heparin are heterogeneous and nonspecific. Heparin binds to endothelium, acute-phase plasma proteins, and platelet Factor IV. Heparin is unable to inhibit clot-bound thrombin (29) and is susceptible to neutralization by activated platelets (29). Recent studies demonstrated that heparin also binds to and activates glycoprotein IIb-IIIa receptors on platelets, leading to platelet activation (28, 31).

Bivalirudin (previously called Hirulog) is a synthetic, 20-amino acid, polypeptide analog of hirudin, a naturally occurring anticoagulant produced by the salivary glands of the European leech (*Hirudo medicinalis*). Bivalirudin is a bivalent molecule consisting of three domains, i.e., a carboxyl-terminal domain that binds to the fibrinogen recognition site, an amino-terminal domain capable of blocking the catalytic activity of thrombin, and a linker domain of four glycine residues (20). Experimental studies have demonstrated that inhibition of both sites on thrombin, the fibrinogen recognition site and the catalytic site, markedly increases the antithrombotic potency of bivalirudin, compared with inhibition of either site alone (15). Bivalirudin binds to thrombin in a 1:1 stoichiometric complex (20). After binding to thrombin, bivalirudin is slowly cleaved by thrombin (24), which frees the active site of throm-

bin and leaves the remaining fragment of bivalirudin binding competitively to the fibrinogen recognition site of thrombin (12). This reversible interaction is thought to be the basis for the lesser tendency of bivalirudin to cause bleeding complications, compared with heparin.

Bivalirudin reversibly inhibits all of the major actions of thrombin, including cleavage of fibrinogen to fibrin, activation of platelets, and activation of Factors V and VIII (21, 23). Bivalirudin produces dose-dependent increases in activated partial thromboplastin time, prothrombin time, and thrombin time (6). Bivalirudin is rapidly cleared from the plasma by a combination of renal mechanisms and proteolytic cleavage (19) and has a relatively short half-life of 25 minutes (package insert; The Medicines Company). Unlike the effects of heparin, which can be reversed with protamine, there is no known agent to reverse the therapeutic effects of bivalirudin, although there have been no reports of overdoses in clinical trials (6).

Bivalirudin has several properties that distinguish it from heparin. In contrast to heparin, bivalirudin does not bind to plasma proteins, platelet Factor IV, or red blood cells (26), and it is capable of inhibiting both circulating and fibrin-bound thrombin (29). The property of fibrin-bound thrombin inhibition suggests that bivalirudin might have thrombolytic activity in the setting of acute thrombosis. Moreover, unlike heparin, bivalirudin does not seem to activate platelets.

In this case, we used intravenously administered bivalirudin to obtain systemic anticoagulation during the intervention. The intravenous use of bivalirudin has been widely reported in the cardiology literature. Most clinical trials of bivalirudin compared the agent with unfractionated heparin, administered intravenously, for the treatment of acute coronary syndromes and percutaneous coronary interventions, and evidence has accumulated to indicate that bivalirudin has superior antithrombotic efficacy and is associated with fewer bleeding complications. A meta-analysis of six trials that compared bivalirudin with heparin among 5674 patients with acute coronary syndromes demonstrated a 27% reduction in the rate of death or myocardial infarction and a 59% reduction in the rate of major bleeding episodes among patients treated with bivalirudin (16). In a randomized trial of 17,073 patients who underwent intravenous thrombolytic therapy for acute myocardial infarctions, patients who received bivalirudin demonstrated a 30% lower rate of reinfarction, compared with patients who received heparin (30). In a double-blind, randomized trial of 4312 patients who underwent coronary artery angioplasty for treatment of unstable or postinfarction angina, patients who received bivalirudin demonstrated a 22% reduction in myocardial ischemic complications and a 62% reduction in the relative risk of clinically significant bleeding, compared with patients who received heparin (4). A randomized trial of 1056 patients who underwent percutaneous coronary interventions in combination with the provisional use of glycoprotein IIb-IIIa inhibitors compared bivalirudin and heparin (17). There was a 20% reduction in the rate of the composite clinical end point of death, myocardial infarction, repeat re-

vascularization, or major bleeding in the bivalirudin group, compared with the heparin group.

The activated coagulation time of approximately 350 seconds during the procedure in the case reported here corresponds to the optimal activated coagulation time range (350–375 s) that has been determined for percutaneous coronary interventions (7). The primary disadvantage of bivalirudin is the lack of an agent to reverse its anticoagulant effects. Bivalirudin should therefore be used with caution among patients with intracranial vascular lesions and only in situations in which the perceived risk of vessel thrombosis exceeds that of lesion rupture during the procedure.

In this case, we also used intra-arterially administered bivalirudin for thrombolysis. To our knowledge, this is the first report of the intra-arterial use of bivalirudin. Fibrinolytic agents were demonstrated in randomized trials to yield significantly higher rates of recanalization (10) and improvements in neurological outcomes (13) in acute ischemic stroke. Mechanical clot disruption (2, 22, 25) and snare removal (8) are adjunctive maneuvers to reopen occluded vessels in stroke. Mechanical techniques offer the potential advantage of decreasing the dose of, or even the need for, fibrinolytic agents. In this case, it is possible that the attempt at snare removal macerated the thrombus and effectively increased the surface area available for thrombolysis with intra-arterial infusion of bivalirudin.

CONCLUSION

Intravenously administered bivalirudin is an established anticoagulant for cardiological interventions with numerous advantages, compared with intravenously administered heparin, in terms of efficacy and reduction of hemorrhagic complications. It is a potential alternative to intravenously administered heparin for neuroendovascular procedures. Intra-arterially administered bivalirudin may be an effective thrombolytic agent in acute ischemic stroke.

DISCLOSURE

LNH receives research support from and is a consultant for Cordis. He also is a consultant for and has a financial interest in Precision Vascular Systems.

REFERENCES

1. Arnold M, Schroth G, Nedeltchev K, Loher T, Remonda L, Stepper F, Sturzenegger M, Mattle HP: Intra-arterial thrombolysis in 100 patients with acute stroke due to middle cerebral artery occlusion. *Stroke* 33:1828–1833, 2002.
2. Barnwell SL, Clark WM, Nguyen TT, O'Neill OR, Wynn ML, Coull BM: Safety and efficacy of delayed intraarterial urokinase therapy with mechanical clot disruption for thromboembolic stroke. *AJNR Am J Neuroradiol* 15:1817–1822, 1994.
3. Bates SM, Weitz JI: The mechanism of action of thrombin inhibitors. *J Invasive Cardiol* 12[Suppl F]:27F–32F, 2000.

4. Bittl JA, Chaitman BR, Feit F, Kimball W, Topol EJ: Bivalirudin versus heparin during coronary angioplasty for unstable or postinfarction angina: Final report reanalysis of the Bivalirudin Angioplasty Study. *Am Heart J* 142:952–959, 2001.
5. Broderick JP: Recanalization therapies for acute ischemic stroke. *Semin Neurol* 18:471–484, 1998.
6. Carswell CI, Plosker GL: Bivalirudin: A review of its potential place in the management of acute coronary syndromes. *Drugs* 62:841–870, 2002.
7. Chew DP, Bhatt DL, Lincoff AM, Moliterno DJ, Brener SJ, Wolski KE, Topol EJ: Defining the optimal activated clotting time during percutaneous coronary intervention: Aggregate results from 6 randomized, controlled trials. *Circulation* 103:961–966, 2001.
8. Chopko BW, Kerber C, Wong W, Georgy B: Transcatheter snare removal of acute middle cerebral artery thromboembolism: Technical case report. *Neurosurgery* 46:1529–1531, 2000.
9. Davie EW, Fujikawa K, Kisiel W: The coagulation cascade: Initiation, maintenance, and regulation. *Biochemistry* 30:10363–10370, 1991.
10. del Zoppo GJ, Higashida RT, Furlan AJ, Pessin MS, Rowley HA, Gent M: PROACT: A Phase II randomized trial of recombinant pro-urokinase by direct arterial delivery in acute middle cerebral artery stroke—PROACT Investigators: Prolyse in Acute Cerebral Thromboembolism. *Stroke* 29:4–11, 1998.
11. Fenton JW II: Thrombin functions and antithrombotic intervention. *Thromb Haemost* 74:493–498, 1995.
12. FitzGerald GA: The human pharmacology of thrombin inhibition. *Coron Artery Dis* 7:911–918, 1996.
13. Furlan A, Higashida R, Wechsler L, Gent M, Rowley H, Kase C, Pessin M, Ahuja A, Callahan F, Clark WM, Silver F, Rivera F: Intra-arterial prourokinase for acute ischemic stroke: The PROACT II study—A randomized controlled trial: Prolyse in Acute Cerebral Thromboembolism. *JAMA* 282:2003–2011, 1999.
14. Kase CS, Furlan AJ, Wechsler LR, Higashida RT, Rowley HA, Hart RG, Molinari GF, Frederick LS, Roberts HC, Gebel JM, Sila CA, Schulz GA, Roberts RS, Gent M: Cerebral hemorrhage after intra-arterial thrombolysis for ischemic stroke: The PROACT II trial. *Neurology* 57:1603–1610, 2001.
15. Kelly AB, Maraganore JM, Bourdon P, Hanson SR, Harker LA: Antithrombotic effects of synthetic peptides targeting various functional domains of thrombin. *Proc Natl Acad Sci U S A* 89:6040–6044, 1992.
16. Kong DF, Topol EJ, Bittl JA, White HD, Theroux P, Hasselblad V, Califf RM: Clinical outcomes of bivalirudin for ischemic heart disease. *Circulation* 100:2049–2053, 1999.
17. Lincoff A, Bittl J, Kleiman N, Kereiakes D, Harrington R, Sarembock I, Jackman J, Mehta S, Maieron E, Chew D, Topol E: The REPLACE 1 Trial: A pilot study of bivalirudin versus heparin during percutaneous coronary intervention with stenting and GP IIb/IIIa blockade. *J Am Coll Cardiol* 39[Suppl 5A]:16A–17A, 2002 (abstr).
18. Liu L, Freedman J, Hornstein A, Fenton JW II, Ofosu FA: Thrombin binding to platelets and their activation in plasma. *Br J Haematol* 88:592–600, 1994.
19. Lui HK: Dosage, pharmacological effects and clinical outcomes for bivalirudin in percutaneous coronary intervention. *J Invasive Cardiol* 12[Suppl F]:41F–52F, 2000.
20. Maraganore JM, Bourdon P, Jablonski J, Ramachandran KL, Fenton JW II: Design and characterization of hirulogs: A novel class of bivalent peptide inhibitors of thrombin. *Biochemistry* 29:7095–7101, 1990.
21. Maraganore JM, Chao B, Joseph ML, Jablonski J, Ramachandran KL: Anticoagulant activity of synthetic hirudin peptides. *J Biol Chem* 264:8692–8698, 1989.
22. Nesbit GM, Clark WM, O'Neill OR, Barnwell SL: Intracranial intraarterial thrombolysis facilitated by microcatheter navigation through an occluded cervical internal carotid artery. *J Neurosurg* 84:387–392, 1996.
23. Ofosu FA, Fenton JW II, Maraganore J, Blajchman MA, Yang X, Smith L, Anvari N, Buchanan MR, Hirsh J: Inhibition of the amplification reactions of blood coagulation by site-specific inhibitors of α -thrombin. *Biochem J* 283: 893–897, 1992.
24. Parry MA, Maraganore JM, Stone SR: Kinetic mechanism for the interaction of Hirulog with thrombin. *Biochemistry* 33:14807–14814, 1994.

25. Qureshi AI, Siddiqui AM, Suri MF, Kim SH, Ali Z, Yahia AM, Lopes DK, Boulos AS, Ringer AJ, Saad M, Guterman LR, Hopkins LN: Aggressive mechanical clot disruption and low-dose intra-arterial third-generation thrombolytic agent for ischemic stroke: A prospective study. *Neurosurgery* 51:1319–1329, 2002.
26. Robson R, White H, Aylward P, Frampton C: Bivalirudin pharmacokinetics and pharmacodynamics: Effect of renal function, dose, and gender. *Clin Pharmacol Ther* 71:433–439, 2002.
27. Sambrano GR, Weiss EJ, Zheng YW, Huang W, Coughlin SR: Role of thrombin signalling in platelets in haemostasis and thrombosis. *Nature* 413:74–78, 2001.
28. Sobel M, Fish WR, Toma N, Luo S, Bird K, Mori K, Kusumoto S, Blystone SD, Suda Y: Heparin modulates integrin function in human platelets. *J Vasc Surg* 33:587–594, 2001.
29. Weitz JI, Hudoba M, Massel D, Maraganore J, Hirsh J: Clot-bound thrombin is protected from inhibition by heparin-antithrombin III but is susceptible to inactivation by antithrombin III-independent inhibitors. *J Clin Invest* 86: 385–391, 1990.
30. White H: Thrombin-specific anticoagulation with bivalirudin versus heparin in patients receiving fibrinolytic therapy for acute myocardial infarction: The HERO-2 randomised trial. *Lancet* 358:1855–1863, 2001.
31. Xiao Z, Theroux P: Platelet activation with unfractionated heparin at therapeutic concentrations and comparisons with a low-molecular-weight heparin and with a direct thrombin inhibitor. *Circulation* 97:251–256, 1998.

Acknowledgments

We thank Paul H. Dressel for preparation of the illustrations.

COMMENTS

Harrigan et al. have submitted an exciting report detailing the use of a new thrombin-inhibiting agent for the intra-arterial treatment of an acute thromboembolic event. The article is very well written, and the discussion is appropriately detailed. The authors have made an important contribution.

The only point left unclear by the article revolves around why the authors selected this particular patient for treatment with bivalirudin. I suspect that this experienced group sees many patients with acute stroke who are candidates for intra-arterial thrombolysis. Were there any unique issues in this case that led to the authors' choice of this novel agent? Future selection criteria for the use of this agent would have been a welcome and important addition to the Discussion section. Are the authors recommending bivalirudin as a first-line option for intra-arterial thrombolysis in all patients with acute intracranial arterial occlusion, or will they continue to use more traditionally accepted agents, such as tissue plasminogen activator? Similarly, it would have been worthwhile for the authors to have commented on whether this patient was treated as part of an institutional review board-approved protocol.

Despite these issues, the authors have provided us with an important new option in the management of patients with acute intracranial arterial occlusion. We look forward to future contributions from this group that further elucidate the role of this agent in the management of acute stroke.

Eric S. Nussbaum
Minneapolis, Minnesota

Harrigan et al. describe their experience in using bivalirudin administered both intra-arterially and intravenously in a patient who presented with an acute ischemic event caused by a soft clot. As the authors discuss, this is a synthetic amino acid polypeptide that has been used extensively in the realm of interventional cardiology and has been found to be markedly beneficial in reducing reocclusion and also reducing the incidence of hemorrhagic complications.

Quite interestingly, with no heparin administered, the activated clotting time was dramatically elevated to well over 300 seconds. Despite that effect, recanalization seems to be excellent in hemorrhagic idiopathies and, particularly in the cardiology patient population, has been really quite minimal. This is certainly one of the problems with intra-arterial and intravenous thrombolysis in hemorrhagic conversion of an ischemic lesion, and obviously, the intracranial catastrophe that often results is worse than the problem being treated and makes a bad situation worse.

If recanalization can be achieved and hemorrhagic complications reduced, this drug certainly will have a role in the treatment of acute ischemic stroke. As many investigators know, the hemorrhagic conversion is often a problem of delayed intervention or not knowing the time of the original ictus, and patients are then treated beyond the "6-hour window" for safe intervention. This drug in particular is something that should become very familiar to all endovascular therapists who are treating acute ischemic stroke, and we look forward to hearing more from this group regarding their continued experience.

Robert H. Rosenwasser
Philadelphia, Pennsylvania

Since first being developed in 1994, bivalirudin has saved many lives. Originally developed for the treatment of coronary angioplasty, the early data suggested only marginal advantages and unfavorable economics compared with heparin. The second life of the drug began in 1997, when the agent was licensed to a new sponsor and a less expensive manufacturing process was developed. These events, combined with a high-profile reanalysis of the early data on angioplasty for unstable or postinfarction angina, resulted in renewed interest in this direct thrombin inhibitor as an alternative to heparin.

As Harrigan et al. point out, the interest grows from the fact that, unlike heparin, bivalirudin inhibits both fluid-phase and clot-bound thrombin, is not bound by plasma proteins, and is not neutralized by platelet factors. Moreover, bivalirudin inhibits platelet activation by noncompetitively and reversibly interfering with active-site binding of the thrombin receptor by thrombin, which in turn blocks glycoprotein IIb/IIIa receptor activation and fibrinogen-dependent platelet aggregation. Heparin, by comparison, has been shown to induce glycoprotein IIb/IIIa receptor activation despite its antithrombin III-dependent anticoagulant effect. The overall result of these differences is that bivalirudin is not only an anticoagulant but also an antiplatelet agent that has markedly more predictable

pharmacokinetics and is associated with lower rates of bleeding. In fact, a 6000-patient Phase III trial of bivalirudin versus heparin plus glycoprotein IIb/IIIa receptor antagonists was recently published (1), showing equivalence in the setting of coronary stenting completely driven by a reduction in major bleeding events for the novel therapy. These data certainly support the experimental use of bivalirudin in neurointerventional procedures, especially when heparin is contraindicated or bleeding complications are expected.

Although our results are unpublished, we have performed procedures in patients with anti-heparin antibodies using bivalirudin with good results. Whether bivalirudin turns out to be better than heparin for patients undergoing intracranial thrombolysis remains to be seen, but the authors have suggested this possibility. They should also be encouraged to further explore their hypothesis that the drug is capable of actually lysing clot when injected directly into the thrombus. Although disaggregation of existing thrombi would not be expected on the basis of the known activities of the drug, it is possible that the catheter mechanically disrupted the clot to

some degree and the bivalirudin facilitated reflow by binding the thrombin on the clot surface. This debate could certainly be addressed in ex vivo models. If verified, it could turn out that even if intravenous bivalirudin is no better than heparin, new-generation heparinoids, or drugs in development such as inhibitors of tissue factor or Factor Xa, it may have an important intra-arterial role in cerebral clot extraction when immediate and early rethrombosis remains an important problem.

E. Sander Connolly, Jr.
Sean D. Lavine
New York, New York

1. Lincoff AM, Bittl JA, Harrington RA, Feit F, Kleiman NS, Jackman JD, Sarenbock JJ, Cohen DJ, Spriggs D, Ebrahimi R, Keren G, Carr J, Cohen EA, Betriu A, Desmet W, Kereiakes DJ, Rutsch W, Wilcox RG, de Feyter PJ, Vahanian A, Topel EJ: Bivalirudin and provisional glycoprotein IIb/IIIa blockade compared with heparin and planned glycoprotein IIb/IIIa blockade during percutaneous coronary intervention: REPLACE-2 randomized trial. *JAMA* 289:853-863, 2003.

Customer Service Contact Information

CNS Members: Call Sue Souders at: 301/223-2325.

Non-CNS Members: Call either 301/223-2300 or 1-800/638-3030.

Customer Service fax: 301/223-2400.

Customer Service email: customerservice@lww.com

World Federation of Neurosurgical Societies Web Site

On behalf of the World Federation of Neurosurgical Societies, I would like to invite you to log onto the web site of the WFNS at www.wfns.org. Our web site editor, Dr. Eduardo A. Karol of Argentina, has done a wonderful job in presenting on the web site not only information about the many activities of the WFNS, but also opportunities for young neurosurgeons all around the world to communicate with each other and to participate in web-based educational activities. These include interesting cases, clinicopathological conferences, and the web-based journal *Critical Reviews*, the official electronic journal of the WFNS. We hope you will participate. Those of you who would like to become more involved in the WFNS web site activities are very welcome to volunteer your efforts, which will be much appreciated.

Edward R. Laws, Jr.
President