

A pain in the neck: dissection of the vertebral artery

Glyn Scott, Catherine Jack

INTRODUCTION

Dissection of the vertebral artery may be precipitated by even minor trauma; a detailed history of events preceding the onset of symptoms is pivotal to formulation of the diagnosis. This article presents three cases which clearly demonstrate these points.

DISCUSSION

Vertebral arterial dissection accounts for under 2% of all ischaemic strokes (Schievink, 2001); in younger age groups it may account for up to 20% of cases (Ducrocq et al, 1999). It is more likely to occur in instances of hyperextension or rotation of the neck, as a result of stretching of the vessel which

is relatively mobile within the cervical spinal column. The term 'beauty parlour stroke' has been used to describe the phenomenon in patients who develop symptoms and signs following hyperextension of the neck over the edge of a sink for the purpose of hair washing in salons (Weintraub, 1993).

Conventional angiography detects pathognomonic appearances (such as an intimal flap) in under 10% of vertebral arterial dissections (Houser et al, 1984). Magnetic resonance angiography (MRA) is thus emerging as the gold standard for diagnosis. In instances where this is not possible or inconclusive, the history frequently suggests the underlying pathology,

with patients describing neck pain or headache, often after a time lapse of several hours to a few days following a relatively minor abnormal movement or positioning of the head. This delay presents an opportunity to instigate treatment before onset of neurological signs with potential for reducing severity of functional deficits or possibly preventing them in the first place.

Randomized controlled trials evaluating treatments for the condition are lacking and existing recommendations are usually made in the context of extrapolations of evidence for carotid

CASE REPORT 1

A 49-year-old male model developed an acute severe occipital headache and neck stiffness following a day spent striking dynamic poses for a modelling assignment, during which he had been required to hold his head in several awkward positions for protracted periods of time. In the subsequent 24 hours he developed slurred speech, poor balance and a persistent pain in the neck. On presentation to hospital he was dysarthric and ataxic of gait, and had upper limb weakness, finger nose ataxia, an upper motor neurone facial nerve palsy and an extensor plantar response.

Magnetic resonance imaging of the brain showed a 2 cm x 1 cm infarction in the left pons extending to the midbrain (Figure 1).

The patient was commenced on aspirin and by 8 weeks his neurological symptoms had completely resolved.

CASE REPORT 2

A 35-year-old man injected an unknown quantity of heroin into a vein in his right antecubital fossa. He subsequently collapsed and awoke next morning on the floor with severe neck pain, double vision, slurred speech, nausea and vomiting. Attempting to stand, he noticed severe weakness of his left arm and leg which progressed over the subsequent 2–3 hours. He stated that when he awoke his neck 'was in an awkward position'.

On presentation he was dysarthric with a left-sided upper motor neurone facial weakness and diplopia on vertical and left lateral gaze. He exhibited left-sided hemiparesis, spinocerebellar sensory impairment and extensor plantar response, with past-pointing and dysidiadochokinesia of the left upper limb.

Magnetic resonance imaging and angiography were performed. The former showed altered signal on the right side of the pons and a similar, smaller area in the left cerebellum, consistent with infarction. The angiogram revealed attenuation of the signal from the right vertebral artery with occlusion of the vessel at the mid-cervical level; the left vertebral angiogram is included for comparison (Figure 2).

He was commenced on aspirin. At 2 months he had persistent double vision, mild weakness of the left arm and spastic dragging of the left leg, with mild heel-shin ataxia, but was mobile independently.

Figure 1. Magnetic resonance scan showing left pontine infarction.

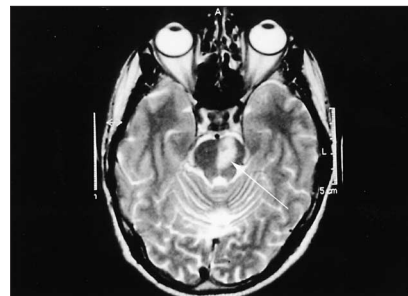
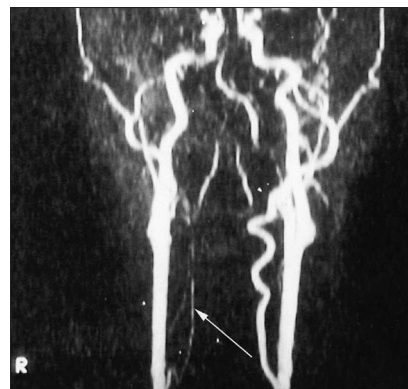

Figure 2. Magnetic resonance angiogram showing abnormal signal in right vertebral artery.



Dr Glyn Scott is Specialist Registrar in Care of the Elderly, and Dr Catherine Jack is Consultant Physician in Care of the Elderly, Acute Stroke Unit, Royal Liverpool University Hospital, Merseyside

Correspondence to: Dr G Scott, Care of the Elderly Directorate, Elderly Health Unit, Broadgreen Hospital, Liverpool L14 3LB

CASE REPORT 3

A 41-year-old West African male developed an acute severe occipital headache while lying in bed. This was rapidly followed by nausea, vomiting and hiccoughs. Over the subsequent 48 hours he experienced progressive difficulty using his right hand.

Initial examination revealed mild neck stiffness on flexion-extension and weakness, past-pointing and dysidiadochokinesia of the right upper limb. Horizontal nystagmus was elicited.

Magnetic resonance angiography showed absence of flow in the right vertebral artery at the level of the common carotid artery and above. Axial sections demonstrated abnormally bright signal from the artery, suggesting the presence of intraluminal thrombus or dissection (Figure 3). Following initiation of aspirin, his clinical recovery was rapid over the subsequent week, with virtually complete restoration of neurological function in the right arm.

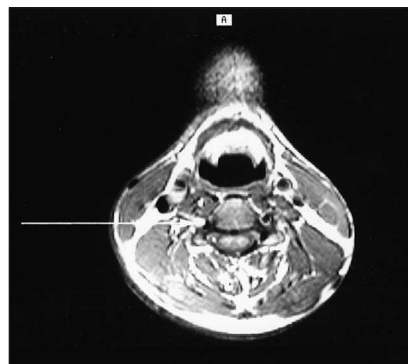


Figure 3. Magnetic resonance angiogram showing right vertebral arterial dissection.

arterial dissections. Most associated infarcts are thromboembolic (Lucas et al, 1998) and dissections have a high frequency of associated microemboli (Srinivasan et al, 2000); treatment with warfarin has thus been recommended to achieve an international normalized ratio of 2.0–3.0 for 3–6 months (Schievink, 2000). The argument for this duration of treatment is based on experience of authors that most dissections heal, with resolution of symptoms, within 3 months, and that symptoms rarely recur after 6 months (Schievink, 2000).

MRA can be used to confirm recanalization and in those in whom an abnormality persists beyond 6 months, substitution of warfarin by lifelong antiplatelet therapy with aspirin is suggested (Schievink, 2000). The usual side effects and contraindications to warfarin apply, particularly where there is mass effect or haemorrhagic transformation associated with an infarct, or

where there is intracranial extension of the dissection or an intracranial aneurysm. In such cases aspirin may be considered but there is no consensus on dose (Schievink, 2000). Aspirin may also be the initial treatment of choice in those who are free of symptoms. Duration of aspirin therapy and its continuation subject to MRA follow-up is recommended along similar lines as warfarin (Schievink, 2000). The use of other antiplatelet agents such as clopidogrel, and of low molecular weight heparins, has not been evaluated.

Where medical treatment is contraindicated or where recurrence indicates its failure, balloon angioplasty with stenting, or extracranial–intracranial saphenous vein bypass grafting in those patients for whom endovascular procedures are technically impossible, may be considered. Endarterectomy is not used as it is associated with high rates of vessel occlusion which would

be deleterious given the significant risk of recurrent dissections in a contralateral vessel (Schievink et al, 1994). **HM**

- Ducrocq X, Lacour JC, Debouverie M, Bracard S, Girard F, Weber M (1999) Cerebral ischaemic accidents in young subjects. A prospective study of 296 patients aged 16 to 45 years. *Rev Neurol (Paris)* **155**(8): 575–82
- Houser OW, Mokri B, Sundt TM Jr, Baker HL Jr, Reese DF (1984) Spontaneous cervical cephalic arterial dissection and its residuum: angiographic spectrum. *AJNR Am J Neuroradiol* **5**: 27–34
- Lucas C, Moulin T, Deplanque D, Tatu L, Chavot D (1998) Stroke patterns of internal carotid artery dissection in 40 patients. *Stroke* **29**: 2646–8
- Schievink WI (2000) The treatment of spontaneous carotid and vertebral artery dissections. *Curr Opin Cardiol* **15**: 316–21
- Schievink WI (2001) Spontaneous dissection of the carotid and vertebral arteries. *N Engl J Med* **344**(12): 898–906
- Schievink WI, Mokri B, O'Fallon WM (1994) Recurrent spontaneous cervical-artery dissection. *N Engl J Med* **330**: 393–7
- Srinivasan J, Newell DW, Sturtzenegger M, Mayberg MR, Winn HR (2000) Transcranial Doppler in the evaluation of internal carotid artery dissection. *Neurology* **54**: 2159–61
- Weintraub MI (1993) Beauty parlour stroke syndrome: report of five cases. *JAMA* **269**: 2085–6

Forthcoming case reports in *Hospital Medicine*

- Atrial myxoma: a cardiocutaneous syndrome
- A vascular left atrial myxoma causing obstructive symptoms
- A lump in the neck and in the petrous part of the temporal bone
- Cerebral venous thrombosis presenting as unilateral headache plus visual blurring in a man with nephrotic syndrome
- Metastatic prostate cancer to lung with normal PSA
- Unusual severe hypercholesterolaemia and xanthomas in a patient with hepatolithiasis
- Dual thrombotic tendency: cerebral sinus thrombosis in a young adult with activated protein C resistance and homocysteinaemia

Please note that there is currently a 6–9 month wait for publication of accepted case reports.