

Tactile Awareness and Limb Position in Neglect: Functional Magnetic Resonance Imaging

Nathalie Valenza, BA,¹ Mohamed L. Seghier, PhD,^{1,2} Sophie Schwartz, PhD,^{1,3} François Lazeyras, PhD,² and Patrik Vuilleumier, MD^{1,4}

We studied a patient with right parietal damage for whom tactile stimuli on the right/*ipsilesional* hand (projecting to the intact left hemisphere) were extinguished from awareness during double simultaneous stimulation, when his right hand was positioned in the left/*contralesional* space. This demonstrates the role of an egocentric spatial reference frame in attention that can determine awareness of stimuli despite intact sensory pathways. Using functional magnetic resonance imaging to elucidate the neural correlates of such perceptual extinction, we found that limb position modulated neural responses to tactile stimuli at early cortical stages (SI) in the intact hemisphere. Activity in bilateral middle frontal gyri also was modulated by limb position and may contribute to integrate sensory inputs into a supramodal, egocentric representation of space.

Ann Neurol 2004;55:139–143

Unilateral parietal lesions in humans often cause spatial neglect and perceptual extinction, in which patients may remain unaware of stimuli contralateral to the lesion, in the absence of major sensory deficits. Extinction may concern tactile inputs, characterized by a failure to report a contralesional touch when stimuli are simultaneously delivered to both hands, although single contralesional touches are correctly detected.^{1,2} Several explanations have been proposed for this loss of tactile awareness on double simultaneous stimulation (DSS). Recent theories argue that extinction may result from a

spatial bias in attention affecting the processing of inputs on the contralesional side, according to various frames of spatial representation.^{1–3} However, the role of subtle sensory dysfunction is still unclear. Other accounts suggest that extinction might reflect a degradation or slowing in processing of sensory stimuli.^{4,5} In support of spatial attentional mechanisms, patients have been reported in whom tactile extinction was modulated by position of the affected hand relative trunk⁶ or to the location of the other hand.³ Thus, tactile extinction may improve when the left hand is positioned in the right rather than left hemisphere⁶ or when hands are crossed, in either hemisphere.³ Tactile extinction also may arise on an intact/*ipsilesional* limb, under conditions in which awareness of tactile stimuli is determined by their relative spatial position on the limb.⁷ Other findings also support a role of hemispacial factors in neglect and extinction.⁸

Here, we describe a patient who presented with a striking deficit in tactile perception on his right/*ipsilesional* hand when it was placed in the left side of space, after a focal right parietal lesion. Using functional magnetic resonance imaging (fMRI) in this patient, we were able to determine the neural correlates of tactile extinction for stimuli delivered on an intact limb, without any concomitant sensory deficit potentially associated with *contralesional* tactile extinction. Critically, we sought to determine brain areas showing differential responses on DSS as a function of the spatial position of the right hand, paralleling the patient's changes in perceptual awareness.

Case Report

A 68-year-old right-handed man, suffered two hemorrhagic strokes in right superior parietal lobe in 1998 and 2000. MRI scan at the time of our study in 2002 showed residual right parietal damage (Fig 1A, B). The patient showed marked signs of left visual neglect in the acute stage (eg, 14–20% left omissions in cancellation tests; 7–9% rightward displacement in line bisection) but only mild signs at the time of our study (eg, slower detection of visual targets in left versus right hemifield [mean, 429 vs 272 milliseconds], but no omission in cancellation tests, and no visual extinction). A detailed neuropsychological examination showed that other cognitive functions were normal. He had minimal weakness and decreased position sense in the left arm but no deficit in superficial touch, pain, and temperature. During clinical testing of tactile extinction, he reported 20 of 20 single touches on the left (contralesional) hand, but only 1 of 20 during DSS of both hands. Right-hand touches were always correctly perceived in these conditions.

A modulation of tactile extinction by hand position in egocentric space was demonstrated by delivering single or DSS stimuli to the right hand and to the right

From the ¹Laboratory of Neurology and Imaging of Cognition, Department of Neurology and Neurosciences and ²Department of Radiology, University of Geneva, Switzerland; ³Institute of Cognitive Neuroscience, University College London, United Kingdom; and ⁴School of Educational Sciences and Psychology, University of Geneva, Switzerland.

Received April 14, 2003, and in revised form July 28. Accepted for publication Oct 15, 2003.

Address correspondence to Dr Vuilleumier, Laboratory NIC, Department of Neurosciences and Physiology, University Medical Center, 1 Rue Michel-Servet, 1211 Geneva 4, Switzerland.
E-mail: patrik.vuilleumier@medecine.unige.ch

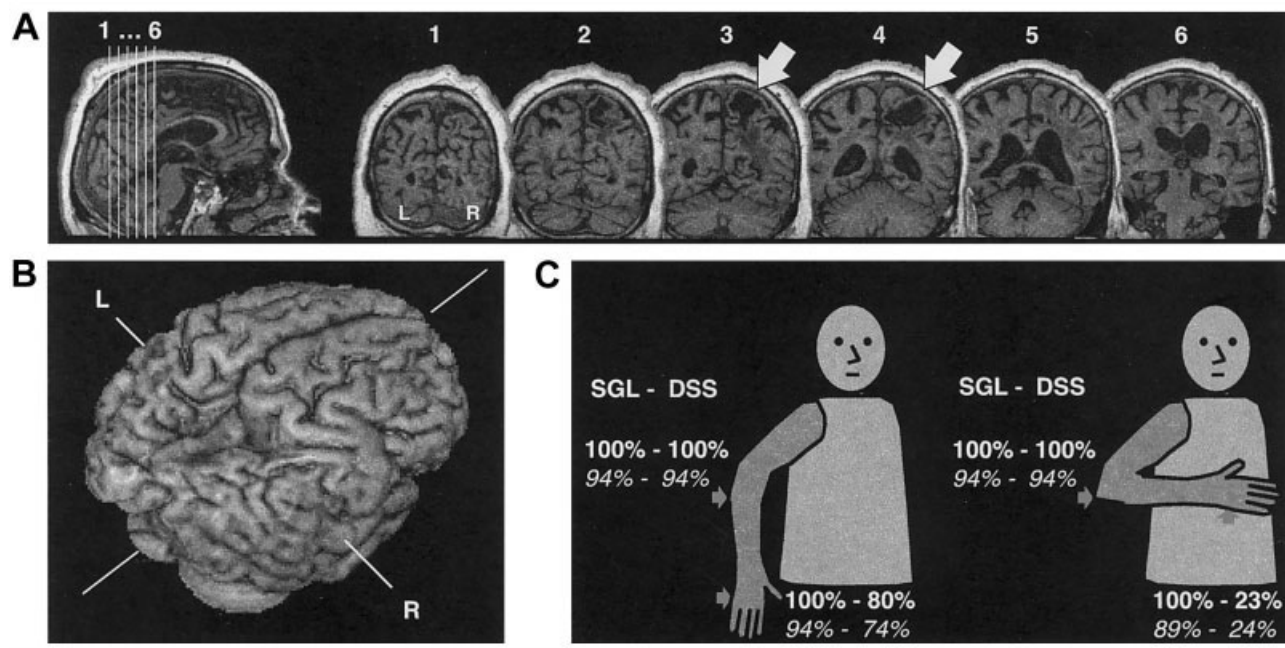


Fig 1. (A) T1-weighted magnetic resonance imaging (MRI) scan of the brain in our patient showing a chronic lesion in right parietal lobe (white arrows), extending in white matter. Only slight white matter disease was visible in the posterior left periventricular region, and the patient had no clinical left hemispheric symptoms. (B) Three-dimensional reconstruction of MRI showing the damaged cortical area. (C) Experimental testing of tactile extinction on the intact right hand was performed with the hand placed to the right or left of the trunk's midline (stimulation on the ulnar edge of the hand, elbow, both, or none), with eye closed, in a similar way both outside (percentage correct detection in boldface) and inside (percentage correct detection in italics) the scanner.

elbow of the patient (ie, the *ipsilesional* limb), in two different spatial conditions (see Fig 1C). Tactile stimuli were applied by a conventional procedure² using a rapid flexion extension of the examiner's finger (40 trials in each condition). DSS on right hand and right elbow produced a marked extinction of hand stimuli when the hand was on the left of the patient's trunk, with the patient reporting only the right elbow touch on 31 of 40 trials. In contrast, detection of hand stimuli on DSS trials was much better with the hand placed to the right of his trunk (only 8/40 misses; $\chi^2(1) = 26.5$, $p < 0.001$). Single stimuli on both hand and elbow were always accurately reported (0/40 missed). These data demonstrate significant extinction on the intact right hand, dependent on this hand being in left hemisphere. Incidentally, we also note that some extinction occurred for right-hand touches even in right space during DSS to hand and elbow, consistent with other clinical observations of frequent extinction for the more distal of two tactile stimuli delivered on the same limb.⁹

Functional Imaging Methods

During fMRI scanning, tactile extinction on the *right* hand was tested in a similar way as outside the scanner, either on the right or left side of the trunk, with eyes closed (see Fig 1C). A MRI-compatible device (attached to the patient's arm by a splint) was used to deliver light taps with constant intensity and constant intervals, time-

locked by a computer (45 trials in each condition). Four stimulus types (rest; single hand; single elbow; hand + elbow DSS) were applied in short blocks (24 seconds) consisting of five stimuli of a particular type (SOA approximately 4 seconds), plus one stimulus from another type to limit expectations biases. Each condition was repeated three times in random order during a session, with four sessions performed in the two different hand positions (ABBA). The patient reported the number of felt stimuli (one or two) by left-hand key presses.

In addition, a separate hand-localizer scan was performed, during which four blocks of passive right-hand stimulation (24 seconds) and four blocks of rest (24 seconds) were given in alternation, with the right hand in right space.

Whole-brain fMRI was performed on a 1.5T MR system, using an echo planar imaging GRE sequence (TR/TE/flip, 2 seconds/40 milliseconds/80 degrees; FOV, 250mm; matrix, 128×128 ; 19 contiguous 5mm axial slices, resolution = $1.95 \times 1.95\text{mm}^2$). Data were processed and analyzed on a voxel-by-voxel basis using SPM99,¹⁰ including eight different conditions (four stimulation types \times two limb positions) in the extinction scan session, and two conditions in the hand-localizer session (hand-stimulation and rest). Only activations surviving a threshold at p value 0.001 voxelwise are reported.

Results

During fMRI scanning, as observed in behavioral testing outside the scanner, DSS on the right (ipsilesional) hand and elbow resulted in a severe extinction of hand stimuli when this hand was in left space (DSS-L: 66% missed), compared with when the hand was in right

space (DSS-R: 26% missed; $\chi^2(1) = 23.73$, $p < 0.001$). Hand position did not affect detection of single stimuli on either the hand (11% vs 6% missed; $\chi^2(1) = 0.39$, NS) or elbow (6% missed in each condition). Elbow stimuli were correctly detected during DSS regardless of limb position.

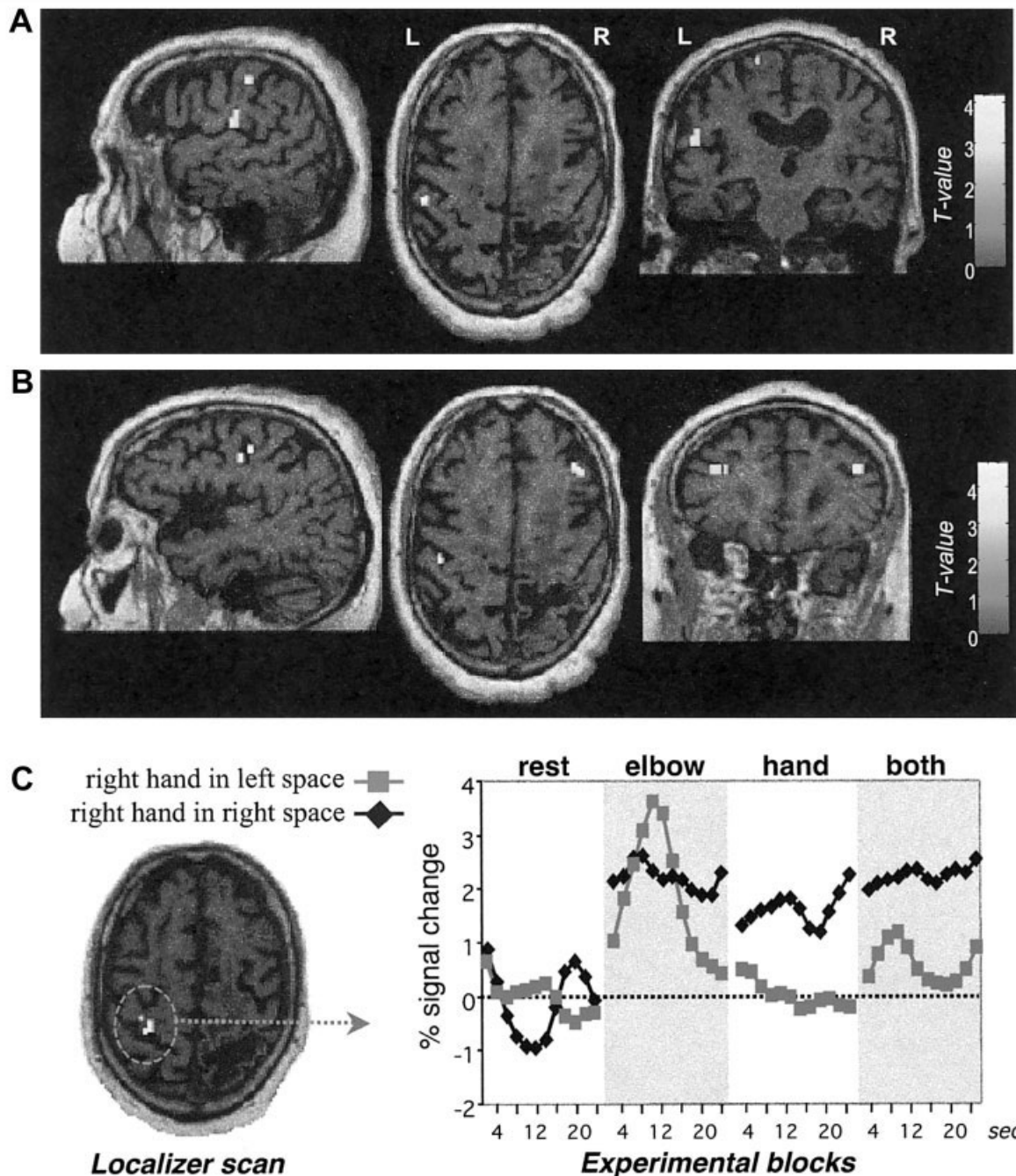


Fig 2. (A) Activation by single-hand more than single-elbow stimuli were found in left postcentral (SI) and opercular (SII) somatosensory cortex. (B) Activation modulated by hand position during double simultaneous stimulation (DSS-R > DSS-L) occurred in similar left postcentral regions and bilateral middle frontal gyri. (C) Region of interest in postcentral somatosensory cortex (SI) defined by an independent localizer-scan (hand dorsum > rest), in which average activity across each block condition showed a consistent increase during single-hand and DSS stimuli only when the hand was in right space, but not in left space.

Our fMRI analysis first determined neural responses elicited by single right-hand stimuli, irrespective of hand position in space (hand > rest). Significant activation was found in postcentral gyrus and parietal operculum of the left hemisphere (Fig 2A), corresponding to human primary (SI) and secondary (SII) somatosensory areas, respectively.^{11,12} Bilateral parietal regions, precentral frontal cortex, and left superior occipital gyrus also were activated (see the Table for complete list of activations and normalized coordinates). Greater responses to hand than to elbow stimulation were specifically found in a lateral part of the left post-central gyrus, parietal operculum, and superior parietal cortex. Similar results are typically found during somatosensory stimulation of the hand in normal subjects.¹²

The next critical analysis determined brain regions where somatosensory responses were modulated by hand position during DSS condition, that is, the neural correlates of tactile extinction when the *intact/right* hand was placed in *contralesional/left* space. Comparing activation produced by DSS with the right hand on the right versus left side (DSS-R > DSS-L) showed greater responses in the left postcentral and precentral gyri, as well as left superior medial parietal cortex and bilateral middle frontal gyri (see Fig 2B). When we restricted

our analysis to areas specifically activated by hand stimulation (DSS-R > DSS-L, masked inclusively by hand > elbow contrast), activation again was found specifically in left postcentral gyrus and bilateral superior parietal cortex. These results indicate that placing the right hand in left space reduced responses to tactile stimuli in somatosensory areas of the intact hemisphere, in parallel with the striking loss of awareness for hand stimuli in these conditions.

To confirm our findings, we also defined an a priori region of interest in the postcentral somatosensory cortex based on a separate hand-localizer scan (passive right-hand stimulation vs rest, in right space). Figure 2C shows the time course of activity in this SI region across the different conditions of the extinction scan. Greater responses to single-hand stimulation and DSS were observed when the right hand was in right space. In contrast, positioning the right hand in the left space suppressed responses in SI to the same tactile stimuli.

For completeness, we also determined areas whose response was independent of hand position (hand > rest, masked exclusively by DSS-R > DSS-L). This showed activation in left parietal operculum (SII), left inferior frontal sulcus, and right posterior parietal cortex (see Table).

Table. Brain Areas Activated in Each Condition

Side	Brain Areas	Coordinates ^a			Z-score ^b
		x	y	z	
Responses to right-hand stimulation (single-hand stimuli > rest)					
L	Parietal operculum (SII) ^c	-68	-26	1	5.33
L	Posterior inferior frontal gyrus	-62	14	25	5.28
L	Postcentral gyrus (SI) ^c	-51	-40	57	5.25
L	Superior occipital gyrus	-25	-81	48	4.86
L	Medial paracentral cortex	-9	-1	53	3.89
L	Posterior parietal cortex ^c	-33	-72	57	3.37
R	Superior parietal cortex	56	-30	49	5.68
R	Paracentral	6	-5	74	4.58
R	Superior parietal (perilesional)	4	-37	66	4.36
R	Parietal operculum (SII) ^c	57	27	17	3.66
Effects of hand position (DSS in right space > DSS in left space)					
L	Anterior middle frontal gyrus	-42	34	19	3.84
L	Postcentral gyrus (SI) ^c	-40	-32	55	3.75
L	Precentral gyrus	-44	-8	46	3.64
L	Superior precentral sulcus	-47	18	50	3.62
L	Posterior parietal cortex ^c	-61	-34	42	3.52
R	Anterior middle frontal gyrus	36	41	23	4.19
R	Superior frontal sulcus	8	60	33	3.50
Responses unaffected by hand position (single-hand stimuli > rest, masked exclusively by DSS-R > DSS-L)					
L	Parietal operculum (SII)	-68	-26	1	5.33
L	Posterior-inferior frontal gyrus	-61	14	32	5.23
R	Posterior parietal cortex	56	-30	50	4.96

^aCoordinates of activation peaks in the patient are converted into the standard normalized MNI space.

^bAll activations $p < 0.001$ at the voxel level, $p < 0.05$ at the cluster level.

^cAlso hand > elbow ($z > 3.11$, $p < .001$).

DSS = double simultaneous stimulation.

Discussion

Our study is the first to our knowledge to show neural correlates for impaired awareness of tactile stimuli on an intact limb, associated with right parietal damage and mild left spatial neglect. Salient tactile stimuli on the right hand were extinguished when this hand was placed in left space, relative to the patient's midline. Such influences of position demonstrate the role of higher spatial coordinates in attention and extinction,^{3,6,7} in the absence of primary sensory loss.

Our fMRI results establish that spatial biases can affect early stages of cortical processing, including primary somatosensory areas. With the right hand in left space, neural responses during DSS decreased in post-central regions corresponding to SI and in superior parietal cortex of the intact left hemisphere, as well as in bilateral prefrontal regions. This supports previous findings in animals¹³ and healthy humans^{11,14} that attentional factors can modulate early sensory areas, including SI and SII. Our findings of greater hand position effects on SI than SII appears also consistent with some suggestions that there might not be a strict serial-hierarchical flow from SI to SII.^{15,16}

A recent positron emission tomography study¹⁷ similarly showed decreased activation in the right primary somatosensory area (SI) of patients with left tactile extinction (both during DSS and unilateral stimulation), raising the possibility of a primary sensory deficit in tactile extinction. Our findings for an intact/ipsilesional limb strongly suggest that primary somatosensory cortex may be influenced by spatial attention and be directly involved in awareness of tactile stimuli.¹⁸ Note that averaged activity in SI cortex as defined by our localizer scan showed that, in left space, even single right-hand stimulation produced smaller fMRI responses, although behaviorally the patient still correctly reported these single right-hand stimuli. This suggests that weaker neural responses in SI for stimuli in contralesional space might lead to their erasure from awareness only in the presence of competing simultaneous stimuli in ipsilesional space, on DSS trials.

Importantly, placing the right hand in left space also decreased responses in left posterior parietal cortex and bilateral middle frontal gyri. These frontal regions may participate to a supramodal representation of space¹⁹ that, together with parietal cortex, integrate tactile inputs with proprioceptive information into body-centered coordinates.^{19,20} Dysfunction in such a spatial representation after right parietal lesion might impair awareness for stimuli processed in intact sensory pathways.

We thank Dr T. Landis and A. Schnider and F. Terrier for their help.

References

1. Vallar G. Spatial frames of reference and somatosensory processing: a neuropsychological perspective. *Philos Trans R Soc Lond B Biol Sci* 1997;352:1401–1409.
2. Ladavas E, di Pellegrino G, Farne A, Zeloni G. Neuropsychological evidence of an integrated visuotactile representation of peripersonal space in humans. *J Cogn Neurosci* 1998;10:581–589.
3. Aglioti S, Smania N, Peru A. Frames of reference for mapping tactile stimuli in brain-damaged patients. *J Cogn Neurosci* 1999;11:67–79.
4. Birch HG, Belmont I, Karp E. Delayed information processing and extinction following cerebral damage. *Brain* 1967;90:113–130.
5. Farah MJ, Monheit MA, Wallace MA. Unconscious perception of “extinguished” visual stimuli: reassessing the evidence. *Neuropsychologia* 1991;29:949–958.
6. Smania N, Aglioti S. Sensory and spatial components of somesthetic deficits following right brain damage. *Neurology* 1995;45:1725–1730.
7. Moscovitch M, Behrmann M. Coding of spatial information in the somatosensory system: evidence from patients with neglect following parietal lobe damage. *J Cogn Neurosci* 1994;6:151–155.
8. Coslett HB, Schwartz MF, Goldberg G, et al. Multi-modal hemispatial deficits after left hemisphere stroke. A disorder of attention? *Brain* 1993;116:527–554.
9. Critchley M. The phenomenon of tactile inattention with special reference to parietal lesions. *Brain* 1949;72:538–561.
10. Friston KJ, Holmes AP, Worsley KJ, et al. Statistical parametric maps in functional imaging: A general linear approach. *Hum Brain Mapp* 1995;2:189–210.
11. Burton H, Sinclair RJ. Attending to and remembering tactile stimuli: a review of brain imaging data and single-neuron responses. *J Clin Neurophysiol* 2000;17:575–591.
12. Paulesu E, Frackowiak RSJ, Bottini G. Maps of somatosensory systems. In: Frackowiak RSJ, Friston KJ, Frith CD, et al., eds. *Human brain functions*. San Diego: Academic Press, 1997:183–242.
13. Hyvarinen J, Poranen A, Jokinen Y. Influence of attentive behavior on neuronal responses to vibration in primary somatosensory cortex of the monkey. *J Neurophysiol* 1980;43:870–882.
14. Hamalainen H, Hiltunen J, Titevskaia I. Activation of somatosensory cortical areas varies with attentional state: an fMRI study. *Behav Brain Res* 2002;135:159–165.
15. Iwamura Y. Hierarchical somatosensory processing. *Curr Opin Neurobiol* 1998;8:522–528.
16. Zhang HQ, Murray GM, Turman AB, et al. Parallel processing in cerebral cortex of the marmoset monkey: effect of reversible SI inactivation on tactile responses in SII. *J Neurophysiol* 1996;76:3633–3655.
17. Remy P, Zilbovicius M, Degos JD, et al. Somatosensory cortical activations are suppressed in patients with tactile extinction: a PET study. *Neurology* 1999;52:571–577.
18. Meador KJ, Ray PG, Echaz JR, et al. Gamma coherence and conscious perception. *Neurology* 2002;59:847–854.
19. Graziano MS. Where is my arm? The relative role of vision and proprioception in the neuronal representation of limb position. *Proc Natl Acad Sci USA* 1999;96:10418–10421.
20. Lloyd DM, Shore DI, Spence C, Calvert GA. Multisensory representation of limb position in human premotor cortex. *Nat Neurosci* 2003;6:17–18.

This work was supported by a Swiss National Science Foundation grant (632-065935, P.V.).