

Retrograde Carotid Stenting for Isolated Stenosis of the Proximal Common Carotid Artery

—Case Report—

Masanori TSUTSUMI, Kiyoshi KAZEKAWA, Tomonobu KODAMA,
Hiroshi AIKAWA, Minoru IKO, and Akira TANAKA

Department of Neurosurgery, Fukuoka University Chikushi Hospital, Chikushino, Fukuoka

Abstract

A 49-year-old female with a history of systemic hypertension and diabetes mellitus suffered transient right hemiparesis. Carotid angiography with arch-aortography detected severe stenosis of the proximal portion of the left common carotid artery. The left carotid bifurcation was surgically exposed and retrograde catheterization was performed to approach the proximal common carotid artery stenosis. The lesion was dilated with a balloon catheter and successfully stented without complications. The left internal carotid artery was clamped during the procedure to avoid embolism. Retrograde carotid stenting for stenosis of the proximal common carotid artery is a safe and effective alternative to conventional surgery in selected patients.

Key words: common carotid artery, stenosis, stent

Introduction

Isolated atherosclerotic lesions of the proximal common carotid artery are relatively rare compared with carotid bifurcation disease, with a reported incidence of only 1.8%.⁸⁾ Selective common carotid artery angiography and carotid ultrasonography may miss more proximal lesions, especially if full examination of the origin of the common carotid artery is not performed.¹⁶⁾ Aortography is more useful for detection of stenosis of the proximal common carotid artery. The natural history of this condition remains unclear, but may cause ischemic stroke, with artery-to-artery embolism or hemodynamic compromise, as may carotid bifurcation stenosis.¹²⁾ Therefore, preventive therapy is recommended. Intrathoracic to cervical bypass operation or endarterectomy were indicated for proximal lesions of the supra-aortic branches including the common carotid artery and the brachiocephalic trunk.⁴⁾ Recently, several less-invasive extrathoracic approaches have come to be preferred.¹⁸⁾ Median sternotomy with direct endotheracic repair is recommended because of the good early and long-term results.^{3-5,11)} Nevertheless, this procedure is not

without risks, such as hemorrhage, embolism, aortic dissection, infection, and death.¹¹⁾ More recently, advances in endovascular technology including percutaneous carotid balloon angioplasty and stenting have resulted in improvement of treatment and safe access for extracranial carotid artery stenosis, and even for proximal common carotid artery stenosis.^{7,10,12-16,19)}

We describe a case of isolated stenosis of the proximal portion of the left common carotid artery treated by retrograde balloon angioplasty and additional stent placement via the exposed common carotid artery with cerebral protection ensured by internal carotid artery clamping.

Case Report

A 49-year-old female with a history of systemic hypertension and diabetes mellitus suffered transient right hemiparesis and was referred to our department. Magnetic resonance imaging revealed an infarction in the left frontal periventricular white matter. Carotid ultrasonography detected decreased flow velocity in the left internal carotid artery but no definite stenosis. Aortography demonstrated severe stenosis of the proximal portion of the left common carotid artery, and carotid angiography showed occlusion of the left external carotid artery (Fig. 1).

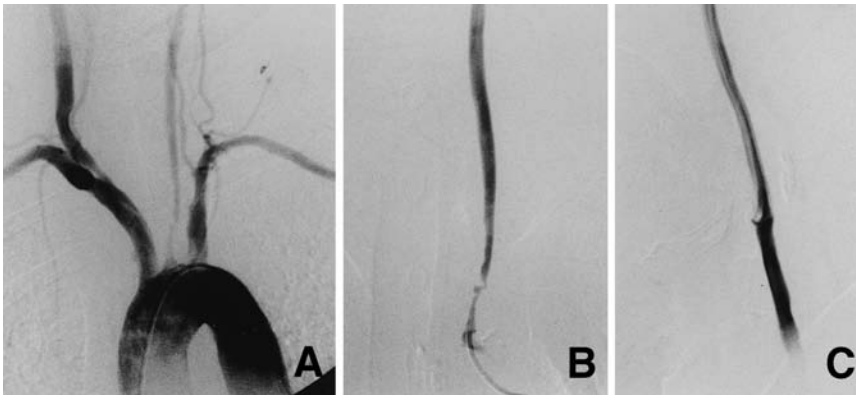


Fig. 1 Preoperative aortogram (A) demonstrating severe stenosis of the left common carotid artery in the supra-aortic portion. Frontal (B) and lateral (C) left common carotid angiograms revealing occlusion of the external carotid artery.

Selective left common carotid angiography failed because the 0.032-inch guidewire could not pass through the left common carotid stenosis. The internal carotid artery territory was perfused by collateral flow via the anterior communicating artery and the ipsilateral posterior communicating artery. Xenon computed tomography demonstrated normal perfusion at rest and marked reduction of perfusion after acetazolamide challenge in all territories of the left internal carotid artery. We believed that the symptoms to be caused by artery-to-artery embolism and decided to perform carotid stenting to prevent further stroke. The procedures performed were in accordance with ethical standards of the institutional Ethics Committee, and informed consent was obtained after full explanation to the patient. Aspirin and ticlopidine hydrochloride were administered for 14 days before angioplasty.

The patient was taken to the neuroangiography suite, and general endotracheal anesthesia was initiated. A 4-French sheath was percutaneously placed in the right femoral artery for intraoperative angiography. The left common carotid artery and carotid bifurcation were exposed in a manner similar to standard carotid endarterectomy. The left internal carotid artery was clamped, and a 7-French sheath was inserted into the left common carotid artery in the retrograde direction under fluoroscopic guidance (Fig. 2). Activated clotting time was then maintained between 200 and 250 seconds throughout the procedure by injection of heparin. A 0.014-inch Essence 300-cm guidewire (Cordis, Miami Lakes, Fla., U.S.A.) passed through the stenosis without difficulty. A 6 × 40-mm Smash percutaneous transluminal angioplasty balloon catheter (Boston Scientific, Fremont, Calif., U.S.A.) was navigated across the stenosis and balloon angioplasty was successfully performed. The balloon catheter was exchanged for an 8 × 30-mm Easy Wallstent (Boston Scientific), which was deployed without

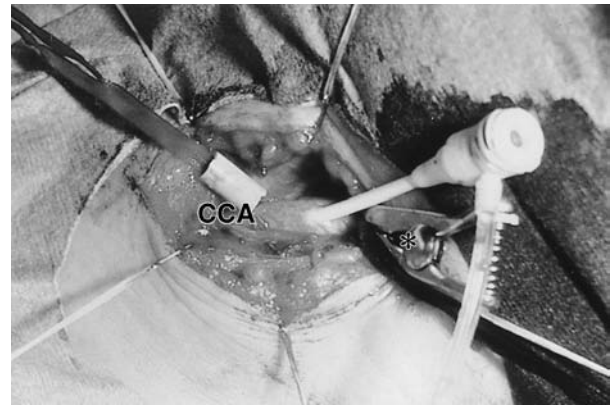


Fig. 2 Intraoperative photograph showing retrograde cannulation of a 7-French sheath into the common carotid artery (CCA). The asterisk indicates the clamped left internal carotid artery.

difficulty. Postdilation was not performed. Aortography and left carotid angiography obtained after the procedure revealed excellent dilation of the left common carotid artery, normalization of blood flow in the left internal carotid artery, and recanalization of the external carotid artery (Fig. 3). The sheath was removed and pooled blood and debris were flushed out via the arteriotomy. The arteriotomy site was closed by suturing with 6-0 nylon. Heparinization was discontinued immediately but not reversed.

The postoperative course was uneventful. The patient continued to receive aspirin and ticlopidine hydrochloride. Follow-up angiography at 6 months demonstrated excellent dilation of the treated site of the common carotid artery.

Discussion

The transfemoral route is used in most cases for the endovascular treatment of carotid artery stenosis.

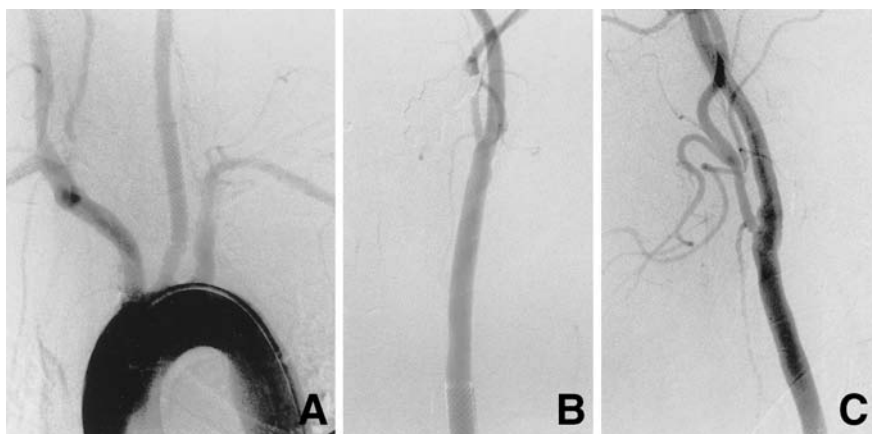


Fig. 3 Postoperative aortogram (A) demonstrating excellent dilation of the left common carotid artery in the supra-aortic portion. Frontal (B) and lateral (C) left common carotid angiograms revealing normal flow in the distal portion of the common carotid artery and internal carotid artery. Note the recanalization of the external carotid artery.

However, transfemoral intervention is difficult in 1–2% of cases due to elongation of the aortic arch, the brachiocephalic trunk, or the carotid artery.²⁰⁾ Under these conditions, alternative vascular access routes can be used, such as the brachial artery, the transseptal route, or the direct carotid route using the carotid artery.^{7,9,17,20)} In the present case, catheterization of a narrow origin of the common carotid artery was technically difficult and carried the risk of embolization, so we used the direct transcrotid approach.

The combined use of carotid endarterectomy and retrograde angioplasty with or without stenting is effective and safe performed via an arteriotomy.^{12,14–16)} In the present case, retrograde carotid stenting by percutaneous direct carotid puncture was considered possible. Carotid stenting requires strong anticoagulation and antiplatelet therapy. Under such conditions, sheath removal exposes patients to the risk of neck hematoma and tracheal compression, with significant increase in morbidity, if manual compression is not sufficient. Recently, percutaneous hemostatic devices have reduced the time to hemostasis, and have been applied for hemostasis after carotid artery puncture.¹⁾ However, these devices are not perfect and have potential complications including hematoma, thrombosis, pseudoaneurysm, infection, and arteriovenous fistula.^{2,8)} Therefore, we exposed the carotid bifurcation and sutured arteriotomy site to achieve definite and quick hemostasis, and avoid cervical hematoma and prolonged manual carotid compression. Another special advantage of this method is protection against embolism, a significant complication of carotid angioplasty and stenting, by clamping of the internal carotid artery during the procedure.¹⁶⁾

The present case of isolated stenosis of the proximal portion of the left common carotid artery was treated by retrograde balloon angioplasty and stent-

ing via the exposed common carotid artery with cerebral protection ensured by internal carotid artery clamping. We believe this technique to be a safe and effective alternative to conventional surgery, especially if use of the transfemoral approach is difficult. However, the ultimate clinical role of this technique remains to be determined.

References

- 1) Blanc R, Mounayer C, Piotin M, Sadik JC, Spelle L, Moret J: Hemostatic closure device after carotid puncture for stent and coil placement in an intracranial aneurysm: technical note. *AJNR Am J Neuroradiol* 23: 978–981, 2002
- 2) Carey D, Martin JR, Moore CA, Valentine MC, Nygaard TW: Complications of femoral artery closure devices. *Catheter Cardiovasc Interv* 52: 3–8, 2001
- 3) Cormier F, Ward A, Cormier JM, Laurian C: Long-term results of aortoinnominate and aortocarotid polytetrafluoroethylene bypass grafting for atherosclerotic lesions. *J Vasc Surg* 10: 135–142, 1989
- 4) Crawford ES, De Bakey ME, Morris GC Jr, Howell JF: Surgical treatment of occlusion of the innominate, common carotid, and subclavian arteries: a 10 year experience. *Surgery* 65: 17–31, 1969
- 5) Crawford ES, Stowe CL, Powers RW Jr: Occlusion of the innominate, common carotid, and subclavian arteries: long-term results of surgical treatment. *Surgery* 94: 781–791, 1983
- 6) Diethrich EB, Marx P, Wrasper R, Reid DB: Percutaneous techniques for endoluminal carotid interventions. *J Endovasc Surg* 3: 182–202, 1996
- 7) Diethrich EB, Ndiaye M, Reid DB: Stenting in the carotid artery: initial experience in 110 patients. *J Endovasc Surg* 3: 42–62, 1996
- 8) Eidt JF, Habibipour S, Saucedo JF, McKee J, Southern F, Barone GW, Talley JD, Moursi M: Surgical complications from hemostatic puncture closure devices. *Am J Surg* 178: 511–516, 1999
- 9) Joseph G, Krishnaswami S, Baruah DK,

- Kuruttukulam SV, Abraham OC: Transseptal approach to aortography and carotid artery stenting in pulseless disease. *Cathet Cardiovasc Diagn* 40: 416-421, 1997
- 10) Kachel R, Basche S, Heerklotz I, Grossmann K, Endler S: Percutaneous transluminal angioplasty (PTA) of supra-aortic arteries especially the internal carotid artery. *Neuroradiology* 33: 191-194, 1991
 - 11) Kieffer E, Sabatier J, Koskas F, Bahnini A: Atherosclerotic innominate artery occlusive disease: early and long-term results of surgical reconstruction. *J Vasc Surg* 21: 326-337, 1995
 - 12) Levien LJ, Benn CA, Veller MG, Fritz VU: Retrograde balloon angioplasty of brachiocephalic or common carotid artery stenoses at the time of carotid endarterectomy. *Eur J Vasc Endovasc Surg* 15: 521-527, 1998
 - 13) Mori T, Arisawa M, Honda S, Fukuoka M, Mori K: Percutaneous transluminal angioplasty of supra-aortic arterial stenoses in patients with concomitant cerebrovascular and coronary artery diseases. Report of two cases. *Neurol Med Chir (Tokyo)* 33: 368-372, 1993
 - 14) Pappada G, Marina R, Fiori L, Carozzi C, Taho A, Petri D, Sganzerla E, Gaini SM: Surgery and stenting as combined treatment of a symptomatic tandem stenosis of the carotid artery. *Acta Neurochir (Wien)* 141: 1177-1181, 1999
 - 15) Ruebben A, Tettoni S, Muratore P, Rossato D, Savio D, Conforti M, Nessi F, Rabbia C: Feasibility of intraoperative balloon angioplasty and additional stent placement of isolated stenosis of the brachiocephalic trunk. *J Thorac Cardiovasc Surg* 115: 1316-1320, 1998
 - 16) Sidhu PS, Morgan MB, Walters HL, Baskerville PA, Fraser SC: Technical report: Combined carotid bifurcation endarterectomy and intra-operative transluminal angioplasty of a proximal common carotid artery stenosis: an alternative to extrathoracic bypass. *Clin Radiol* 53: 444-447, 1998
 - 17) Sievert H, Ensslen R, Fach A, Merle H, Rubel C, Spies H, Sultan N, Beykirch KF, Theis R, Schultze HJ: Brachial artery approach for transluminal angioplasty of the internal carotid artery. *Cathet Cardiovasc Diagn* 39: 421-423, 1996
 - 18) Thompson JE, Garrett WV: Peripheral-arterial surgery. *N Engl J Med* 302: 491-503, 1980
 - 19) Vitek JJ, Keller FS, Duvall ER, Gupta KL, Chandra-Sekar B: Brachiocephalic artery dilation by percutaneous transluminal angioplasty. *Radiology* 158: 779-785, 1986
 - 20) Yoo BS, Lee SH, Kim JY, Lee HH, Ko JY, Lee BK, Hwang SO, Choe KH, Yoon J: A case of transradial carotid stenting in a patient with total occlusion of distal abdominal aorta. *Catheter Cardiovasc Interv* 56: 243-245, 2002
-
- Address reprint requests to: M. Tsutsumi, M.D., Department of Neurosurgery, Fukuoka University Chikushi Hospital, 377-1 Ohaza-Zokumyoin, Chikushino, Fukuoka 818-8502, Japan.
e-mail: tsutsumi@fukuoka-u.ac.jp