

Successful stent placement for cervical artery dissection associated with the Ehlers–Danlos syndrome

Case report and review of the literature

AKIRA KURATA, M.D., HIDEHIRO OKA, M.D., TAKETOMO OHMOMO, M.D., HITOSHI OZAWA, M.D., SACHIO SUZUKI, M.D., KIYOTAKA FUJII, M.D., SHINICHI KAN, M.D., YOSHIO MIYASAKA, M.D., AND HARUE ARAI, M.D.

Departments of Neurosurgery, Radiology, and Dermatology, Kitasato University School of Medicine, and Yamato Municipal Hospital, Kanagawa, Japan

✓ This 44-year-old man with Ehlers–Danlos syndrome (EDS) Type IV presented with hemiparesis and the Gerstmann syndrome. Left carotid artery (CA) angiography revealed a dissecting aneurysm with severe stenosis located in the common CA; the lesion was successfully treated with a stent graft. The patient's clinical course after endovascular surgery was uneventful, without occurrence of megacolon. The literature for spontaneous CA dissection in EDS Type IV cases is reviewed and points for investigation and treatment are discussed.

KEY WORDS • Ehlers–Danlos syndrome • dissection • carotid artery • stent • endovascular surgery

EHLERS–DANLOS syndrome is a rare autosomal–dominant hereditary disease,¹⁵ with approximately 50% of cases occurring because of spontaneous mutation.¹ Vascular complications are the main cause of catastrophic events;^{1,13} the second most common complication is intestinal perforation in young patients.¹³ Complications are especially frequent in patients with EDS Type IV (a vascular type), which is characterized by a major abnormality in collagen Type III that constitutes approximately 40% of the vascular wall⁸ so that fragility results.

The most common neurovascular complication in EDS Type IV cases is the spontaneous direct CCF.^{1,2,4,6,7,14} Carotid artery dissection, fistula formation, and intracranial aneurysm rupture are other typical disorders. All of these vascular complications are very life-threatening. Nevertheless, diagnostic angiography,^{3,4,14} endovascular surgery,^{4,6,14} and surgical intervention³ should be avoided if at all possible because of associated high morbidity and mortality rates.^{2–5,14}

Case Report

History and Examination. This 44-year-old man reported weakness of the right arm 2 hours after playing tennis. This symptom was followed by disturbance of consciousness,

Abbreviations used in this paper: CA = carotid artery; CBF = cerebral blood flow; CCA = common CA; CCF = carotid–cavernous fistula; CT = computerized tomography; EDS = Ehlers–Danlos syndrome; FA = femoral artery; ICA = internal CA; IMP SPECT = inosine 5'-monophosphate single-photon emission CT; MR = magnetic resonance; VA = vertebral artery.

and the patient was therefore immediately transported to a local hospital. On admission, he exhibited mild disturbance of consciousness, aphasia, the Gerstmann syndrome, and right hemiparesis. Admission CT scans revealed watershed infarction in the left parietal lobe beyond the left posterior horn (Fig. 1). On MR angiography a pearl-and-string appearance of the left CCA was demonstrated, and aortography revealed a dissection (Fig. 2 *left*). The remaining bilateral ICAs, external CAs, and intracranial CAs were nor-

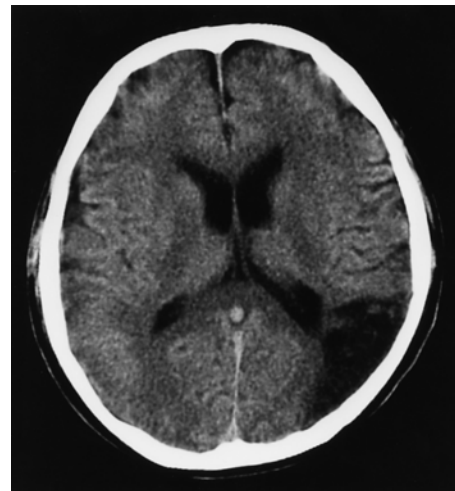


FIG. 1. Axial CT scan revealing a low-density area in the left frontoparietal lobe.

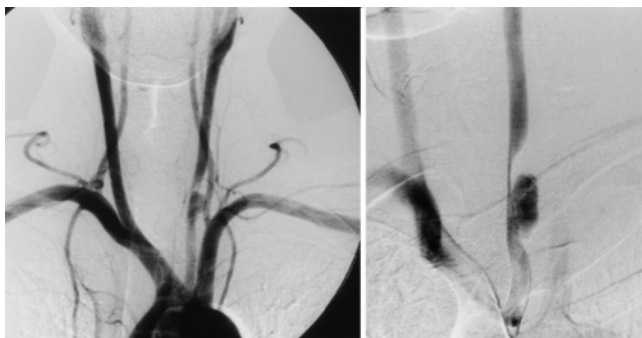


FIG. 2. *Left:* Aortogram revealing stenosis associated with aneurysm formation in the left CCA. *Right:* Follow-up aortogram demonstrating aggravation of the dissecting aneurysm, with severe stenosis (> 90%) of the left CCA.

mal. The facial appearance of the patient was compatible with EDS (prominent eyes, lobeless ears and thin lips, along with hyperextensible skin, evident since childhood). His father and elder brother demonstrated the same features, and a clinical diagnosis of EDS was made. The patient and his family had no history of easy bruising or vascular events, but histological examination of a skin biopsy sample showed changes compatible with EDS Type IV, with findings of fragmented elastic fibers and disarrangement of collagen. The small arteries exhibited disruption of internal elastic membranes (Fig. 3).

Follow-Up Diagnostic Testing. Fortunately, the clinical symptoms gradually improved and disappeared 1 month after the event. The patient was then referred to our hospital.

Follow-up angiography performed 1 month after the event revealed aggravation of the dissecting aneurysm, with severe stenosis of the left CCA of more than 90% (Fig. 2 *right*). A ^{123}I -IMP SPECT study demonstrated a decrease in CBF beyond the infarction. The extensive decrease in CBF involving the dominant left temporal lobe pointed to a high risk of reinfarction (Fig. 4 *left*), and therefore stent placement was selected for reconstruction of the left CCA and prevention of aneurysm rupture, despite the inherent danger in this procedure.

Operation. Aspirin (81 mg) and ticlopidine hydrochloride (200 mg) had already been started 2 weeks before endovascular surgery. Preoperatively, the activated coagulation time was assessed as a control value through a No. 6 French sheath placed in the left FA, followed by a bolus injection of 2000 U heparin. During endovascular surgery, heparin was continuously infused to maintain an activated coagulation time of two to three times the control value. Gentle manipulation of and predilation with a Commodore balloon catheter (Cordis; Johnson & Johnson Medical, Arlington, TX) inserted through a No. 6 French Envoy catheter (Cordis) introduced in the left FA sheath resulted in establishment of a diameter of 1.3 to 4 mm.

A shuttle sheath (No. 7 French) with a coaxial system (Cook, Inc., Bloomington, IN) introduced through the right FA was placed in a proximal portion of the left CCA, preceding a No. 5–7 French catheter (Meditech; Boston Scientific Co., Watertown, MA). The length of dissection was measured and found to be greater than 3.5 cm. To cover the site, with additional 10-mm overlaps of the proximal and distal normal vessel walls, a 6-cm-long, 8-mm-diameter stent (Easy Wall; Boston Scientific Co.) was selected and

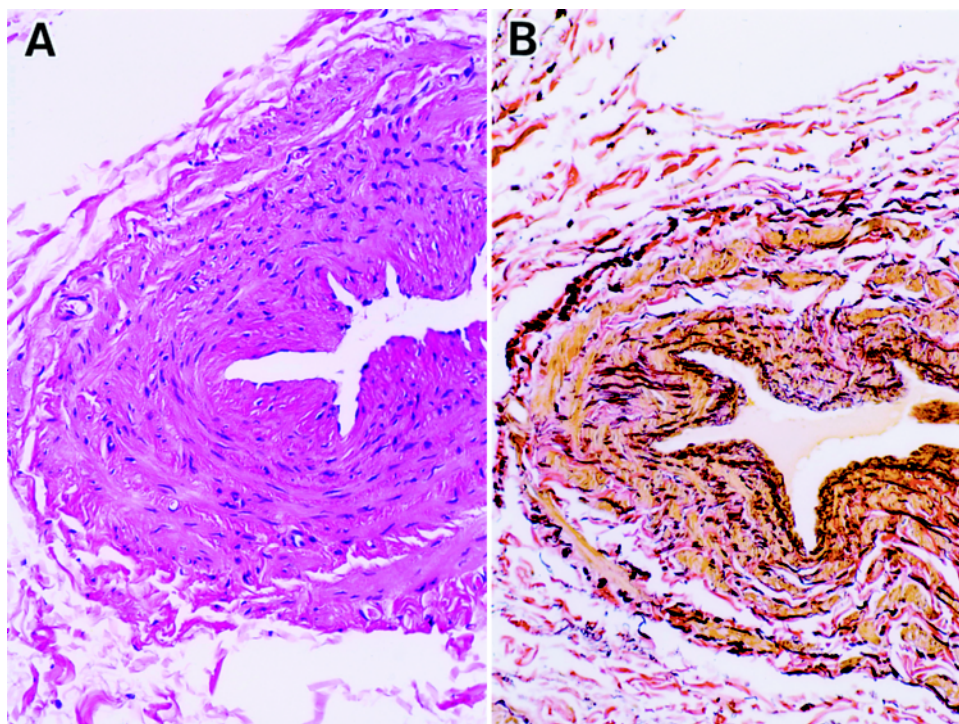


FIG. 3. Photomicrographs revealing fragmentation of elastic fibers and disarrangement of collagen fibers. The small arteries show disruption of the internal elastic membranes. H & E (A), van Gieson elastic (B). Original magnifications $\times 400$.

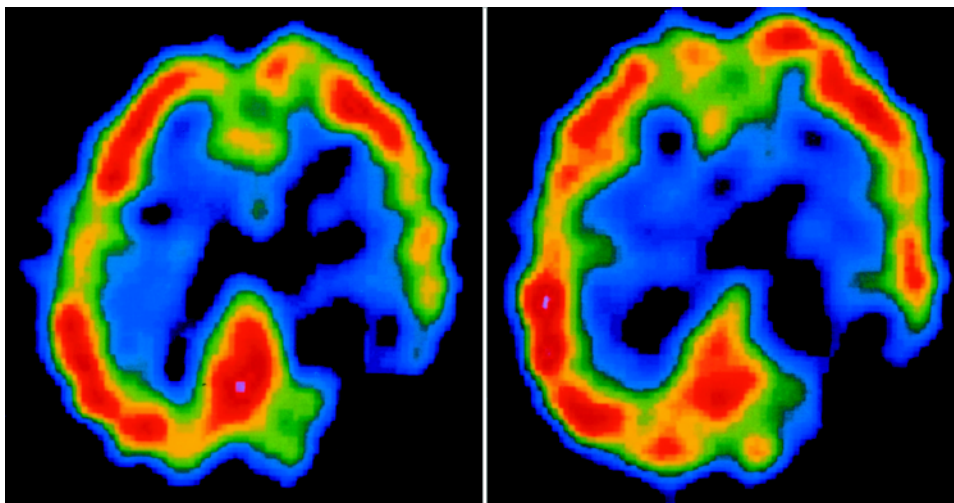


FIG. 4. *Left:* A ^{123}I -IMP SPECT scan revealing an extensive decrease in CBF in the left temporoparietal lobe. *Right:* A ^{123}I -IMP SPECT scan obtained after treatment, demonstrating an increase in CBF in the temporal lobe.

placed in the center of the dissection site. Finally, postdilation, less than 2 atm for 10 seconds, was added by the Power Flex Plus balloon catheter (Cordis) (Fig. 5). Heparinization was continued for 2 days after endovascular surgery to maintain two to three times the control activated coagulation time.

Postoperative Course. The postoperative course was uneventful and the patient was discharged 3 days after the procedure. A ^{123}I -IMP SPECT study performed 9 days post-treatment demonstrated an improvement in the CBF in the left temporal lobe (Fig. 4 *right*). A follow-up echogram obtained 3 months afterward demonstrated good blood flow with no stenosis of the artery, and the aneurysm had disappeared. Aspirin (81 mg) and ticlopidine hydrochloride (200 mg) were continued, and 4 months after the procedure a neurological examination revealed no abnormality. Follow-up MR angiography performed 6 months posttreatment demonstrated artifacts at the proximal and distal ends of the stent in the left CCA (Fig. 6A). Digital subtraction angiography performed 7 months after stent placement demonstrated good blood flow through the left CCA, with no dissecting aneurysm (Fig. 6B).

The clinical course 1 year and 2 months after the procedure was still uneventful. The patient experienced mild constipation, and a diagnosis of megacolon caused by EDS was made.

Discussion

Freeman, et al.,³ reviewed the cases of 18 patients with EDS Type IV who underwent angiography: four (22%) suffered major complications and one (5.6%) died. Schievink, et al.,¹⁴ reported a 36% morbidity with 12% mortality rate after diagnostic angiography, and a 17% death rate after interventional therapy. In the series by Halbach, et al.,⁴ 50% of four patients with EDS Type IV accompanied by direct CCF demonstrated major morbidity and 25% died. Massive, untreatable hemorrhage at the puncture site; vascular perforation; and dissection of the major vessels are major complications of angiography and endovascular surgery.

Freeman, et al.,³ reviewed 45 vascular complications in patients with EDS Type IV. These complications caused death in 12 patients (30%), seven of whom had been treated with arterial reconstruction. These authors concluded that surgical intervention, when required, should focus on simple vessel ligation rather than reconstruction, which generally fails because of the poor tensile strength in the vessel. Angiographic and surgical complications are related to the fragility of the vascular wall and subcutaneous connective tissue in patients with EDS.

When performing angiography and endovascular surgery careful insertion and manipulation of the smallest possible soft-tipped angiographic catheter may decrease some of the risk. In our case, a shuttle sheath featuring a coaxial system with a soft tip (6-cm length) and large lumen (No. 7 French) allowed satisfactory placement of a stent.

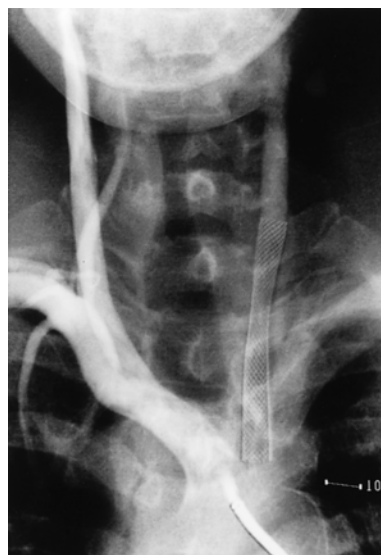

FIG. 5. Aortogram obtained after stent placement, demonstrating good blood flow through the left CCA and a decrease in blood flow to the dissecting aneurysm.

TABLE 1

*Literature review of spontaneous dissections in cervical arteries in patients with EDS syndrome, Type IV**

Authors & Year	Patient Age (yrs), Sex	Location of Lesion	Presenting Symptoms	Investigations/ Treatment	Complications	Outcome
Ruby, et al., 1989	45, F	lt ICA	TIA	angiogram/ ligation	none	resolved
Schievink, et al., 1990	16, F	rt ICA	TIA	angiogram/ aspirin	none	resolved
Schievink, et al., 1991	20, F	rt ICA	orbital pain, thumping noise	angiogram	hematoma at puncture site	resolved
North, et al., 1995	30, NA	CA	headache, rt hemiparesis	angiogram/ warfarin	NA	resolved
	17, NA	ICA	NA	Doppler ultrasonography	NA	resolved
	48, NA	bilat ICA	NA	NA	NA	NA
present study	49, M	lt CCA	rt hemiparesis, Gerstmann syndrome	angiogram/ stent insertion	none	resolved

* NA = not available; TIA = transient ischemic attack.

Literature Review

Spontaneous arterial dissections of extracranial ICAs and VAs are well-known complications of EDS, and were recently recognized as frequent features of EDS Type IV.¹³ Dissections of the cervical arteries also may be iatrogenic and may occur after angiography in patients with EDS Type IV. Nevertheless, spontaneous lesions have recognizable features. Six patients with EDS Type IV and spontaneous CA dissection have previously been identified in the literature,^{9,11,12,14} but underdiagnosis is probable. Spontaneous dissection may be the underlying pathogenic mechanism for spontaneous CCF and aneurysms in the cervical vessels. Pope, et al.,¹⁰ reported on a 45-year-old woman with marked tortuosity and ectasia of the ICA who presented with spontaneous CCF. Halbach, et al.,⁴ reported that in all

four cases of spontaneous CCF in EDS Type IV there was marked ectasia and pseudoaneurysm formation involving the CA proximal to the fistula. In two of these patients, the contralateral CA showed the same changes, leading to speculation that weak ectatic arteries may develop dissecting aneurysms or spontaneous rupture without antecedent aneurysm formation.

The clinical features of the six previously reported cases and our patient are summarized in Table 1. Three were women, ours was a man, and no sex was given for the other three patients; a mean age of 31 years (range 16–49 years) was reported. The left side was involved in two, the right side in two, lesions were bilateral in one, and the side was not given in two.

In 1989, Ruby, et al.,¹¹ reported on the first well-documented case of a dissecting aneurysm of the cervical segment of the ICA in a patient with EDS Type IV, in whom there was a 5-month history of transient blindness in the left eye, and who was successfully treated with ligation of the left ICA. One year later, Schievink, et al.,¹² described a 16-year-old woman who presented with left facial weakness and right ICA dissection, in whom EDS Type IV was diagnosed. In another case involving a 20-year-old woman, a right-sided, spontaneous CCF arising from a left-sided, spontaneous CCF was treated with ligation of the left ICA. The location of the lesion just proximal to the CA canal indicated that it was most likely due to the previous ICA dissection, with arterial dissection in the ectatic extracranial portion of the left VA.

In our patient, only the left CCA was involved; arteriograms of the other intra- and extracranial vessels revealed normal findings. We believe that this is the first report of spontaneous dissection of the CCA in EDS. Tennis playing may have had a role in causing the dissection in our patient.

Imaging Modalities and Treatment

Angiography has been reported to be contraindicated unless absolutely essential for adequate treatment, and non-invasive investigative methods such as Doppler ultrasonography, MR angiography, CT scanning, and intravenous

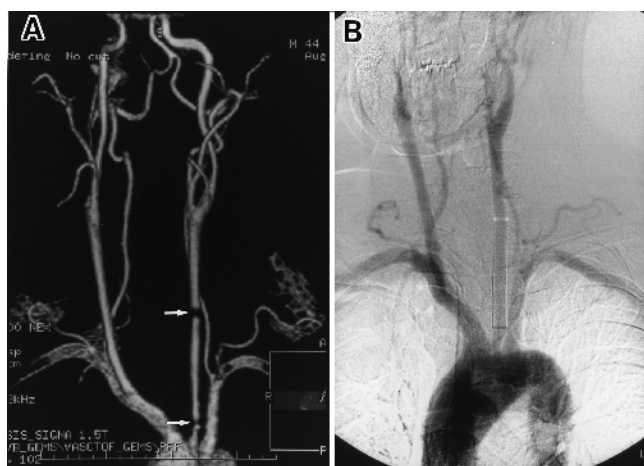


FIG. 6. A: Follow-up MR angiogram obtained 6 months post-treatment, demonstrating artifacts (arrows) at the proximal and distal ends of the stent in the left CCA. B: Follow-up intravenous digital subtraction angiogram obtained 7 months after the procedure, demonstrating patency of the left CCA and disappearance of the dissecting aneurysm.

Stent placement for cervical artery dissection in EDS

angiography should be given preference. Extremely conservative treatment is recommended.

In our case, however, progressive, severe stenosis with more than 90% occlusion meant a high risk of ischemic attack. An extensive decrease in CBF beyond the infarct also required reconstruction of the left CCA. Furthermore, the dissecting aneurysm appeared to be worsening with time, and there was a distinct possibility of rupture. Halbach, et al.,⁴ emphasized that maintaining patency of cerebral vessels is a high priority in EDS, because occurrence of contralateral arterial dissection and CCF after ligation is a known complication. Schoolman and Kepes¹⁵ reported on a patient with a spontaneous left-sided CCF caused by EDS in whom a contralateral CCF developed 2 hours after ligation of the left CA.

To our knowledge, stent placement for the treatment of CA dissection in EDS Type IV has not been previously reported. Horowitz, et al.,⁵ described a 40-year-old woman suffering from the disease in whom arteriovenous shunts of bilateral VAs were treated with stents, but she died of iliac artery perforation and active retroperitoneal bleeding.

At stent placement, a large luminal catheter and sheath are essential for introduction of the device. Using conventional sheaths and catheters, a No. 9 French inner diameter of sheath (outer diameter > No. 10 French) and a No. 9 French catheter with an inner diameter of at least No. 7 French are needed. In contrast, as in our case, a shuttle sheath (Cook, Inc.) in which a coaxial system is used has the advantage of a small external diameter (No. 8.6 French) with a large lumen (No. 7.7 French) and a soft tip (6-cm length). During angiography and endovascular surgery, careful insertion and manipulation of the smallest possible soft-tipped angiographic catheter is essential to decrease the risk of catastrophic events in EDS Type IV cases.

After placement of metallic stents, various artifacts may be observed on MR angiography, especially at the proximal and distal edges. After stent placement in EDS, follow-up studies should be performed using intravenous digital subtraction angiography because of the good visualization and relative lack of invasiveness associated with this modality.

References

1. Bergqvist D: Ehlers-Danlos type IV syndrome. A review from a vascular surgical point of view. **Eur J Surg** **162**:163–170, 1996
2. Forlodou P, Kersaint-Gilly A, Pizzanelli J, et al: Ehlers-Danlos

syndrome with a spontaneous carotidocavernous fistula occluded by detachable balloon: case report and review. **Neuroradiol** **38**:595–597, 1996

3. Freeman RK, Swegle J, Sise MJ: The surgical complications of Ehlers-Danlos syndrome. **Am Surg** **62**:869–873, 1996
4. Halbach VV, Higashida RT, Dowd CF, et al: Treatment of carotid-cavernous fistulas associated with Ehlers-Danlos syndrome. **Neurosurgery** **26**:1021–1027, 1990
5. Horowitz MB, Purdy PD, Valentine RJ, et al: Remote vascular catastrophes after neurovascular interventional therapy for type 4 Ehlers-Danlos syndrome. **AJNR** **21**:974–976, 2000
6. Kanner AA, Maimon S, Rappaport ZH: Treatment of spontaneous carotid-cavernous fistula in Ehlers-Danlos syndrome by transvenous occlusion with Guglielmi detachable coils. Case report and review of the literature. **J Neurosurg** **93**:689–692, 2000
7. Lach B, Nair SG, Russell NA, et al: Spontaneous carotid-cavernous fistula and multiple arterial dissections in type IV Ehlers-Danlos syndrome. Case report. **J Neurosurg** **66**:462–467, 1987
8. Mayne R: Vascular connective tissue. Normal biology and derangement in human diseases, in Uitto J, Perejda AJ (eds): **Connective Tissue Disease. Molecular Pathology of the Extracellular Matrix**. New York: Marcel Dekker, 1987, pp 163–183
9. North KN, Whiteman DAH, Pepin MG, et al: Cerebrovascular complications in Ehlers-Danlos syndrome. **Ann Neurol** **38**:960–964, 1995
10. Rope FM, Kendall BE, Slapak GI, et al: Type III collagen mutations cause fragile cerebral arteries. **Br J Neurosurg** **5**:551–574, 1991
11. Ruby ST, Kramer J, Cassidy SB, et al: Internal carotid artery aneurysm: a vascular manifestation of type IV Ehlers-Danlos syndrome. **Conn Med** **53**:142–144, 1989
12. Schievink WI, Limburg M, Oorthuys JWE, et al: Cerebrovascular disease in Ehlers-Danlos syndrome type IV. **Stroke** **21**:626–632, 1990
13. Schievink WI, Michels VV, Piepgras DG: Neurovascular manifestations of heritable connective tissue disorders. A review. **Stroke** **25**:889–903, 1994
14. Schievink WI, Piepgras DG, Earnest F IV, et al: Spontaneous carotid-cavernous fistulae in Ehlers-Danlos syndrome Type IV. Case report. **J Neurosurg** **74**:991–998, 1991
15. Shoolman A, Kepes J: Bilateral spontaneous carotid-cavernous fistulae in Ehlers-Danlos syndrome. Case report. **J Neurosurg** **26**:82–86, 1967

Manuscript received March 3, 2003.

Accepted in final form August 1, 2003.

Address reprint requests to: Akita Kurata, M.D., Department of Neurosurgery, Kitasato University School of Medicine, 1-15-1 Kitasato, Sagamihara, Kanagawa, Japan. email: akirak@med.kitasato-u.ac.jp.