

Brief Report of Special Case

A glioma with an arteriovenous malformation: an association or a different entity?

I. M. Ziyal¹, K. Ece¹, B. Bilginer¹, G. G. Tezel², and O. E. Özcan¹

¹ Department of Neurosurgery, Hacettepe University, Faculty of Medicine, Ankara, Turkey

² Department of Pathology, Hacettepe University, Faculty of Medicine, Ankara, Turkey

Published online December 5, 2003

© Springer-Verlag 2003

Case report

A 58-year-old male was admitted with headache to our neurosurgery clinic. His neurological examination revealed slight left hemiparesis. The radiological evaluation with contrast administered magnetic resonance imaging (MRI) scan demonstrated a right temporo-parietal ring enhancing mass lesion surrounded by edema which was resembling a typical glioma (Fig. 1). The patient was operated on via a temporo-parietal craniotomy and an arteriovenous malformation surrounded by abnormal glial tissue was observed during the exposure. A nidus supplied by several branches arising from the middle cerebral artery (MCA) was obvious. The venous drainage of the malformation was to the superficial venous system. The observed arterial feeders and the draining vein were coagulated and the nidus was macroscopically totally excised. The frozen examination from surrounding glial tissue revealed a high grade glioma. The tumor was also macroscopically totally excised. Postoperatively, the cerebral angiogram demonstrated a right temporal arteriovenous malformation with a centrally excised nidus. The remaining major feeders involved the angular gyrus and the posterior temporal arteries. The venous drainage was to the straight and sigmoid sinuses (Fig. 2). The final histopathological examination of the specimen revealed an arteriovenous malformation surrounded by a high grade glioma (Fig. 3). The patient refused a second operation for total removal of the AVM. Postoperatively, he is doing well with improvement of his left hemiparesis.

Discussion

The association of intracranial AVMs with brain tumors is 0.1%. This incidence was reported at the time when computed tomographic (CT) scan was popular and was the only imaging technique for intracranial lesions [5]. After clinical use of advanced neuro-imaging techniques, the accurate diagnosis rate between similar pathological conditions and the rate of association of several pathologies between each other have increased.

The differential diagnosis of most tumor cases with MRI scan is so successful that an additional cerebral angiography investigation to exclude a vascular malformation is frequently not undertaken.

Among the tumors associated with an AVM, gliomas are more common [4–8]. The term angioglioma is a histological term and represents simply a low grade highly vascular glioma. It must not be confused with gliomas of high grade malignancy [6]. Actually, Tönnis was the first to describe the similarities between brain tumors and vascular malformations [2]. However, the association of gliomas with vascular malformations is a different entity. Whether this association is a coexistence of individual lesions or not, is still open to discussion [8, 9]. The AVM and the glioma may be intermixed or adjacent [2]. Induction of acquired AVM by anaplastic astrocytoma has also been considered [3]. It was also speculated that there might be secondary neoplastic changes in the perivascular glial tissue in response to the vascular malformation [5, 9]. However, cases in the literature are too few to come to a conclusion regarding the etiology.

If the patient presents with hemorrhage, it is essential to perform preoperative angiography. In these cases, the association of a tumor may be established during the operation [2, 5–7, 9]. Cases with obvious radiological appearance of tumor preoperatively and establishment of the association of an AVM intraoperatively is very rare [1]. Our case admitted with symptoms and signs of a

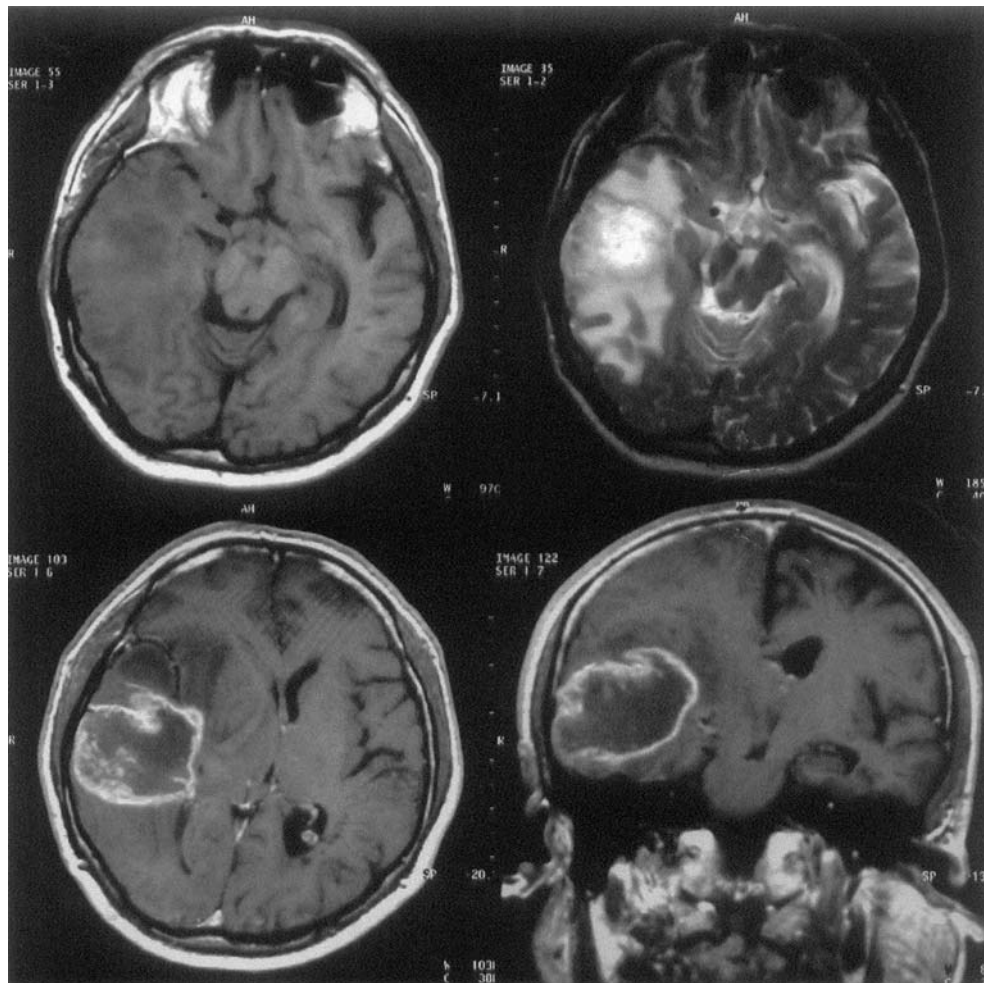


Fig. 1. T1-weighted axial, T2-weighted axial, and T1 weighted axial and coronal images with contrast administration of a 58-year-old male revealed a right temporo-parietal mass lesion which resembled a typical glioma

mass lesion and no hemorrhage was observed during our radiological evaluation. Because the appearance of the MRI scan resembled a glial neoplasm and there was no evidence of hemorrhage, we did not plan a preoperative angiography.

Surgical planning of such cases should be performed according to which lesion is responsible from the patient's presenting symptoms. The resection of the malformation may not be indicated when the tumor is malignant because the median survival time is short and the risk of hemorrhage is approximately 2% per year. In our case, our initial preoperative planning was for a gross total removal of the tumor. However, during the operation we observed and tried to remove the AVM

with the tumor as totally as possible. Because of technical difficulties it was not possible for us to perform angiography during the operation. It is absolutely necessary to perform intraoperative angiography in such cases. Routine preoperative angiography for brain tumors will also give us the precise information not only about the tumor itself, but also the vascularity and displacement of normal vessels. In that way, an association of an AVM with a brain tumor can be demonstrated preoperatively.

In conclusion, the association of tumors and vascular malformations should always be taken into consideration and preoperative angiography should be performed in selected cases.

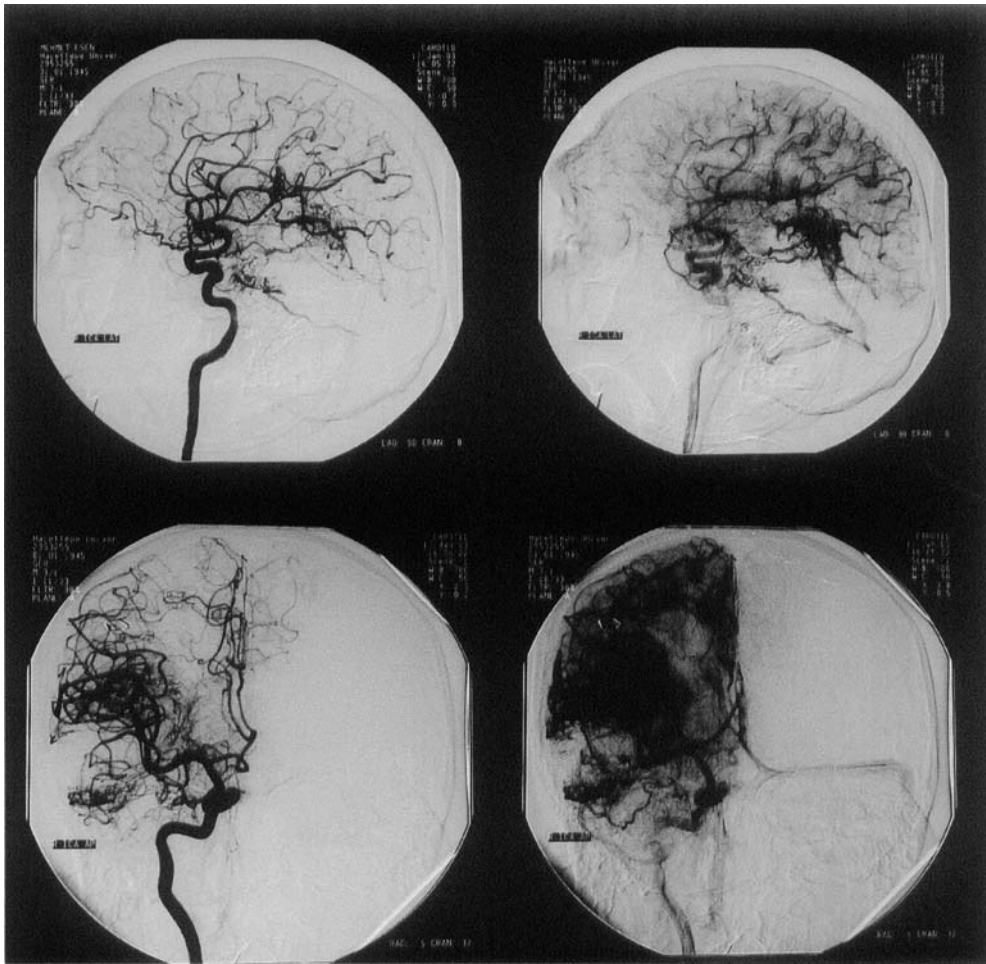


Fig. 2. The postoperative cerebral angiogram demonstrated a right temporal arteriovenous malformation with a centrally excised nidus. It was supplied by the angular gyrus and the posterior temporal arteries. The venous drainage was to the straight and sigmoid sinuses

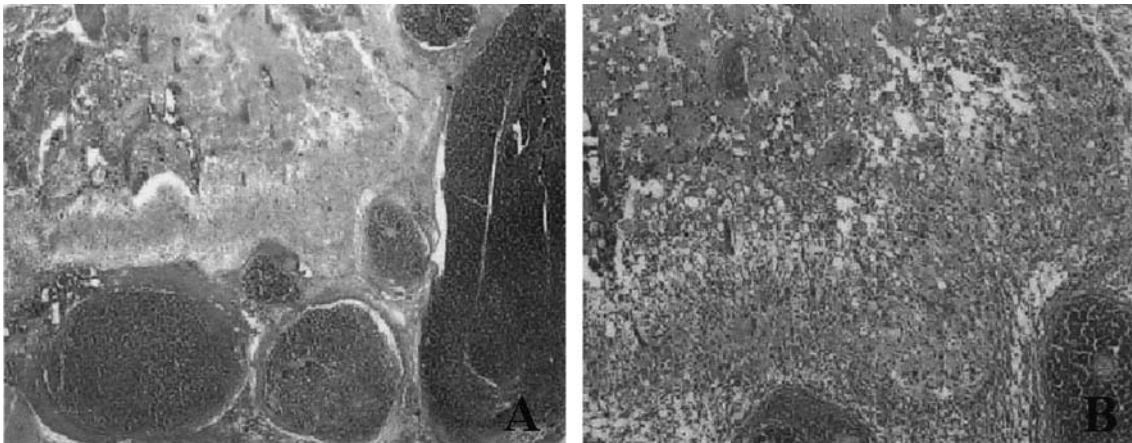


Fig. 3. Histologically, there were two components intermingled in the sections. First component was composed of numerous enlarged blood vessels in varying sizes, some of which were thrombosed. These areas of blood vessels were separated by brain parenchyma (HE staining, original magnification $\times 40$) (A). Low magnification of the same area showed small tumor cells clearly (HE staining, original magnification $\times 100$) (B). The second component was glial tumor excised within the arteriovenous malformation. The tumor was cellular and composed of small, round cells with eosinophilic cytoplasm. Large areas of hemorrhage and necrosis have also been observed throughout the lesion. Immunohistochemical staining revealed that tumor cells expressed GFAP (C) and p53 (D). (Nuclei were counterstained with hematoxyline. Original magnification $\times 400$, 200 , respectively)

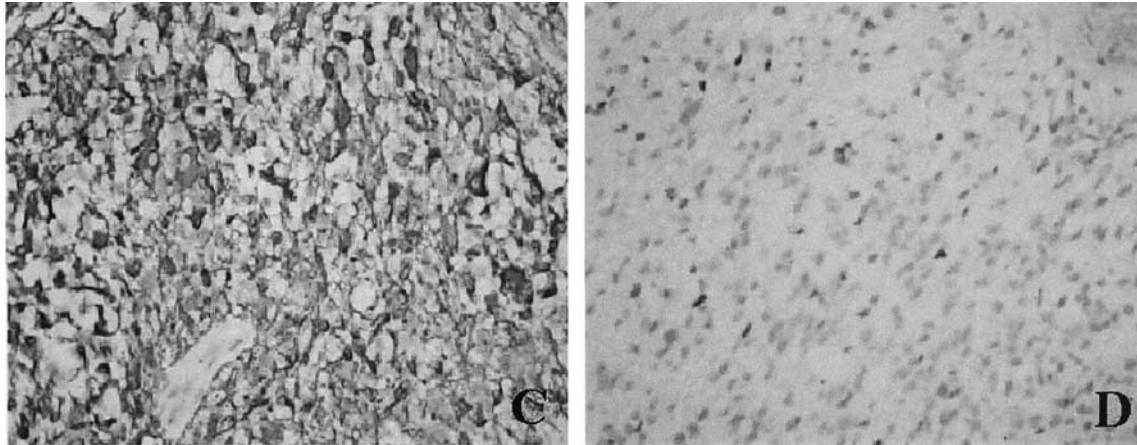


Fig. 3 (continued)

References

1. Foy PM, Lozada L, Shaw MD (1981) Vascular malformation simulating a glioma on computerized tomography. Case report. *J Neurosurg* 54: 125–127
2. Goodkin R, Zaias B, Michelsen J (1990) Arteriovenous malformation and glioma: coexistent or sequential? Case report. *J Neurosurg* 72: 798–805
3. Harris OA, Chang SD, Harris BT, Adler JR (2000) Acquired cerebral arteriovenous malformation induced by an anaplastic astrocytoma: an interesting case. *Neurol Res* 22(5): 473–477
4. Lee TT, Landy HJ, Bruce JH (1996) Arteriovenous malformation associated with pleomorphic xanthoastrocytoma. *Acta Neurochir (Wien)* 138(5): 590–591
5. Licata C, Pasqualin A, Freschini A, Barone G, Da Pian R (1986) Management of associated primary cerebral neoplasms and vascular malformations: 2. Intracranial arterio-venous malformations. *Acta Neurochir (Wien)* 83: 38–46
6. Lombardi D, Scheithauer BW, Piepgras D, Meyer FB, Forbes GS (1991) “Angioglioma” and the arteriovenous malformation-glioma association. *J Neurosurg* 75: 589–596
7. Malcolm GP, Symon L, Tan LC, Pires M (1991) Astrocytoma and associated arteriovenous malformation. *Surg Neurol* 36: 59–62
8. Tews DS, Bohl JE, Van Lindert E, Ringel K (1998) Association of oligodendroglioma-like cell proliferation and angiomatous vasculature-coincidence or pathogenetically related lesions? *Clin Neuropathol* 17(2): 69–72
9. Zuccarello M, Giordano R, Scanarini M, Mingrino S (1979) Malignant astrocytoma associated with arteriovenous malformation. Case report. *Acta Neurochir (Wien)* 50: 305–309

Comment

In Japan, we do angiography preoperatively routinely for brain tumours. As you understand very well, because we have to know the precise information not only about the tumour itself, but also the vascularity, displacement of normal vessels, tumour vessels, etc., and we have to give this preoperative information to patients and family. We have to explain the risk about operative procedure.

K. Kurisu

Correspondence: Ibrahim M. Ziyal, M.D., Susam Sokak, Yuvam Apt. 20/4, Cihangir, Istanbul, Turkey. e-mail: ibrahimziyal@yahoo.com