

Toru Watanabe · Hiroo Onda

## Hemichorea with antiphospholipid antibodies in a patient with lupus nephritis

Received: 29 August 2003 / Revised: 25 November 2003 / Accepted: 26 November 2003 / Published online: 23 January 2004  
© IPNA 2004

**Abstract** Although central nervous system involvement is an important manifestation of systemic lupus erythematosus (SLE), chorea is a relatively uncommon complication. A strong association between chorea and the presence of antiphospholipid antibodies (aPLs) has been reported in patients with SLE, lupus-like disease, or primary antiphospholipid syndrome. We describe a patient with lupus nephritis and cerebral infarction, who subsequently developed recurrent hemichorea associated with increased aPLs levels. A 7-year-old boy suffered from lupus nephritis and a left middle cerebral artery infarction associated with aPLs. He subsequently experienced two episodes of right hemichorea associated with increased aPLs levels without any evidence of further neurological lesions by brain computed tomography or magnetic resonance imaging. The previous left cerebral artery infarction might have increased the susceptibility of the left basal ganglia to the effects of aPLs that contributed to the development of the right hemichorea in this patient.

**Keywords** Chorea · Cerebral infarction · Central nervous system · Brain disease · Systemic lupus erythematosus · Antiphospholipid antibody syndrome

### Introduction

Although central nervous system involvement is a well-recognized and important manifestation of systemic lupus

erythematosus (SLE), chorea is a relatively uncommon complication [1]. A strong association of chorea with antiphospholipid antibodies (aPLs) has been reported in patients with SLE, lupus-like disease, or primary antiphospholipid syndrome (APS) [2, 3]. Although vascular lesions and immune-mediated mechanisms have been proposed to be of pathophysiological relevance in some studies [4], the precise pathogenic roles of aPLs in the development of chorea in patients with SLE remain unclear. In this report, we present a patient with lupus nephritis and cerebral infarction, who subsequently developed recurrent hemichorea associated with increased aPLs levels.

### Case report

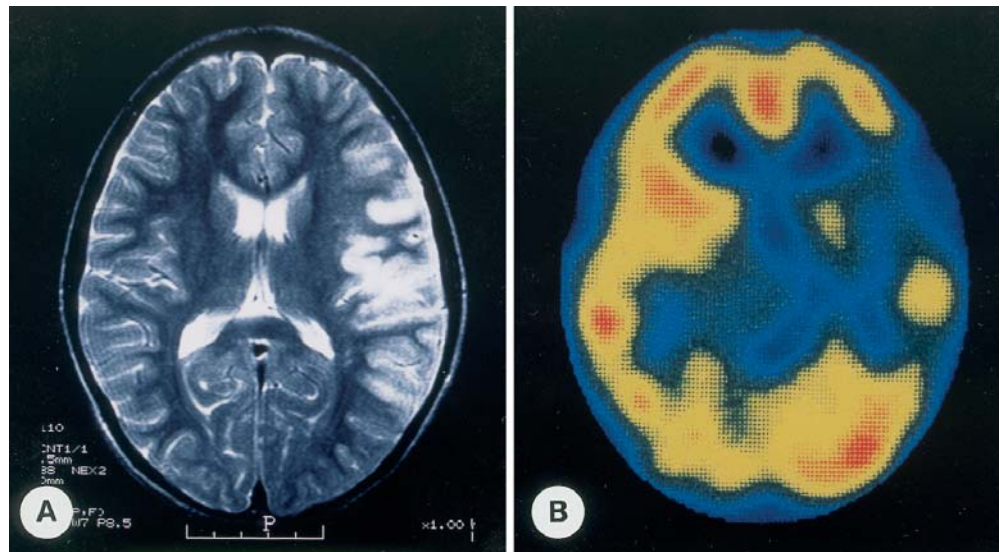
A 7-year-old boy was admitted to our hospital because of sudden-onset right hemiplegia and aphasia. He had been suffering from facial erythema and knee joint pain for 2 months prior to admission. Physical examination revealed a butterfly rash, generalized edema together with bilateral swelling and pain of the knee joints. He was febrile at 38.0°C and normotensive at 117/50 mmHg with a pulse rate of 68/min. Neurological examination revealed a right hemiplegia, right hypesthesia, and aphasia.

Laboratory studies revealed a pancytopenia (red blood cell count  $339 \times 10^4/\mu\text{l}$ , hemoglobin 8.8 g/dl, hematocrit 26.5%, white blood cell count  $3,100/\mu\text{l}$ , and platelet count  $7.1 \times 10^4/\mu\text{l}$ ), hypoproteinemia (serum total protein 4.4 g/dl and serum albumin 2.0 g/dl), hypocomplementemia [C3 25 mg/dl (normal >64), C4 3 mg/dl (normal >14), and  $\text{CH}_{50} < 12.5 \text{ CH}_{50}\text{U/ml}$  (normal 30–40)], and an increased erythrocyte sedimentation rate (48 mm/h). Serum titers of liver enzymes, electrolytes, blood urea nitrogen, and creatinine were within normal limits. Urinalysis indicated marked proteinuria (4–10 g/day), hematuria, and various casts. Immunological studies revealed a positive antinuclear antibody (1:1,280) and an elevated anti-double-stranded DNA antibody level of 179 IU/ml (normal <10). Anticardiolipin antibody (aCL) IgG and aCL IgM levels were elevated at 2.0 (enzyme-linked immunosorbent assay, optical density at 430 nm, normal <1.0) and 1.5 (normal <1.0) respectively. Circulating immune complexes were elevated at  $35.0 \mu\text{g/ml}$  (C1q binding assay, normal <3.0). Anti-Sm antibody, anti-SS-A antibody, anti-SS-B antibody, anti-RNP antibody, and rheumatoid factor were negative. Lupus anticoagulant (LA) was detected on the basis of a prolonged activated partial thromboplastin time with a positive mixing study and confirmatory testing with hexagonal phase phospholipid being present. VDRL test was negative.

T. Watanabe (✉)  
Department of Pediatrics,  
Niigata City General Hospital,  
2–6-1 Shichikuyama, Niigata 950–8739, Japan  
e-mail: twata@hosp.niigata.niigata.jp  
Tel.: +81-25-2415151  
Fax: +81-25-2483507

H. Onda  
Central Laboratory,  
Niigata City General Hospital,  
Niigata, Japan

**Fig. 1** **A** T2-weighted images on brain magnetic resonance imaging showing high intensity in the cortical and subcortical lesions of the left frontal and temporal lobes. **B** Brain single photon emission computed tomography showing hypoperfusion of the left frontal and temporal lobes as well as the basal ganglia



Computed tomography (CT) of the brain revealed low-density areas in the left frontal, temporal and parietal lobes. The T2-weighted magnetic resonance image (MRI) of the brain revealed high-intensity areas in the left frontal, temporal and parietal lobes compatible with infarction as a result of occlusion of the left middle cerebral artery (Fig. 1A). Single photon emission computed tomography (SPECT) of the brain demonstrated decreased perfusion of the left frontal, temporal and parietal cortical regions, as well as the left basal ganglia (Fig. 1B).

A diagnosis of SLE was made from these clinical and laboratory findings, with associated lupus nephritis, nephrotic syndrome, and cerebral infarction. A renal biopsy demonstrated diffuse and global mesangial proliferative glomerulonephritis with segmental spike formation and tram track lesions (WHO class IV). The patient was treated with daily intravenous methylprednisolone (20 mg/kg) for 3 days, followed by oral prednisolone (PSL) (1 mg/kg per day for 4 weeks, with gradual tapering thereafter), cyclophosphamide (2 mg/kg per day, 8 weeks), and dipyridamole (5 mg/kg per day). Six months later, he was antinuclear antibody negative with normal urinalysis and serum complement levels. The aCL IgG and aCL IgM titers had normalized (0.8 and 0.5, respectively) and LA disappeared. He was discharged with no neurological sequelae and the oral PSL dose was decreased gradually thereafter. The patient has still continued to take dipyridamole to prevent the recurrence of thrombotic events.

One year after the onset of SLE, he developed involuntary movement of the right extremities. Neurological examination revealed a right hemichorea. Laboratory studies demonstrated elevated aCL IgG (2.3) and aCL IgM (1.8) titers, together with a positive LA test. Serum concentrations of complement, antinuclear antibody, and anti-double-stranded DNA antibody were normal, as was urinalysis. Brain CT and MRI revealed no new lesions, whilst brain SPECT demonstrated normal perfusion of the left basal ganglia. He was diagnosed with SLE-related hemichorea. An increase in PSL dose and oral mizoribine (3 mg/kg per day) improved the hemichorea and resulted in a decrease in the aCL IgG and aCL IgM levels. The oral PSL dose was gradually decreased 4 months later since the hemichorea had completely resolved and the aCL IgG (0.6) and aCL IgM (0.5) levels had normalized. However, aCL IgG and aCL IgM levels increased following the reduction in the PSL dose. One year after the onset of hemichorea, the right hemichorea recurred and was associated with elevated aCL IgG (2.6) and aCL IgM (1.3) levels, as well as a positive LA test. Serum concentrations of complement, antinuclear antibody, and anti-double-stranded DNA antibody were normal, as was urinalysis. Brain CT, MRI, and SPECT findings were unchanged. An increased dose of PSL and mizoribine (5 mg/kg per day)

resulted in the resolution of the hemichorea as well as normalization of aCL IgG and aCL IgM levels over a period of 3 months. Thereafter, we determined the appropriate PSL dose for maintaining normal aCL IgG and aCL IgM levels and the hemichorea has not recurred.

## Discussion

Chorea usually occurs early in the clinical course of SLE and has a good prognosis [3]. Several reports have indicated a strong relationship between chorea and aPLs levels in patients with SLE, lupus-like disease, or APS [2, 3, 4, 5, 6, 7]. Asherson et al. [2] reported that 9 of 12 chorea patients with SLE or lupus-like disease had elevated levels of aPLs. Pediatric case reports have also described chorea patients with SLE or APS with elevated aPLs levels at the onset of chorea [5, 6]. The observation that our patient suffered from recurrent hemichorea only when aPLs levels had significantly increased suggests that aPLs directly contributed to the development of hemichorea in our patient.

Although the precise pathogenic role of aPLs in the development of chorea in patients with SLE, lupus-like disease, or APS remains unclear, several mechanisms have been postulated. These include transient or permanent ischemic injury to the basal ganglia or to the connecting tract serving basal ganglia, secondary to aPLs-mediated vasculopathy caused by aPLs, and direct aPLs-mediated damage to phospholipid-containing structures in the basal ganglia [3, 5, 8]. Recently, Kent et al. [9] demonstrated experimentally that monoclonal phosphatidylserine-reactive antibodies directly bound to intracellular targets of myelin in rat brain, suggesting that aPLs react directly with central nervous system tissue, with the potential for significant pathological consequences.

Review of 50 chorea patients with SLE, lupus-like disease, or APS indicates that 45% of patients had hemichorea whilst 34% of patients presented recurrent

episodes of chorea [3]. Therefore, recurrent hemichorea, such as in our patient, is not particularly uncommon in SLE-related chorea. Most patients with hemichorea and SLE, lupus-like disease, or APS exhibit normal brain CT/MRI [3]. The precise reasons why hemichorea occurs in the absence of brain CT/MRI lesions in these patients are unknown. However, there is evidence of contralateral striatal hypermetabolism using  $^{18}\text{F}$ -fluorodeoxyglucose and positron emission tomography in an APS patient with alternating hemichorea and normal brain MRI [10]. Our patient developed recurrent right hemichorea associated with increased aPLs levels 1 year after left middle cerebral artery occlusion. Although brain CT and MRI revealed no apparent changes in the left basal ganglia, brain SPECT at the onset of cerebral infarction revealed hypoperfusion of the left basal ganglia. Brain CT and MRI performed at the onsets of hemichorea revealed no new lesions. These findings suggest that previous left cerebral artery infarct increased the susceptibility of the left basal ganglia to the adverse effects of aPLs. The association of recurrent right hemichorea with concomitant increases in the levels of circulating aPLs suggests that aPLs played an active role in the development of recurrent right hemichorea in our patient.

Some studies have reported that carbamazepine is highly effective in the treatment of rheumatic chorea [11]. However, because aPLs were produced by immune-mediated mechanisms, immunosuppressive treatments such as high-dose corticosteroids, cyclophosphamide, and combinations of the two, or methotrexate have been employed in most patients with aPLs-associated chorea [12]. Since our patient had already been treated with cyclophosphamide, we used mizoribine as an immunosuppressive drug, which reduced our patient's aPLs titers and resulted in the chorea subsiding. Mizoribine may be an effective immunosuppressive agent for aPLs-associated chorea.

## References

- Steinlin MI, Blaser SI, Gilday DL, Eddy AA, Logan WJ, Laxer RM, Silverman ED (1995) Neurologic manifestations of pediatric systemic lupus erythematosus. *Pediatr Neurol* 13:191–197
- Asherson RA, Derksen RHWM, Harris EN, Bouma BN, Gharavi AE, Kater L, Hughes GRV (1987) Chorea in systemic lupus erythematosus and "lupus-like" disease: association with antiphospholipid antibodies. *Semin Arthritis Rheum* 16:253–259
- Cervera RC, Asherson RA, Font J, Tikly M, Pallarés L, Chamorro A, Ingelmo M (1997) Chorea in the antiphospholipid syndrome. Clinical, radiologic, and immunologic characteristics of 50 patients from our clinics and the recent literature. *Medicine (Baltimore)* 76:203–212
- Brey RL, Escalante A (1998) Neurological manifestations of antiphospholipid antibody syndrome. *Lupus* 7 [Suppl 2]:S67–S74
- Vlachoyiannopoulos PG, Dimou G, Siamopoulou-Mavridou A (1991) Chorea as a manifestation of the antiphospholipid syndrome in childhood. *Clin Exp Rheumatol* 9:303–305
- Besbas N, Damarguc I, Ozen S, Aysun S, Saatci U (1994) Association of antiphospholipid antibodies with systemic lupus erythematosus in a child presenting with chorea: a case report. *Eur J Pediatr* 153:891–893
- Angelini L, Zibordi F, Zorzi G, Nardocci N, Caporali R, Ravelli A, Martini A (1996) Neurological disorders, other than stroke, associated with antiphospholipid antibodies in childhood. *Neuropediatrics* 27:149–153
- Janavs JL, Aminoff MJ (1998) Dystonia and chorea in acquired systemic disorders. *J Neurol Neurosurg Psychiatry* 65:436–445
- Kent MN, Alvarez FJ, Ng AK, Rote NS (2000) Ultrastructural localization of monoclonal antiphospholipid antibody binding to rat brain. *Exp Neurol* 163:173–179
- Furie R, Ishikawa T, Dhawan V, Eidelberg D (1994) Alternating hemichorea in primary antiphospholipid syndrome: evidence for contralateral striatal hypermetabolism. *Neurology* 44:2197–2199
- Harel L, Zecharia A, Straussberg R, Volovitz B, Amir J (2000) Successful treatment of rheumatic chorea with carbamazepine. *Pediatr Neurol* 23:147–151
- Paus S, Pötzsch B, Risse JH, Klockgether T, Wüllner U (2001) Chorea and antiphospholipid antibodies: treatment with methotrexate. *Neurology* 56:137–138