

Revelation of a New Mitochondrial DNA Mutation (G12147A) in a MELAS/MERFF Phenotype

Mariarosa A. B. Melone, MD; Alessandra Tessa, PhD; Stefania Petrini, PhD; Giacomo Lus, MD; Simone Sampaolo, MD; Giuseppe di Fede, MD; Filippo M. Santorelli, MD; Roberto Cotrufo, MD

Background: A 26-year-old man presented at onset with the syndrome of mitochondrial encephalomyopathy, lactic acidosis, and stroke-like episodes (MELAS) and later with a phenotype for MELAS and myoclonic epilepsy and ragged red fiber disease (MELAS/MERFF).

Objective: To identify the possible defects in the mitochondrial genome in blood and muscle samples of the patient.

Design: Case study of a patient clinically exhibiting stroke-like episodes and then epilepsy with myoclonic features, ataxia, and dementia.

Setting: Research unit of a university hospital.

Main Outcome Measures: Electromyographic, morphologic, and biochemical studies of muscle and molecular analysis of blood and muscle to investigate mitochondrial DNA (mtDNA) size and quantity.

Results: Morphologically, we found abnormal mitochondrial proliferation with several cytochrome-c oxidase (COX)-negative fibers in muscle biopsy specimens; the analysis of serial sections showed a decreased immunoreactivity for the mtDNA-encoded subunits COXII and, partially, COXI. Biochemically, we found a partial and isolated COX deficiency. The complete mtDNA sequence analysis identified 3 sequence changes, 2 of which were reported polymorphisms. The remaining change, a G12147A transition in the transfer RNA^{His} gene, appeared to be the likely pathogenic mutation.

Conclusions: Our data propose that the G12147A change, the first mutation in the transfer RNA^{His} gene associated with an overlapped MELAS/MERFF phenotype, is the cause of the encephalomyopathy in this patient interfering with the overall mitochondrial protein synthesis.

Arch Neurol. 2004;61:269-272

From the First Division of Neurology, Department of Neurological Sciences, Second University of Naples, Naples, Italy (Drs Melone, Lus, Sampaolo, di Fede, and Cotrufo); and the Department of Molecular Medicine, Istituto di Ricerca e Cura a Carattere Scientifico (IRCCS)-Bambino Gesù (Drs Tessa, Petrini, and Santorelli), Rome, Italy.

THE ASSOCIATION BETWEEN the syndrome of mitochondrial encephalomyopathy, lactic acidosis, and stroke-like episodes (MELAS) (*Mendelian Inheritance in Man* 540000) and the A3243G mutation in the mitochondrial DNA (mtDNA) transfer RNA (tRNA)^{Leu(UUR)} gene is well established in all ethnic backgrounds.¹ However, clinical and genetic heterogeneity is also recognized. Besides the obligatory signs indicated in the acronym, virtually any neurological abnormality described in mitochondrial disorders (often in varied combination) can occur in patients with typical MELAS.² Moreover, approximately 20% of A3243G-positive patients are affected by other syndromes, including progressive external ophthalmoplegia³ and a syndrome combining deafness and diabetes mellitus.⁴ Furthermore, not all typical patients with MELAS carry the A3243G mutation. Generally, myoclonic

epilepsy and ragged red fiber disease (MERFF) (*Mendelian Inheritance in Man* 545000) can be clinically distinguished from MELAS on the basis of the absence of strokes.⁵ Seldom, features of MERFF and MELAS can be seen during the clinical course of some patients⁶⁻⁸ and within the same pedigree.⁹ Approximately 80% to 90% of MERFF cases are caused by a heteroplasmic G-to-A point mutation at base pair 8344 in the TΨC loop of the tRNA^{Lys} gene (G8344A mutations).^{10,11}

In a molecular investigation of a case that was negative for A3243G and G8344A, we identified a novel heteroplasmic mtDNA mutation (G12147A) in the tRNA^{His} gene. The patient exhibited a progression from MELAS to an overlapped MELAS/MERFF phenotype.

REPORT OF A CASE

Patient III:1 is a 26-year-old man whose medical history was significant for psyc-

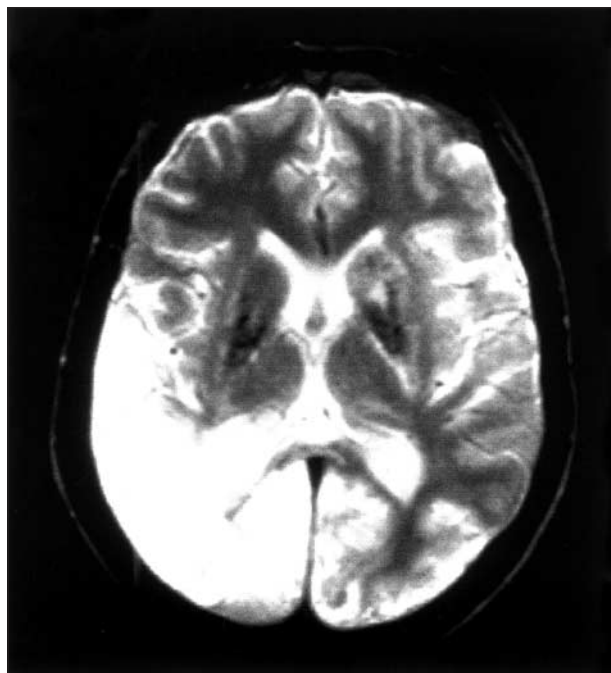


Figure 1. Axial noncontrast T2-weighted magnetic resonance image in the proband (III:1).

pathological disturbances (hysterical and paranoid personality), left sensorineural hearing loss, and endocrine abnormalities (hypogonadotropic hypogonadism). At 20 years of age, he experienced sudden severe migrainous headache and vomiting. These episodes were followed by left lateral homonymous hemianopia and left hemiparesis, complex partial seizure, and stupor for a few days. Results of a neurological examination showed left hemiparesis, hypoesthesia, and lateral homonymous hemianopia slowly and incompletely remitting in 3 months. At 22 years of age, he had 2 seizures in 2 consecutive days, without modifications of his neurological status. A third episode of his disease occurred at 23 years of age, characterized by sudden cortical blindness, without recovery. At 25 years of age, he was admitted to the hospital because of the appearance of myoclonus and ataxia, which emphasized a progression to a MERRF phenotype. A brain magnetic resonance image (**Figure 1**) disclosed T2-weighted hyperintense signals in the right posterior temporal lobe and bilaterally in the occipital lobe. Moreover, as a sequela of previous episodes, small areas of abnormal signal intensity were noticed in the left temporal lobe, right thalamus, and periaqueductal gray matter. Blood and cerebrospinal fluid lactate levels and serum creatine kinase activity were abnormally increased.

The proband's mother (II:1) had died after an extended strokelike attack at 36 years of age. Her medical records showed recurrent strokelike episodes of hemiparesis and hemianopia, often associated with severe migrainous headache, that began in adolescence.

A total of 11 relatives underwent direct examination and were deemed free of signs and symptoms often associated with mtDNA disorders. They underwent sampling with informed consent.

METHODS

Two muscle biopsy specimens from the proband, taken at 20 and 23 years of age, underwent histological and histochemical processing. Also, we performed immunohistochemical incubations with the primary antibodies slow myosin (Ylem Co, Rome, Italy) and cytochrome-*c* oxidase (COX) subunits I, II, IV, and VIc (Molecular Probes, Inc, Eugene, Ore) and detected them with a streptavidin-biotin method described elsewhere.¹² Respiratory chain complexes were measured in a post-600-revolution supernatant and expressed relative to the activity of the matrix marker enzyme citrate synthase. The size and quantity of mtDNA were investigated by means of Southern blotting in skeletal muscle. We used a procedure described elsewhere¹ to screen for the common A3243G MELAS and G8344A MERRF mutations. The entire mtDNA coding region was amplified in 13 overlapping amplicons and sequenced directly with BigDye chemistry (Applied Biosystems, Foster City, Calif). Using suitable oligonucleotide primers and the endonuclease *Tsp509I*, we screened for the G12147A mutation in tissues from the proband, his relatives, and control subjects. To assess the abundance of mutated genomes, radiolabeled amplicons were analyzed by means of ImageQuant software (Molecular Dynamics, Eugene, Ore).

Single-muscle fibers were isolated from cryostat cross section after succinate dehydrogenase staining in the proband. Staining with COXIV was also performed in some experiments. Abnormal fibers were considered those showing unusual accumulation of mitochondria or pale to absent COX staining. Selected normal and abnormal muscle fibers were processed using a modification of the laser capture microdissection technique (PixArthurus, MWG Biotech, Ebersberg, Germany) that allows the selective sampling of tissue from histological sections,¹³ following the manufacturer's suggested procedures. The relative proportion of wild-type and mutant mtDNA genomes was determined as described above. We used the non-parametric Mann-Whitney test to compare the levels of mutated genomes in normal and abnormal muscle fibers.

RESULTS

Morphologically, we found abnormal mitochondrial proliferation by means of succinate dehydrogenase staining, with several COX-negative fibers in the muscle biopsy specimens (data not shown). Fibers with strong succinate dehydrogenase staining represented about 15% of the muscle fibers. In addition, we found vessels that were strongly reactive for succinate dehydrogenase. The mosaic pattern of the COX activity suggested an mtDNA origin of the disease. This finding was further corroborated by the analysis of serial sections, which showed a decreased immunoreactivity for the mtDNA-encoded subunits COXII and, partially, COXI (**Figure 2A**). The nuclear DNA-encoded subunits COXIV and COXVIc were virtually normal. Biochemically, we found a partial and isolated COX deficiency (residual activity was 50% normal) in the patient's muscle homogenate and increased citrate synthase activity indicating mitochondrial proliferation. When compared with the human reference sequence, complete mtDNA sequence analysis identified 3 sequence changes, 2 of which were reported polymorphisms. The remaining change, a G12147A transition in the tRNA^{His} gene (**Figure 2B**), appeared to be the likely pathogenic mutation. The mutation was present in 81% of the muscle mtDNA molecules and in 25% of the mtDNA from the patient's blood,

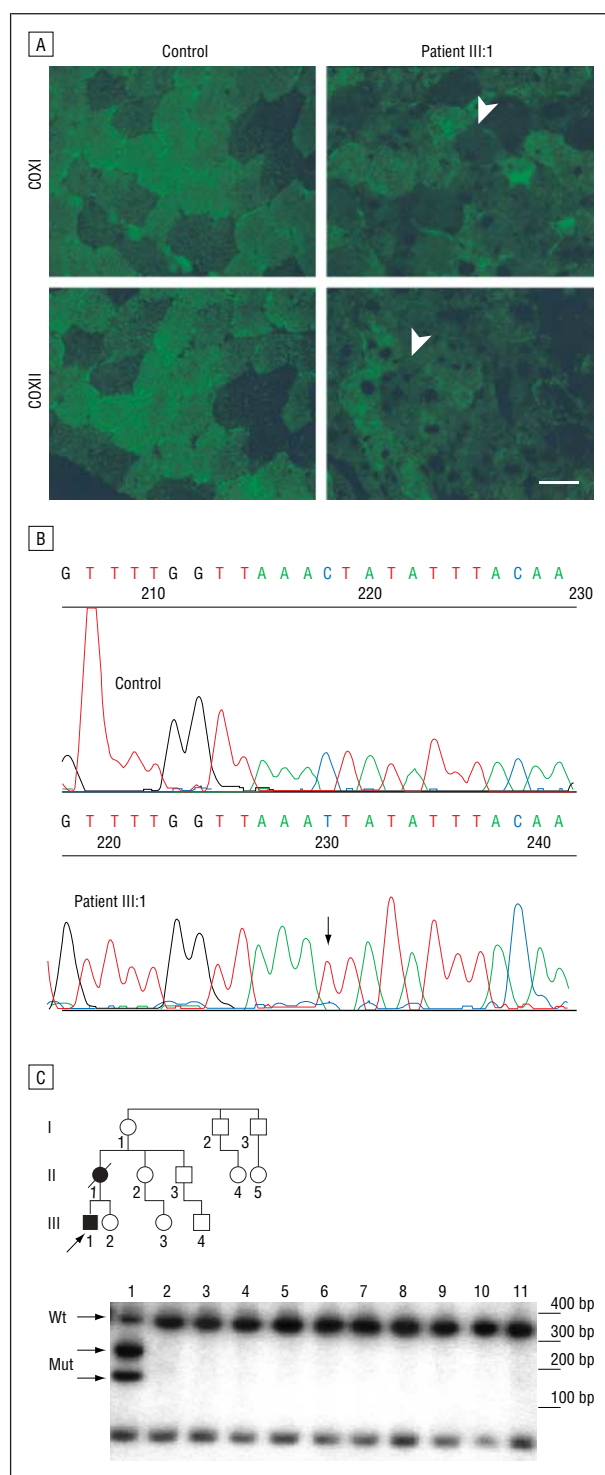
Figure 2. A, Results of immunohistochemistry in serial muscle sections from a control subject and the proband (patient III:1) using antibodies against cytochrome-c oxidase subunit I (COXI) and COXII (bar indicates 60 μ m). In serial sections, a COX-negative muscle fiber is indicated by an arrowhead. B, Electropherogram of the mitochondrial DNA (mtDNA) transfer RNA (tRNA)^{His} gene flanking the novel G12147A mutation. The sequence of DNA from a healthy control and patient III:1 are presented. Sequencing was performed by means of an antisense primer. The arrow indicates the novel mutation. C, Autoradiogram of the restriction-fragment length polymorphism analysis used to quantitate mutant mtDNA. A 470-bp (bp) polymerase chain reaction fragment flanking the tRNA^{His} gene was amplified using suitable oligonucleotide primers. The amplicon was cleaved with the endonuclease *Tsp509*I and electrophoresed on a 12% polyacrylamide gel, and the dried gel was exposed to an x-ray film. The G12147A mutation introduces an additional *Tsp509*I site of cleavage in the 389-bp fragment (wild-type [wt]) generating 2 additional fragments sized 163 and 226 bp (mutation [mut]). Lanes 1 to 9 are subjects III:1, III:2, III:3, III:4, II:2, II:3, I:1, I:2, and I:3 in the superimposed pedigree. Lanes 10 and 11 are from a healthy control and a patient with the A3243G mtDNA mutation, respectively. The DNA marker size is also indicated. No sample could be tested from the deceased mother (II:1). The solid symbols in the pedigree show clinically affected family members; open symbols, healthy members; squares, male members; circles, female members; slash, deceased; and arrow, proband.

but it was absent in blood, hair roots, and urinary sediment from 11 healthy maternal relatives (Figure 2C). Single-muscle fiber analysis showed more abundant mutated genomes in abnormally appearing muscle fibers ($n=22$) than in normal fibers ($n=15$). The mean \pm SD percentage of mutant mtDNA was $90\% \pm 2\%$ in the former group and $58\% \pm 6\%$ in the latter, and this difference was significant ($P=.007$). In the 12 ragged red-COX-negative fibers studied, the average of mutated genomes was even more abundant (94%).

COMMENT

The combination of the pathologic history of the mother, clinical data, and biochemical and morphologic impairment of oxidative metabolism strongly indicated a defect in the mitochondrial genome in this patient. The G12147A transition in the tRNA^{His} gene was considered potentially pathogenic for indirect reasons. First, it was heteroplasmic and detectable at higher levels in skeletal muscle than in circulating lymphocytes. This is a well-recognized phenomenon for many pathogenic mtDNA point mutations. Second, the mutation was not identified in 100 healthy subjects or in 35 disease controls, and it has not been reported previously as a common polymorphic variant.¹⁴ Third, the involved nucleotide within the dihydrouridine arm of the tRNA displays high phylogenetic conservation through evolution. The computer-generated model of the mutant tRNA using the MFOLD program (available at <http://www.bioinfo.rpi.edu/applications/mfold>) reveals that the novel change is likely to perturb secondary and tertiary structure. As shown for another pathogenic mtDNA change,¹⁵ mutations in the dihydrouridine arm might well cause mitochondrial dysfunction by impairing mitochondrial protein synthesis. For instance, this seems pertinent for COXIII, the richest polypeptide in histidine residues,¹⁴ eventually accounting for the observed COX defect in skeletal muscle. Finally, the deleterious potential of the mutation was also shown by the highly significant correlation between the morphologic defect and mutation load in single-muscle fibers as shown by laser capture microdissection-polymerase chain reaction analyses.

Our data propose that the G12147A change, the first mutation in the tRNA^{His} gene associated with the



MELAS/MERRF phenotype, is the cause of the encephalomyopathy in this patient. Its pathogenicity stems from alteration of a highly conserved nucleotide, perturbation of the tRNA secondary structure, and good correlation with the morphologic alterations in the muscle biopsy specimens. Although it is possible that the novel change interferes, reducing particularly COX peptide levels, the exact mechanisms underlying the clinical presentation of the patient remain to be shown.

Accepted for publication September 12, 2003.

Author contributions: *Study concept and design* (Drs Melone and Santorelli); *acquisition of data* (Drs Melone, Tessa, Petrini, Lus, Sampaolo, di Fede, and Santorelli); *analysis and interpretation of data* (Drs Melone, Tessa, Petrini, Santorelli, and Cotrufo); *drafting of the manuscript* (Drs Melone, Tessa, Petrini, Lus, di Fede, and Santorelli); *critical revision of the manuscript for important intellectual content* (Drs Melone, Lus, Sampaolo, Santorelli, and Cotrufo); *obtained funding* (Drs Lus and Sampaolo); *administrative, technical, and material support* (Dr Santorelli); *study supervision* (Drs Melone, Santorelli, and Cotrufo).

Work in the Filippo Maria Santorelli Laboratory, Department of Molecular Medicine, IRCCS Bambino Gesù, Rome, Italy, was supported by grants from the Italian Ministry of Health, Rome.

Corresponding author and reprints: Mariarosa A. B. Melone, MD, First Division of Neurology, Department of Neurological Sciences, Second University of Naples, School of Medicine, Policlinico Universitario Federico II, Edificio10, Via Sergio Pansini, 5, 80131 Naples, Italy (e-mail: marina.melone@unina2.it).

REFERENCES

1. Ciafaloni E, Ricci E, Shanske S, et al. MELAS: clinical features, biochemistry, and molecular genetics. *Ann Neurol*. 1992;31:391-398.
2. Mariotti C, Savarese N, Suomalainen A, et al. Genotype to phenotype correlations in mitochondrial encephalomyopathies associated with the A3243G mutation of mitochondrial DNA. *J Neurol*. 1995;242:304-312.
3. Damian MS, Seibel P, Reichmann H, et al. Clinical spectrum of the MELAS mutation in a large pedigree. *Acta Neurol Scand*. 1995;92:409-415.
4. Maassen JA, Jansen JJ, Kadowaki T, van den Ouweland JM, 't Hart LM, Lemkes HH. The molecular basis and clinical characteristics of maternally inherited diabetes and deafness (MIDD), a recently recognized diabetic subtype. *Exp Clin Endocrinol Diabetes*. 1996;104:205-211.
5. Pavlakis SG, Phillips PC, DiMauro S, De Vivo DC, Rowland LP. Mitochondrial myopathy, encephalopathy, lactic acidosis, and stroke-like episodes: a distinctive clinical syndrome. *Ann Neurol*. 1984;16:481-488.
6. Kuriyama M, Igata A. Mitochondrial encephalopathy, lactic acidosis, and stroke-like syndrome (MELAS) [letter]. *Ann Neurol*. 1985;18:625-626.
7. Fukuhara N. Stroke-like episodes in MERRF [letter]. *Ann Neurol*. 1985;18:368.
8. Byrne E, Trounce I, Dennett X, Gilligan B, Morley JB, Marzuki S. Progression from MERRF to MELAS phenotype in a patient with combined respiratory complex I and IV deficiencies. *J Neurol Sci*. 1988;88:327-337.
9. Danks RA, Dorevitch M, Cummins JT, Byrne E. Mitochondrial myopathy, encephalopathy, lactic acidosis, and stroke-like episodes (MELAS): adolescent onset with severe cerebral edema. *Aust N Z J Med*. 1988;18:69-72.
10. Shoffner JM, Lott MT, Lezza AM, Seibel P, Ballinger SW, Wallace DC. Myoclonic epilepsy and ragged-red fiber disease (MERRF) is associated with a mitochondrial DNA tRNA(Lys) mutation. *Cell*. 1990;61:931-937.
11. Berkovic SF, Shoubridge EA, Andermann F, Andermann E, Carpenter S, Karpati G. Clinical spectrum of mitochondrial DNA mutation at base pair 8344 [letter]. *Lancet*. 1991;338:457.
12. Hsu SH, Raine L. Protein A, avidin and biotin in immunohistochemistry. *J Histochem Cytochem*. 1981;29:1349-1353.
13. Ehrig T, Abdulkadir SA, Dintzis SM, Milbrandt J, Watson MA. Quantitative amplification of genomic DNA from histological tissue sections after staining with nuclear dyes and laser capture microdissection. *J Mol Diagn*. 2001;3:22-25.
14. MITOMAP. Available at: <http://www.mitomap.org/>. Accessed June 30, 2003.
15. Hao H, Moraes CMT. Functional and molecular mitochondrial abnormalities associated with a C→T transition at position 3256 of the human mitochondrial genome: the effects of a pathogenic mitochondrial tRNA point mutation in organelle translation and RNA processing. *J Biol Chem*. 1996;271:2347-2352.