

Impaired Volitional Closure of the Left Eyelid After Right Anterior Cerebral Artery Infarction

Apraxia Due to Interhemispheric Disconnection?

Thomas Korn, MD; Wolfgang Reith, MD; Georg Becker, MD†

Background: The inability of volitional unilateral eyelid closure is an uncommon symptom of a central nervous system disorder. When it occurs as the result of a localized brain lesion, it is debated to be a form of supranuclear facial palsy or an apraxic phenomenon.

Objectives: To report and discuss a unilateral (left-sided) higher-order movement disorder of the facial periorcular musculature bearing apraxic features.

Setting: University neurology department.

Patient: A 78-year-old right-handed man was admitted to the hospital with a left-sided brachiofacial hemiparesis of sudden onset. After thrombolysis with intravenous recombinant tissue-type plasminogen activator, the hemiparesis, including the left-sided facial weakness, disappeared. Serial computed tomographic scans showed that the patient was left with a stroke in the right

anterior cerebral artery territory, affecting the frontal commissural fibers of the corpus callosum. There were no signs of upper motor neuron facial paresis on the left side when gesturing in a natural context. Eyelid closure was complete during sleep. However, left eyelid closure and elevation of the left eyebrow were not possible on verbal command. In contrast, voluntary innervation of the perioral facial musculature was performed properly.

Conclusions: The voluntary-automatic dissociation of our patient's eyelid closure was suggestive of an apraxic disorder. Disconnection from a praxis center caused by callosal damage may be assumed to be the underlying cause. The unilaterality of the symptom might imply that in a bilaterally organized corticonuclear system such as upper face innervation, it is the crossing fibers that are primarily involved in praxis tasks.

Arch Neurol. 2004;61:273-275

THE CONCEPT OF APRAXIC DISORDERS has essentially been worked out on a phenomenologic basis regarding errors of limb usage.¹ Ideational (or conceptual), ideomotor, and limb-kinetic apraxia are common terms to describe different deficits in limb praxis. Ideational apraxia was considered as agnosia for tool usage² or more general, as loss of the space-time plan.³ The patient does not know what to do. Lesions most often found with this condition were left parieto-occipital or parietotemporal. In ideomotor apraxia, the space-time plan is intact but is disconnected from the innervating motor engram. The patient knows what to do but not how to do it. Ideomotor apraxia is commonly associated with lesions of left parietal association areas or intrahemispheric white matter bundles. Limb-kinetic apraxia is eventually due to damage of innervating motor engrams and usually observed contralaterally to the affected hemisphere. It is often described as

a loss of dexterity in complex finger movements.

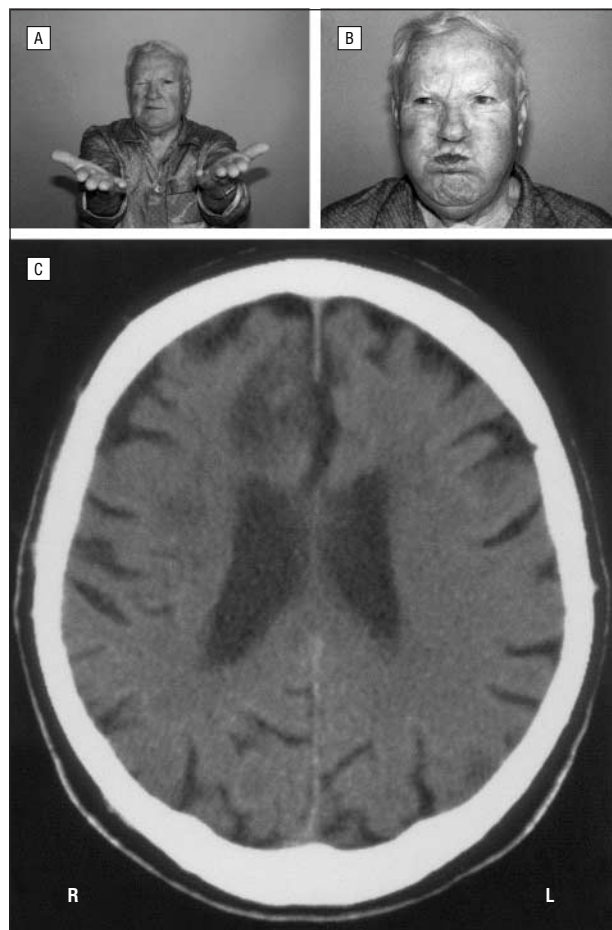
Callosal lesions may produce unilateral apraxia of the nondominant limb. Apraxic deficits in callosal apraxia may reflect ideomotor apraxic features. In a report by Geschwind and Kaplan⁴ that refers to interhemispheric disconnection syndromes, pantomiming with the left hand was impaired on verbal command whereas there was no problem with object use. In the present report, we describe a patient with impaired voluntary eyelid closure on the left side. The patient's facial motor deficits clearly bore features of a higher-order motor disorder.

REPORT OF A CASE

A 78-year-old right-handed man was admitted to the hospital because of acute left-sided hemiparesis. The man lived independently and had been well until 2½ hours prior to admission, when he suddenly noticed tingling and weakness in his

From the Departments of Neurology (Drs Korn and Becker) and Neuroradiology (Dr Reith), Universität des Saarlandes, Homburg/Saar, Germany.

†Deceased.



A 78-year-old man with an apraxic movement disorder that affected selectively the upper portion of the left face (A and B). The causative lesion was an ischemic stroke, damaging the right rostral part of the callosal forceps (computed tomographic scan, C).

left arm. Eight years previously, he had to be treated with bypass surgery because of coronary heart disease. Four years before, a pacemaker was implanted because of atrioventricular blockage. His main cardiovascular risk factor was arterial hypertension.

At examination, the patient was alert and fully oriented, with fluent speech. He had a conjugated deviation of gaze to the right but no gaze palsy to the left. A medium-grade paresis of the left-sided lower facial muscles was evident. The other cranial nerve functions were preserved. The left-sided hemiparesis was high grade in the arm and minor in the leg. The deep tendon reflexes of the left arm were increased. The left plantar response was extensor. The initial computed tomographic scan did not show signs of an ischemic stroke but excluded hemorrhage. Magnetic resonance imaging was not possible since the patient had a pacemaker.

A systemic thrombolysis with intravenous recombinant tissue-type plasminogen activator (rtPA) (1 mg/kg) was performed. One day later, the patient exhibited normal strength in his left arm and hand. However, it turned out to be very difficult for him to voluntarily close his left eye. While he could easily puff up his cheeks and hold in the air, it was virtually impossible for him to close his left eye on verbal command (**Figure**, A and B). He

was unable to lift his left eyebrow when told to do so nor could he keep it elevated when it had been lifted passively by the examiner. In contrast, the involuntary eyelid closure during sleep was not affected and neither was the blink reflex. There was no impairment of automatic gesticulation (smiling, laughing, or blinking) outside the clinical test setting.

Control computed tomographic scans were performed 11 hours and 10 days after thrombolysis. They revealed an ischemic stroke in the right anterior cerebral artery territory (**Figure**, C). In the digital subtraction arteriogram, the proximal internal carotid artery on the right side was found to be occluded and had not become recanalized after the thrombolysis procedure, whereas the distal part of the internal carotid artery and the medial cerebral artery but not the anterior cerebral artery on the right side were refilled via the ophthalmic artery. Regarding the initial medial cerebral artery syndrome (left-sided brachiofacial hemiparesis), we therefore hypothesize that initially, the carotis bifurcation could have been blocked by a thrombus whose medial cerebral artery "limb" might have been lysed successfully by rtPA, leaving part of the anterior cerebral artery territory infarcted.

COMMENT

The impossibility of voluntary unilateral eyelid closure due to a localized brain lesion was observed in our patient. Previous reports about the bilateral lack of volitional eyelid closure as a pseudobulbar phenomenon resulting from generalized or disseminated brain lesions are abundant.⁵ The number of cases is getting rarer when a localized lesion—especially in the right hemisphere—is supposed to be the underlying cause.⁶⁻⁸ Ghika et al⁵ considered cortical damage and loss of association fibers between supplementary motor regions and the premotor or primary motor areas responsible for the bilateral inability of 2 patients with ischemic lesions involving Brodmann areas 4 and 6 of the right parietal lobe to close their eyes voluntarily. Disconnection between these areas would lead to failure of volitional eyelid closure. The failure would be bilateral since eyelid closure is supposed to be an axial movement with bilateral innervation. A systematic investigation of patients with lateralized brain lesions for (bilateral) face apraxia has recently been conducted, illustrating that 46% of left-hemisphere-damaged and 44% of right-hemisphere-damaged patients showed apraxic upper face movements.⁹

Here we describe a patient with a disorder of voluntary movement in the upper portion of the left face after right anterior cerebral artery stroke. The intact spontaneous facial gesturing revealed no evidence for left facial weakness due to upper motor neuron damage. Also, a supranuclear palsy of cranial nerve VII could hardly be present on theoretical grounds since it is commonly true for the innervation of the periocular and forehead musculature to be spared in contralateral stroke due to uncrossed innervation of the corresponding part of the facial nucleus. If ever there is some variability in the organization of the corticonuclear pathway to the facial nucleus, it is in the way that the motoneurons of the lower

facial muscles (in addition to the upper ones) may receive bilateral corticonuclear input.¹⁰ Therefore, it is quite unlikely that the impaired voluntary movement of the left periocular muscles was due to right pyramidal (corticonuclear) tract damage.

Rather, we suggest that the lesion of the right limb of the frontal callosal forceps (Figure, C) led to disconnection of the right hemispheric motor system from the praxis center in the left hemisphere. The disconnection from the left intraparietal cortex (intraparietal sulcus) or the left dorsolateral frontal cortex is believed to be a substrate of ideomotor apraxia in right-handed subjects.¹¹⁻¹³ The observed left-sided facial movement disorder was reminiscent of ideomotor apraxic features since there was a clear dissociation between impaired voluntary closure of the left eyelid on verbal command and perfectly normal blinking and automatic eyelid closure in a natural context. In our patient, the disturbance of voluntary gesturing was unilateral (confined to the left half of the face). Given the commonly accepted truth that the innervation of the upper face is bilateral with a contralateral predominance,¹⁴ we would like to hypothesize that the predominance of the crossing corticonuclear fibers is unmasked more clearly in volitionally evoked movements of the periocular musculature as compared with reflex movements.

Nevertheless, we cannot exclude that the described phenomenon is the facial equivalent of a limb-kinetic apraxia (loss of deftness), which may result from right-sided damage to intrahemispheric premotor cortex connections, with subsequent alteration of motor engrams. However, a certain dominance of the left hemisphere has recently been shown.¹⁵ In contrast with the present case, a voluntary-automatic dissociation of motor performance is usually not observed in limb-kinetic apraxia. In addition, according to the bilateral projections of the upper facial corticonuclear tract neurons, we would predict more prominent bilateral clinical signs if the intrahemispheric motor engram for the movement of the upper face was lesioned.

It has long been known that lesions of the callosal splenium can make individuals lose the very concept of skilled movements. This has been referred to as agnosia for tool usage¹⁶ and is associated with disconnection from the dominant posterior parietal lobe, whose projections cross over in the splenium. Isolated defects of the callosal trunk result in poor performance of a particular motor act in response to a verbal command (ideomotor apraxia).¹⁷ This type of apraxia is seen unilaterally in the left hand when the anterior callosal trunk is lesioned ("alien hand syndrome").^{18,19}

As a conclusion from this case, the hypothesis might be raised that lesions involving the anterior parts of the callosal body could selectively cause left-sided dyspraxia that presents as isolated higher-order disturbance of facial movement. In this sort of "disconnection syndrome," the preformed lateralization of the bilater-

ally organized corticonuclear tract for upper face innervation may be unmasked.

Accepted for publication August 13, 2003.

Author contributions: *Study concept and design* (Drs Korn and Becker); *acquisition of data* (Drs Korn, Reith, and Becker); *analysis and interpretation of data* (Drs Korn, Reith, and Becker); *drafting of the manuscript* (Drs Korn and Becker); *critical revision of the manuscript for important intellectual content* (Drs Korn, Reith, and Becker); *administrative, technical, and material support* (Drs Korn, Reith, and Becker); *study supervision* (Dr Becker).

This study was supported by the Universität des Saarlandes, Homburg/Saar, Germany.

During the review period, Dr Becker died in an accident. We are mourning for him.

Corresponding author: Thomas Korn, MD, Department of Neurology, Universität des Saarlandes, Kirrberger Str, 66421 Homburg/Saar, Germany (e-mail: netkor@uniklinik-saarland.de).

REFERENCES

1. Leiguarda RC, Marsden CD. Limb apraxias: higher-order disorders of sensorimotor integration. *Brain*. 2000;123:860-879.
2. Denny-Brown D. The nature of apraxia. *J Nerv Ment Dis*. 1958;126:9-32.
3. Liepmann H. Apraxie. *Ergebn ges Med*. 1920;1:516-543.
4. Geschwind N, Kaplan E. A human cerebral disconnection syndrome: a preliminary report. 1962. *Neurology*. 1998;50:1201.
5. Ghika J, Regli F, Assal G, Bogousslavsky J. Inability to voluntarily close the eyes. Discussion of supranuclear disorders in palpebral closure based on 2 cases, with a review of the literature [in French]. *Schweiz Arch Neurol Psychiatr*. 1988;139:5-21.
6. Belin C, Larmande J, Gaymard B, Larmande P. Loss of unilateral eye closure and right parietal lesion. *J Neurol Neurosurg Psychiatry*. 1988;51:1008.
7. Wada Y, Kita Y, Yamamoto T. Dissociation of voluntary eye closure—to keep the eyes closed and to blink—following right hemisphere stroke [in Japanese]. *No To Shinkei*. 2000;52:529-533.
8. Papagno C, Della SS. Crossed face apraxia. *J Neurol Neurosurg Psychiatry*. 2000;69:694-695.
9. Bizzozero I, Costato D, Sala SD, Papagno C, Spinnler H, Venneri A. Upper and lower face apraxia: role of the right hemisphere. *Brain*. 2000;123:2213-2230.
10. Meyer BU, Werhahn K, Rothwell JC, Roericht S, Fauth C. Functional organization of corticonuclear pathways to motoneurons of lower facial muscles in man. *Exp Brain Res*. 1994;101:465-472.
11. Geschwind N. Disconnection syndromes in animals and man, I. *Brain*. 1965;88:237-294.
12. Geschwind N. Disconnection syndromes in animals and man, II. *Brain*. 1965;88:585-644.
13. Haaland KY, Harrington DL, Knight RT. Neural representations of skilled movement. *Brain*. 2000;123:2306-2313.
14. Penfield W, Rasmussen T. *The Cerebral Cortex of Man*. New York, NY: MacMillan; 1950.
15. Heilman KM, Meador KJ, Loring DW. Hemispheric asymmetries of limb-kinetic apraxia: a loss of deftness. *Neurology*. 2000;55:523-526.
16. De Renzi E, Lucchelli F. Ideational apraxia. *Brain*. 1988;111:1173-1185.
17. Watson RT, Heilman KM. Callosal apraxia. *Brain*. 1983;106:391-403.
18. Bakchine S, Slachevsky A, Tourbah A, Serres J, Abdelmounni H. Four "alien" hands for two hands after a lesion in corpus callosum [in French]. *Rev Neurol (Paris)*. 1999;155:929-934.
19. Chan JL, Liu AB. Anatomical correlates of alien hand syndromes. *Neuropsychiatry Neuropsychol Behav Neurol*. 1999;12:149-155.