

disturbances but had a normal neurological examination. The second MRI showed that both the largest diameter and the maximal wall thickness had increased by 22.2 and 13.3 mm, respectively (fig. 1d), associated with a moderate ventricular enlargement.

Case 3. This 54-year-old man had a long history of hypertension and hypercholesterolemia. He was admitted after sudden onset of dizziness and dysarthria. Neurological examination performed 6 h later showed bilateral moderate distal upper limbs weakness, a left cerebellar ataxia and a bilateral Babinski sign. Ultrasound examination revealed an enlargement of right and left MCA associated with BADE. ECG was normal. MRI 1, performed on day 1, showed a recent right paramedian pontine infarct with a large BADE and brainstem compression. The BADE had an initial largest diameter of 23.5 mm and a maximal wall thickness of 13.5 mm including a mural thrombus (fig. 1e). After administration of aspirin the patient recovered and no further event occurred. A second MRI performed 7 months later showed an increase in both the diameter (now 26.9 mm) and the wall thickness (now 18.3 mm) of the BADE (fig. 1f). At 12 months, the clinical status was unchanged.

Discussion

These 3 cases of BADE had different patterns of presentation. In case 1, BADE was diagnosed by MRI showing an infarct in the left MCA deep territory, in case 2 it was identified due to a recent history of isolated severe headache, and in case 3 it had caused a right paramedian pontine infarct. The clinical course also differed considerably between our 3 cases. Patient 1 died a year later due to a sudden subarachnoid hemorrhage while the 2 other patients improved or remained stable during the same length of follow-up. These results are in accordance with the reported death rates (varying from 55% at 1 year [2] to 40% at 3 years [10] in small series of patients).

We observed that the patient who deceased 1 year after subarachnoid hemorrhage initially had the smallest wall thickness and the smallest diameter of BADE but later had the largest and fastest increase in diameter. The BADE expansion was also important in the second patient, who developed ventricular enlargement secondary to brainstem compression. The third case, who initially had both the largest BADE diameter and the largest wall thickness (including the thrombus) had no ischemic or hemorrhagic events during the 1-year follow-up. These data suggest that the initial diameter of the arterial ectasia is not the only prognostic parameter and that the combination of a thin wall and a rapid, important expansion may be more pejorative and predictive of rupture. In contrast, the height of the BADE bifurcation or its lateral displacement do not change before arterial rupture. These data are in line with those reported for aortic aneurysms often associated with BADE [11, 12], in which the risk of rupture is related not only to the size of the ectasia but also to the rate of expansion [13, 14].

References

- 1 Smoker WR, Corbett JJ, Gentry LR, Keyes WD, Price MJ, Mc-Kusker S: High-resolution computed tomography of the basilar artery 2. Vertebro-basilar dolichoectasia: Clinical-pathological correlation and review. *Am J Neuroradiol* 1986;7:61–72.
- 2 Haddad GF, Haddad FS: Cerebral giant serpentine aneurysm: Case reports and review of the literature. *Neurosurgery* 1988;23:92–97.
- 3 Yu YL, Moseley IF, Pullicino P, McDonald WI: The clinical picture of ectasia of intracerebral arteries. *J Neurol Neurosurg Psychiatry* 1982;45:29–36.

- 4 Inanasi J, Suga S, Stao S, Onozuka S, Kawase T: Long-term outcome of 17 cases of large-giant posterior fossa aneurysm. *Clin Neurol Neurosurg* 2000;102:65–71.
- 5 Nagahiro S, Takada A, Goto S, Kai Y, Ushio Y: Thrombosed growing aneurysm of the vertebral artery: Growth mechanism and management. *J Neurosurg* 1995;82:796–801.
- 6 Nakatomi H, Segawa H, Kurata A, Shiokawa Y, Nagat K, Kamiyama H, Ueki K, Kirino T: Clinicopathological study of intracranial fusiform and solichoectatic aneurysms. Insight on the mechanisms of growth. *Stroke* 2000;31:896–900.
- 7 Anson JA, Lawton MT, Spetzler RF: Characteristics and surgical treatment of dolichoectatic and fusiform aneurysms. *J Neurosurg* 1966;84:185–193.
- 8 Little JR, St Louis P, Weinstein M, et al: Giant fusiform aneurysm of the cerebral arteries. *Stroke* 1981;12:183–188.
- 9 Passero S, Filosomi G: Posterior circulation infarcts in patients with vertebrobasilar dolichoectasia. *Stroke* 1998;29:653–659.
- 10 Milandre L, Bonnefoi B, Pestre P, Pelissier JF, Grisoli F, Khalil R: Vertebrobasilar arterial dolichoectasia. Complications and prognosis. *Rev Neurol (Paris)* 1991;147:714–722 [in French].
- 11 Gautier JC, Hauw JJ, Awada A, Loron P, Gray F, Juillard JB: Dolichoectatic intracranial arteries. Association with aneurysms of the abdominal aorta. *Rev Neurol (Paris)* 1988;144:437–446 [in French].
- 12 Sacks JG, Lindenburg R: Dolicho-ectatic intracranial arteries: Symptomatology and pathogenesis of arterial elongation and distention. *Johns Hopkins Med J* 1969;125:95–106.
- 13 Limet R: Determination of level of expansion and incidence of rupture of abdominal aortic aneurysms. *Bull Mem Acad R Med Belg* 1992;147:253–264 [in French].
- 14 Powell JT, Brown LC: The natural history of abdominal aortic aneurysms and their risk of rupture. *Acta Chir Belg* 2001;101:11–16.

Hugues Chabriot, Service de Neurologie, Hôpital Lariboisière
2 rue Ambroise Paré, FR-75010 Paris (France)
Tel. +33 1 4995 2593, Fax +33 1 4995 2595
E-Mail hugues.chabriot@lrb.ap-hop-paris.fr

Cerebrovasc Dis 2004;17:264–266

DOI: 10.1159/000076964

Diffusion MRI in Pure Transient Global Amnesia Associated with Bilateral Vertebral Artery Dissection

D. Michel^a, P. Garnier^a, F. Schneider^b, A. Poujois^a, F.G. Barral^b, C. Thomas-Antérion^a

Departments of ^aNeurology and ^bNeuroradiology, University of Saint-Etienne, Saint-Etienne, France

Introduction

The clinical criteria for the diagnosis of transient global amnesia (TGA) have been well established [1]. TGA is characterized by an abrupt onset of massive anterograde amnesia accompanied by repetitive questioning and generally resolves within 24 h. Retrograde amnesia variable in extent is also present. During the attack, the patient appears perplexed, disoriented in time and place but remains alert and communicative with preservation of self-identity. Cognitive impairment is limited to amnesia (e.g. no aphasia or apraxia). Other focal neurological symptoms are absent.

Though pure TGA is a well-documented clinical entity, there is still uncertainty concerning the mechanism of neuronal dysfunction.

Fig. 1. The axial T₂-weighted images (TE/TR: 119/5,340 ms, FOV 17.2 × 23 cm, matrix 240 × 512, 6-mm slices, 3 NEX) obtained during the TGA show no abnormalities.

Fig. 2. On DWI, a hyperintensity was seen in the left thalamus corresponding to an ADC ratio decrease of 33%.

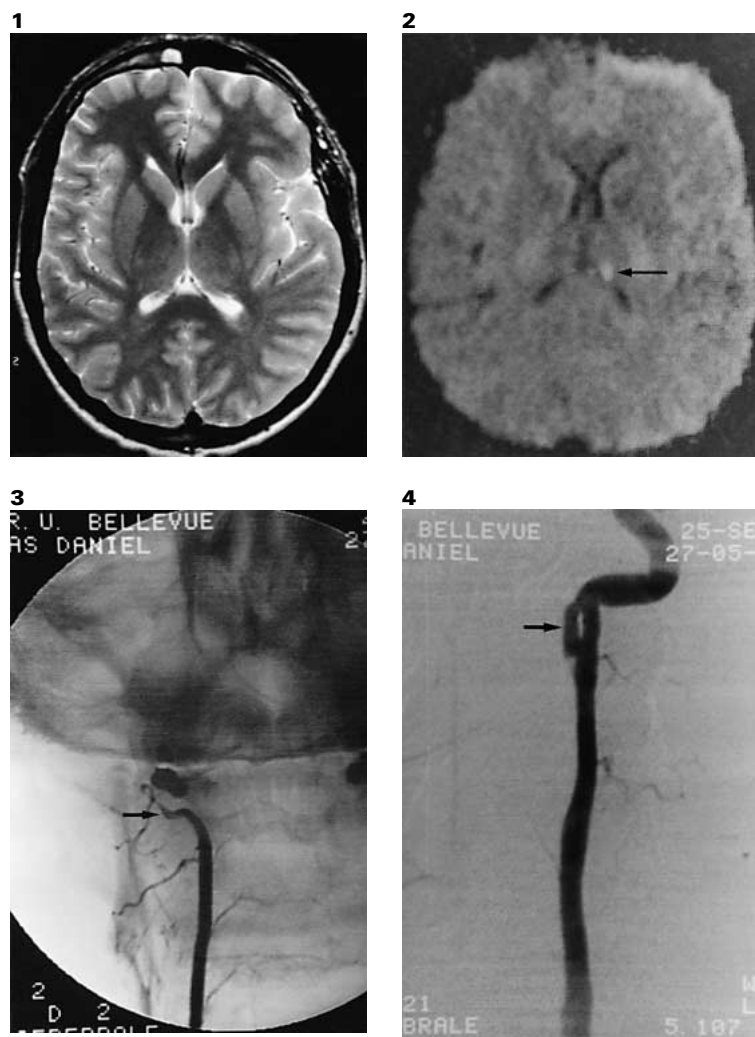


Fig. 3, 4. The cerebral angiography shows a tapered occlusion on the V2, V3 segment of the right vertebral artery (arrow in **3**) and a false channel on the V2 segment of the left vertebral artery (arrow in **4**).

Pure TGA has been shown to be associated with migraine, epilepsy and various precipitating events. We report a case of a young patient with a TGA, fulfilling the clinical criteria of Hodges and Warlow [1]. Diffusion-weighted imaging (DWI) with evaluation of the apparent diffusion coefficient (ADC) was performed during the active phase of the TGA. At the same time, a bilateral vertebral artery dissection was shown. So, this case raises the hypothesis that a pure TGA in a young subject could have the meaning of a vertebrobasilar transient ischaemic attack.

Case Report

A 27-year-old right-handed man was admitted to the hospital for an abrupt memory loss. He had no medical history of migraine headache, seizures or recent head injury. Over the previous 15 days, he had gone for several rides on a mountain bike. Moreover, he had been painting his ceiling during 1 day. During this period, he complained of an unusual cervical pain. In the course of his last mountain bike excursion, he repetitively queried about the bicycle pump, the cyclometer, the score of a recent football match, his job. His friend noted that he was not bewildered but abnormally quiet. He could easily drive his bike, then his car.

On admission at 1 a.m., about 10 h after onset, a senior neurologist noted a dense anterograde amnesia. The cognitive impairment was limited to amnesia. He had no behavioural manifestations. He was oriented to place but not to time and had no loss of personal identity. No accompanying neurological focal signs or symptoms were noted. The attack lasted about 13 h. The patient's amnesia was present throughout the MRI imaging procedures. T₁- and T₂-weighted images were normal (fig. 1). The diffusion-weighted images (double-spin echo, single-shot echo planar using two bipolar diffusion gradients in 3 orthogonal directions, b value: 1,000 s/mm², TE/TR: 166/4,712 ms, FOV 27.5 × 27.5 cm, matrix 128 × 128 zero filled to 256 × 256, 6-mm slices, 1 NEX) show a hyperintense signal in the left thalamus (fig. 2) corresponding to an ADC decrease of 33% compared to the mirror thalamus region. The following day, a vertebral angiography showed a dissection of the right (V2–V3 segments) and left (V2 segment) vertebral arteries (fig. 3, 4). The basilar artery was well injected. The echocardiography was normal. Anticoagulation was administered during the next 3 months.

Clinical evolution was favourable. At this time, neuropsychological tests were normal, except for the amnesia of the events and a very short retrograde amnesia (1 h). Two months later, T₂-weighted MRI

was normal. Magnetic resonance angiography showed a recanalization of the right vertebral artery and a small aneurysm on the left. The patient remained asymptomatic 18 months after his TGA.

Discussion

Although ischaemia has been proposed as a potential cause of pure TGA, there is still uncertainty concerning this hypothesis. In the cases related to a cerebrovascular event, the observed signs and symptoms were not consistent with a pure TGA. Focal neurological symptoms and signs like a blurred vision [2] or an alteration of the consciousness were present [3]. The impairment of memory did not resolve within 24 h and occurred 1 year before an acute thalamic infarct [4] or could be a coincident event [5]. Moreover, neither CT scan nor standard magnetic resonance studies were able to establish a temporal or causal relation between the cerebrovascular event and symptoms [4, 6]. A case of pure TGA, really due to a vascular cause, was reported in association with a simultaneous haemorrhage of the lentiform nucleus [6]. In SPECT studies during the attack [7], the distinction between flow reduction caused by a vascular disease and flow reduction secondary to neuronal dysfunction is difficult.

In our case, an exact temporal relation between TGA and the left thalamic abnormalities noted on DWI is established. Only a few magnetic resonance DWI studies have previously investigated pure TGA without evidence of cerebrovascular disease. In these studies, DWI was performed in the active or in the recovery phase. Images were normal [8, 9] or showed regressive elevated signals [10–13] in neuronal networks implicated in memory: the splenium of the corpus callosum, the right or left hippocampus and the medial basal temporal lobe. In our patient, a hyperintense signal on DWI was seen in the left thalamus during the active phase of the ictus. The corresponding ADC reduction (33%) was similar to that observed in long TIAs and less pronounced than in stroke patients [14].

Furthermore, the association with a bilateral vertebral artery dissection argues in our case also in favour of a transitory ischaemia even if pure TGA has not been published in vertebral artery disease [15]. Moreover, such DWI/ADC changes were also reported in a case report of TGA precipitated by cerebral angiography with a non-ionic contrast agent [11]. The authors concluded to an ischaemia due to emboli.

Some authors have proposed spreading depression as the underlying mechanism in TGA [10] like in migraine aura [16]. However, a spreading depression has never been proven in usual TGA. Although the underlying mechanism of pure TGA remains uncertain, we conclude to a relationship between transient ischaemia and pure TGA in our case. A pure TGA, particularly in a young subject, requires a search for a cerebrovascular disease.

References

- Hodges JR, Warlow CP: The aetiology of transient global amnesia: A case-control study of 114 cases with prospective follow-up. *Brain* 1990;113:639–657.
- Howard RS, Festenstein R, Mellers J, Kartsounis LD, Ron M: Transient amnesia heralding brain stem infarction. *J Neurol Neurosurg Psychiatry* 1992;55:977.
- Laterra J, Gebarski S, Chris Sackellares J: Transient amnesia resulting from vertebral artery dissection. *Stroke* 1988;19:98–101.
- Gorelick PB, Amico LL, Ganellen R, Benevento LA: Transient global amnesia and thalamic infarction. *Neurology* 1988;38:496–499.
- Kushner MJ, Hauser WA: Transient global amnesia: A case controlled study. *Ann Neurol* 1985;18:684–691.

- Bogousslavsky J, Regli F: Transient global amnesia and stroke. *Eur Neurol* 1988;28:106–110.
- Goldenberg G, Podreka I, Plaffelmeyer N, Wessely P, Deeke L: Thalamic ischemia in transient global amnesia: A SPECT study. *Neurology* 1991;41:1748–1752.
- Gaas A, Gaa J, Hirsch J, Schwartz A, Hennerici MG: Lack of evidence of acute ischemic tissue change in transient global amnesia on single short echoplanar diffusion-weighted MRI. *Stroke* 1999;30:2070–2072.
- Budson AE, Schlaug G, Briemberg HR: Perfusion and diffusion weighted magnetic resonance imaging in transient global amnesia. *Neurology* 1999;53:239–240.
- Strupp M, Brüning R, Wu RH, Deimling M, Reiser M, Brandt T: Diffusion-weighted MRI in transient global amnesia: Elevated signal intensity in the left mesial temporal lobe in 7 of 10 patients. *Ann Neurol* 1998;43:164–170.
- Woolfenden AR, O'Brien MW, Schwartzberg RE, Norbash AM, Tong DC: Diffusion-weighted MRI in transient global amnesia precipitated by cerebral angiography. *Stroke* 1997;28:2311–2314.
- Ay H, Furie KL, Yamada K, Koroshetz WJ: Diffusion-weighted MRI characterizes the ischemic lesion in transient global amnesia. *Neurology* 1998;51:901–903.
- Matsui M, Imamura T, Sakamoto S, Ishii K, Kazui H, Mori E: Transient global amnesia: Increased signal intensity in the right hippocampus on diffusion-weighted magnetic resonance imaging. *Neuroradiology* 2002;44:235–238.
- Kidwell CS, Alger JR, Di Salle F, Starkman S, Villablanca P, Benston J, Saver JL: Diffusion MRI in patients with transient ischemic attacks. *Stroke* 1999;30:1174–1180.
- Mokri B, Houser WH, Sandok BA, Piepgras DG: Spontaneous dissections of the vertebral arteries. *Neurology* 1988;38:880–885.
- Hadjikhani N, Sanchez Del Rio M, Wu O, Schwartz D, Bakker D, Fischl B, Kwong KK, Cutrer FM, Rosen BR, Tootell RBH, Sorensen AG, Moskowitz MA: Mechanisms of migraine aura revealed by functional MRI in human visual cortex. *Proc Natl Acad Sci USA* 2001;98:4687–4692.

Daniel Michel, MD

Department of Neurology, Hôpital Bellevue

FR-42055 Saint-Etienne Cedex (France)

Tel. +33 4 7712 7805, Fax +33 4 7712 0543

E-Mail daniel.r.michel@free.fr

Cerebrovasc Dis 2004;17:266–268

DOI: 10.1159/000076965

Crescendo Transient Ischemic Attacks due to Middle Cerebral Artery Stenosis

Konstantinos Spengos^a, Marios Panas^a, Georgios Tsivgoulis^a, Konstantinos Vemmos^b, Konstantinos Sfagos^a, Demetris Vassilopoulos^a

^aDepartment of Neurology, University of Athens Medical School, Eginition Hospital, and ^bDepartment of Clinical Therapeutics, Acute Stroke Unit, University of Athens Medical School, Alexandra Hospital, Athens, Greece

Crescendo transient ischemic attacks (TIAs) are defined as disabling, recurrent transient cerebral ischemic episodes, which are characterized by an increasing frequency, duration, or severity of events [1, 2] indicative of a critical narrowing of the lumen of the involved artery by an atherosclerotic plaque with superimposed thrombus [3].