

Case Report

Middle cerebral artery thrombosis in course of parvovirus B19 infection in a young adult: A new risk factor for stroke?

Jessica Mandrioli,¹ Marinella Portolani,² Pietro Cortelli,¹ and Patrizia Sola¹

¹Department of Neuroscience and ²Laboratory Medicine Department, University of Modena and Reggio Emilia, Modena, Italy

Previous infection, both of bacterial and viral origin, is reported to represent an independent risk factor for ischemic stroke in children and young adults. The authors describe the case of an immunocompetent young woman who developed a middle cerebral artery thrombosis and stroke in course of a recurrence of human parvovirus B19 (PVB19) infection. A previously healthy 25-year-old woman developed right ataxic hemiparesis, 5 days after the onset of a flulike syndrome. Magnetic resonance imaging of the brain revealed acute multiple left frontal-parietal ischemic lesions. Conventional and magnetic resonance angiograms revealed a stenosis in the left middle cerebral artery. Nested polymerase chain reaction detected PVB19-specific DNA sequences in the cerebrospinal fluid and blood, and serology showed high titers of high avidity immunoglobulin G against PVB19. After 10 days, the patient's recovery was nearly complete. One month later, PVB19 disappeared from the serum, whereas it persisted in the peripheral blood mononuclear cells. This case report suggests that PVB19 infection may play a trigger role in the development of ischemic stroke, and that it should be considered in the screening of infectious risk factors for cerebrovascular diseases in young adults. *Journal of NeuroVirology* (2004) 10, 71–74.

Keywords: human parvovirus B19; stroke; young people

Introduction

There is increasing evidence that recent infection, both viral and bacterial may represent an independent risk factor for stroke, mostly in young people (Grau *et al.*, 1998).

We report the case of an ischemic stroke occurred in a 25-year-old immunocompetent woman, in whom a possible association with parvovirus B19 (PVB19) infection was suggested by the results of virological investigations.

Case report

A 25-year-old healthy woman developed mild weakness and numbness to the right arm 5 days after the

onset of a flulike syndrome with fever. In the days after fever disappeared, she had profuse diarrhea and nausea, and she was admitted for the worsening of right arm paresthesias and weakness. On history, the relevant risk factors were mild smoking habit and oral contraceptives assumption. Neurological examination showed right ataxic hemiparesis, right central facial nerve palsy, and right hemianopsia. Brain magnetic resonance imaging (MRI) showed multiple left fronto-parietal ischemic lesions (Figure 1A). MR angiography (MRA) and conventional angiography revealed partial thrombosis of the left middle cerebral artery (MCA), and congenital hypoplasia of the right MCA only (Figure 1B).

Extracranial doppler ultrasound and transthoracic and transesophageal echocardiography were normal. Standard blood examination revealed a mild increase of white blood cell count, erythrocyte sedimentation rate and C-reactive protein, whereas hematocrit, hemoglobin, erythrocytes, total blood serum protein, immunoglobulins, and electrolytes were normal.

Address correspondence to Patrizia Sola, MD, PhD, Department of Neuroscience, University of Modena, Via Del Pozzo n. 71, 41100 Modena, Italy. E-mail: sola.patrizia@unimo.it

Received 20 August 2003; revised 17 September 2003; accepted 27 September 2003.

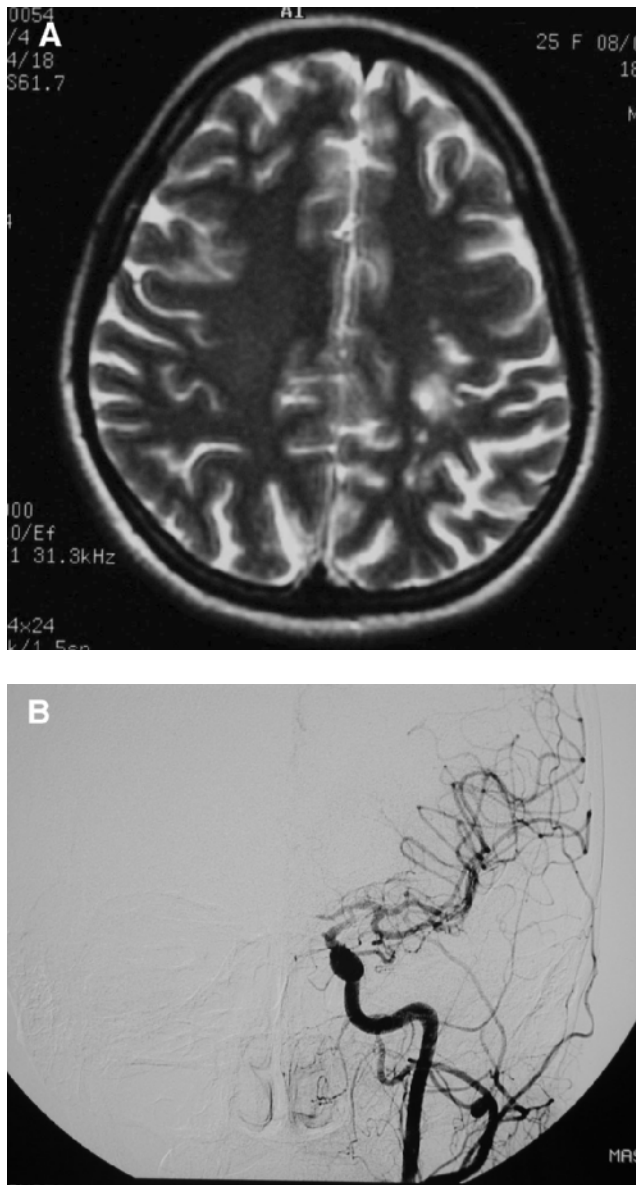


Figure 1 (A) MR T2-weighted spin-echo axial scan: hyperintense multiple ischemic lesions in the left frontal-parietal white matter. (B) Conventional angiography: lack of visualization of the left MCA.

All coagulation tests, including antithrombin III, protein C and S activities, activated protein C resistance, and homocysteine were normal. Factor V Leiden mutation was absent. Plasmatic autoantibodies search was negative for lupus anticoagulant, antinuclear antibodies, antibodies to extractable nuclear antigens, anti-neutrophil cytoplasm autoantibodies, anticardiolipin antibodies, and cryoglobulins.

Cerebrospinal fluid (CSF) cell count and total proteins were normal, oligoclonal immunoglobulin G (IgG) bands, intrathecal IgG synthesis, and blood-brain barrier damage were absent.

Serum and CSF antibodies to *Borrelia burgdorferi* and *Treponema pallidum*, and CSF culture for

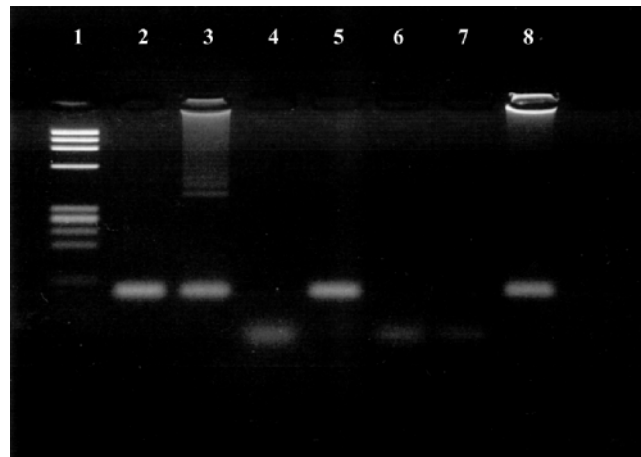


Figure 2 PVB19 DNA searched for in CSF, serum, and PBLs samples by nPCR. Lanes 1 = *Phi* X 174 DNA/Hae III marker; lane 2 = CSF (March 16); lane 3 = serum sample (March 16); lane 4 = plasma sample (April 22); lane 5 = PBLs (April 22); lanes 6 and 7 = negative control; lane 8 = PVB19 DNA positive control. Electrophoresis on 3% agarose gel; ethidium bromide staining.

bacteria and fungi were negative. CSF and blood nested polymerase chain reaction (nPCR) assays resulted negative for herpes simplex virus (HSV) 1 and 2, cytomegalovirus, human immunodeficiency virus (HIV), Epstein-Barr, influenza and parainfluenza viruses, adenovirus, and enteroviruses; on the contrary, both biological materials proved nPCR positive when tested for PVB19 DNA (Durigon *et al*, 1993) (Figure 2). Search for PVB19 antibodies revealed high content of anti-PVB19 IgG at high avidity, as demonstrated by results of urea treatment, in absence of detectable IgM (Table 1). After 10 days, the patient completely recovered.

One month later, the ischemic lesion was unchanged at MRI, whereas MRA revealed a reduction of the MCA stenosis. Repeated nPCR evidenced the disappearance of PVB19 DNA from the patient's serum, whereas it was still detectable in the peripheral blood lymphocytes (PBLs) (Table 1, Figure 2).

Table 1 Results of PVB19 DNA n-PCR and seroimmunological assays

Sample	PVB19 DNA	PVB19 antibodies*	
		IgM	IgG
CSF (March 16)	+	0.13	0.04
Serum (March 16)	+	0.28	9.57
Plasma (April 22)	-	0.28	9.18
PBLs (April 22)	+		

*PVB19 IgM and IgG antibody content is expressed as antibody index: serum sample optical density (OD) value/cut-off OD value; positive value >1.

Search for PVB19 antibodies performed by ELISA commercial kits (Denka, Seiken, Tokyo, Japan) revealed high content of anti-PVB19 IgG at high avidity: IgG value 9.2 after urea treatment of the serum sample (March 16).

Discussion

A young woman developed an ischemic stroke 5 days after a flulike syndrome. The only relevant risk factors for cerebrovascular disorders were mild smoking habit and oral contraceptives assumption. A possible hyperviscosity state due to febrile illness and diarrhea was excluded by proper hematological tests, which failed to reveal dehydration and hemoconcentration findings, whereas an inflammatory condition was present. Virological investigations led to PVB19 DNA detection both in the patient's blood and CSF. Because long periods of viremia may occur after PVB19 primary infection (Musiani *et al*, 1995), the presence of PVB19 in the blood of a sick subject could be just accidental and unrelated with his current illness. Nevertheless, in the present case, the presence of PVB19 in the CSF in addition to the blood in course of the acute neurological manifestation, together with the disappearance of viral DNA from the blood after the patient's recovery, suggest a pathogenetic role for the virus. PVB19 (Parvoviridae family) is a widespread, small, single-stranded DNA virus, with seropositive rates reaching 60% in young adults (Heegaard and Brown, 2002). The most common clinical manifestation is erythema infectiosum, but also flulike symptoms without rash are reported (Anderson, 1990). A large spectrum of acute and chronic complications are associated with PVB19 infection and the cases of neurological (Koduri and Naides, 1995) and vascular (Fawaz-Estrup, 1996) disorders support the ability of PVB19 to reach the central nervous system (CNS) and cause vascular injury. Two mechanisms may be involved in the development of endothelial damage and artery thrombosis by PVB19: the production of circulating immune complexes, with subsequent deposition, and/or a direct action of the virus on the endothelium. Because in our patient no increased circulating immunocomplexes were detected, a direct vascular injury by PVB19 appears to be more likely. Moreover, the cellular receptor for PVB19, the P antigen, is expressed not only on erythroid progenitor cells but also on endothelial cells (Brown *et al*, 1993), and PVB19 DNA has been detected by "in situ" PCR into endothelial cells in a case of fetal brain infection (Isumi *et al*, 1999). Once the capsid protein VP2 has interacted with the endothelial P-antigen receptor, it may trigger the inflammatory cascade through two viral nonstructural proteins, NS1 and NS2. In particular,

NS1 exerts cell cytotoxicity and triggers an inflammatory reaction through the induction of the proinflammatory interleukin-6 gene expression (Moffatt *et al*, 1996).

The hypothesis of an involvement of PVB19 in stroke development is also supported by the cases of prenatal stroke during maternal infection (Craze *et al*, 1996), thrombotic microangiopathy on the graft kidney (Murer *et al*, 2000), and the increased risk of stroke in children with homozygous sickle cell disease (Wierenga *et al*, 2001) in course of PVB19 infection.

Previous infection is a known risk factor for stroke, and several viral agents have been suspected to be involved in the pathogenesis of cerebral ischemia, including varicella-zoster virus, HIV, cytomegalovirus, herpes simplex virus (HSV) (Lindsberg and Grau, 2003). Pathogens may exert an atherogenic action by inducing a procoagulant state by the inhibition of the anticoagulant system (proteins C and S), by increasing fibrinogen levels, fibrin generation, thromboplastin expression, and cardiolipin immunoreactivity, and by inducing serum cytokines production, leading to endothelial damage. Other reported mechanisms linking infection with stroke include emboli from infected heart valves, and small and large vessels vasculitis (Grau *et al*, 1998; Lindsberg and Grau, 2003).

In the present case, the PVB19 antibody pattern, characterized by absence of IgM and high content of IgG at high avidity, suggests an endogenous reactivation of PVB19, whereas a recently reported case of stroke in an immunocompetent child (Guidi *et al*, 2003) was associated with a PVB19 primary infection. Up to now, PVB19 recurrent infection with clinical manifestations usually involving rapidly dividing blood cellular components, have been reported only in people with impaired immune system (Brown, 2000). The present case suggests that PVB19 reactivation may occur in immunocompetent and previously healthy persons and may be followed by unusual clinical pictures.

In conclusion, the angiopathic potential and the ability to reach the central nervous system (CNS) of PVB19, as confirmed by several literature reports (Murer *et al*, 2000; Wierenga *et al*, 2001) and two cases of ischemic stroke diagnosed in course of PVB19 infection (Craze *et al*, 1996; Guidi *et al*, 2003), warrant the inclusion of this virus among the infectious agents that should be considered as a possible risk factors for stroke in young people.

References

- Anderson LJ (1990). Human parvoviruses. *J Infect Dis* **161**: 603–608.
- Brown KE (2000). Haematological consequences of parvovirus B19 infection. *Baillieres Best Pract Res Clin Haematol* **13**: 245–259.
- Brown KE, Anderson SM, Young NS (1993). Erythrocyte P antigen: cellular receptor for B19 parvovirus. *Science* **262**: 114–117.
- Craze JL, Salisbury AJ, Pike MG (1996). Prenatal stroke associated with maternal parvovirus infection. *Dev Med Child Neurol* **38**: 84–85.

- Durigon EL, Erdman DD, Gary GW, Pallansch MA, Torok T, Anderson LJ (1993). Multiple primer pairs for polymerase chain reaction (PCR) amplification of human parvovirus B19 DNA. *J Virol Methods* **44**: 155–165.
- Fawaz-Estrup F (1996). Human parvovirus infection: rheumatic manifestations, angioedema, C1 esterase inhibitor deficiency, ANA positivity, and possible onset of systemic lupus erythematosus. *J Rheumatol* **23**: 1180–1185.
- Grau AJ, Buggle F, Becher H, Zimmermann E, Spiel M, Fent T, Maiwald M, Werle E, Zorn M, Hengel H, Hacke W (1998). Recent bacterial and viral infection is a risk factor for cerebrovascular ischemia: clinical and biochemical studies. *Neurology* **50**: 196–203.
- Guidi B, Bergonzini P, Crisi G, Frigieri G, Portolani M (2003). Case of stroke in a 7-year-old male after parvovirus B19 infection. *Pediatr Neurol* **28**: 69–71.
- Heegaard ED, Brown KE (2002). Human parvovirus B19. *Clin Microbiol Rev* **15**: 485–505.
- Isumi H, Nunoue T, Nishida A, Takashima S (1999). Fetal brain infection with human parvovirus B19. *Pediatr Neurol* **21**: 661–663.
- Koduri PR, Naides SJ (1995). Aseptic meningitis caused by parvovirus B19. *Clin Infect Dis* **21**: 1053.
- Lindsberg PJ, Grau AJ (2003). Inflammation and infections as risk factors for ischemic stroke. *Stroke* **34**: 2518–2532.
- Moffatt S, Tanaka N, Tada K, Nose M, Nakamura M, Muraoka O, Hirano T, Sugamura K (1996). A cytotoxic nonstructural protein, NS1, of human parvovirus B19 induces activation of interleukin-6 gene expression. *J Virol* **70**: 8485–8491.
- Murer L, Zacchello G, Bianchi D, Dall'Amico R, Montini G, Andretta B, Perini M, Dossi EC, Zanon G, Zacchello F (2000). Thrombotic microangiopathy associated with parvovirus B19 infection after renal transplantation. *J Am Soc Nephrol* **11**: 1132–1137.
- Musiani M, Zerbini M, Gentilomi G, Plazzi M, Gallinella G, Venturoli S (1995). Parvovirus B19 clearance from peripheral blood after acute infection. *J Infect Dis* **172**: 1360–1363.
- Wierenga KJ, Serjeant BE, Serjeant GR (2001). Cerebrovascular complications and parvovirus infection in homozygous sickle cell disease. *J Pediatr* **139**: 438–442.