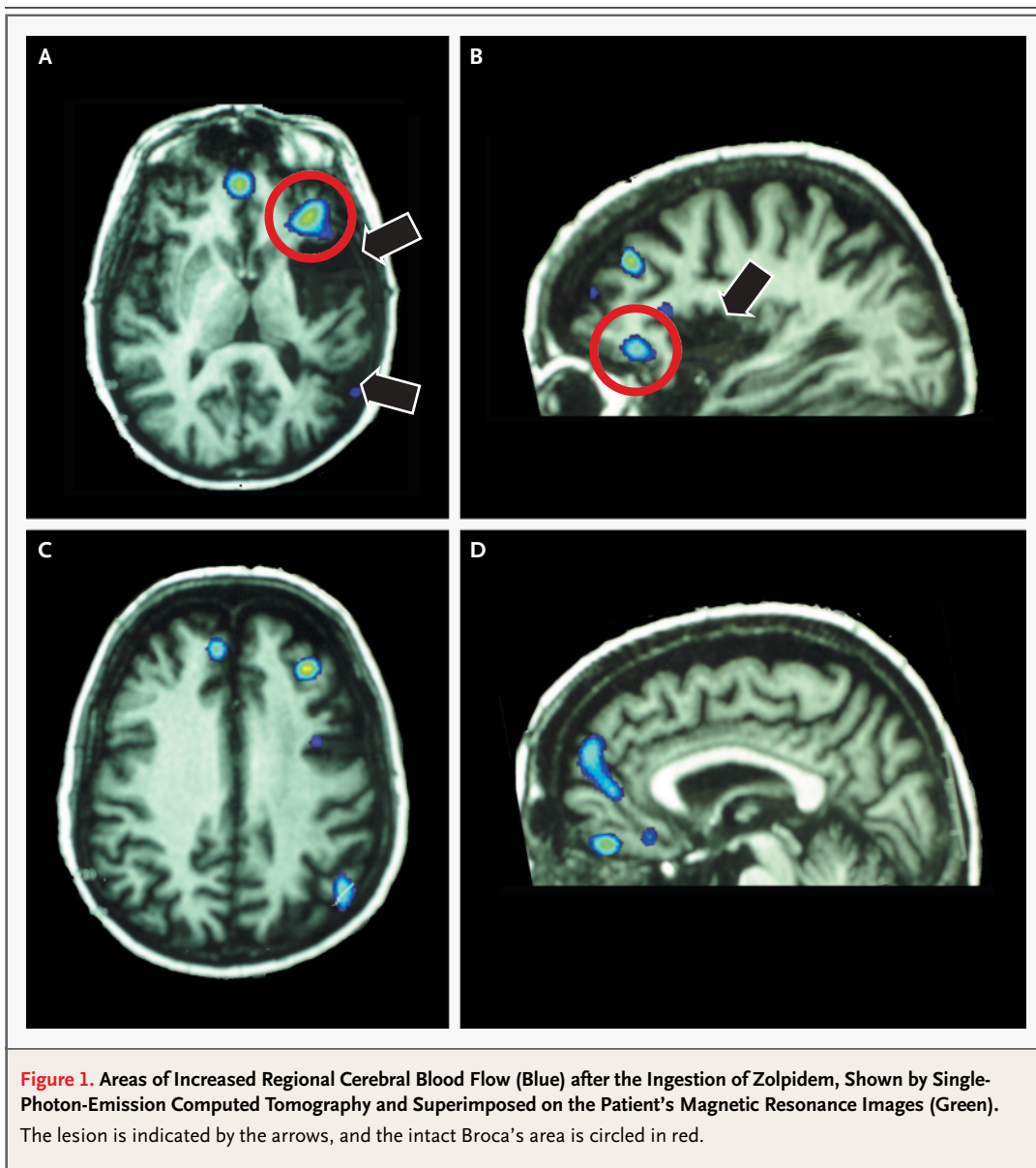


Transient Improvement of Aphasia with Zolpidem

TO THE EDITOR: There is currently no effective pharmacologic treatment for chronic aphasia, a frequent and incapacitating consequence of hemispheric stroke. We report the case of a 52-year-old right-handed woman, who had a stroke that affected her left insula, putamen, and superior temporal gyrus. Three years later, her speech was still restricted to stereotyped syllables, with not a single

identifiable word. Language comprehension was better preserved. Because of occasional insomnia, zolpidem (10 mg) was prescribed. To the amazement of the patient and her family, ingestion of the first dose was followed by a dramatic improvement in her speech, which persisted until the patient went to bed later in the night. On the following morning, aphasia had returned at its usual level of



severity. This phenomenon was systematically reproducible, reflecting a regular temporal pattern. About 20 minutes after the ingestion of zolpidem, the patient regained effective speech abilities, and zolpidem did not induce major sleepiness. She then engaged in meaningful, albeit telegraphic, speech, consisting of sentence fragments with accurately selected words. In contrast to her basal status, she could repeat most single words and pseudowords, and the first words of sentences; she was able to name most pictures of objects correctly and count up to 10.

An electroencephalogram showed slow waves over the left temporal region and did not change with ingestion of zolpidem. Single-photon-emission computed tomography with technetium-99m-labeled ethyl-cysteinate dimer showed an area of nonperfusion overlapping the lesion, with moderate hypoperfusion in contiguous frontal and parietal areas. Thirty minutes after the ingestion of zolpidem, an increase in regional cerebral blood flow of 35 to 40 percent was observed in Broca's area, in the left middle frontal and supramarginal gyri, and bilaterally in the orbitofrontal and mesial frontal cortex (Fig. 1). The patient left France after the completion of these studies. No follow-up information is available.

Zolpidem is a benzodiazepine agonist selective for α_1 subunit-containing γ -aminobutyric acid (type A) receptors.^{1,2} Apart from its hypnotic properties, it markedly improves catatonia.³ In a patient with complete mutism and akinesia, treatment with zolpidem resulted in transient recovery of effective verbal and gestural interaction, effects that were

concomitant with increased regional cerebral blood flow in left-hemispheric structures.⁴

Considering the complete stability of aphasia over a period of years and the increase in regional cerebral blood flow with zolpidem, it seems unlikely that the improvement of speech in our patient resulted from the suppression of a seizure. One may speculate that the lesion, possibly in the lentiform nucleus,⁵ impeded the operation of intact structures involved in language production, including Broca's area and the mesial frontal cortex. Zolpidem may transiently counteract this dynamic diaschisis, allowing for improved functioning of the residual language network. A selected subgroup of patients with aphasia, perhaps with subcortical lesions and spared but hypometabolic cortical structures, might benefit from this treatment.

Laurent Cohen, M.D., Ph.D.
Bassem Chaaban, M.D.
Marie-Odile Habert, M.D.

Hôpital de la Salpêtrière
75651 Paris CEDEX 13, France

1. Depoortere H, Zivkovic B, Lloyd KG, et al. Zolpidem, a novel nonbenzodiazepine hypnotic. I. Neuropharmacological and behavioral effects. *J Pharmacol Exp Ther* 1986;237:649-58.
2. Finelli LA, Landolt HP, Buck A, et al. Functional neuroanatomy of human sleep states after zolpidem and placebo: a H215O-PET study. *J Sleep Res* 2000;9:161-73.
3. Thomas P, Rasclé C, Mastain B, Maron M, Vaiva G. Test for catatonia with zolpidem. *Lancet* 1997;349:702.
4. Clauss RP, Guldenpfennig WM, Nel HW, Sathekge MM, Venkannagari RR. Extraordinary arousal from semi-comatose state on zolpidem: a case report. *S Afr Med J* 2000;90:68-72.
5. Russmann H, Vingerhoets F, Ghika J, Maeder P, Bogousslavsky J. Acute infarction limited to the lenticular nucleus: clinical, etiologic, and topographic features. *Arch Neurol* 2003;60:351-5.

Breakthrough Zygomycosis after Voriconazole Treatment in Recipients of Hematopoietic Stem-Cell Transplants

TO THE EDITOR: The Food and Drug Administration (FDA) approved voriconazole for the treatment of invasive aspergillosis partly on the basis of data published in a report in the *Journal*,¹ which showed an improved clinical response and improved survival with voriconazole treatment as compared with a strategy of initial treatment with amphotericin B deoxycholate. In patients with neutropenia and persistent fever, the use of voriconazole as empirical therapy failed to fulfill criteria for noninferiority as

compared with liposomal amphotericin B,² and the results of that trial generated substantial discussion after the FDA declined approval of the drug for that indication.³ Nevertheless, the use of voriconazole has become common in the management of neutropenia and persistent fever, in the treatment of high-risk patients with pneumonia, and as prophylaxis in patients who are at risk for the development of invasive fungal infections. These uses of voriconazole are probably attributable to its lower overall tox-