

The impact of extensive medial frontal lobe damage on ‘Theory of Mind’ and cognition

Chris M. Bird,¹ Fulvia Castelli,¹ Omar Malik,² Uta Frith¹ and Masud Husain^{1,2}

¹*Institute of Cognitive Neuroscience, University College London, and* ²*Division of Neuroscience and Psychological Medicine, Imperial College London, Charing Cross Hospital, London, UK*

Correspondence to: C. Bird, 17 Queen Square, London WC1N 3AR, UK. E-mail: chris.bird@ucl.ac.uk

Summary

The ability of humans to predict and explain other people’s behaviour by attributing to them independent mental states, such as desires and beliefs, is considered to be due to our ability to construct a ‘Theory of Mind’. Recently, several neuroimaging studies have implicated the medial frontal lobes as playing a critical role in a dedicated ‘mentalizing’ or ‘Theory of Mind’ network in human brains. Here, we report a patient, G.T., who suffered an exceptionally rare form of stroke—bilateral anterior cerebral artery infarction, without rupture or the complications associated with anterior communicating artery aneurysms. Detailed high-resolution neuroanatomical investigations revealed extensive damage to the medial frontal lobes bilaterally, including regions identified to be critical for ‘Theory of Mind’ by functional neuroimaging of healthy human subjects. For the first time in such a patient, we carried

out a thorough assessment of her cognitive profile including, critically, an experimental investigation of her performance on a range of tests of ‘Theory of Mind’. G.T. had a dysexecutive syndrome characterized by impairments in planning and memory, as well as a tendency to confabulate. Importantly, however, she did not have any significant impairment on tasks probing her ability to construct a ‘Theory of Mind’, demonstrating that the extensive medial frontal regions destroyed by her stroke are not necessary for this function. These findings have important implications for the functional anatomy of ‘Theory of Mind’, as well as our understanding of medial frontal function. Possible reasons for the discrepancies between our results and neuroimaging studies are discussed. We conclude that our findings urge caution against using functional imaging as the sole method of establishing cognitive neuroanatomy.

Keywords: Theory of Mind; mentalizing; medial frontal; anterior cingulate; anterior cerebral artery

Abbreviations: ACA = anterior cerebral artery; BA = Brodmann area; BADS = Behavioural Test of the Dysexecutive Syndrome; fMRI = functional MRI; IQ = intelligence quotient; NART-R = National Adult Reading Test—Revised; ToM = Theory of Mind; WAIS-R = Wechsler Adult Intelligence Scale—Revised.

Received June 13, 2003. Revised November 4, 2003. Accepted December 14, 2003. Advanced Access publication March 3, 2004

Introduction

Recently there has been considerable interest in the brain structures underpinning various aspects of social cognition (e.g. Adolphs, 2003). A particularly important focus of research has been the ability of humans to attribute mental states to others. Such an ability to form a ‘Theory of Mind’ (ToM) or to ‘mentalize’ is considered vital for our understanding of complex social interactions that we encounter every day (e.g. Frith, 2001). Indeed, one leading hypothesis regarding the abnormal social behaviour of adults and children with autism contends that this might specifically be due to an impaired ToM (Baron-Cohen *et al.*, 1985; Baron-Cohen, 1995). Evidence from neuroimaging and neuropsychological studies has led researchers to conclude that ToM is subserved by dedicated brain systems, including the amygdala, temporo-parietal junction, orbital frontal cortex and, in particular, the medial frontal lobes (Siegal and Varley, 2002; Frith and Frith, 2003).

Several neuroimaging studies, commencing with the work of Fletcher *et al.* (1995), have implicated the medial frontal region as having a role in comprehending stories with a ToM component. These investigators used an advanced ToM test that involves the comprehension of non-literal utterances associated with, for example, tact or a double bluff, and shown to be sensitive to ToM impairments in an autistic

population (Happé, 1995). The critical contrast between ToM stories and physical stories revealed activation in the medial aspects of Brodmann area (BA) 8. A subsequent report (Happé *et al.*, 1996) used the same tests in five individuals with Asperger's syndrome (a milder form of autism that is often distinguished from other forms of autism by the lack of linguistic or cognitive delay; e.g. Coleman and Gillberg, 1995). ToM stories also activated the medial frontal lobes in the Asperger individuals, albeit an area inferior to the one most strongly activated in the healthy controls (BA 9/10 versus BA 8). A subsequent functional MRI (fMRI) study (Gallagher *et al.*, 2000) confirmed that, amongst other regions, the medial prefrontal cortex was activated in ToM conditions in healthy subjects. This latter study also documented activation in the same medial frontal area when participants viewed cartoons with a ToM component.

Other investigations of brain regions involved in mentalizing have used different tasks, but found very similar activations in medial frontal cortex (Goel *et al.*, 1995; Baron-Cohen *et al.*, 1999b; Brunet *et al.*, 2000; Castelli *et al.*, 2000; McCabe *et al.*, 2001; Vogeley *et al.*, 2001; Berthoz *et al.*, 2002; Gallagher *et al.*, 2002; Wicker *et al.*, 2003). The results of these studies have been used to argue that the medial frontal lobes play a critical role in a dedicated mentalizing system (Frith and Frith, 2003; Gallagher and Frith, 2003). However, while functional imaging studies are very useful for identifying brain areas sufficient for the neural underpinning of cognition functions, they cannot identify areas that are necessary for these functions (Price and Friston, 2002). An important way to test whether areas identified by functional imaging studies are necessary to perform the tasks of interest is through detailed neuropsychological and neuroanatomical investigation of patients with brain damage.

Although there have been several studies of mentalizing abilities in patients with acquired brain lesions (Stone *et al.*, 1998, 2003; Happé *et al.*, 1999; Channon and Crawford, 2000; Rowe *et al.*, 2001; Stuss *et al.*, 2001; Gregory *et al.*, 2002; Shamay-Tsoory *et al.*, 2003), the neuropsychological literature relevant specifically to the medial frontal cortex is sparse. To the best of our knowledge, only three studies have included patients with relatively focal medial frontal lobe damage and have sought to investigate correlations between specific frontal brain areas and performance on ToM tasks (Rowe *et al.*, 2001; Stuss *et al.*, 2001; Shamay-Tsoory *et al.*, 2003). However, as we discuss below, there are important limitations to these investigations.

A recent large group study (Stuss *et al.*, 2001) reported the results of two ToM tasks in 19 patients with frontal lesions and 13 patients with non-frontal lesions. Patients with right frontal and bilateral frontal lobe damage were impaired on a task examining the ability to infer visual experience in others. There were no significant correlations between performance and specific lesion locations. On a second task, which examined the ability to infer when somebody tries to deceive, patients with bilateral frontal lesions were most impaired. Furthermore, damage to right superior and inferior medial

frontal areas, and the right anterior cingulate, correlated significantly with number of errors. Thus, there is at least preliminary evidence that acquired brain damage to the medial frontal lobes does impact on ToM ability. However, there are some important caveats.

Although the aetiology of brain damage for each patient is not reported, the text implies that most of the bifrontal group had suffered head trauma. It is often very difficult to assess reliably the extent of brain damage after head trauma as widespread damage can often occur through axonal shearing and other effects (e.g. Pang, 1989). Often, head trauma patients may exhibit profound cognitive deficits while structural scans can appear normal (e.g. Richardson, 2000). In addition, it is difficult to compare accurately the results of this study with those from neuroimaging studies for at least two reasons. First, the tasks have never been investigated using neuroimaging techniques and therefore it is uncertain whether the same areas would be implicated. Secondly, comparison of brain areas damaged in the patients with those areas implicated using functional imaging is not easy as exact lesion locations for individual patients are not shown and lesion overlap figures are of inadequate resolution. Furthermore, correlational analyses were only performed using rather large anatomical regions.

The second neuropsychological study (Rowe *et al.*, 2001) enrolled 31 patients with unilateral lesions of the frontal lobes and documented significantly impaired performance on both first order and second order ToM tests. Further analyses revealed that patients with left and right-sided lesions were equally impaired, while lesion size was unrelated to performance. Importantly, no effect of lesion location was found when comparing patients with focal dorsolateral, medial or orbital frontal lesions. It is possible that this is due to the underlying aetiologies. For example, nearly half of the patients had received surgical treatment for intractable epilepsy, and it is widely accepted that longstanding epilepsy may be associated with an atypical cerebral organization of cognitive function.

Finally, a recent group study of empathy in patients (Shamay-Tsoory *et al.*, 2003) also included an assessment of performance on the Faux Pas Test, a probe of ToM ability. Patients with frontal lobe lesions were impaired on this task. Specifically, 12 patients with ventromedial frontal lobe damage made significantly more errors than patients with posterior lesions or healthy controls on the Faux Pas Test. Importantly, however, there was no significant difference in the numbers of errors made by this group and seven patients with dorsolateral frontal lobe lesions; detailed anatomical data regarding the critical lesions that impaired performance on the Faux Pas Test were not reported. However, a detailed analysis of lesion sites associated with empathy deficits was performed, revealing a particularly important role for the right ventromedial frontal lobe, inferior to and distinct from the area implicated by neuroimaging studies as being involved in ToM, and consistent with the results of a previous study of empathy in frontal patients (Grattan *et al.*, 1994).

Although there was a correlation between empathy and ToM scores, the precise relationship between these processes remains unclear. It should also be noted that a large proportion of the patients in this study also had suffered head trauma, making detailed assessment of lesion location problematic.

In summary, a large number of neuroimaging studies have identified medial prefrontal areas as important for understanding interactions involving ToM. However, the findings from patients with circumscribed lesions to the frontal lobes have been much less specific in the neuroanatomy underpinning normal or impaired performance on these tasks. This is largely due to the scarcity of patients with damage to medial frontal areas that is not associated with head injury. Bilateral medial frontal damage may occur as a result of a ruptured anterior communicating artery aneurysm. However, brain damage in these patients may not be confined to the medial frontal region because of the remote effects of vasospasm and transient hydrocephalus that may occur in this condition (e.g. Bottger *et al.*, 1998; Leclerc *et al.*, 2002). Moreover, the medial frontal regions that are damaged often do not extend to cover all the medial frontal cortex bilaterally (see Bottger *et al.*, 1998).

There is one group of patients, however, who would lend themselves to such a study. These are patients who have bilateral infarction in the territory supplied by the anterior cerebral artery (ACA). However, such patients are extremely rare. Recent estimates suggest that, while unilateral ACA infarction is unusual, representing only 0.6–3.0% of all strokes (Bogousslavsky and Regli, 1990; Kumral *et al.*, 2002), bilateral infarction in this territory is very rare, affecting only 4% of all ACA infarcts in one recent series (Kumral *et al.*, 2002), with only 13 cases previously reported in the literature (for brief reviews see Minagar and David, 1999; Kumral *et al.*, 2002). Although, the description of neurological signs in these patients is well documented, neuropsychological evaluation has not been so extensive. To the best of our knowledge, the case we present here is unique with respect to the detailed assessment of executive, memory and intellectual functions following bilateral ACA infarction and presents a rare opportunity to investigate whether the medial frontal cortex really is necessary for ToM.

Methods

Case report

G.T. is a 62-year-old retired teacher who presented to hospital following a sudden collapse at home. On admission, she was considered to be confused. She had a mild left facial weakness and dysarthria. Although power appeared full in the left arm, the admitting physician noted she had some difficulty co-ordinating it. There was a mild [Medical Research Council (MRC) grade 4] weakness of the left leg. By the next day, there was no obvious weakness and she was mobilizing with supervision and able to follow simple

commands. Over the next week, she was observed occasionally to be drowsy; at other times, she was alert but thought to have difficulty remembering recent material and was noted to be confabulating.

She was first examined by one of the authors (O.M.) a week after admission. By that stage, there was only a mild left pyramidal drift, sustained clonus at the left knee and ankle with bilaterally brisk deep tendon reflexes. She was also noted to have positive primitive reflexes (pout and grasp) bilaterally. Over the next 3 weeks, she repeatedly absconded from the ward, saying she was bored. Seven weeks after admission, she was assessed by a second neurologist (M.H.), who found that she had a positive grasp reflex in the left hand, but no limb weakness, gait apraxia or ideomotor apraxia. She was able to perform in-phase alternating hand movements well, but had moderate difficulties performing out-of-phase alternating hand movements, particularly if vision of the hands was occluded. She did not demonstrate any evidence of constructional impairment on copying tasks nor was there any evidence of visual neglect. It was noted that she had a low spontaneous speech output.

Assessments by occupational therapists concluded that she had difficulties with memory, planning and initiating actions. She appeared to have poor insight into her problems and did not seem to adopt systematic strategies when attempting to solve problems. She had difficulties remembering events following her admission, but seemed to recollect well events prior to that time. She required urinary catheterization because of persistent problems with incontinence. G.T.'s agitation at being in hospital improved considerably following discharge. The only persistent problems noted by her husband were in her memory and planning. For example, she would occasionally prepare a meal for her husband and their children despite the fact that the children had all left home.

Clinical CT imaging on admission demonstrated bilateral medial frontal low attenuation regions. A subsequent MRI scan demonstrated confluent areas of signal change affecting both medial and inferior frontal lobes and the right caudate nucleus. MRI angiography reported an absent A1 segment of the left anterior cerebral artery with a relatively small A1 segment on right, and the left A2 filling via the anterior communicating artery. Thus, she had a vascular variation with a single A1 segment (on the right). A clinical diagnosis of bilateral infarction in the territory of the anterior cerebral artery was made.

High resolution MRI

Six months after her stroke, we performed a high-resolution structural MRI scan which comprised one 256-slice T1-weighted acquisition [MPRAGE: TR (repetition time) = 9.7 ms; TE (echo time) = 4 ms; flip angle = 12°; TA (acquisition time) = 12 min] performed in the coronal plane, on a 1.5 T MRI scanner (Siemens Vision, Munich, Germany). Within- and between-slice resolution was 1 mm, giving an isotropic voxel dimension of 1 mm³. Twenty-five sagittal

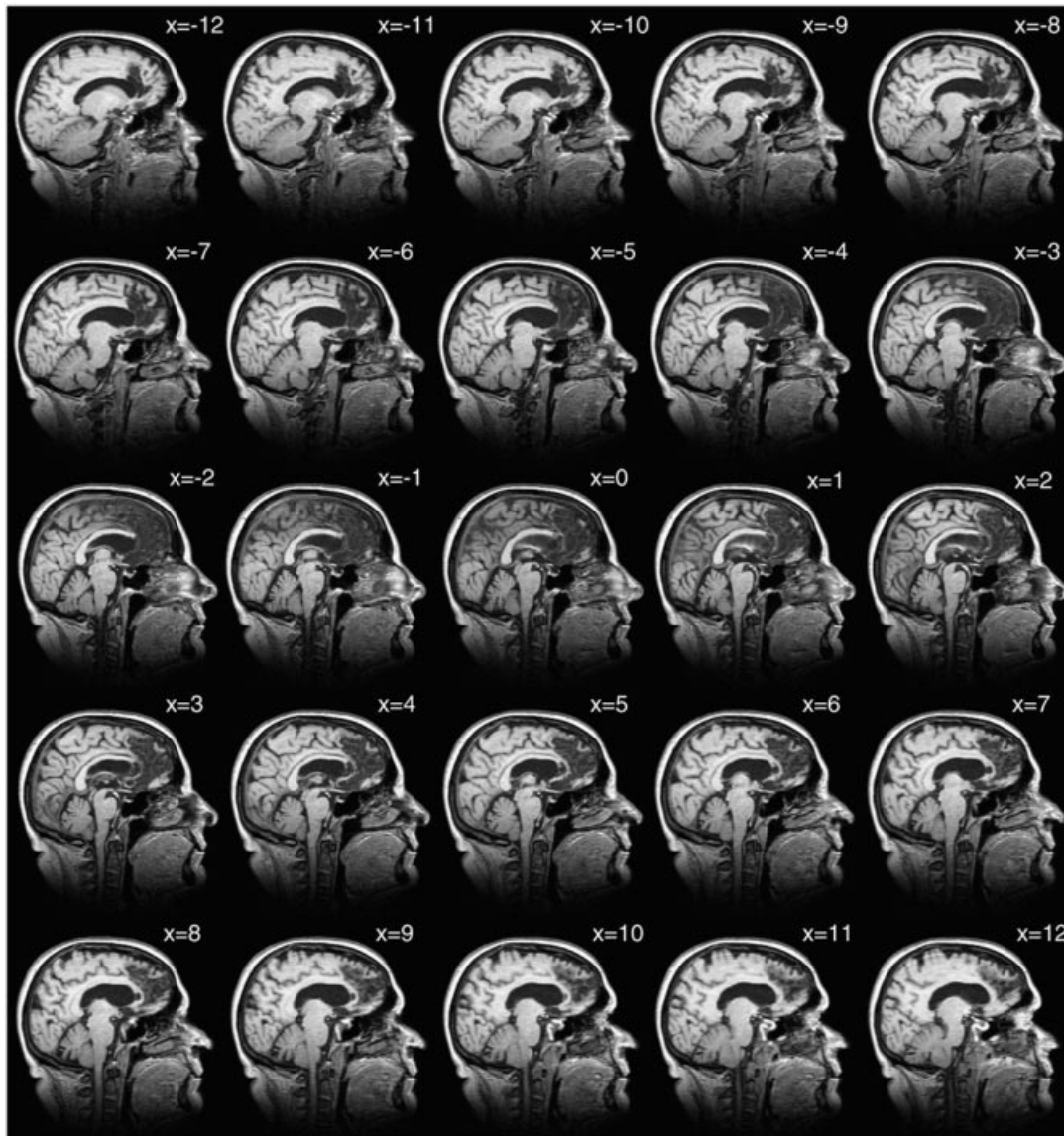

Fig. 1 1 mm Sagittal sections through GT's brain, extending 12 mm left (x values are negative) to 12 mm right (x values positive) of the midline, demonstrating extensive cortical damage in both hemispheres and, generally, greater sub-cortical involvement in the right hemisphere.

sections extending from 12 mm left of the midline to 12 mm right of the midline are shown in Fig. 1.

The scans demonstrate extensive bilateral medial frontal infarction extending from the orbitofrontal region caudally to the genu of the corpus callosum, involving the anterior cingulate gyrus, cingulate and medial superior frontal sulcus (all within the territory of the anterior cerebral artery). In addition, there was involvement of fornix and basal forebrain, and in the right hemisphere (but not in the left) of the caudate nucleus, anterior limb of the internal capsule and putamen (consistent with involvement of perforating artery branches from the right A1 segment of the anterior cerebral artery). There are also some differences in the symmetry of the lesion involving cortex in left and right medial frontal lobes. Their extent is clearly seen in Fig. 1.

The cortical damage extends over a large part of the medial frontal cortex, including many of the cortical regions implicated by functional imaging in ToM (for meta-analyses see Shallice, 2001; Gallagher and Frith, 2003; Frith and Frith, 2003). Some functional imaging studies, however, have reported activation peaks that are 12 mm lateral to the midline (e.g. Fletcher *et al.*, 1995; Goel *et al.*, 1995) and, as can be seen in Fig. 1, the depth of the lesion does not extend fully to include all sub-cortical structures at 12 mm depth. But at this distance from the midline, most of the brain substance consists of white matter rather than cortex, and some authors explicitly consider ToM to be subserved by medial frontal cortex (Gallagher and Frith, 2003). Moreover, the resolution of PET studies is relatively poor and even fMRI has a spatial precision of, at best, ~5 mm (Ugurbil *et al.*, 2003). Secondly,

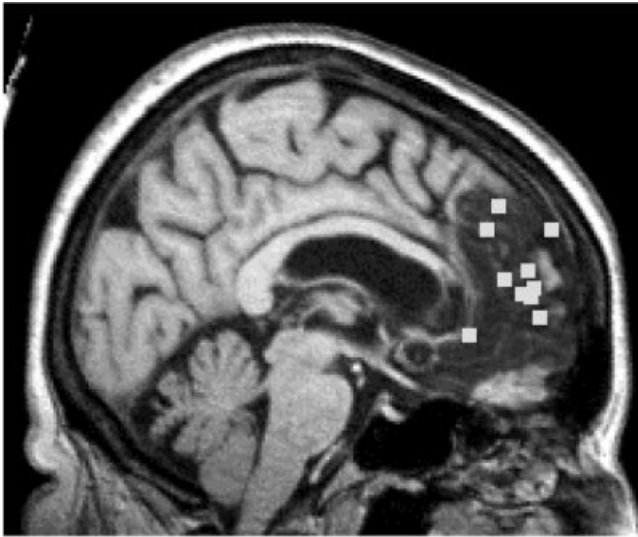


Fig. 2 Foci of ToM activations from ten different neuroimaging studies rendered onto a normalised version of G.T.'s lesion. Note all foci are projected onto the medial surface, regardless of lateralisation to left or right hemisphere. The plotted co-ordinates are 8, 54, 12 (Gallagher *et al.*, 2002), 8, 53, 9 (McCabe *et al.*, 2001), -12, 42, 40 (Fletcher *et al.*, 1995), -12, 38, 32 (Goel *et al.*, 1995), 0, 44, 15 (Baron-Cohen, *et al.*, 1999b), -8, 50, 10 (Gallagher *et al.*, 2000), 8, 32, -4 (Brunet *et al.*, 2000), -4, 60, 32 (Castelli *et al.*, 2000), 6, 56, 2 (Vogelely *et al.*, 2001) and -8, 52, 18 (Berthoz *et al.*, 2002).

although the peaks of some imaging studies are lateralized, the laterality is not consistent, with some reports demonstrating activation peaks in the left hemisphere (e.g. Fletcher *et al.*, 1995; Goel *et al.*, 1995) and others in the right (e.g. Gallagher *et al.*, 2002). Still other studies show peaks on or just beside the midline (e.g. Baron-Cohen *et al.*, 1999b). The most parsimonious explanation for this body of data is that the activations may in fact represent bilateral foci close to the midline (C. Frith, personal communication). The case described here presents an important opportunity to determine whether Theory of Mind is impaired by loss of the extensive bilateral areas of medial frontal cortex demarcated in Fig. 1.

For purposes of illustration, we also show some of the foci of activation reported in functional imaging studies of ToM projected onto the medial surface of G.T.'s normalized brain (Fig. 2).

Neuropsychological assessment

An initial neuropsychological assessment of G.T. was carried out by one of the authors (C.B.), 87 days after her stroke followed by a second, 14 days later. The findings concerning G.T.'s intellectual, language, memory, nominal perceptual and attentive functioning are shown in Table 1.

G.T. was assessed on a seven-subtest short form of the Wechsler Adult Intelligence Scale—Revised (WAIS-R) (Wechsler, 1981) and obtained a full-scale intelligence

Table 1 Neuropsychological assessment of G.T.

Test	Score, percentile
WAIS-R Full Scale IQ ^A : age-related subtest scaled scores (mean = 10)	102
Digit span	9
Vocabulary	10
Arithmetic	13
Similarities	10
Picture completion	11
Picture arrangement	12
Block design	10
NART-R ^A	121
Graded Naming Test ^A	27/30, >75th percentile
Wechsler Memory Scale-III ^A : age-related subtest scaled scores (mean = 10)	
Prose recall: immediate	5, <5th percentile
Prose recall: delayed	3, <1st percentile
Faces recognition: immediate	6, ~10th percentile
Recognition Memory Test ^A	
Words	39/50, 10th–25th percentile
Famous Faces Test ^B	
Named	7/12
Recognized	10/12
Autobiographical Memory Interview ^B : personal semantic	
Childhood	21/21
Early adult life	21/21
Recent life	12/21
Autobiographical Memory Interview ^B : autobiographical incidents	
Childhood	5/12
Early adult life	4/12
Recent life	3/12
Silhouettes Test ^A	26/30, >75th percentile
Test of Everyday Attention ^B	
Elevator counting	7/7
Elevator counting with distraction	4/10, 5th–10th percentile

^AFirst assessment (87 days post stroke); ^BSecond assessment (101 days post stroke).

quotient (IQ) in the average range. Performance on all subtests was in the average range except for arithmetic and picture arrangement, which were both in the high average range. Her premorbid IQ, based on the National Adult Reading Test—Revised (NART-R) (Nelson and Willison, 1991), was at the lower end of the superior range. Therefore, these scores represent a modest degree of intellectual underfunctioning.

G.T.'s language skills were largely intact. She performed adequately on all verbal subtests of the WAIS-R including the Similarities subtest, which requires relatively complex verbal reasoning. However, it was noted that on some subtests, particularly Vocabulary, G.T. would tend to give rather short responses and give up easily if she was not sure of the answer. Her reading ability on the NART was good and her nominal skills as assessed by the Graded Naming Test (McKenna and

Warrington, 1983) were excellent. Qualitatively, however, G.T.'s spontaneous speech during conversation was rather sparse. See also below for further discussion of her verbal generation.

At the first and subsequent testing sessions, G.T.'s anterograde and retrograde memory skills were severely compromised. Verbal recall memory was particularly impaired at both immediate and delayed recall. In addition, verbal and visual recognition memory appeared to be somewhat weak, although less so than recall. Retrograde memory, as assessed by the Autobiographical Memory Interview (Kopelman *et al.*, 1990), tended to show a temporally graded retrograde amnesia with memory for autobiographical incidents being more affected than personal semantic memories. However, G.T. was able to recognize 10 out of 12 faces of currently famous people. G.T. was noted to confabulate during her time in hospital before discharge (where she often said that she thought she was in a school) and to a lesser extent after discharge. She confabulated for ~9 months after the stroke.

G.T.'s perceptual functions were intact. Conversely, her auditory verbal working memory was poor, as tested by the Elevator Counting with Reversal Task [from the Test of Everyday Attention (Robertson *et al.*, 1994)]. This may reflect a deficit in auditory selective attention.

Given the known location of G.T.'s lesion, and the proposal that ToM and executive functioning are independent (e.g. Fine *et al.*, 2001; Rowe *et al.*, 2001), particular attention was paid to her executive skills. G.T. shows an interesting pattern of intact performance on some tasks and impairment on others (see Table 2).

She performed rather well on some 'classic' tests of executive function. Thus, her performance on the Modified Card Sorting Test (Nelson, 1976), Stroop Test (Trenerry *et al.*, 1989), Trail Making Test (Army Individual Test Battery, 1944) and Verbal Fluency Test (letters F, A and S) were all within the normal range. Nevertheless, G.T.'s verbal fluency score of 27 words was substantially below that predicted by her performance on the NART (51 words; Crawford *et al.*, 1992) and is consistent with the clinical impression that she initiated little spontaneous speech. This may reflect a mild dynamic aphasia (Costello and Warrington, 1989). Performance on more unstructured tests of planning and prospective memory revealed profound impairments. Most noteworthy was her performance on the six-element subtest of the Behavioural Test of the Dysexecutive Syndrome (BADS) (Wilson *et al.*, 1996). G.T. only attempted two out of six tasks, since she got 'stuck in set' on a picture naming task and spent >8 min performing this task until the test was finished. Outside of the testing environment, a similar failure to switch tasks had been noted by her occupational therapist. G.T. obtained a moderate average score on part 1 of the Hayling Test (Burgess and Shallice, 1997), which measures how fast one can initiate a cued verbal response. She was unable to complete the second part of the Hayling Test, having great difficulty in producing an appropriate word. This test requires making a response that

Table 2 G.T.'s performance on tests of 'executive' function

Test	Score, percentile
Modified Card Sorting Test ^B	
Categories	6, >40th percentile
Percentage perseverative errors	15%, 45th–50th percentile
Verbal fluency (F, A, S) ^A	27, 20th–30th percentile
Stroop Test ^A	101, 50th–60th percentile
Trail Making Test ^B	
Part A	68 s, 10th–25th percentile
Part B	83 s, 75th percentile
BADS (profile score)	
Rule shift ^B	4/4
Six-element ^B	1/4
Zoo map ^A	1/4
DEX questionnaire ^B	
Self rating	29/80
Other rating	38/80
Hayling Test (scaled score) ^B	
Part 1	5/7
Part 2	Abandoned (1/8 on section B after 4 items)

^AFirst assessment (87 days post stroke); ^BSecond assessment (101 days post stroke).

is unrelated to the cueing sentence. Thus, G.T. failed to inhibit a cued verbal response and generate an uncued verbal response, which contrasts with her rather good performance on the Stroop Test, where the non-dominant verbal response is nevertheless provided on the stimulus sheet (i.e. naming the colour of the ink). G.T.'s gross failure on the second part of this test is probably due to an inability to generate an appropriate strategy, but could also reflect a mild dynamic aphasia (see Burgess and Shallice, 1996).

On the DEX questionnaire (from the BADS; Wilson *et al.*, 1996), G.T.'s husband rated deficits in impulsivity (questions 4, 7, 18 and 19), executive memory (questions 3 and 6) and changes in negative affect (questions 8 and 11) and variable motivation (question 10) as being the most marked effects of the stroke [see Burgess *et al.*, (2000) for a discussion of the factorial structure of the DEX].

Experimental investigation

At the same time as G.T.'s first two neuropsychological assessments, and 84 days after her second neuropsychological assessment, a battery of tests of ToM and social cognition were administered by one of the authors (C.B.). We aimed to investigate the null hypothesis that G.T.'s stroke would not affect her ToM ability. On the tasks where G.T. made errors, comparisons of G.T.'s scores with controls were made using the procedure of Crawford and Garthwaite (2002) for comparing a single case with a control population. Whilst some may consider this a rather conservative criterion (perhaps biasing towards a null result), we felt that it was appropriate to use the standard 5% cut-off for impairment. Thus, all comparisons were made using a 1-tailed level of significance.

Task 1: Picture sequences (Baron-Cohen et al., 1986)

G.T. was assessed on her ability to arrange pictures into a predetermined sequence, thereby showing her understanding of the 'story' depicted in the pictures, a test failed by autistic children (Baron-Cohen *et al.*, 1986). Baron-Cohen *et al.* (1986) argued that good performance on this test requires understanding of the characters' mental states. An fMRI study using similar materials activated the medial frontal lobes when the tasks involved the attributions of intentions (Brunet *et al.*, 2000).

G.T. was tested on two types of stories. The first involved two characters engaged in some form of behaviour, but did not require the appreciation of their mental states (e.g. a girl taking an ice cream away from a boy). The second also involved two characters interacting but, in addition, required the comprehension of their mental states. Each story comprised four single events (pictures). There were three different stories for each condition. G.T. performed at ceiling on this task, correctly ordering the pictures in all stories in all conditions. Thus, she achieved 3 out of 3 correct on the ToM stories and 3 out of 3 correct on the Behavioural stories.

Task 2: Advanced ToM test (Happe, 1995)

G.T.'s ability to use mental state understanding to make sense of non-literal utterances was tested using 16 short passages involving the comprehension of either a mental state (ToM condition) or a physical state. The ToM passages involved a double bluff, mistake, persuasion or white lies. These passages were followed by questions requiring an inference about the characters' thoughts, feelings and/or intentions. The physical state stories required inferences to be made, but in these cases the protagonists' mental states were not relevant. This test has been shown to be sensitive to the effects of brain damage in patients with right hemisphere stroke (Happe *et al.*, 1999); children and adults with Asperger's syndrome perform poorly on this test (Happe, 1995; Baron-Cohen *et al.*, 1997; Jolliffe and Baron-Cohen, 1999), which has activated the medial frontal cortex in imaging experiments conducted on healthy individuals (e.g. Fletcher *et al.*, 1995; Gallagher *et al.*, 2000).

Each passage was read aloud to G.T. and a written copy was placed in front of her. The passage was read aloud again if G.T. felt that she could not remember all the details. After this, G.T.'s copy of the passage was turned over to reveal a question (see Appendix for an example of a story). G.T.'s responses were recorded and later transcribed and scored by two independent raters, who were blind to all aspects of the investigation.

Answers to the questions were scored as 0 for incorrect, 1 for implicitly or partially correct, and 2 for elaborate and explicitly correct as in previous studies (e.g. Fletcher *et al.*, 1995). A detailed scoring sheet was given to the two raters. Both independent raters scored G.T.'s responses identically.

G.T. performed at ceiling on this test, scoring 16 out of 16 on the ToM passages and 16 out of 16 on the physical state passages. Her responses to the ToM stories implied a full appreciation of the mental states of the protagonists (see Appendix).

Therefore, G.T.'s performance on this task suggests that she has no difficulty in understanding complex social interactions requiring the representation of mental states.

Task 3: Violation of social norms (Berthoz et al., 2002)

The previous two tasks indicate that G.T. has little difficulty in representing the mental states of others in order to understand social interactions. However, it may be possible that whilst her mentalizing ability is sufficient to carry out these tests, she still has little appreciation of what the protagonists in the stories are actually 'feeling'. Therefore, we tested her ability to understand both intentional and unintentional violations of social norms, using a shorter variant of a paradigm that has recently been used in a neuroimaging study that activated the medial frontal lobes in healthy individuals (Berthoz *et al.*, 2002).

Our test comprised 14 short passages describing a social situation. Each of the 14 passages has three different endings, resulting in 42 passages altogether. The endings were either: (i) a description of a situation where a protagonist unintentionally violates a social norm (embarrassing); (ii) a description where a protagonist intentionally violates a social norm (inappropriate); or (iii) a description of a normal situation. An example of a sentence with the three endings is reproduced in the Appendix.

The 42 passages were randomized. After reading each passage, participants had to decide: (i) whether the protagonist would be embarrassed (yes or no); and (ii) whether the protagonist's behaviour was appropriate (yes or no). The text remained in front of the participant while they decided about their responses. The rationale behind the designation of correct responses is shown in the appendix.

The results of G.T. and 12 age- and NART IQ-matched controls (age = 64.1, SD = 5.4; NART IQ = 118.8, SD = 4.9) are shown in Table 3.

All conditions

The first analyses, comparing G.T.'s responses with those of the controls on all conditions, revealed no significant differences, either in judgements of embarrassment or appropriateness of behaviours [embarrassment judgements: $t(11) = -0.28$, $P = 0.39$; appropriateness judgements: $t(11) = 1.12$, $P = 0.14$]. Since the ability to make these kinds of judgements would be expected to require the attribution of mental states to the characters, the results of this test further support the previous findings that G.T. has unimpaired ToM ability.

Table 3 G.T.'s performance on the test of violation of social norms

Condition	Rating	G.T.	Controls [mean (SD)]
All	Embarrassment judgement (total = 42)	38 (n.s.)	39.8 (2.2)
	Behaviour judgement (total = 42)	39 (n.s.)	33.8 (4.4)
Specific conditions			
Unintentional violation (embarrassing)	Embarrassment judgement (total = 14)	10*	13.3 (1.1)
	Behaviour judgement (total = 14)	12 (n.s.)	6.7 (4.1)
Intentional violation (inappropriate)	Embarrassment judgement (total = 14)	14 (n.s.)	12.8 (1.1)
	Behaviour judgement	14 (n.s.)	13.6 (0.7)
Control condition	Embarrassment judgement (total = 14)	14 (n.s.)	13.7 (0.6)
	Behaviour judgement (total = 14)	13 (n.s.)	13.6 (1.2)

*Significantly less than controls ($P < 0.01$); n.s. = no significant difference (all $P > 0.2$).

Unintentional violations

G.T. was slightly less likely than controls to judge an unintentional violation of a social norm as embarrassing (Table 3). G.T. rated 10 out of 14 of these situations as 'embarrassing'. This was significantly fewer than controls [mean for control group = 13.3, SD = 1.1; $t(11) = -2.98$, $P < 0.01$]. G.T. reasoned (on four out of 14 occasions) that since the incidents had not been caused deliberately, the protagonist should not feel embarrassed by them. For example, in one situation the protagonist (Sandra) is in a rush when she goes to the supermarket. She does not notice that she is in a quick-checkout lane and wheels in her full trolley, but the cashier points to a sign saying 'for ten or fewer items'. G.T. argued that Sandra simply made an honest mistake and therefore would not have been embarrassed. Eight out of 12 controls rated all 14 situations as embarrassing for the protagonist.

Turning to the behavioural judgements in this condition, G.T. rated more behaviours as appropriate than all but one of the controls. However, this difference was not significant and there were considerable individual differences in the responses of the control group [$t(11) = 1.24$, $P = 0.12$]. Some control subjects appeared to not take into account the specific situation when judging the appropriateness of behaviours. For example, in the passage given in the methods section, two out of 12 controls judged the behaviour of sneezing over the neighbour's table to be inappropriate despite the fact that Simon was allergic to dogs. Thus, in these situations involving unintentional violations of social norms, there was a hint that G.T. was less sensitive to embarrassment than matched controls. However, when considering the judgements of appropriateness, if anything G.T. appeared more sensitive to the situations described than many of the controls.

Intentional violations and control conditions

G.T.'s responses did not differ significantly from those of the controls in the intentional violations condition or the control condition [see Table 3: Unintentional violations, embarrassment judgements: $t(11) = 1.24$, $P = 0.12$, appropriateness

judgements: $t(11) = 0.60$, $P = 0.28$; Control condition, embarrassment judgements: $t(11) = 0.39$, $P = 0.35$, appropriateness judgements: $t(11) = -0.48$, $P = 0.32$].

Therefore, the results of this test indicate that G.T. is generally unimpaired at making judgements of either embarrassment or appropriateness in a wide variety of social situations. However, it is possible that G.T. is slightly insensitive in her appreciation of the embarrassment another person would feel after unintentionally violating a social norm.

Task 4: Faux Pas Test (Baron-Cohen et al., 1999a)

We further investigated G.T.'s ability to understand situations where an unintentional social transgression had been made by administering the Faux Pas Test, which shares obvious similarities with the previous test (Adolphs, 2003). This has been shown to be sensitive to subtle ToM deficits in a population with Asperger's syndrome (Baron-Cohen *et al.*, 1999a) and in patients with acquired brain lesions in the frontal lobes, two patients with bilateral amygdala lesions and in a group of patients with frontal variant frontotemporal dementia (Stone *et al.*, 1998, 2003; Gregory *et al.*, 2002).

We used the procedure and materials described by Gregory and colleagues (Gregory *et al.*, 2002), consisting of 20 short passages each involving a social situation. In 10 of the passages, one of the characters says something inappropriate to the situation (a faux pas). Participants must indicate whether somebody said something that they should not have said. If a faux pas is detected, then comprehension of the situation is assessed by asking three further clarifying questions about the faux pas. The first of these clarifying questions concerns who made the faux pas. The second concerns why the protagonist should not have said what s/he said and the third concerns why s/he did say it. Thus, the clarifying questions test whether a subject has appreciated why the utterance was a faux pas and, also, that the character in the story was ignorant of this fact. There are also one or two control questions concerning other aspects of the story.

Table 4 G.T.'s performance on the Faux Pas Test

Condition	G.T.	Controls [mean (SD)]
Identification of a faux pas	8/10	9.5 (1)
Correct rejections of non faux pas	10/10	9.9 (1)
Control questions	0.88	0.99 (0.1)
Composite score	0.84	0.94 (0.1)

Each passage was read aloud while G.T. was able to follow the test on her own copy. G.T. was able to refer to her copy while answering the questions. An example of a passage with the associated questions and G.T.'s responses are given in the Appendix.

Quantitative analysis

G.T.'s responses were recorded, transcribed and then scored by the same blind raters who scored task 2. The raters were asked to allocate one point to every correctly answered question. Following Stone *et al.* (2003), "only answers that clearly missed the point were scored as incorrect". The raters agreed on the allocation of point in all but three of the 75 questions (96%). In the three instances where there was a disagreement, a third rater made the decision about whether to allocate the point or not. G.T.'s scores were compared with the healthy controls tested by Gregory *et al.* (2002), who were well matched in terms of age and NART IQ (age = 57.1, SD = 5.1; NART IQ = 116.5, SD = 8.9; $n = 16$).

The results of G.T. and the controls are shown in Table 4. G.T. correctly identified eight out of 10 of the faux pas. This is towards the lower end of performance of the controls [$t(15) = -1.46, P = 0.08$]. In addition, she correctly rejected 10 out of 10 of the situations not involving a faux pas. G.T. answered all but three of the control questions correctly, which places her performance in the normal range [$t(15) = -1.07, P = 0.15$]. Following Gregory *et al.* (2002), we calculated a composite score to measure G.T.'s sensitivity to the faux pas that included performance on the clarifying questions after a faux pas was detected (number of faux pas detected plus the number of correctly answered clarifying questions plus the number of correct rejections all divided by 50). G.T. achieved a composite score of 0.84, which was well within the range of normal performance [$t(15) = -0.97, P = 0.17$]. To check this result, G.T.'s performance was also compared with the performance of 34 age-matched controls from a more recent study (Stone *et al.*, 2003). In this study, the total score was based on the sum of all faux pas related questions (four for each story, giving a maximum of 40). G.T. scored 32 out of 40, while the control mean was 35.5 (SD = 3.0), which again places G.T.'s score within the normal range [$t(33) = -1.15, P = 0.13$].

The results of these analyses place G.T.'s performance on the Faux Pas Test at the lower end of normal range, hinting

that G.T. may have some difficulty appraising awkward or embarrassing social situations. However, given that her performance on control questions was also rather poor, this may reflect a generalized difficulty on the task, perhaps due to her weak verbal memory. For these reasons, we examined G.T.'s responses in greater detail.

Qualitative analysis

When G.T. correctly recognized the faux pas, her answers indicated that she had a full understanding of the mental states of all the characters in the passages. In particular, there was little evidence that G.T. failed to recognize that the listener's feelings might have been hurt and that responses were based on a more general rule having been violated. This latter strategy has been documented in two patients with Asperger's syndrome (Shamay-Tsoory *et al.*, 2002). Similarly to the Violation of Social Norms Test, G.T.'s reasoning on the Faux Pas Test was rather more concrete than that of most of the controls. For example, she often denied that somebody had said "something they shouldn't have", since the protagonist was not aware of the whole situation. However, she readily admitted that somebody had said something "rather tactless" or "hurtful". In similar vein, on one of the items where G.T. failed to recognize the faux pas, she justified her answer by saying that "everybody is entitled to their own opinion". This response tacitly suggests that G.T. has recognized that a faux pas had been committed, indicating an adequate understanding of the situation. However, it reveals a possible insensitivity to the feelings on the listener and/or the subsequent embarrassment of the speaker.

Thus, G.T.'s performance on an advanced ToM test was in the normal range of matched control subjects. Her ability to correctly reject stories that did not contain a faux pas was flawless. Careful analysis of G.T.'s responses revealed no problems in understanding the mental states of the characters in the stories. As with the previous test, on a minority of occasions there was a hint that G.T. was rather insensitive to the embarrassment a protagonist might feel in a situation.

Task 5: Animations test (Abell et al., 2000; Castelli et al., 2000, 2002)

G.T. performed adequately on all the ToM tests detailed above. However, performance on these tests may be facilitated by the highly familiar nature of the stimuli. For this reason we administered to G.T. a new test of the ability to attribute mental states to moving objects 'online'. These tests have activated, among other areas, the medial frontal lobes in neuroimaging studies and are sensitive to mentalizing deficits in children and adults with autism or Asperger's syndrome (Abell *et al.*, 2000; Castelli *et al.*, 2002).

For a detailed description of the stimuli see Castelli *et al.* (2000). Briefly, eight animations were used for the test, and

an additional two were shown for practice. Four of the test animations and one of the practice animations involved a ToM interaction. The other animations involved goal-directed movements. All the animations featured two characters, a big red triangle and a small blue triangle, moving about on a framed white background. Each sequence lasted between 34 and 45 s. The 'scripts' for the ToM sequences involved the two triangles persuading, bluffing, mocking and surprising one another. The goal-directed 'scripts' involved the two triangles dancing together, one chasing, one imitating and one leading the other.

Since G.T.'s spontaneous speech output was reduced, comprehension of the animations was tested using a forced-choice procedure rather than having participants generate verbal descriptions as has been used previously. An appropriate description for the movements and three alternatives were devised for every animation (see Appendix). The ToM and the physical descriptions were balanced with respect for the number of ToM, physical and random movement descriptions that were provided. The order of the targets and the lures were randomized. Eight control subjects, matched for age and NART estimated IQ (age = 63.0, SD = 1.9; NART IQ = 122.9, SD = 3.9), also participated.

There were no differences between G.T.'s responses to either the ToM animations or the physical animations. G.T. made two out of four correct responses on the ToM animations, whereas controls made a mean of 3.0 correct responses (SD = 0.82, range = 2–4; two out of eight controls made the same number of errors as G.T.). This difference was not significant [$t(7) = -1.15$, $P = 0.14$]. G.T.'s errors and those made by all the controls involved choosing the appropriate physical descriptions. This is consistent with our findings from pilot studies that older adults tend to use physical descriptions for the ToM animations more than younger participants (unpublished data). G.T. made three out of four correct responses on the physical animations whereas controls made a mean of 3.57 correct responses [SD = 0.53, range = 3–4; $t(7) = -1.00$, $P = 0.18$]. G.T.'s error and that made by three of the eight controls was to choose a ToM description.

Thus, G.T.'s performance was within the normal range of performance for her age and IQ group. It should be noted, however, that the use of a multiple choice procedure means that the statistical power for detecting a subtle deficit on this task is rather weak.

Summary of tasks 1–5

To illustrate G.T.'s overall performance on all the experimental tasks, her t -scores are plotted in Fig. 3.

It is clear that her performance was well within the normal range of healthy subjects for all tasks apart from Task 3, where she judged slightly fewer of the 'embarrassing' situations as being embarrassing for the character in the story.

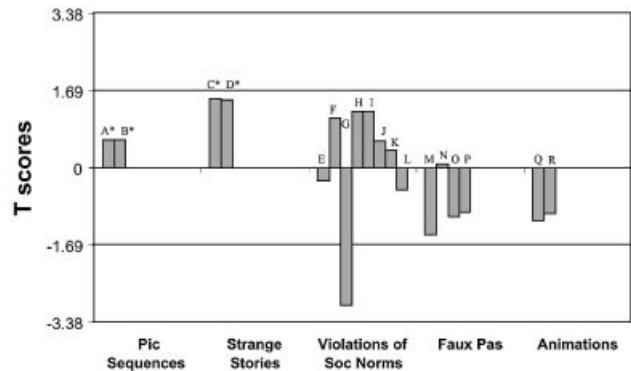


Fig. 3 Task 1: picture sequences. A = ToM stories; B = behavioural stories; * = performance at ceiling (t -scores calculated from control data from Baron-Cohen *et al.*, 1986). Task 2: strange stories. C = ToM stories; D = physical state stories; * = performance at ceiling (t -scores calculated from control data from Fletcher *et al.*, 1995). Task 3: violations of social norms. E = all conditions, embarrassment judgements; F = all conditions, appropriateness judgements; G = 'embarrassing' conditions, embarrassment judgements; H = 'embarrassing' conditions, appropriateness judgements; I = 'inappropriate' conditions, embarrassment judgements; J = 'inappropriate' conditions, appropriateness judgements; K = control conditions, embarrassment judgements; L = control conditions, appropriateness judgements; details of controls in text. Task 4: faux pas. M = hits; N = correct rejections; O = control questions; P = composite score (control data from Gregory *et al.*, 2000). Task 5: animations. Q = ToM interactions; R = physical interaction (details of control in text). For impairment, T must be < -1.69 in all cases.

Discussion

The medial frontal cortex has been hypothesized to play a critical role in a dedicated 'mentalizing' brain network that underpins ToM ability (Frith and Frith, 1999, 2003; Gallagher and Frith, 2003). G.T., the patient reported here, presented us with a rare opportunity to test whether the medial frontal cortex is really necessary for ToM. She suffered bilateral infarction in the territory supplied by the anterior cerebral artery, resulting in damage to most of the left and right anterior portions of her medial frontal lobes. For the first time in such a patient, we carried out detailed neuropsychological investigations, as well as an extensive experimental investigation of ToM ability, administering several tasks that have been used previously in the developmental, neuropsychological and neuroimaging ToM literature.

G.T. performed within the normal range on these tasks, indicative of an accurate ability to represent and understand mental states of others, although she exhibited a mild insensitivity to embarrassing situations and a slight blunting of empathy for other people. These findings suggest that the regions of the medial frontal lobes damaged in G.T. are not necessary for at least the cognitive aspects of ToM. This has important implications for the further development of theories concerning the cognitive anatomy of the ToM network.

There have been several studies investigating the effects of frontal lobe lesions (dorsolateral and ventromedial/orbital) on performance on ToM tasks (Stone *et al.*, 1998; Channon and Crawford, 2000; Happe *et al.*, 2001; Rowe *et al.*, 2001; Stuss *et al.*, 2001; Gregory *et al.*, 2002; Shamay-Tsoory *et al.*, 2003). However, the bulk of these studies have shed no light on the precise neuroanatomical underpinnings of ToM ability. It has been suggested that differences between the tests used in these studies may be a reason for differing lesion effects such as, for example, laterality, on task performance (Shallice, 2001). Furthermore, no previous study has explicitly set out to test the predictions of neuroimaging investigations, perhaps due to the scarcity of patients suitable for such an investigation. The studies that have included patients with bilateral frontal lobe damage are limited by a lack of detailed anatomical specification of lesion location (Stone *et al.*, 1998; Stuss *et al.*, 2001; Gregory *et al.*, 2002; Shamay-Tsoory *et al.*, 2003). Moreover, the vast majority of patients with bilateral lesions that have been assessed on ToM tasks have suffered head trauma—an aetiology associated with rather diffuse brain damage that is particularly likely to impinge on orbitofrontal brain areas, which lie outside the critical regions commonly activated during neuroimaging tasks. Thus, the present study represents the only direct test of the hypothesis that the medial frontal cortex is a critical component of the ToM network (Gallagher and Frith, 2003).

Comparison of G.T.'s performance with previous neuroimaging studies of ToM

G.T. performed flawlessly when asked to arrange picture cards into sequences to make stories, half of which involved representing the mental states of the protagonists, indicating that she has no difficulty representing the mental states of the characters in the stories. By contrast, an fMRI study recruiting healthy adults (Brunet *et al.*, 2000) used similar stimuli and found robust medial frontal activations. G.T. also performed our second experimental task—an advanced ToM test developed by Happe (1995)—without making any errors. Three neuroimaging studies have implicated medial frontal regions when healthy adults performed this task (Fletcher *et al.*, 1995; Happe *et al.*, 1996; Gallagher *et al.*, 2000). Gallagher *et al.* (2000) also reported that the same medial frontal area was also activated during the ToM condition of a cartoon task. It should be noted that, while G.T. was not formally assessed on her ability to comprehend cartoons with a ToM component, she was shown two of the cartoons used by Gallagher *et al.* (2000) at the first neuropsychological assessment and had no difficulty explaining the situations depicted. Thus, despite considerable evidence that the medial frontal regions are engaged in these tasks in healthy subjects, our data reveal that the areas damaged in G.T. (see Fig. 1) are not crucial for intact performance on a number of ToM tests.

Our third experimental task used the same stimuli that have recently been used in a neuroimaging study of transgressions

of social norms (Berthoz *et al.*, 2002), which identified several medial frontal areas associated with both intentional and unintentional violations of social norms. Similarly to the other ToM tests, G.T. performed within the normal range on every condition apart from her ratings of embarrassment in the 'embarrassing' conditions. Rather similar results were obtained from the fourth experimental task—the Faux Pas Test (Stone *et al.*, 1998; Baron-Cohen *et al.*, 1999a). G.T.'s performance fell within the normal range of age-matched control subjects and her answers revealed no difficulties in understanding and representing the mental states of the protagonists. However, qualitative analysis of her responses suggested that G.T.'s reasoning was somewhat concrete, which may have been due to a slight blunting of empathy for the characters in the stories. Interestingly, a recent patient study has identified a distinct ventral medial region in this process (Shamay-Tsoory *et al.*, 2003). This area is also damaged in G.T., as is the anterior 'affective' region of the anterior cingulate, which has been hypothesized to play a role in assessing the salience of emotional information and the regulation of appropriate responses (Bush *et al.*, 2000). While G.T.'s performance on these latter two tasks could be taken to indicate a specific (albeit minor) impairment in the appreciation of embarrassment and in empathy, it cannot be ruled out that her lesion resulted in an overall blunting of affect—a commonly reported consequence of anterior cingulate and ventromedial frontal damage (e.g. Cohen *et al.*, 1999a, b; Hornak *et al.*, 2003). This view is supported by her husband's comments about her behaviour following the stroke and his answers to the DEX questionnaire.

Our fifth task investigated G.T.'s ability to infer mental states from animations depicting the movement of abstract shapes. We believed that this task was more sensitive than the others, which may have been solved through logical inferences or the memory of specific social situations. However, we found no significant differences between the performance of G.T. and age-matched controls, although we accept that the statistical power of this test is rather weak. These findings are consistent with our other data demonstrating the G.T.'s ability to infer and understand the mental states of others is unimpaired.

Interestingly, when considering the results of both the neuropsychological and the experimental investigations, G.T. provides further evidence that executive functioning and ToM ability are dissociable (Fine *et al.*, 2001; Rowe *et al.*, 2001).

Implications for the cognitive anatomy of ToM

Our findings leave us with a paradox as to why neuroimaging studies of ToM consistently activate areas of the medial frontal cortex, whilst G.T.'s performance of ToM tests is unimpaired. The first possibility is that G.T.'s lesion did not involve all areas of the medial frontal lobe necessary to subservise ToM. Some functional imaging studies, for example, have reported activation

peaks that are 12 mm lateral to the midline (e.g. Fletcher *et al.*, 1995; Goel *et al.*, 1995) and G.T.'s lesion does not extend fully to include all sub-cortical structures at this depth. Moreover, her lesion is not perfectly symmetrical, as she has, in general, more extensive involvement of right sub-cortical regions. It therefore remains possible that the areas of the medial frontal lobes spared by her lesion are sufficient to subservise her ToM abilities. Nevertheless, G.T. represents an important case because the data presented here suggest ToM is not impaired in her by bilateral loss of the extensive areas of medial frontal cortex demarcated in Fig. 1. Furthermore, given the dramatic and lasting effect G.T.'s stroke had on several areas of cognition (see below), it seems unlikely that there should be very little impact on her ToM ability, were this area critical.

It is nevertheless possible that the areas damaged in G.T. are necessary for the normal acquisition of a ToM, despite not being essential for the implementation of ToM (as assessed by our range of mentalizing tasks) during adulthood. By analogy, for example, it has been shown using fMRI that anterior brain regions (in the dorsolateral prefrontal cortex) are involved when learning a sequence of movements, but after the sequence has been overlearned, this frontal activation decreases and the task is subserved by other regions (e.g. Jueptner *et al.*, 1997a, b). Learning the subtleties of social interactions would, of course, require a much longer learning phase and medial frontal areas may always be recruited in the healthy brain even if they are no longer essential for normal ToM abilities. This proposal could be tested by investigating ToM abilities in (rare) individuals who sustained very early damage to medial frontal areas.

A related issue concerns the precise role that the medial frontal cortex plays while subjects perform mentalizing tasks. The role ascribed to the medial frontal cortex is in top-down control over processing taking place in other parts of the mentalizing circuit (Frith and Frith, 2003). It is quite possible that, in adults who have developed normally, such top-down control is unnecessary to perform the kinds of tasks used in this study and is only necessary for rapidly modulating processing in complex, novel social situations [cf. a proposed role of the orbitofrontal cortex in reward learning (Rolls, 1999)]. Were this the case, G.T. may show deficits in social cognition in complex social environments or her social behaviour may become more aberrant over time as a result of prolonged absence of top-down modulation.

Another possible explanation for the discrepancy between our findings and those of neuroimaging studies is that following G.T.'s stroke, there was re-organization of her mentalizing circuit. We consider this to be unlikely because G.T.'s performance on ToM tests was first tested within 13 weeks of lesion onset. However, we accept that it remains a possibility that compensation or recovery of function occurred during this period in G.T., and that is why ToM might be intact. But if this is the case, it would still suggest that the medial frontal regions damaged in G.T. are not

necessary for ToM and that other brain regions are capable of performing this function.

Our final suggestion concerns the areas beside the medial frontal cortex that have been implicated in mentalizing. Functional imaging studies of ToM have implicated several regions other than the medial frontal cortex, e.g. temporo-parietal junction or superior temporal sulcus, temporal pole, amygdala and orbitofrontal cortex (Adolphs, 2003; Frith and Frith, 1999, 2003). Although some analyses have suggested a special role for medial frontal cortex within a dedicated mentalizing system (Gallagher and Frith, 2003), it remains a distinct possibility that damage to one part of that network is not sufficient to destroy its functional integrity. Whatever the precise reason(s) for the differences between our results and those of functional imaging studies, the data reported here urge caution in concluding that medial frontal cortex is critical for effecting ToM.

Is G.T. an unrepresentative case?

Given her lack of impairment on ToM tasks, it is worth considering whether there was any evidence of unusual cerebral organization of cognitive function in G.T.. We think it is unlikely that G.T. is a 'special' case, unrepresentative of the normal population. First, as far as we are aware from discussions with her family, she did not appear to have a particularly unusual personality prior to her stroke. Secondly, she was able to perform her job as a teacher without difficulty for the duration of her working life. Thirdly, and perhaps more importantly, all the cognitive impairments we identified in G.T. are in good accordance with previous neuropsychological studies.

A previous case of bilateral infarction of the anterior cingulate gyri reported that the patient exhibited a confabulatory amnesic syndrome, although no formal neuropsychological assessment was conducted (Laplaine *et al.*, 1981). In addition, it has been widely reported that patients with lesions to the posterior medial orbitofrontal cortex and basal forebrain often confabulate for several months (e.g. Schnider *et al.*, 2000). Furthermore, fornix damage alone is sufficient profoundly to impair anterograde recall memory and to a lesser extent, recognition memory (Aggleton *et al.*, 2000). Since her lesion compromised posterior medial orbitofrontal cortex, basal forebrain and the fornix, the neuropsychological deficits we found in G.T. are consistent with previous neuropsychological studies of memory.

G.T. also demonstrated severe impairment on the six-element subtest of the BADS (Wilson *et al.*, 1996), in that she failed to spontaneously initiate switches between tasks. Burgess and colleagues (Burgess *et al.*, 2000) reported failures of task switching on a similar test in patients with damage to medial and polar aspects of BA 8, 9 and particularly 10. These were the areas damaged in G.T. Thus, her pattern of neuropsychological impairment is entirely concordant with previous reports concerning the

neural underpinnings of these cognitive functions. Consequently, in our opinion, there is no reason to assume that G.T.'s cerebral organization of cognitive function is in any way atypical.

Conclusions

In summary, patient G.T. suffered bilateral ACA infarction, resulting in a dysexecutive syndrome characterized by a severe planning and prospective memory impairment, as well as a confabulatory, amnesic syndrome. Despite this, her performance on a range of ToM tasks was unimpaired. We therefore conclude that the medial frontal regions damaged in this case are not necessary for ToM, and our results urge caution against using functional imaging as the sole method of establishing cognitive neuroanatomy.

Acknowledgements

We wish to thank Professor Chris Frith for his helpful comments, Professor John Hodges and Dr Sinclair Lough for making available the materials for the Faux Pas Test and Gail Robinson and Ameer Baird for rating G.T.'s responses. We are very grateful to G.T. and her husband. This research was supported by the MRC Co-operative Grant at the Institute of Cognitive Neuroscience, UCL. M.H. is supported by the Wellcome Trust.

References

- Abell F, Happe F, Frith U. Do triangles play tricks? Attribution of mental states to animated shapes in normal and abnormal development. *Cogn Dev* 2000; 15: 1–16.
- Adolphs R. Cognitive neuroscience of human social behaviour. *Nat Rev Neurosci* 2003; 4: 165–78.
- Aggleton JP, McMackin D, Carpenter K, Hornak J, Kapur N, Halpin S, et al. Differential cognitive effects of colloid cysts in the third ventricle that spare or compromise the fornix. *Brain* 2000; 123: 800–15.
- Army Individual Test Battery. Washington (DC): War Department, Adjutant General's Office; 1944.
- Baron-Cohen S. *Mindblindness: an essay on autism and theory of mind*. Cambridge (MA): MIT Press, 1995.
- Baron-Cohen S, Leslie AM, Frith U. Does the autistic child have a 'theory of mind'? *Cognition* 1985; 21: 37–46.
- Baron-Cohen S, Jolliffe T, Mortimore C, Robertson M. Another advanced test of theory of mind: evidence from very high functioning adults with autism or Asperger syndrome. *J Child Psychol Psychiatry* 1997; 38: 813–22.
- Baron-Cohen S, Leslie AM, Frith U. Mechanical, behavioural and intentional understanding of picture stories in autistic children. *Br J Dev Psychol* 1986; 4: 113–25.
- Baron-Cohen S, O'Riordan M, Stone V, Jones R, Plaisted K. Recognition of faux pas by normally developing children and children with Asperger syndrome or high-functioning autism. *J Autism Dev Disord* 1999a; 29: 407–18.
- Baron-Cohen S, Ring HA, Wheelwright S, Bulmore ET, Brammer MJ, Simmons A, et al. Social intelligence in the normal and autistic brain: an fMRI study. *Eur J Neurosci* 1999b; 11: 1891–8.
- Berthoz S, Armony JL, Blair RJ, Dolan RJ. An fMRI study of intentional and unintentional (embarrassing) violations of social norms. *Brain* 2002; 125: 1696–708.
- Bogousslavsky J, Regli F. Anterior cerebral artery territory infarction in the Lausanne Stroke Registry. Clinical and etiologic patterns. *Arch Neurol* 1990; 47: 144–50.
- Bottger S, Prosiegel M, Steiger HJ, Yassouridis A. Neurobehavioural disturbances, rehabilitation outcome, and lesion site in patients after rupture and repair of anterior communicating artery aneurysm. *J Neurol Neurosurg Psychiatry* 1998; 65: 93–102.
- Brunet E, Sarfati Y, Hardy-Bayle MC, Decety J. A PET investigation of the attribution of intentions with a nonverbal task. *Neuroimage* 2000; 11: 157–66.
- Burgess PW, Shallice T. Response suppression, initiation and strategy use following frontal lobe lesions. *Neuropsychologia* 1996; 34: 263–72.
- Burgess PW, Shallice T. *The Hayling and Brixton Tests*. Bury St Edmunds (UK): Thames Valley Test Company; 1997.
- Burgess PW, Veitch E, de Lacy Costello A, Shallice T. The cognitive and neuroanatomical correlates of multitasking. *Neuropsychologia* 2000; 38: 848–63.
- Bush G, Luu P, Posner MI. Cognitive and emotional influences in anterior cingulate cortex. *Trends Cogn Sci* 2000; 4: 215–22.
- Castelli F, Happe F, Frith U, Frith C. Movement and mind: a functional imaging study of perception and interpretation of complex intentional movement patterns. *Neuroimage* 2000; 12: 314–25.
- Castelli F, Frith C, Happe F, Frith U. Autism, Asperger syndrome and brain mechanisms for the attribution of mental states to animated shapes. *Brain* 2002; 125: 1839–49.
- Channon S, Crawford S. The effects of anterior lesions on performance on a story comprehension test: left anterior impairment on a theory of mind-type task. *Neuropsychologia* 2000; 38: 1006–17.
- Cohen RA, Kaplan RF, Moser DJ, Jenkins MA, Wilkinson H. Impairments of attention after cingulotomy. *Neurology* 1999a; 53: 819–24.
- Cohen RA, Kaplan RF, Zuffante P, Moser DJ, Kenkins MA, Salloway S, et al. Alteration of intention and self-initiated action associated with bilateral anterior cingulotomy. *J Neuropsychiatry Clin Neurosci* 1999b; 11: 444–53.
- Coleman M, Gillberg C. *The biology of the autistic syndromes*. New York: Praeger; 1995.
- Costello AL, Warrington EK. Dynamic aphasia: the selective impairment of verbal planning. *Cortex* 1989; 25: 103–14.
- Crawford JR, Garthwaite PH. Investigation of the single case in neuropsychology: confidence limits on the abnormality of test scores and test score differences. *Neuropsychologia* 2002; 40: 1196–208.
- Crawford JR, Moore JW, Cameron IM. Verbal fluency: a NART-based equation for the estimation of premorbid performance. *Br J Clin Psychol* 1992; 31: 327–9.
- Fine C, Lumsden J, Blair RJ. Dissociation between 'theory of mind' and executive functions in a patient with early left amygdala damage. *Brain* 2001; 124: 287–98.
- Fletcher PC, Happe F, Frith U, Baker SC, Dolan RJ, Frackowiak RS, et al. Other minds in the brain: a functional imaging study of 'theory of mind' in story comprehension. *Cognition* 1995; 57: 109–28.
- Frith U. Mind blindness and the brain in autism. *Neuron* 2001; 32: 969–79.
- Frith CD, Frith U. Interacting minds—a biological basis. *Science* 1999; 286: 1692–5.
- Frith U, Frith CD. Development and neurophysiology of mentalizing. *Philos Trans R Soc Lond B Biol Sci* 2003; 358: 459–73.
- Gallagher HL, Frith CD. Functional imaging of 'theory of mind'. *Trends Cogn Sci* 2003; 7: 77–83.
- Gallagher HL, Happe F, Brunswick N, Fletcher PC, Frith U, Frith CD. Reading the mind in cartoons and stories: an fMRI study of 'theory of mind' in verbal and nonverbal tasks. *Neuropsychologia* 2000; 38: 11–21.
- Gallagher HL, Jack AI, Roepstorff A, Frith CD. Imaging the intentional stance in a competitive game. *Neuroimage* 2002; 16: 814–21.
- Goel V, Grafman J, Sadato N, Hallett M. Modeling other minds. *Neuroreport* 1995; 6: 1741–6.
- Grattan LM, Bloomer RH, Archambault FX, Eslinger PJ. Cognitive flexibility and empathy after frontal lobe lesion. *Neuropsychiatry Neuropsychol Behav Neurol* 1994; 7: 251–9.

- Gregory C, Lough S, Stone V, Erzincliglu S, Martin L, Baron-Cohen S, et al. Theory of mind in patients with frontal variant frontotemporal dementia and Alzheimer's disease: theoretical and practical implications. *Brain* 2002; 125: 752–64.
- Happe FG. The role of age and verbal ability in the theory of mind task performance of subjects with autism. *Child Dev* 1995; 66: 843–55.
- Happe F, Ehlers S, Fletcher P, Frith U, Johansson M, Gillberg C, et al. 'Theory of mind' in the brain. Evidence from a PET scan study of Asperger syndrome. *Neuroreport* 1996; 8: 197–201.
- Happe F, Brownell H, Winner E. Acquired 'theory of mind' impairments following stroke. *Cognition* 1999; 70: 211–40.
- Happe F, Malhi GS, Checkley S. Acquired mind-blindness following frontal lobe surgery? A single case study of impaired 'theory of mind' in a patient treated with stereotactic anterior capsulotomy. *Neuropsychologia* 2001; 39: 83–90.
- Hornak J, Bramham J, Rolls ET, Morris RG, O'Doherty J, Bullock PR, et al. Changes in emotion after circumscribed surgical lesions of the orbitofrontal and cingulate cortices. *Brain* 2003; 126: 1691–712.
- Jolliffe T, Baron-Cohen S. The Strange Stories Test: a replication with high-functioning adults with autism or Asperger syndrome. *J Autism Dev Disord* 1999; 29: 395–406.
- Jueptner M, Frith CD, Brooks DJ, Frackowiak RS, Passingham RE. Anatomy of motor learning. II. Subcortical structures and learning by trial and error. *J Neurophysiol* 1997a; 77: 1325–37.
- Jueptner M, Stephan KM, Frith CD, Brooks DJ, Frackowiak RS, Passingham RE. Anatomy of motor learning. I. Frontal cortex and attention to action. *J Neurophysiol* 1997b; 77: 1313–24.
- Kopelman MD, Wilson BA, Baddeley AD. *The Autobiographical Memory Interview*. Bury St Edmunds (UK): Thames Valley Test Company; 1990.
- Kumral E, Bayulkem G, Evyapan D, Yuntun N. Spectrum of anterior cerebral artery territory infarction: clinical and MRI findings. *Eur J Neurol* 2002; 9: 615–24.
- Laplante D, Degos JD, Baulac M, Gray F. Bilateral infarction of the anterior cingulate gyri and of the fornices. Report of a case. *J Neurol Sci* 1981; 51: 289–300.
- Leclerc X, Fichten A, Gauvrit JY, Riegel B, Steinling M, Lejeune JP, et al. Symptomatic vasospasm after subarachnoid haemorrhage: assessment of brain damage by diffusion and perfusion-weighted MRI and single-photon emission computed tomography. *Neuroradiology* 2002; 44: 610–6.
- McCabe K, Houser D, Ryan L, Smith V, Trouard T. A functional imaging study of cooperation in two-person reciprocal exchange. *Proc Natl Acad Sci USA* 2001; 98: 11832–5.
- McKenna P, Warrington EK. *The Graded naming test*. Windsor, Berks, UK: NFER-Nelson Publishing Co Ltd; 1983.
- Minagar A, David NJ. Bilateral infarction in the territory of the anterior cerebral arteries. *Neurology* 1999; 52: 886–8.
- Nelson HE. A modified card sorting test sensitive to frontal lobe defects. *Cortex* 1976; 12: 313–24.
- Nelson HE, Willison J. *National Adult Reading Test*. Windsor (UK): NFER-Nelson; 1991.
- Pang D. Physics and pathology of closed head injury. In: Lezak MD, editor. *Assessment of the behavioral consequences of head trauma*. New York: Alan R. Liss; 1989.
- Price CJ, Friston KJ. Degeneracy and cognitive anatomy. *Trends Cogn Sci* 2002; 6: 416–21.
- Richardson JTE. *Clinical and neuropsychological aspects of closed head injury*. Hove (UK): Psychology Press; 2000.
- Robertson IH, Ward V, Ridgeway V, Nimmo-Smith I. *The Test of Everyday Attention*. Bury St Edmunds (UK): Thames Valley Test Company; 1994.
- Rolls ET. *The brain and emotion*. Oxford: Oxford University Press; 1999.
- Rowe AD, Bullock PR, Polkey CE, Morris RG. 'Theory of mind' impairments and their relationship to executive functioning following frontal lobe excisions. *Brain* 2001; 124: 600–16.
- Schnider A, Ptak R, von Daniken C, Remonda L. Recovery from spontaneous confabulations parallels recovery of temporal confusion in memory. *Neurology* 2000; 55: 74–83.
- Shallice T. 'Theory of mind' and the prefrontal cortex. *Brain* 2001; 124: 247–8.
- Shamay-Tsoory SG, Tomer R, Yaniv S, Aharon-Peretz J. Empathy deficits in Asperger syndrome: a cognitive profile. *Neurocase* 2002; 8: 245–52.
- Shamay-Tsoory SG, Tomer R, Berger BD, Aharon-Peretz J. Characterization of empathy deficits following prefrontal brain damage: the role of the right ventromedial prefrontal cortex. *J Cogn Neurosci* 2003; 15: 324–37.
- Siegal M, Varley R. Neural systems involved in 'theory of mind'. *Nat Rev Neurosci* 2002; 3: 463–71.
- Stone VE, Baron-Cohen S, Knight RT. Frontal lobe contributions to theory of mind. *J Cogn Neurosci* 1998; 10: 640–56.
- Stone VE, Baron-Cohen S, Calder A, Keane J, Young A. Acquired theory of mind impairments in individuals with bilateral amygdala lesions. *Neuropsychologia* 2003; 41: 209–20.
- Stuss DT, Gallup GG Jr, Alexander MP. The frontal lobes are necessary for 'theory of mind'. *Brain* 2001; 124: 279–86.
- Trenerry MR, Crosson B, DeBoe J, Leber WR. *Stroop Neuropsychological Screening Test*. Odessa (FL): Psychological Assessment Resources; 1989.
- Ugurbil K, Toth L, Kim DS. How accurate is magnetic resonance imaging of brain function? *Trends Neurosci* 2003; 26: 108–14.
- Vogeley K, Bussfeld P, Newen A, Herrmann S, Happe F, Falkai P, et al. Mind reading: neural mechanisms of theory of mind and self-perspective. *Neuroimage* 2001; 14: 170–81.
- Wechsler D. *Wechsler Adult Intelligence Scale—Revised*. New York: Psychological Corporation; 1981.
- Wicker B, Perrett DI, Baron-Cohen S, Decety J. Being the target of another's emotion: a PET study. *Neuropsychologia* 2003; 41: 139–46.
- Wilson BA, Alderman N, Burgess PW, Emslie H, Evans JJ. *The Behavioural Assessment of the Dysexecutive Syndrome*. Bury St Edmunds (UK): Thames Valley Test Company; 1996.

Appendix I: Description of the experimental tasks

Task 2: Strange Stories Test

An example of a ToM story is reproduced below with the question and G.T.'s verbatim response:

During the war, the Red Army captures a member of the Blue Army. They want him to tell them where his army's tanks are: they know they are either by the sea or in the mountains. They know that the prisoner will not want to tell them, he will want to save his army, and so he will certainly lie to them. The prisoner is very brave and clever; he will not let them find his tanks. The tanks are really in

the mountains. Now when the other side ask him where his tanks are, he says: "They are in the mountains".

Why did the prisoner say that?

"Because he thought that the other side knew he always avoided the truth, and that by saying that, they would naturally assume that he was telling them fibs and they would expect to find the tanks in the other location."

Note her appropriate use of mental state terms such as 'thought', 'knew' and 'expect'.

Task 3: Violation of Social Norms Test

An example of a sentence used in the test with the three different endings is reproduced below:

'Simon is having tea at his neighbour's house when their dog enters into the living room.'

(i) "He can not stop sneezing all over his neighbour's table and has to explain he is allergic to dogs."

(ii) "He kicks the dog outside, explaining that animals have all sorts of germs."

(iii) "He asks for the name of the dog and whether it is a good watchdog."

Where (i) is *embarrassing*, (ii) is *inappropriate* and (iii) is *normal*. Correct responses were scored as follows: (i) protagonist embarrassed but behaviour appropriate; (ii) protagonist not embarrassed and behaviour not appropriate; (iii) protagonist not embarrassed and behaviour appropriate.

Task 4: Faux Pas Test

An example of a question where a faux pas was committed is reproduced below:

'Helen's husband was throwing a surprise party for her birthday. He invited Sarah, a friend of Helen's, and said: "Don't tell anyone, especially Helen." The day before the party, Helen was over at Sarah's, and Sarah spilled some coffee on a new dress that was hanging over her chair. "Oh!" said Sarah, "I was going to wear this to your party!" "What party?" asked Helen. "Come on," said Sarah, "Let's go see if we can get the stain out."

The questions and G.T.'s verbatim responses are reproduced below:

Did someone say something they shouldn't have said? "Yes"

Who was that? "That was Sarah, and she said that she was going to wear a particular dress to Helen's party."

And why was shouldn't she have said that? "It was supposed to be a secret."

So why did she said it? "I think she just forgot."

Control question: *Who was the surprise party for?* "Sarah... oh no, Helen"

Task 5: Animations Test

All subjects were first read these instructions, whilst they were able to follow the instructions on a separate sheet:

'The aim of this experiment is to understand how people interpret the movement of abstract shapes. All you have to do is relax, and watch the animations shown on the screen in front of you. The animations are similar to one another (two triangular shapes moving about), but different in their content. The triangles act as characters performing different stories.

Some animations show the two triangles doing something simple together, for example, they are imitating, or copying, each other. Other animations show the two triangles doing something more complex together, as if they are taking into account the other's feelings and thoughts. For example, one triangle is courting the other.

In this experiment, there is no 'right' or 'wrong' answer. While you are watching the animations, be relaxed, and ... enjoy them! After each animation, I will give you four possible descriptions of how the triangles were moving. I want you to choose the description that you think best describes the animation.

Now I will show you some examples of animations you are going to see. If you have any questions, feel free to ask.'

The animations can be viewed online at: <http://www.icn.ucl.ac.uk/groups/UF/research/animations.html>. An example of the correct description and three lure descriptions for a mentalizing animation and a physical animation are reproduced below.

Mentalizing animation

Correct 'Red encourages Blue to go out' (ToM description)

Lure 1 'Red barges Blue out' (physical description)

Lure 2 'Blue skips out past Red' (physical description)

Lure 3 'Red and Blue are moving around aimlessly' (random movement description)

Physical animation

Correct 'Red and Blue are fighting' (physical description)

Lure 1 'Blue is offended by Red' (ToM description)

Lure 2 'Blue is chasing Red' (physical description)

Lure 3 'Red and Blue are moving around aimlessly' (random movement description)