

Crossed Wernicke's aphasia: A case report

Laurie M. Sheehy^{a,*} and Mary E. Haines^b

^a *Department of Speech–Language Pathology, Rehabilitation Services Division of the Medical College of Ohio, Toledo, OH 43614, USA*

^b *Department of Neuropsychology, Rehabilitation Services Division of the Medical College of Ohio, Toledo, OH 43614, USA*

Accepted 15 September 2003

Abstract

Crossed aphasia is a phenomenon in which an individual sustains a lesion in the right hemisphere (typically non-language dominant), but who exhibits an aphasic syndrome. The authors present a case study of an individual with crossed aphasia (CA) in an attempt to provide anecdotal information for four questions posed by Pita, Karavelis, and Foroglou (1997): (a) Is CA a reversal of the normal cerebral hemisphere pattern of language function? (b) Does the presence of aphasia following a right cerebral hemisphere lesion indicate that typical right hemisphere functions (e.g., visual perception) are intact? (c) How may the aphasia's presentation differ from typical left hemisphere aphasias? And (d) is the pattern of improvement following CA similar to that of typical left hemisphere aphasias? We longitudinally examined the communicative-cognitive performance of an adult man with crossed aphasia of the Wernicke's type following a cerebrovascular accident. A 21-week follow-up evaluation indicated improvements in his language functioning from our initial evaluation, but he continued to exhibit a classic, moderately severe Wernicke's aphasia.

© 2003 Elsevier Inc. All rights reserved.

Keywords: Aphasia; Wernicke's aphasia; Crossed aphasia; Language impairment; Fluent aphasia

1. Introduction

Crossed aphasia (CA) refers to a right-handed person who experiences a cerebrovascular accident (CVA) in the right hemisphere, but who exhibits multi-modality language impairment.

Pita, Karavelis, and Foroglou (1997) proposed the following questions regarding the syndrome of Crossed Aphasia (CA): (a) Is CA a mirror image, that is, a complete reversal of the normal pattern (left hemisphere) for language function? (b) Does this atypical cerebral dominance suggest that other functions (i.e., attention, visuo-perception, etc.) are redistributed or spared? (c) What type of relationship exists between the language dominant hemisphere and the type of aphasia? And (d) Does the interpretation of CA apply to the general issue of right hemisphere language function and recovery from aphasia in general (regardless of right/left lesion location)?

The present case study attempted to provide anecdotal answers to some of these questions. The individual in the present study met the following criteria for CA as cited by Primavera and Bandini (1993): (a) absence of left-handedness or ambidexterity in the individual or his relatives; (b) clear documentation of the size and location of the lesion; (c) absence of any previous neurological lesions; (d) sufficiently documented aphasic symptomatology; and (e) absence of environmental factors suspected to be related to the different functional organization of the brain (bi- or plurilingualisms, illiteracy, ideographic, or tonal languages).

2. History of reported case

PD is a 67-year-old, right-handed, married man. Per his report, his immediate family (parents, siblings, son) are all right handed. There was no history of developmental delay or learning disabilities in childhood or previous neurological insult. Medical history was positive for hypertension, hyperlipidemia, cholecystectomy, and congenital hearing impairment requiring hearing aid.

* Corresponding author. Fax: 1-419-861-4869.

E-mail addresses: lsheehy@mco.edu (L.M. Sheehy), mhaines@mco.edu (M.E. Haines).

PD's school history included some college. Prior to the CVA, he had been working for many years as a food broker.

On September 19, 2000, his wife found him in the basement exhibiting left-sided weakness and an inability to communicate; she brought him to the emergency room of a local acute care hospital. Upon physical examination, PD was awake, but did not consistently answer questions or respond to commands. He appeared to have a profound neglect of his left side and would routinely neglect individuals attempting to speak to him on his left side. Initially, he appeared to have complete flaccidity of the left arm and leg and some slight facial weakness on the left side. Computed tomography (CT) without contrast of the brain revealed a decrease in the sharpness in the right hemisphere compared to the left hemisphere, raising the question of early changes associated with infarct (see Fig. 1). A neurological examination performed approximately one hour after his admission to the emergency room revealed that PD was able to move voluntarily his left arm, but he exhibited reduced voluntary movement in the left leg. Because the emergency room physicians did not know the exact time of onset of the stroke and because he was improving, he

was not deemed an appropriate candidate for “clot busting” medication. Non-contrast magnetic resonance imaging (MRI) of the brain indicated apparent diminished flow (as seen on spin echo images) through the central right middle cerebral artery branches in comparison with the left. No additional signal abnormalities were exhibited and there was no evidence of additional recent infarcts or of any pathology on the left (see Fig. 2). PD was diagnosed with an acute right middle cerebral infarct.

Upon admission to the outpatient rehabilitation facility (three weeks post-onset), PD presented with left hemiparesis, reduced cognitive abilities, and impaired home management skills. From a speech–language perspective, he demonstrated Wernicke's aphasia characterized by deficits in auditory comprehension, verbal expression, reading comprehension, and written expression. A detailed evaluation is reported for both verbal and non-verbal cognitive-linguistic tasks.

2.1. Laterality

PD indicated a strong right-hand preference for practice tasks. A task of gross motor strength indicated grip

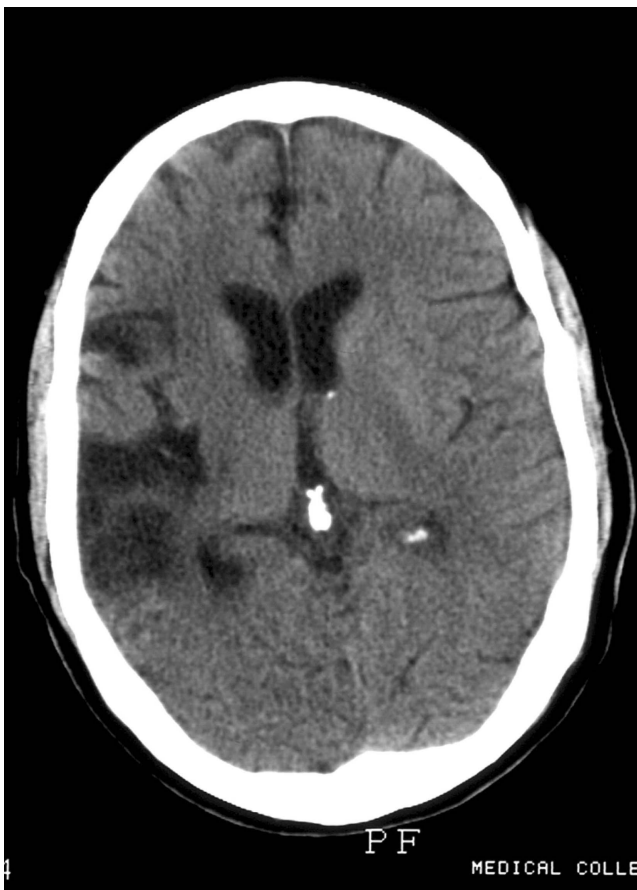

Fig. 1. CT of brain indicating right middle cerebral artery infarct.

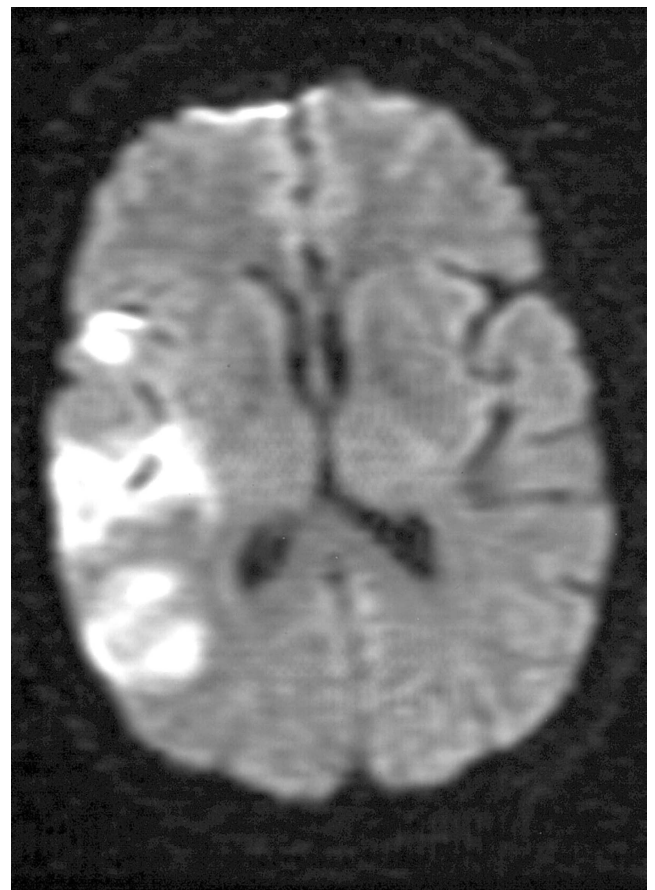


Fig. 2. MRI of the brain indicating right middle cerebral artery infarct.

strength of 42.5 kg with his right hand and 32.5 kg with his left, a discrepancy consistent with left hemiparesis.

3. Speech and language functions

3.1. Initial evaluation

At the initial evaluation, (3-weeks post-onset), PD presented with fluent but frequently unintelligible speech and writing skills characterized by literal (phonemic) paraphasias (e.g., “nikes” for “likes”), verbal (semantic) paraphasias (e.g., “boy” for “girl”), and neologistic jargon (e.g., “derk,” “tickie”). A closer examination of his verbal language revealed that he demonstrated non-functional naming skills, a phrase length of 7 plus “words” per utterance, more functor words (e.g., the, an, and a) than substantive/content words, extensive paraphasias, but normal prosody. His verbal output appeared hyperfluent in that he seemed to try to say as much as he could at one time.

His written language was characterized by intact praxis for writing movement, preserved automatisms (e.g., producing the numbers 1 to 21, or writing the alphabet), and a preserved ability to copy sentences. However, it was vitiated by the production of paraphasias and written neologisms, poor written confrontation naming and an inability to formulate biographical information or single words. On a narrative writing task in which he was asked to look at a picture of a woman washing dishes and two children getting cookies (“Cookie Theft” from BDAE), he wrote a limited number of relevant words (see Appendix A). The sentence structure was recognizable, but the nouns are mostly neologistic. He also demonstrated greater than normal written output.

Auditory comprehension was impaired at the sentence level. While he was able to understand straightforward questions such as, “Is it a policeman’s duty to enforce the law?” he exhibited difficulty with more subtle relationships, such as comparative questions: “Does an apple have more juice than an orange?”

Reading comprehension was intact for single words and impaired for sentences.

3.2. Follow-up evaluation

Twenty-one weeks post-onset, PD’s language skills had improved and his overall communication effectiveness was only mildly-to-moderately impaired. He independently used gestures and written words or drawings to augment and complement his verbal productions.

His expressive speech/language skills had improved to the moderately impaired level. Although he was able to recite automatic sequences (e.g., counting from 1 to 20), he demonstrated mild difficulties with anything more

complex. His naming skills continued to be non-functional. On a verbal narrative task again using the Cookie Theft picture, PD demonstrated only two paraphasias, but he appeared to be having word retrieval difficulties as evidenced by the vagueness of the verbal output.

Written expression was also improved. The mechanics of writing continued to be consistent with his premorbid level. His ability to produce written automatisms continued to be relatively preserved. On the written narrative task (Cookie Theft), his performance was improved (see Appendix A). The most significant difference was subjective, in that he appeared to be very conscientious and took his time to formulate his thoughts rather than impulsively writing.

Auditory comprehension was intact for spoken paragraphs (contextual information). However, based on the results from the Revised Token Test, his auditory comprehension skills for following instructions, when compared to norms based on individuals without neurological insult, were mildly impaired.

Reading comprehension was mildly impaired for sentences and his ability to read paragraphs continued to be non-functional. This frustrated PD and he often said he wished he could just pick up the newspaper and understand it.

4. Cognitive functions

4.1. Initial evaluation

Extensive neurocognitive testing was not completed during the initial assessment given the severity of his aphasia. However, we administered two subtests from the Wechsler Memory Scale—Revised to examine immediate visual memory for figural stimuli (Figural Memory) and abstract visual material (Visual Paired Associates). He performed in the average range on the immediate recall subtest of Figural Memory subtest, but in the impaired range on the immediate recall subtest of Visual Paired Associates. A closer examination of his performance suggested difficulties in encoding and consolidation of the information. We also administered the Raven’s Coloured Progressive Matrices (RCPM) to examine non-verbal abstract reasoning. His performance on the RCPM was low average. Subjectively, both PD and wife stated that he would have done better with the task premorbidly.

4.2. Follow-up evaluation

At 21 weeks post-onset, we conducted a more comprehensive neuropsychological assessment to delineate cognitive functioning. A qualitative examination of his performance suggests that his visual memory (both immediate and delayed) and his visual attention skills

were within normal limits. In addition, PD was administered the Performance tasks from the Wechsler Adult Intelligence Scale—3rd Edition (WAIS-III). He obtained an overall Performance IQ of 92 (average). However, his performance on the Block Design subtest from the WAIS-III was in the mildly impaired range; his approach to this subtest was characterized by broken matrices, an indication of visual perceptual disturbance. Additionally, we administered a task of visual form discrimination task; his performance was impaired and characterized by errors of rotation and distortion. Overall, PD exhibited visual perceptual deficits, suggesting the right CVA also impacted this area of functioning.

5. Discussion

This case study has attempted to provide anecdotal answers to several questions about CA. First, is CA a mirror image, that is, a complete reversal of the normal pattern (left hemisphere) for language function? Based upon PD's performance on testing, the answer is no. While PD appears to be right hemisphere dominant for language, (which resulted in deficits in auditory comprehension, naming, speaking, reading comprehension, writing, calculations, and verbal memory), he also exhibited some typical right hemisphere impairments such as visual perceptual deficits and impaired visual memory. Furthermore, the more significant recovery of his auditory comprehension as compared to his verbal expression may suggest that some of this ability is located in PD's left hemisphere, which appeared to be intact. An additional factor could be the type of alexia that PD exhibited: his reading ability appeared essentially intact for understanding high frequency, concrete nouns (i.e., table) but impaired for less "visual" words such as modifiers (i.e., adjectives and adverbs) or functors (i.e., pronouns, prepositions, conjunctions, etc). Perhaps some of his reading ability was in his intact left hemisphere.

The second question we attempted to answer was as follows: Does this atypical cerebral dominance suggest that other functions (i.e., attention, visuoperception) are redistributed or spared? Based upon PD's performance, the answer is yes. He evidenced intact prosodic expression/comprehension, and good constructional skills. His ability to communicate using a wide variety of strategies (gestures, drawing, writing, and speaking) suggests good organization/planning and problem solving/reasoning skills.

The third question we proposed was as follows: What type of relationship exists between the language dominant hemisphere and the type of aphasia? Strokes occurring in the dominant hemisphere involving the middle cerebral artery (MCA) typically lead to paresis of

the face and arm on the contralateral side with the eyes deviated toward the side of infarction. When the stroke is restricted to the central portion of the MCA, Wernicke's aphasia often occurs. Person's with Wernicke's aphasia will have fluent language output characterized by average sentence structure and grammatical use with paraphasic content, normal speech intelligibility, poor ability to repeat and name, and impaired auditory comprehension. PD's stroke occurred in the central MCA and his cognitive-communicative performance was consistent with Wernicke's aphasia.

The final question we endeavored to resolve was as follows: Does the interpretation of CA apply to the general issue of right hemisphere language function and recovery from aphasia in general (regardless of right/left lesion location)? What we observed in PD was a course of recovery from his aphasia not unlike that which is typically seen in traditional Wernicke's aphasia. That is, he presented with severe expressive aphasia and while he did make gains, by 21 weeks post-onset, he was still exhibiting moderate expressive aphasia.

Appendix A. Verbal and written narrative of "Cookie Theft"

A.1. 3-weeks post onset

PD's verbal response

She's out watching his kids. Both of them are trying to get those up. His is up. His is in that. They have to call bear something in the house. This thing that little thing. The boy has a ruff-ruff dog. And this house is jay dishes.

PD's written response:

The month is wring and the wathe is cover up. The boy is cookie. The boy will flose.

A.2. 21 weeks post-onset

PD's verbal response:

The lady. . .uh. . .mudder is getting uh her trying to get washed . . . and its watering too much into the into there. . . and while she's doing uh that her guy her kids are trying to get cwookers while they're in the back. The gal the little lady is waiting till he get it and he's getting ready ready to fall in the house

References

- Pita, G., Karavelis, A., & Foroglou, G. (1997). Crossed aphasia with alalia in Greek—a case study: Extent of a problem. *Journal of Neurolinguistics*, 10, 1–9.
- Primavera, A., & Bandini, F. (1993). Crossed aphasia: Analysis of a case with special reference to the nature of the lesion. *European Neurology*, 33, 30–33.