
Selected Topics: Toxicology

CEREBRAL INFARCTS IN A PEDIATRIC PATIENT SECONDARY TO PHENYLPROPANOLAMINE, A RECALLED MEDICATION

Nicole M. Delorio, MD

Department of Emergency Medicine, Oregon Health and Science University, Portland, Oregon

Reprint Address: Nicole M. Delorio, MD, Oregon Health and Science University, 3181 SW Sam Jackson Park Rd., Mail code CDW-EM, Portland, OR 97201

□ **Abstract**—Phenylpropanolamine (PPA) recently has been publicly implicated as a cause of stroke and other neurologic events. In November of 2000, the Food and Drug Administration (FDA) requested a voluntary recall of the product from all manufacturers. However, medications containing PPA still can be found in many homes of those unaware of the voluntary recall. We present a case of stroke after PPA ingestion that occurred 4 months after the recall in an 8-year-old boy on chronic peritoneal dialysis. The patient developed occipital infarcts and was found to have extremely elevated levels of PPA in his blood and dialysis fluid. Though the voluntary recall was in effect, the family already had a bottle of the medication at home. Physicians must be aware that the public is still ingesting the drug and remain rigorous in including its toxicity in the differential diagnosis of acute neurologic events. © 2004 Elsevier Inc.

□ **Keywords**—phenylpropanolamine; cerebral infarction; cerebrovascular accident; pediatrics; overdose

INTRODUCTION

Phenylpropanolamine (PPA) has been suspected to be the cause of various adverse neurologic effects since at least the 1960s (1). Case reports have noted associations of PPA use with headache, seizure, intracranial hemorrhage, hypertensive encephalopathy, and cerebral vasculitis (2).

Until as recently as November of 2000, PPA was an

ingredient in over 100 over-the-counter formulations as cold medications and diet aids (2,3). Prompted by the results of the Yale study, *Phenylpropanolamine & Risk of Hemorrhagic Stroke: Final Report of the Hemorrhagic Stroke Project*, which linked the drug with hemorrhagic stroke, the FDA issued a request that drug manufacturers voluntarily remove PPA from their medications (4). However, despite the FDA issuing a Public Health Advisory, the public may remain unaware of these events. As a result, PPA still exists on the medicine shelves of consumers.

CASE REPORT

An 8-year-old boy on chronic peritoneal dialysis secondary to renal agenesis developed upper respiratory tract infection symptoms with a cough and fevers as high as 38.4°C. At home, he was treated with approximately 3 days of acetaminophen, ibuprofen, and an unknown amount of over-the-counter cold remedy containing phenylpropanolamine. The father stated that he was administering the medications according to the packaging directions, but could not be more specific regarding the amount of PPA-containing product the child had received. Other chronic medications were ranitidine, paroxetine, calcium, epoetin alfa, and growth hormone. He did have a history of mild hypertension, for which he was on no medication; he had no past medical history of

Selected Topics: Toxicology is coordinated by *Kenneth Kulig*, MD, of Denver, Colorado

RECEIVED: 28 October 2002; FINAL SUBMISSION RECEIVED: 27 August 2003;

ACCEPTED: 16 September 2003

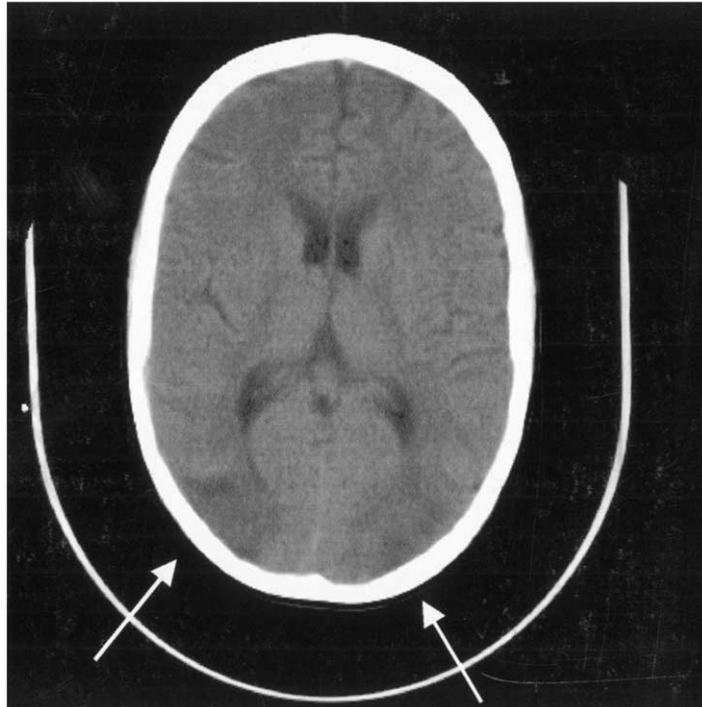


Figure 1. Bilateral parieto-occipital infarcts secondary to PPA-induced vasculitis.

seizures. Other past medical history included a failed cadaveric renal transplant, recurrent peritonitis, and anemia of chronic disease. On the 3 days preceding the admission, his father had noted the patient's blood pressure to be elevated in the 140–150/100 mm Hg range, when it was usually about 120 mm Hg systolic. This was treated as it routinely was, by manipulating the peritoneal dialysis fluid. The patient presented to the Emergency Department (ED) the next day when he developed a diffusely severe headache, one episode of vomiting, and blurry vision.

Physical examination on admission revealed an uncomfortable-appearing patient holding the front of his head. He seemed sleepy and slightly confused. The blood pressure was 154/90 mm Hg and pulse was 64 beats/min. He was afebrile. The neurological examination showed that he was disoriented to location. He had no light perception bilaterally, but the other cranial nerves were normal. The fundi could not be visualized. Motor and sensory components of the examination were normal, but because the patient was blind, cerebellar testing was difficult to assess.

After the administration of intravenous antibiotics, computed tomography (CT) scan of the head without contrast was performed, demonstrating bilateral watershed infarcts in the parieto-occipital areas with edema, though without mass effect (Figure 1). An MRI/MRA confirmed the presence of a focal vasculitis.

A complete blood count was normal. A basic metabolic panel showed a sodium of 138 mEq/L, potassium of 2.9 mEq/L, chloride of 91 mEq/L, CO_2 of 32 mEq/L, BUN of 37 mg/dL, creatinine of 8.2 mg/dL, glucose of 99 mg/L, and a calcium of 8.7 mEq/L; with the exception of the potassium, these values were similar to the patient's baseline levels. An initial phenylpropanolamine level obtained from the serum was 300 ng/ml. Reference values for our laboratory report the "normal range" for PPA to be 90 ng/ml after a 50-mg dose (suggested adult dose). Therapeutic blood concentrations are believed to range from 30 to 200 ng/mL (5). Serial levels were found to be 190 ng/mL on hospital day (HD) 2, 140 ng/mL on HD 3, 110 ng/mL on HD 4, 89 ng/mL on HD 5, 62 ng/mL on HD 6, and 53 ng/mL on HD 7. Dialysate levels of PPA peaked at 120 ng/mL on HD 2. Lumbar puncture was performed, which showed an opening pressure of 40. All viral and bacterial serologic exams were negative. Two grand mal seizures and further episodes of hypertension complicated the patient's hospital course. Fosphenytoin was begun but discontinued before discharge. The patient's hypertension did resolve without treatment. The blindness began to resolve spontaneously, and at follow-up 7 weeks later his vision was completely normal.

The discharge diagnosis was "cortical infarct, thought to be secondary to phenylpropanolamine-induced vasculitis."

DISCUSSION

Phenylpropanolamine is a catecholamine, which, though less potent than amphetamines, still causes many similar effects such as hypertension and vasoconstriction. It is also a direct alpha-1 agonist and indirect alpha and beta agonist. Its first use occurred early in the 20th century, when it was administered as a parenteral vasopressor agent. Over-the-counter use began in the 1930s as a decongestant, and in the 1940s drug manufacturers began exploiting its anorexia-causing properties by marketing it as a diet aid.

Though PPA is known to be excreted 80–90% unchanged in the urine within 48 h, little is published about its effects in patients with renal failure (5). Citations of problems with the drug began in the 1960s (1). Case reports through the 1990s note an apparent association with PPA and hemorrhagic strokes, cerebral hypertension, seizures, cerebral infarcts, and cerebral vasculitis (2,5). Renal problems such as acute interstitial nephritis, acute tubular necrosis, and acute renal failure have been reported as well (5). In 1982, the FDA banned products that contained PPA, ephedrine, and caffeine in combination. However, the FDA still regarded PPA used without those other medications to be safe.

Until recently, few studies adequately and effectively addressed the safety of PPA. Previous references are limited to case reports, small trials, or supratherapeutic dosing regimens. However, in 2000 the FDA received the results of a Yale study that looked at the odds ratios (OR) for the associations of cerebral hemorrhage and use of PPA (4). Analysis showed that an increased OR did exist, with the highest subgroup analysis showing an OR of 16.58 for the association of stroke and PPA-containing appetite suppressants in the previous 72 h. However, the study does not address the association of PPA with cerebral infarctions as occurred in our patient, and this issue remains poorly investigated in the literature. Though the etiology of our patient's hypertension and ultimate stroke may have been multi-factorial, epogen and paroxetine also have been associated with hypertension. The temporal association of elevated PPA levels and acute cerebral vasculitis in this patient cannot be denied. Eighty to ninety percent of the drug is normally

excreted unchanged through the kidneys (5). Thus, a patient with renal failure such as this one would be at a much higher risk for potential toxicity from prolonged exposure in the bloodstream.

As a result of the Yale Hemorrhagic Stroke Project and other literature review, the FDA concluded that there is an association between PPA and hemorrhagic stroke. In November 2000, the FDA formally recommended that PPA not be considered safe for over-the-counter use and asked drug manufacturers to voluntarily discontinue marketing any products containing PPA (6,7). All manufacturers have complied.

The FDA also issued a public health advisory warning consumers and health care providers of the risk of PPA. However, as our case illustrates, penetration of this information into households is less than 100%. Though many physicians realize that the drug has been voluntarily taken off the market, they may not be aware that the drug still exists in the medicine cabinets of many consumers. When CNS catastrophe occurs in the absence of other risk factors, PPA toxicity must be on the differential diagnosis. Patients should be warned to avoid expired or recalled medications.

REFERENCES

1. Kernan WN, Viscoli CM, Brass LM, et al. Phenylpropanolamine and the risk of hemorrhagic stroke. *N Engl J Med* 2000;343:1826–32.
2. Lake CR, Gallant S, Masson E, Miller P. Adverse drug effects attributed to phenylpropanolamine: a review of 142 case reports. *Am J Med* 1990;89:195–208.
3. Mersfelder T. Phenylpropanolamine and stroke: the study, the FDA ruling, the implications. *Cleve Clin J Med* 2001;68:208–23.
4. Horwitz RI, Brass LM, Kernan WN, et al, preparers. Phenylpropanolamine and risk of hemorrhagic stroke. Final report of The Hemorrhagic Stroke Project; 2000 May 10. Available at: www.fda.gov/ohrms/dockets/ac/00/backgrd/3647b1&umbar;tab19/doc. Accessed November 10, 2001.
5. Poisindex [computer program]. Micromedex Healthcare Series. Accessed August 31, 2001.
6. FDA letter to manufacturers of drug products containing phenylpropanolamine (PPA) dated 11/03/2000. Available at: www.fda.gov/cder/drug/infopage/ppa/ppaltr.htm. Accessed August 14, 2003.
7. Phenylpropanolamine (PPA) Information Page. Available at: www.fda.gov/cder/drug/infopage/ppa/default.htm. Accessed August 14, 2003.