

Essam A. Elgamal
Waleed R. Murshid
Hesham M. Abu-Rahma
Deema Samir

Aneurysmal subarachnoid hemorrhage in the first year of life: case report and review of the literature

Received: 22 March 2003
Revised: 6 November 2003
Published online: 17 March 2004
© Springer-Verlag 2004

E. A. Elgamal · W. R. Murshid (✉)
Neurosurgery Department,
King Khalid University Hospital
and College of Medicine,
Riyadh, Saudi Arabia
e-mail: eelgamal@hotmail.com
Fax: +966-1-4679493

H. M. Abu-Rahma
Neurosurgery Department,
Shebin Al-Koom University,
Egypt

D. Samir
Department of Pediatrics,
King Khalid University Hospital
and College of Medicine,
Riyadh, Saudi Arabia

Abstract *Introduction:* Primary subarachnoid hemorrhage is rare in infancy. A bleeding arterial aneurysm as its cause is even less frequent. A review of the literature turned up 85 cases of cerebral aneurysm that occurred in the 1st year of life, 63 of them presenting with subarachnoid hemorrhage (SAH). *Case report:* The authors report a case of an 8-month-old boy who presented with seizures due to ruptured anterior communicating (ACom) artery aneurysm with subsequent subarachnoid and intraventricular hemorrhage. The infant was operated successfully, without complications. *Discussion:* In this report the authors highlight certain clinical and diagnostic features, sur-

gical considerations, and outcomes of aneurysmal subarachnoid hemorrhage in the 1st year of life.

Keywords Cerebral aneurysm · Subarachnoid hemorrhage · Seizures · Infant

Introduction

Pediatric intracranial aneurysms are rare, accounting for 0.5–4.6% of all aneurysms in published series [1, 2, 3, 10, 13, 19, 24, 25, 30, 31, 32, 36, 37]. Rupture of an intracranial aneurysm is extremely uncommon in the 1st year of life [44].

With the increasing use of magnetic resonance angiography (MRA), cerebral angiography, and computed tomography (CT), intracranial aneurysms are now being discovered more often, even in neonates with subarachnoid or intracranial hemorrhage, and several successful operations on infants have been reported [15, 18, 22, 30, 35, 42].

A review of the literature turned up only 85 cases of cerebral aneurysms in the 1st year of life, 63 of them presenting with SAH.

This report documents the clinical course of an infant with a ruptured anterior communicating (ACom) artery aneurysm and demonstrates many key characteristics of aneurysmal subarachnoid hemorrhage in the 1st year of life.

Case report

An 8-month-old boy who was delivered to healthy non-consanguineous parents by smooth delivery after an uncomplicated pregnancy. He had no history of trauma or infectious disease and his development was unremarkable. He was completely well until 6 days prior to admission, when he suddenly began to cry excessively and extended his neck. This was associated with upward rolling of the eyes, salivation, and bluish discoloration of the lips, followed by extension of the right arm and leg and loss of consciousness for 15 min. Two days later, he had similar three episodes, each lasting for a few minutes.

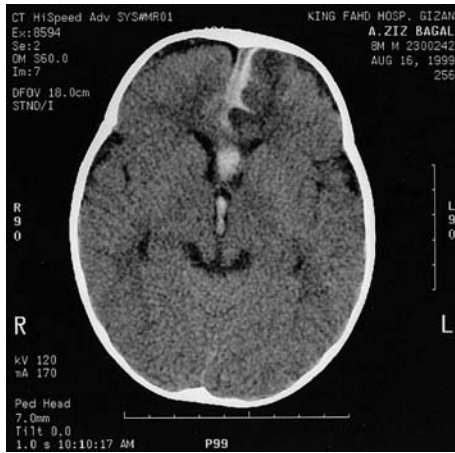


Fig. 1 CT scan of the brain showing subarachnoid hemorrhage filling the interhemispheric fissure, septum pellucidum, and third ventricle

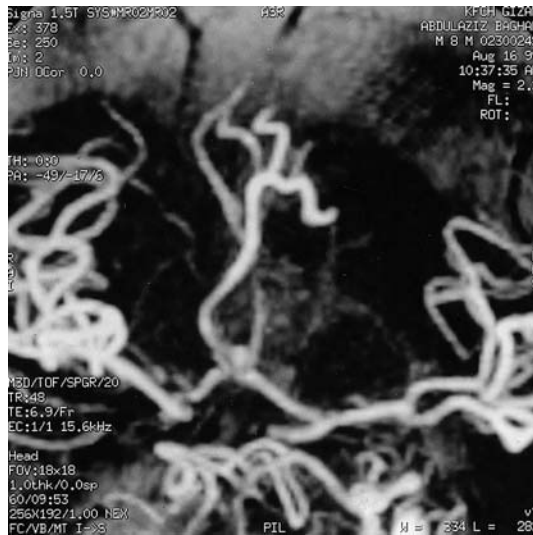


Fig. 2 Cerebral MRA showing ACom artery aneurysm

Upon admission to the hospital, he was conscious, with no posturing or lateralizing signs. The anterior fontanel was not bulging and there was no evidence of retinal hemorrhage or papilloedema on funduscopy.

Cranial CT disclosed SAH mainly in the chiasmatic cistern and interhemispheric fissure, and intraventricular hemorrhage involving all ventricles (Fig. 1).

Magnetic resonance angiography showed an ACom artery aneurysm and a cerebral angiogram confirmed that the aneurysm was filling mainly from the left side, demonstrating spasm of the left anterior cerebral artery (Figs. 2, 3).

A left pterional craniotomy was performed. After splitting the Sylvian fissure the gyrus rectus was sucked out, and a large aneurysm was identified arising from the ACom artery. A small pediatric curved clip, supported by a straight Yasargil clip, was used to secure the aneurysm. The postoperative course was uneventful and the baby was discharged without neurological deficits.

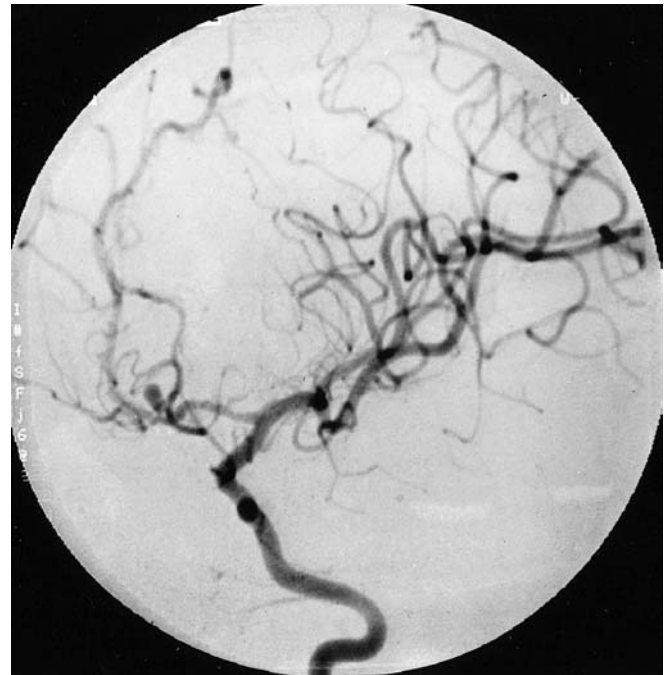

Fig. 3 Cerebral angiography showing ACom artery aneurysm and radiological evidence of vasospasm

Discussion

Intracranial aneurysms are very uncommon in the 1st year of life [38]. We found in the English-language literature only 85 infants aged less than 1 year who were reported to have cerebral aneurysms.

Sixty-three infants suffering aneurysmal SAH were reviewed. There was a slight male predominance (1.4:1.0) and the patients' ages at the time of diagnosis ranged from 0 to 12 months with a mean of 4.8 months. In 75% of the patients (47), the onset of SAH was in early infancy at less than 6 months of age, particularly in the newborn stage. This fact may support the hypothesis of a congenital origin of infantile cerebral aneurysms [20].

Loss of consciousness, apnea, or seizures are the most common initial signs of a bleeding cerebral aneurysm in an infant [34]. Epileptic seizures was an important warning sign in 15 patients (24%) with aneurysmal SAH, including our case (Table 1). The clinical presentation of seizures from ruptured cerebral aneurysms is rarely seen in adults or in series of seizures in infants [12, 43].

Subarachnoid hemorrhage and aneurysms were demonstrated by a combination of imaging studies (CT, angiography, and MRI/MRA) or lumbar puncture or autopsy.

Out of the 85 infants with a cerebral aneurysm, 34 aneurysms (40%) occurred in the middle cerebral artery. The second most frequent location was the posterior

Table 1 Cases reported with aneurysmal subarachnoid hemorrhage (SAH) and presenting with seizures. AComA anterior communicating artery, MCA middle cerebral artery, ACA anterior cerebral artery, PCA posterior cerebral artery, BA basilar artery, PICA posterior inferior cerebellar artery

Reference	Age	Sex	Presentation	Site	Surgery	Prognosis
Present case	8 months	Boy	SAH, IVH, seizures	AComA	Yes	Excellent
[45]	34 days	Girl	SAH, seizures, mycotic	MCA	Yes	Excellent
[5]	4 weeks	?	ICH, seizures, astrocytoma	MCA	Yes	Excellent
[10]	7 weeks	Girl	SAH, seizures	ACA	Yes	Excellent
[35]	7 weeks	?	ICH, seizures, MRI	PCA	Yes	Excellent
[6]	11 months	Girl	SAH, seizures, left hemiparesis	MCA	Yes	Excellent
[21]	12 months	Boy	SAH, seizures	MCA	Yes	Good
[26]	12 months	Boy	SAH, seizures	ACA	Yes	Excellent
[23]	1 day	Girl	SAH, seizures	BA	No	Died
[8]	3 months	Boy	SAH, seizures, left hemiparesis, ophthalmoplegia	Multiple	No	Died
[33]	1 month	Boy	SAH, focal seizures	PICA	No	Died
[41]	3 months	Girl	SAH, seizures, hemiparesis	MCA	Yes	Excellent
[11]	7 weeks	Girl	SAH, seizures	ACA	No	Died
[20]	4 weeks	Girl	SAH, seizures	MCA	Yes	Excellent
[14]	3 months	Boy	Seizures, sudden death	BA Bif.	No	Died

Table 2 Location of the cerebral aneurysms reported in 85 infants below 1 year of age. ICA internal carotid artery, AICA anterior inferior cerebellar artery

Site	Number	%
Anterior circulation		
MCA	34	40
ACA	9	10.5
ICA	7	8.2
AComA	4	4.7
Posterior circulation		
PCA	10	11.8
BA	9	10.5
PICA	5	5.9
AICA	1	1.2
Multiple	2	2.4
Unknown	4	4.8

circulation (29.2%), and 2 infants (2.4%) were reported to have multiple aneurysms. Anterior communicating artery aneurysm in infants is very rare; only 4 cases (4.8%) have been reported including our case (Table 2) [4, 7, 14].

Another characteristic location of the aneurysm in infants is at the distal branches of the main cerebral arteries [5, 21]. These sites differ from the predominance in the anterior portion of the circle of Willis in adults. A history of significant trauma before cerebral aneurysms were discovered, was reported in 8 cases (9.5%), while mycotic aneurysms were found in 4 cases (4.8%).

The first report of aneurysmal surgery on an infant was by Jones and Sheburn [18] in 1961. Since then, the results of many such operations have been reported. Operative results among infants with aneurysmal SAH seem to be better than those among adults. A full prospective recovery occurred in 35 (excellent in 26 and good in 9) out of 54 operated patients (64.8%) with ruptured cerebral aneurysm under 1 year of age, while there was operative mortality was in 6 cases (11.1%). The youngest surgically treated patient reported was a 4-week-old baby who

underwent successful clipping of a right middle cerebral artery aneurysm [18].

The more favorable outcome with aneurysms in infants has been attributed to the rarity of vasospasm and the subsequent cerebral infarction, and to the good functional compensation of the young brain, as it can tolerate increased intracranial pressure due to the elasticity of the skull [38].

Infants usually have no systemic disorders such as diabetes mellitus, hypertension, or arteriosclerosis, all of which are common in adults and significantly affect the outcome.

Endovascular intervention with detachable platinum coils is now considered to be the first line of definitive treatment in patients with ruptured intracranial aneurysms. The International Subarachnoid Aneurysm Trial (ISAT) has shown that with endovascular treatment, the chances of independent survival at 1 year are significantly better than with neurosurgical intervention [27]. To our knowledge, there have been no reports of endovascular treatment of aneurysmal SAH in infants below the age of 1 year.

Summary

There are several distinct characteristics that distinguish infantile cerebral aneurysms from those in older children and adults, summarized as follows:

1. Male predominance, which is contrary to the definitive female dominance in adult aneurysm series [3, 16, 19, 24, 25]
2. Higher incidence of onset in early infancy [9, 19]
3. Higher incidence of aneurysms of the middle cerebral artery and posterior circulation [3, 13, 19, 28, 29]
4. Lower incidence of multiple aneurysms [39, 40]
5. They tend to be larger and giant [3, 10, 19, 37]

6. Seizures are more commonly observed at presentation [12, 17, 43]
7. Lower mortality and better surgical outcome [39]

Cerebral arterial aneurysms have to be considered in the differential diagnosis of stroke-like symptoms in infancy, although the incidence of reported cases is less than two cases per year.

Although conventional angiography remains the gold standard for preoperative imaging, MRA frequently reveals aneurysms and can be used in the future as a non-invasive screening and/or a follow-up tool.

With current progress in microsurgical and endovascular techniques, excellent results can be obtained in a large majority of these patients.

References

1. Allison JW, Davis PC, Sato Y, James CA, Haque SS, Glasier CM (1998) Intracranial aneurysms in infants and children. *Pediatr Radiol* 28:223–229
2. Amacher AL, Drake CG (1975) Cerebral artery aneurysm in infancy, childhood and adolescence. *Childs Brain* 1:72–80
3. Amacher AL, Drake CG (1979) The results of operating upon cerebral aneurysms and angiomas in children and adolescents. *Cerebral aneurysms. Childs Brain* 5:151–165
4. Bolander H, Hassler O, Liliquist B, West K A (1978) Cerebral aneurysm in an infant with fibromuscular hyperplasia of the renal arteries. Case report. *J Neurosurg* 49:57–69
5. Boop FA, Chaddock WM, Sawyer J, Husain M (1991) Congenital aneurysmal hemorrhage and astrocytoma in an infant. *Pediatr Neurosurg* 17:44–47
6. Crisostomo EA, Leaton E, Rosenblum EL (1986) Features of intracranial aneurysms in infants and report of a case. *Dev Med Child Neurol* 28:62–76
7. Ferrante L, Fortuna A, Celli P et al (1988) Intracranial arterial aneurysms in early childhood. *Surg Neurol* 29:39–56
8. Ferry PC, Kerber C, Peterson D, Gallo AA (1974) Arteriectasis, subarachnoid hemorrhage in a three-month-old infant. *Neurology* 27:494–500
9. Forster FM, Alpers BJ (1943) Aneurysm of the circle of Willis associated with congenital polycystic disease of the kidneys. *Arch Neurol Psychiatry* 50:669–676
10. Frank E, Zusman E (1990) Aneurysms of the distal cerebral artery in infants. *Pediatr Neurosurg* 16:179–182
11. Garcia-Chavez C, Moosy J (1963) Cerebral artery aneurysm in infancy: association of agenesis of corpus callosum. *J Neuropathol Exp Neurol* 24:492–501
12. Gewirtz RJ, Broderick RW, Baumann RJ, Stevens J (1998) Fusiform P1 segment artery aneurysm in a pediatric patient: technical case report. *Pediatr Neurosurg* 29:218–221
13. Grode ML, Saunders M, Carton CA (1978) Subarachnoid hemorrhage secondary to ruptured aneurysm in infants. *J Neurosurg* 49:898–902
14. Herman JM, ReKate HL, Spetzler RF (1991) Pediatric intracranial aneurysms: simple and complex cases. *Pediatr Neurosurg* 17:66–73
15. Hirata K, Yamashita T, Ishiwata Y, Yamaguchi K, Kuabara T (1983) A case report of an intracranial aneurysm in an infant. *Nerv Syst Child (Kobe)* 8:1–7
16. Hungerford GD, Marzluff JM, Kempe LG, Powers JM (1981) Cerebral arterial aneurysm in a neonate. *Neuroradiology* 21:107–110
17. Ito M, Yoshihara M, Ishii M, Wahi A, Sato K (1992) Cerebral aneurysms in children. *Brain Dev* 14:263–268
18. Jones RK, Sheaburn EW (1961) Intracranial aneurysm in a 4-week-old infant: diagnosis by angiography and successful operation. *J Neurosurg* 18:122–124
19. Kanaan I, Lasjaunias P, Coates R (1995) The spectrum of intracranial aneurysms in pediatrics. *Minim Invasive Neurosurg* 38:1–9
20. Kasahara E, Murayama T, Yamane C (1996) Giant cerebral arterial aneurysm in an infant: report of a case and review of 42 previous cases in infants with cerebral arterial aneurysm. *Acta Paediatr Jpn* 38:684–688
21. Kitano I, Fukui M, Kinoshita K (1981) Infantile cerebral aneurysm. *Surg Neurol* 6:386–390
22. Kunimine H, Inoue H, Isobel I, Nukui H (1982) Intracranial aneurysm in an infant. Report of a case and review of 31 cases in the literature. *Neurol Surg (Tokyo)* 11:531–538
23. Lee KS, Liu SS, Spetzler RF, ReKate HL (1990) Intracranial mycotic aneurysm in infant: report of a case. *Neurosurgery* 26:129–133
24. Locksley HB (1966) Report on the co-operative study of intracranial aneurysms and subarachnoid hemorrhage. I. Natural history of subarachnoid hemorrhage, intracranial aneurysms and arteriovenous malformations. Based on 6368 cases in the co-operative study. *J Neurosurg* 25:219–239
25. Meier FB, Sundt TM, Fode NC, Morgan MK, Forbes GS, Mellinger JF (1989) Cerebral aneurysms in childhood and adolescence. *J Neurosurg* 70:420–425
26. Milhorat TH (1978) Pediatric neurosurgery. Davis, Philadelphia, pp 334–335
27. Molyneux A, Kerr R, Stratton I, Sandercock P, Clarke M, Shrimpton J, Holman R (2002) International Subarachnoid Aneurysm Trial (ISAT) Collaborative Group. International Subarachnoid Aneurysm Trial (ISAT) of neurosurgical clipping versus endovascular coiling in 2143 patients with ruptured intracranial aneurysms: a randomised trial. *Lancet* 360:1267–1274
28. Morelli R, Laubscher F (1977) Intracranial aneurysm in infancy. *J Neurosurg* 46:832–834
29. Nakamura T, Matsuoka Y, Nishimura S (1977) Traumatic cerebral aneurysm showing remarkable extravasation into the lateral ventricle. Case report in an infant. *No Shinkei Geka* 5:371–378
30. Nishio A, Sakaguchi M, Murata K, Egashira M, Yamada T, Izuo M, Nakanishi N (1991) Anterior communicating artery aneurysm in early childhood. Report of a case. *Surg Neurol* 35:224–229
31. Ostergaard JR, Voldby B (1983) Intracranial arterial aneurysms in children and adolescents. *J Neurosurg* 58:832–837
32. Patel AN, Richardson AE (1971) Ruptured intracranial aneurysms in the first two decades of life. A study of 58 patients. *J Neurosurg* 35:571–576
33. Pickering LK, Hogan GR, Gilbert EF (1970) Aneurysm of the posterior inferior cerebellar artery, rupture in a newborn. *Am J Dis Child* 119:155–158

-
34. Plunkett J (1999) Sudden death in an infant caused by rupture of basilar artery aneurysm. *Am J Forensic Med Path* 20:211–214
 35. Putty TK, Luerssen TG, Campbell RL, Boaz JC, Edwards MK (1990) Magnetic resonance imaging diagnosis of a cerebral aneurysm in an infant. *Pediatr Neurosurg* 16:48–51
 36. Sano K, Ueda Y, Saito I (1978) Subarachnoid hemorrhage in children. *Childs Brain* 4:38–46
 37. Sedzimir CB, Robinson J (1973) Intracranial hemorrhage in children and adolescents. *J Neurosurg* 38:269–281
 38. Shimauchi M, Yamakawa Y, Marouka N, Miyake K (1989) Ruptured intracranial aneurysm in a 19-day-old infant. Case report. *Neurol Med Chir (Tokyo)* 29:1047–1050
 39. Shucart WA, Wolpert SM (1974) Intracranial arterial aneurysms in childhood. *Am J Dis Child* 127:288–293
 40. Valle ELT, Cavalcanti MN (1965) Aneurysms of the circle of Willis: morphological and clinical considerations. In: Fields WS, Sahs AL (eds) *Intracranial aneurysms and subarachnoid hemorrhage*. Thomas, Springfield, IL, p 7
 41. Valpalhti PM, Schugk P, Tarkkanen L, Bjorkesten G (1969) Intracranial arterial aneurysm in a three-month-old infant: Case report. *J Neurosurg* 30:169–171
 42. Ventruyreya ECG, Cho SH, Beniot BC (1980) Supergiant globoid intracranial aneurysm in infant. Case report. *J Neurosurg* 53:411–416
 43. Vincent FM, Zimmerman JE (1980) Superior cerebellar artery aneurysm presenting as an oculomotor nerve palsy in a child. *Neurosurgery* 6:661–664
 44. Weir B, Macdonald RL (1996) Aneurysms and subarachnoid hemorrhage. In: Wilkins RH, Rengachary SS (eds) *Neurosurgery*. McGraw-Hill, New York, pp 2191–2213
 45. Whitfield PC, Bullock R (1991) Infected intracranial aneurysm in an infant: case report. *Neurosurgery* 28:623–625