

Case report

Right thalamic hemorrhage resulting from high-voltage electrical injury: a case report

Hüseyin Çaksen^{a,*}, Sevil Ari Yuca^a, Ismail Demirtas^b, Dursun Odabas^a,
Yasar Cesur^a, Ahmet Demirok^c

^aDepartment of Pediatric Neurology, Yüzüncü Yil University Medical School, Van, Turkey

^bDepartment of Pediatric Surgery, Yüzüncü Yil University Medical School, Van, Turkey

^cDepartment of Ophthalmology, Yüzüncü Yil University Medical School, Van, Turkey

Received 21 February 2002; received in revised form 20 March 2003; accepted 28 April 2003

Abstract

A 12-year-old boy was admitted with electrical burn and loss of consciousness. On physical examination his general condition was poor. Extensive burn areas, second and third degree, were present on his face, scalp, bilateral auricles, right cervical region, shoulders, right axilla, upper region of the thorax, and proximal region of the upper extremities. The total burned surface area was about 25%. Pupils were isocoric, but response to light was bilateral poor. He was stuporous and responsive only to pain. Deep tendon reflexes were exaggerated and plantar responses were bilateral extensor. Bilateral decorticate rigidity was noted. Computerized tomography of brain revealed brain edema and right thalamic hemorrhage. Magnetic resonance imaging of brain, examined 25 days after admission, revealed right thalamic hemorrhage and mild right subdural effusion. He was discharged from hospital 40 days after admission. However, spastic quadriplegia and severe mental retardation remained as sequela. On the 4th month of follow-up, no improvement was noted in his neurological examination. On the 9th month of follow-up, his clinical condition was better, but bilateral electric cataract was diagnosed. Both eyes were operated on and intraocular lenses were implanted with good results. Now he is 16th month of follow-up: neurological examination revealed only mild hemiparesis on the left side and mild articulation disorder. His school performance was moderate and intelligence quotient was 71. Magnetic resonance imaging of brain showed markedly improvement of the hemorrhage. To our best knowledge thalamic hemorrhage resulting from high-voltage electrical injury has not previously been reported in the literature.

© 2003 Elsevier B.V. All rights reserved.

Keywords: Electrical injury; Burn; Thalamic hemorrhage; Cataract

1. Introduction

Electrical burns account for a small portion of all thermal injuries. High-voltage injuries cause localized entrance and exit burns, extensive arc, flame and flash burns and, even more dangerous, necrosis of the underlying muscles on the pathway of the current through the body [1,2]. Patients surviving high-voltage electrical injury may have early and delayed sequelae. The most apparent neurological complications are known to be cerebral injury, spinal cord lesions, peripheral-nerve injuries and motor neuropathies [3].

In this article we report a case of right thalamic hemorrhage resulting from high-voltage electrical injury because of unusual presentation and to emphasize upon the importance of electrical injury management.

2. Case report

A 12-year-old boy was admitted with electrical burn and loss of consciousness. He climbed an electric pole to receive a bird, and accidentally touched the high-tension electric wire (> 1,000 V), and later he fallen from the pole. He was found in a condition of loss of consciousness by the parents.

On physical examination the temperature was 37 °C, with a respiratory rate of 48/min, a pulse rate of 136/min and blood pressure of 140/100 mmHg. Extensive burn areas,

* Corresponding author. K. Karabekir C. Gölbaşı 3. S., Erkam sitesi. B Blok. No: 3/7, Van, Turkey. Tel.: +90-432-217-6128; fax: +90-432-215-0479.

E-mail address: huseyincaksen@hotmail.com (H. Çaksen).

second and third degree, were present on his face, scalp, bilateral auricles, right cervical region, shoulders, right axilla, upper region of the thorax, and proximal region of the upper extremities. The total burned surface area was about 25%. Pupils were isocoric, but response to light was bilateral poor. He was stuporous and responsive only to pain. Deep tendon reflexes were exaggerated and plantar responses were bilateral extensor. Bilateral decorticate rigidity was noted.

Complete blood count, renal and liver function tests and blood gas analysis were normal. Serum creatine kinase was 200 U/L. (N: 5–130 U/L). No microorganism was isolated from blood culture, but *Acinetobacter bowmani* was isolated from urine culture. On admission, computerized tomography (CT) of brain revealed severe brain edema and mild right thalamic hemorrhage. Two days later CT was reexamined and showed mild brain edema and right thalamic hemorrhage (Fig. 1). Eight days after admission markedly improvement was noted on brain edema. Magnetic resonance imaging (MRI) of brain, examined 25 days after admission, revealed right thalamic hemorrhage and mild right subdural effusion (Fig. 2).

The patient was hospitalized. Besides supportive care, mannitol, dexametazone, prophylactic systemic antibiotherapy, and topical therapy were initiated. Because of hematemesis that occurred on the first day of admission, ranitidine was initiated and gastric decompression was performed. Passive movements were also applied to prevent joint contractures. Cardiac abnormality was not recorded during his follow-up. On the 8th day of admission, mannitol and dexametazone were stopped because brain edema was improved. Ten days after admission, his general condition was found to be better and feeding by nasogastric tube was initiated. On that period he began to sound incomprehensible and utter meaningless words to verbal stimuli. On the 20th

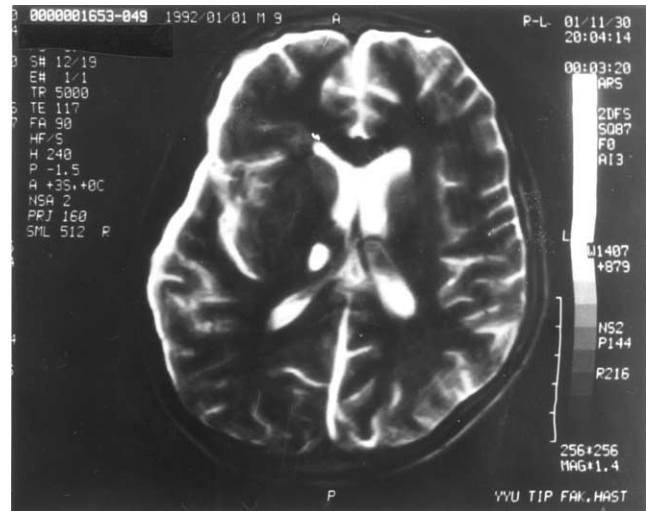


Fig. 2. Axial T2-weighted MRI of the brain shows hyperintensity in the right thalamus and mild subdural effusion.

day of admission, oral feeding was initiated. He was discharged from the hospital with good skin lesions 40 days after admission. However, he had spastic quadriplegia and severe mental retardation. On the 4th month of follow-up, no improvement was noted in his neurological examination, but later his quadriplegia gradually improved with comprehensive rehabilitation program and he can begin to walk without support on the 7th month of follow-up. On the 9th month of follow-up, bilateral electric cataract was diagnosed. Both the eyes were operated on and intraocular lenses were implanted with good results. Now he is 16th month of follow-up: neurological examination revealed only mild hemiparesis on the left side and mild articulation disorder. His school performance was moderate and intelligence quotient was 71. MRI of brain showed markedly improvement of right thalamic hemorrhage (Fig. 3).

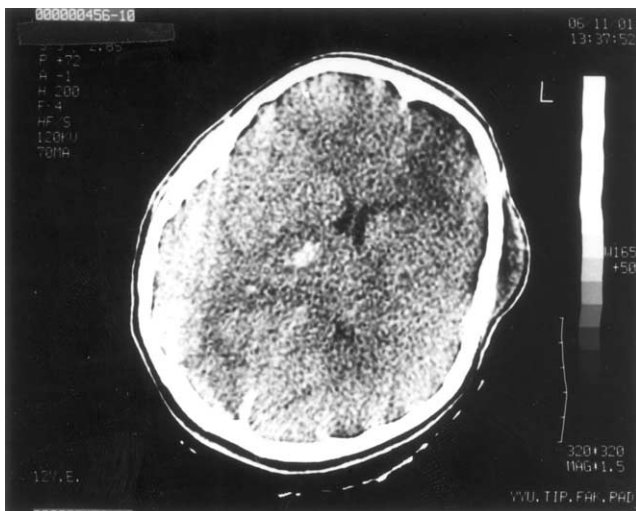


Fig. 1. Computerized tomography of the brain shows mild brain edema and right thalamic hemorrhage.

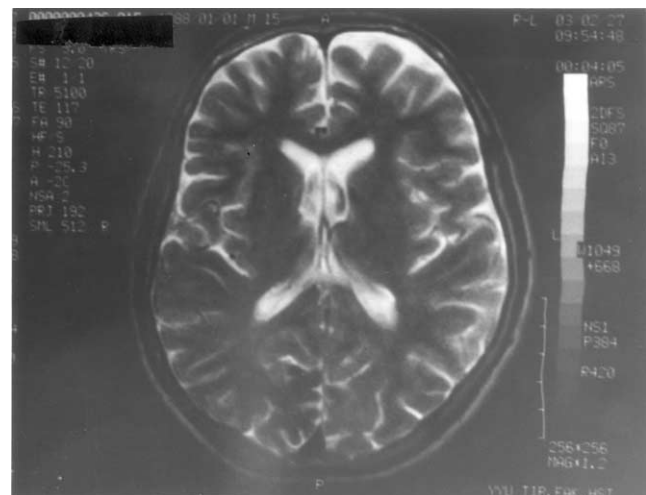


Fig. 3. During long-term follow-up, axial T2-weighted MRI of the brain shows small hypointensity in the right thalamus.

3. Discussion

High-tension electrical wire burns have a mortality of 3–15% for children who arrive at the hospital. Survivors have a high rate of morbidity, including major limb amputations. Damage to abdominal viscera, thoracic structures, and the nervous system in areas remote from obvious extremity injury occurs and must be sought, particularly in multiple current pathway injury or injury in which the victim falls from a high pole[4]. Hulsbergen-Kruger et al. [2] reviewed the findings of 43 patients with high-voltage injuries and found 36 of them in primary care. Six (16.6%) of the primary care patients died. Thirty per cent of the patients had neurological complications such as peripheral paresis, tetraplegia, and paraplegia, 20.7% of these caused solely by the electric current[2]. However, full neurological recovery after intracranial hemorrhage due to a direct lightning stroke, and near complete recovery after paraplegia following electrical injury have been recorded in the literature[5,6]. Clinical condition of our patient was severe during hospitalization, but near complete recovery was recorded on the 16th month of follow-up. Diagnosed and successfully treated cataract was due to high-voltage electrical injury, because it is well known that bilateral cataract may develop after electric injury[7].

Chen et al. [1] noted that eight of 249 burned patients sustained electrical burns associated with head injuries. CT scans of the brain revealed that six patients with moderate to severe head injuries had intracranial hemorrhage including three cases of intracerebral hematoma and another three cases of epidural hematoma[1]. Similar to our patient a case of tetraplegia caused by high-tension electric current has been reported in the literature[8]. Basal ganglia hemorrhages have also been described after a lightning strike to the head[9,10]. Review of the literature shows basal ganglia hemorrhage to be the most common brain imaging finding that can be attributed to a lightning strike. Several mechanistic theories are discussed, with the most plausible

one being related to preferential conduction pathways through the brain[9]. In our patient we diagnosed right thalamic hemorrhage, which has not previously been reported in the literature to our best knowledge. We think that the mechanism of pathophysiology may be related to either vascular or conduction pathways through the brain rather than direct damage due to head trauma.

In conclusion, our patient showed that unilateral thalamic hemorrhage, and bilateral electric cataract might be observed after electrical injury, and despite the severity of initial clinical condition near complete recovery might be seen in these children during long-term follow-up.

References

- [1] Chen CT, Yang JY. Electrical burns associated with head injuries. *J Trauma* 1994;37:195–9.
- [2] Hulsbergen-Kruger S, Pitzler D, Partecke BD. High voltage accidents, characteristics and treatment (in German). *Unfallchirurg* 1995;98: 218–23.
- [3] Deveci M, Bozkurt M, Sengezer M. Clonus: an unusual delayed neurological complication in electrical burn injury. *Burns* 2001;27: 647–51.
- [4] Antoon AY, Donovan MK. Burn injuries. In: Behrman RE, Kliegman RM, Jenson HB, editors. *Textbook of pediatrics*, 16th ed. Philadelphia, PA: WB Saunders; 2000. p. 287–94.
- [5] Thomas M, Pillai M, Krishna Das KV. Intracranial haematoma resulting from lightning stroke. *J Assoc Physicians India* 1991;39: 421–2.
- [6] Kanitkar S, Roberts AH. Paraplegia in an electrical burn: a case report. *Burns Incl Therm Inj* 1988;14:49–50.
- [7] Chaudhuri Z, Pandey PK, Bhatia A. Electrical cataract: a case study. *Ophthalmic Surg Lasers* 2002;33:166–8.
- [8] Benito-Ruiz J, Baena-Montilla P, Navarro-Monzonis A, Bonanad E, Cavadas P. Severe electric burn of the skull. *Burns* 1994;20:553–6.
- [9] Ozgun B, Castillo M. Basal ganglia hemorrhage related to lightning strike. *Am J Neuroradiol* 1995;16:1370–1.
- [10] Stanley LD, Suss RA. Intracerebral hematoma secondary to lightning stroke: case report and review of the literature. *Neurosurgery* 1985;16: 686–8.