

S. O. Casey
A. McKinney
M. Teksam
H. Liu
C. L. Truwit

CT perfusion imaging in the management of posterior reversible encephalopathy

Received: 5 January 2003
Accepted: 22 April 2003
Published online: 26 March 2004
© Springer-Verlag 2004

S. O. Casey (✉) · A. McKinney
M. Teksam · H. Liu · C. L. Truwit
Department of Radiology,
University of Minnesota Medical School,
420 Delaware Street SE, Box 292
Minneapolis, MN 55455, USA
E-mail: Casey021@tc.umn.edu
Tel.: +1-612-2736031
Fax: +1-612-6248495

Abstract A 13-year-old girl with a renal transplant presented with hypertension and seizures. CT and MRI demonstrated typical bilateral parietal, occipital and posterior frontal cortical and subcortical edema, thought to represent posterior reversible encephalopathy syndrome. The cause was presumed to be hypertension. Antihypertensive therapy was started, lowering of the blood pressure in the range of 110–120 mmHg systolic. However, stable xenon (Xe) CT perfusion imaging revealed ischemia within the left parietal occipital region. The antihypertensive was adjusted which increased both the systolic and diastolic blood pressure by 31 mm Hg. The patient was re-imaged with Xe CT and was found to have resolution of the ischemic changes within the left parietal occipital region. In this report, we present a case in which stable Xe CT was used

to monitor the degree of cerebral perfusion and guide titration of antihypertensive therapy. Such brain perfusion monitoring may have helped to prevent infarction of our patient.

Keywords Xenon CT · Posterior reversible encephalopathy · Brain perfusion

Introduction

Posterior reversible encephalopathy has been proposed to denote a diverse group of conditions with similar clinical and imaging features, with systemic hypertension and bilateral posterior cerebral edema [1]. Posterior reversible encephalopathy is most commonly associated with hypertensive encephalopathy, eclampsia, and cyclosporin-A neurotoxicity. Although the lesions on imaging are typically reversible with treatment, some patients have complications of infarction, predominantly

within the posterior border zones of the cerebral hemispheres [2, 3]. The pathophysiology of these disorders has been debated, but most workers believe it is a disorder of cerebral autoregulation [4, 5, 6, 7, 8]. The underlying abnormality is thought to be hyperperfusion, leading to reversible edema, usually without infarction [5, 6, 9, 10, 11]. Most patients are markedly hypertensive on presentation and therapy is typically directed at lowering systemic blood pressure. It has been empirical, without direct monitoring of its effects on cerebral perfusion. However, in autoregulatory disturbances, overly rapid

correction of blood pressure may lead to hypoperfusion and ischemia of the posterior border zones. We used perfusion CT with stable Xenon (Xe CT) to monitoring cerebral perfusion during antihypertensive therapy in a patient with posterior reversible encephalopathy.

Case report

A 13-year-old girl presented with generalized tonic/clonic seizures. She patient had chronic renal failure and had undergone a renal transplant 3 months earlier, but had not complied with antihypertensive medication. She had been treated with cyclosporin-A but this had been changed to oral steroids 2 weeks prior to presentation. She had a headache 2 days prior to presentation and, on the day of presentation, had three generalized tonic/clonic between 3:45 and 4:15 am). In the emergency department, her blood pressure was 205/134 mm Hg. Laboratory tests were unrevealing, except for serum creatinine, 7.2 mg/dl. The patient was postictal, with a decreased level of consciousness, disoriented (but rousable) and weak, although able to move her limbs. Antihypertensive therapy was commenced immediately, in the form of intravenous nitroprusside, initially at 0.5 mcg/kg/h. The patient underwent CT at 4:30 am (Fig. 1A), which revealed subtle bilateral subcortical low density in both parietal lobes. This was interpreted as edema, and in the setting of severe hypertension, a presumptive diagnosis of posterior reversible encephalopathy was made.

Over the next 4 h, the nitroprusside infusion was incrementally increased to 0.75 mcg/kg/h; the blood pressure at 8.30 am was 163/104 mm Hg. Over this period, the patient developed flaccidity of the right limbs, with a pronator drift, but still rousable to voice. The clinicians continued to decrease the blood pressure with a diastolic goal of 80–90 mm Hg. Over the next 4 h the nitroprusside infusion was titrated up to 1.75 mcg/kg/h, ter blood pressure at 12.30 pm being 117/67 mm Hg, and consulted with the neuroradiologists about the onset of a right hemiplegia while the patient was receiving increasing nitroprusside.

At 1.00 pm she underwent Xe perfusion CT on a scanner in which an independent system for stable Xe gas delivery (27% Xe/73% O₂ mixture) and calculation of cerebral blood flow (CBF). Perfusion images 1 cm thick were obtained at four levels. The initial Xe CT, performed at a blood pressure of 119/67 mm Hg, revealed evidence of ischemia in the left (CBF 12.2 cc/100 g/min) and oligemic perfusion in the right parietal-occipital borderzone (Fig. 1B). The blood pressure was then raised by slowing the nitroprusside infusion from 1.75 to 0.81 mcg/kg/hr over 30 min until it reached 150/96 mm Hg at 1:30 pm.

Xe CT then demonstrated significant improvement in perfusion in the left parieto-occipital region (27.8 cc/100 g/min) and normal values in the right (Fig. 1C). The patient underwent MRI at 2.15 pm, confirming edema in the cortex and subcortical white matter of the parietal, occipital, posterior frontal and posterior temporal lobes, as typically encountered in posterior reversible encephalopathy (Fig. 1D). There was also mild edema in both cerebellar hemispheres. Diffusion-weighted imaging and single voxel MR proton spectroscopy (of the left parietal-occipital signal abnormality) revealed no definite abnormality. Dynamic susceptibility perfusion imaging with echoplanar MRI and a rapid bolus of IV contrast medium revealed minimal cortical reduction of CBF and cerebral blood volume with a mildly increased mean transit time in the left parieto-occipital region, confirming that cerebral perfusion was now only minimally reduced.

The patient's left side was still flaccidity at 3.00 pm. The nitroprusside infusion was titrated slowly down to 0.5 mcg/kg/h by 9 pm, when the blood pressure was 158/97 mm Hg. The right hemiplegia had improved (there was no longer a pronator drift),

and the patient was awake but drowsy, with improved orientation to self and place. The nitroprusside was given at the same rate overnight, and at 8 am the next morning, when the blood pressure was 148/92 mm HG, the patient had a mild residual pronator drift, and still complained of headache. Over the next 24 h, her blood pressure was controlled at just above 150 mm Hg systolic and afterwards slowly reduced. The nitroprusside infusion was discontinued on the afternoon of the second hospital day and IV hydralazine was commenced. The hemiplegia and headaches completely resolved over the next 3 days, and the patient was discharged on day 7. She patient returned for MRI 3 months later, which showed total resolution of all brain lesions, with no evidence of infarcts (Fig. 1E).

Discussion

Posterior reversible encephalopathy is typically heralded by headache and altered mental functions, often with seizures and visual symptoms. Diagnosis is made based on symptoms and signs, typical imaging findings and, usually, identification of a risk factor. Our patient had several risk factors, including hypertension, seizures, steroid use and renal insufficiency. In more severe cases, the typical bilateral subcortical and cortical edema can spread to the posterior frontal and temporal lobes, corona radiata, pons, cerebellum and other sites. There has been disagreement over the name reversible posterior leukoencephalopathy, since the condition involves both gray and white matter, occasionally exclusively gray matter [12, 13, 14]. We thus prefer the newer term, posterior reversible encephalopathy.

The pathophysiology of hypertensive encephalopathy and posterior reversible encephalopathy has been studied extensively. The favored pathophysiologic theory suggests autoregulatory disturbance with hyperperfusion, resulting in blood-brain barrier disruption and reversible edema, usually without infarction [5, 6, 7, 9]. Since the brain attempts to maintain a constant blood flow by autoregulation, when systemic blood pressure rises subacutely, the brain's arterioles constrict to create compensatory resistance, to avoid hyperperfusion [7, 15, 16]. Animal studies show an upper limit to cerebral autoregulation, termed a "breakthrough" point, past which constricted arterioles are forced to dilate in response to the increasing blood pressure [8]. Past this breakthrough point, perfusion pressure is sufficient to overcome the blood-brain barrier, allowing extravasation of fluid (and even macromolecules and red blood cells) into the brain parenchyma [8, 17]. Pathologic studies in animals and humans typically show little or no evidence of infarction, revealing only fibrinoid necrosis within the walls of the arterioles, interstitial edema and petechial microhemorrhage [3, 18, 19].

It is not known why the posterior circulation is preferentially affected. However, perivascular sympathetic nerves protect the brain from marked increases in intravascular pressure in the setting of extreme

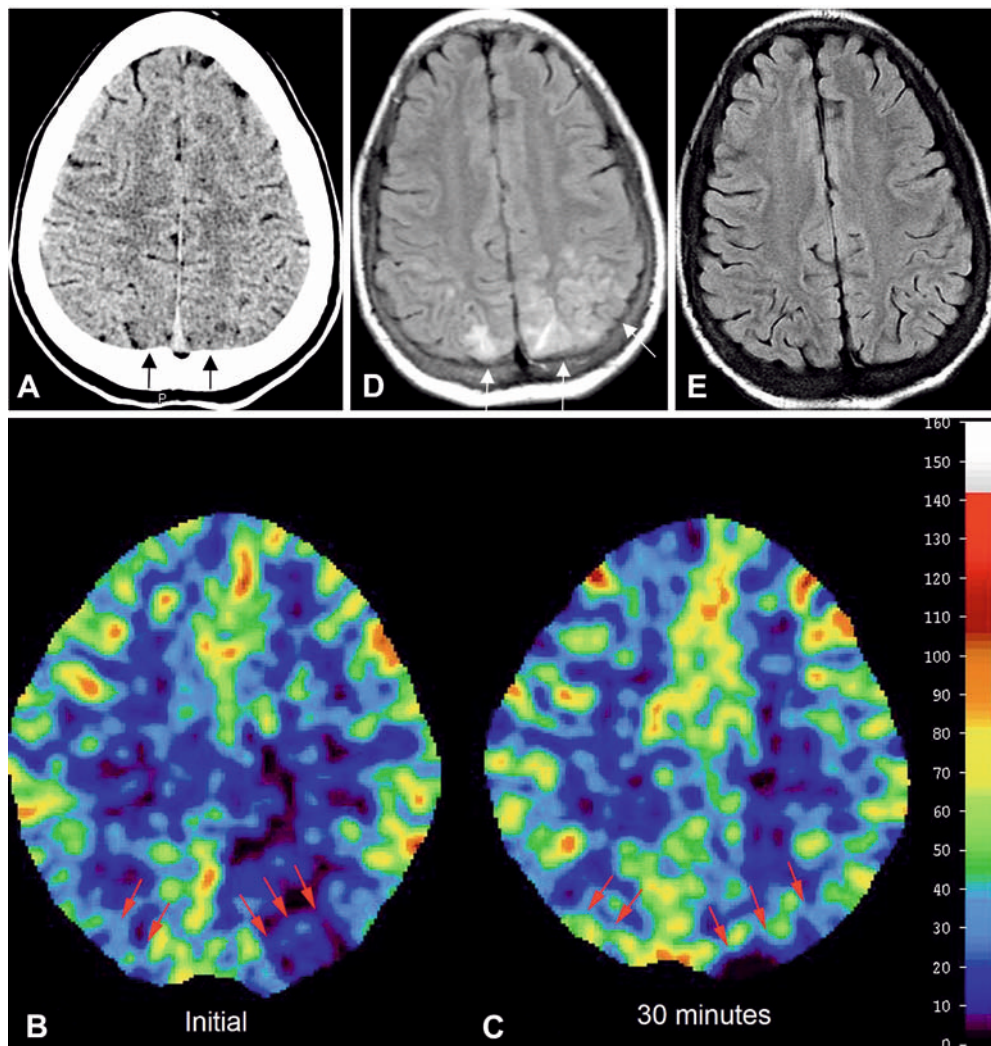


Fig 1A–E A 13-year-old girl with headache, seizures and blood pressure 205/134 mm Hg. **A** CT reveals possible low density bilaterally in the parietal-occipital cortex, left more than right. There is also subtle obscuration of the gray-white matter distinction (*black arrows*). These findings suggest posterior reversible encephalopathy due to hypertension. **B** Stable Xe CT perfusion examination. Baseline study, following institution of IV nitroprusside antihypertensive therapy, with a lower systemic blood pressure, reveals bilateral posterior borderzone hypoperfusion, more on the left. Region of interest (ROI) measurements are 12.2 cc/100 g brain/min from the area of lowest cortical perfusion on the left (*red arrows*) and 25.8 cc/100 g/min on the right. **C** Xe CT at the same level, 30–45 min later, following slowing of nitroprusside administration, with blood pressure 150/96 mm Hg, reveals improved perfusion in the posterior border zones (*red arrows*): 27.8 cc/100 g/min on the left and 81.0 cc/100 g/min on the right. **D** Fluid-attenuated inversion-recovery (FLAIR) image immediately after Xe CT, confirms bilateral parietal cortical and less marked subcortical edema (*white arrows*), typical of hypertensive and posterior reversible encephalopathy. **E** FLAIR image 3 months later shows resolution of the vasogenic edema and no evidence of ischemic brain injury

hypertension [8, 20]. The vertebrobasilar system possesses relatively less sympathetic innervation than the anterior circulation [21]. In the event of excessive prolonged hypertension (which has been reported to be triggered by cyclosporine), perfusion increases past the breakthrough point in the posterior temporal, posterior parietal, occipital lobes, and posterior cranial fossa structures [21, 22, 23, 24].

Although typically reversible, posterior reversible encephalopathy can be complicated by ischemia, with or without vasospasm, and infarcts, typically in a posterior borderzone distribution between the middle and posterior cerebral arteries. This ischemic mechanism is less well understood, but may be related to an autoregulatory disturbance resulting from aggressive antihypertensive therapy. It has been suggested that, in the setting of subacute hypertension, the upper limit of cerebral autoregulation is shifted towards higher

pressures, presumably as a protective measure to prevent excessive blood flow [25, 26, 27]. We postulate that if the blood pressure is lowered too rapidly during treatment in the setting of autoregulatory disturbance, it may no longer maintain the caliber of the constricted arteries, which may result in vasospasm and paradoxical hypoperfusion (as we presume to have occurred in our patient). Ischemia can even occur at relatively normal blood pressures, because with subacute hypertension, the lower limit of cerebral autoregulation gets shifted upwards and takes time to adjust back down to normal levels. There have been reports of death from too rapid reduction of severe hypertension, with borderzone infarcts due to hypoperfusion on autopsy, despite no clinical evidence of systemic hypotension [2, 28]. In the absence of treatment, hypoperfusion and ischemia probably also eventually occur due to severe edema and severely increased intracranial pressure approaching or exceeding the brain perfusion pressure.

Perfusion CT with stable Xe is a quantitative measure of cerebral perfusion [29]. Repeated Xe CT studies, with interval blood pressure manipulation by adjustment of IV pressor delivery rates, have been used for investiga-

tion of cerebral vasospasm following subarachnoid hemorrhage [30]. In our patient, the initial Xe study demonstrated posterior borderzone hypoperfusion with left parietal-occipital perfusion values in the ischemic range. There was relative normalization of perfusion on the second CT, following upward adjustment of the blood pressure, but well below the presenting level. This suggests that the blood pressure may have been below the lower limits of autoregulation. Alternatively, the reduced blood pressure may have been inadequate for perfusion of the edematous parieto-occipital regions. Although seizure-induced brain edema is in the differential diagnosis for the brain changes, these have been reported to give high signal on diffusion-weighted imaging and to show postictal regional hyperperfusion [31]. Our patient did not show these characteristics. Regardless of the exact pathophysiology of the hypoperfusion, we believe that close monitoring of cerebral perfusion with Xe CT and subsequent adjustment of therapy based on the findings decreased the risk of infarcts in the early stages of treatment of the hypertensive encephalopathy.

References

- Hinchey J, Chaves C, Appignani B, et al (1996) A reversible posterior leukoencephalopathy syndrome. *N Engl J Med* 334: 494–500
- Haas DC, Anderson GH, Streeten DPH (1985) Role of angiotensin in lethal cerebral hypoperfusion during treatment of acute hypertension. *Arch Intern Med* 145: 1922–1924
- Ay H, Buonanno FS, Schaefer PW, et al (1998) Posterior leukoencephalopathy without severe hypertension: utility of diffusion-weighted MRI. *Neurology* 51: 1369–1376
- Byrom F (1954) The pathogenesis of hypertensive encephalopathy and its relation to the malignant phase of hypertension. *Lancet* 2: 201–211
- Johansson B (1974) Regional cerebral blood flow in acute experimental hypertension. *Acta Neurol Scand* 50: 366–372
- Haggendal E, Johansson B (1972) On the pathophysiology of the increased cerebrovascular permeability in acute arterial hypertension in cats. *Acta Neurol Scand* 48: 265–270
- Auer L (1978) The sausage-string phenomenon in acutely induced hypertension—arguments against the vasospasm theory in the pathogenesis of acute hypertensive encephalopathy. *Eur Neurol* 17: 166–173
- Mackenzie ET, Strandgaard S, Graham DI, Jones JV, Harper AM, Farrar JK (1976) Effects of acutely induced hypertension in cats on pial arteriolar caliber, local cerebral flow, and the blood-brain barrier. *Circ Res* 39: 33–41
- Ekstrom-Jodal B, Haggendal E, Linder LE, Nillson NJ (1971) Cerebral blood flow autoregulation at high arterial pressures and different levels of carbon dioxide tension in dogs. *Eur Neurol* 6: 6–10
- Tamaki K, Sadoshima S, Baumbach GL, Iadecola C, Reis DJ, Heistad DD (1984) Evidence that disruption of the blood-brain barrier precedes reduction in cerebral blood flow in hypertensive encephalopathy. *Hypertension* 6: 175–181
- Johansson B (1974) The blood brain barrier and cerebral blood flow in acute hypertension. *Acta Neurol Scand* 50: 366–372
- Schwartz RB (1996) A reversible posterior leukoencephalopathy syndrome. *N Engl J Med* 334: 1743
- Dillon WP, Rowley H (1998) The reversible posterior cerebral edema syndrome. *AJNR* 19: 591
- Casey SO, Sampaio RC, Michel E, Truwit CL (2000) Posterior reversible encephalopathy syndrome: utility of fluid-attenuated inversion recovery MR imaging in the detection of cortical and subcortical lesions. *AJNR* 21: 1199–206
- Standgaard S, Paulson O (1984) Cerebral autoregulation. *Stroke* 15: 413–416
- Paulson OB, Strandgaard S, Edvinsson L (1990) Cerebral autoregulation. *Cerebrovasc Brain Metab Rev* 2: 161–192
- Ijima T, Kubota Y, Kuroiwa T, Sankawa H (1994) Blood-brain barrier opening following transient reflex sympathetic hypertension. *Acta Neurochir [Suppl]* 60: 142–144
- Lanzino G, Cloft H, Hemstreet MK, West K, Alston S, Ishitani M (1997) Reversible posterior leukoencephalopathy following organ transplantation. Description of two cases. *Clin Neurol Neurosurg* 99: 222–226
- Pavlikis SG, Frank Y, Kalina P, Chandra M, Lu D (1997) Occipital-parietal encephalopathy: a new name for an old syndrome. *Pediatr Neurol* 16: 145–148

20. Beausang-Linder M, Bill A (1981) Cerebral circulation in acute arterial hypertension—protective effects of sympathetic nervous activity. *Acta Physiol Scand* 111: 193–199
21. Edvinsson L, Owman C, Sjöberg NO (1976) Autonomic nerves, mast cells, and amine receptors in human brain vessels: histochemical and pharmacologic study. *Brain Res* 115: 377–393
22. Scherrer U, Vissing SF, Morgan BJ, et al (1990) Cyclosporin-induced sympathetic activation and hypertension after heart transplantation. *N Engl J Med* 693–699
23. Mark AL (1990) Cyclosporine, sympathetic activity, and hypertension. *N Engl J Med* 323: 748–750
24. Schwartz RB, Bravo SM, Klufas RA, et al (1995) Cyclosporine neurotoxicity and its relationship to hypertensive encephalopathy: CT and MR findings in 16 cases. *Am J Roentgenol* 165: 627–631
25. Yanagisawa M, Kurihara H, Kimura S, et al (1988) A novel potent vasoconstrictor peptide produced by vascular endothelial cells. *Nature* 332: 411–415
26. Lerman A, Hildebrand FL Jr, Margulies KB, et al (1990) Endothelin: a new cardiovascular regulatory peptide. *Mayo Clin Proc* 65: 1441–1445
27. Lee RM, Owens GK, Scott-Burden T, Head RJ, Mulvany MJ, Schiffrin EL (1995) Pathophysiology of smooth muscle in hypertension. *Can J Physiol Pharmacol* 73: 574–584
28. Haas DC, Streeten DHP, Kim, RC, Naalbandian AN, Obeid AI (1983) Death from cerebral hypoperfusion during nitroprusside treatment of acute angiotensin-dependent hypertension. *Am J Med* 75: 1071–1076
29. Hughes RL, Yonas H, Gur D, Latchaw R (1989) Cerebral blood flow determination with the first 8 hours of cerebral infarction using stable xenon-enhanced computed tomography. *Stroke* 20: 754–760
30. Darby JM, Yonas H, Marks EC, Durham S, Snyder RW, Nemoto EM (1994) Acute cerebral blood flow response to dopamine-induced hypertension after subarachnoid hemorrhage. *J Neurosurg* 80: 857–864
31. Kassem-Moussa H, Provenzale JM, Petrella JR, Lewis DV (1994) Early diffusion-weighted MR imaging abnormalities in sustained seizure activity. *Am J Roentgenol* 174: 1304–1306