

CASE REPORT

Non-ketotic hyperglycaemia presenting as epilepsia partialis continua

ÖZLEM ÇOKAR, BETÜL AYDIN & FERİHA ÖZER

Department of Neurology, Haseki Research and Educational Hospital, Istanbul, Turkey

Correspondence to: Dr Özlem Çokar, M.D., Ataköy 3, Kısım O Blok 56, Daire: 8, Istanbul, Turkey.
E-mails: ozlemcokar@hotmail.com, ffozer@yahoo.com

Epilepsia partialis continua (EPC) is a rare epileptic syndrome, observed in various cortical lesions and also in metabolic disorders. We report the case of a 57-year-old patient with EPC as the first manifestation of hyperosmolar non-ketotic hyperglycaemia (NKH) of diabetes mellitus. Computed tomography (CT) and magnetic resonance imaging (MRI) were normal. Initial laboratory data revealing serum glucose 1540 mg/dl, and serum osmolality 391 mOsm/l confirmed the diagnosis. Electroencephalography (EEG) showed ictal discharges in the ipsilateral hemisphere during focal seizures. Seizures are resistant to anticonvulsant treatment and respond best to insulin and rehydration. Focal motor seizures or EPC are commonly a symptom of NKH in the elderly patients. We recommend that in such cases a metabolic disorder such as diabetes mellitus be ruled out.

© 2003 BEA Trading Ltd. Published by Elsevier Ltd. All rights reserved.

Key words: epilepsia partialis continua; non-ketotic hyperglycaemia; electroencephalography.

Epilepsia partialis continua (EPC) is characterised by simple partial motor seizures, restricted to one part of the body with repetitive regular or irregular clonic jerks without loss of consciousness. Clonic activity persists for a period of days or weeks either continuously or with only brief interruptions and remains localised to a single muscle group in most patients or even may progress to secondarily generalised convulsive status. EPC can result from a static insult of known cause with a non-progressive course including stroke, tumour, abscess, cortical dysplasia, and head trauma¹. The second condition characterised by progressive mental and motor deterioration with an unknown cause is usually in the form of Rasmussen encephalitis. EPC may develop also in metabolic disorders such as uremic or hepatic encephalopathy and non-ketotic hyperglycaemia (NKH)^{1,2}.

EPC is a rare condition and here we aim to describe the clinical and electroencephalographic characteristics of one patient who presented with EPC as the first clinical manifestation of diabetes mellitus.

CASE REPORT

A 57-year-old, previously neurologically normal, obese man admitted for his repetitive right-sided partial motor seizures affecting his face and limbs. Ictal events consisting of clonic jerks of the right arm that had begun suddenly 10 days earlier, increased in frequency and occurred every 5 minutes with progressive involvement of the right side of the face and leg. A left hemisphere lesion was suspected and brain computed tomography (CT) and magnetic resonance imaging (MRI) studies were performed 10 days before his admission. Seizures continued despite treatment with carbamazepine and Na valproate. His history includes hypertension and depressive symptoms. There was no past history of diabetes mellitus but his three brothers suffered DM. On admission the patient was afebrile and mildly confused with some degree of agitation. Neurological examination showed right facial paresis of central type and right hemiparesia with decreased tone in the right upper extremity.

Episodes of seizures characterised by axial myoclonus followed by head and eye tonic turning to the right side associated more or less continuous clonic or myoclonic jerks on the right arm (distal muscles preferentially) and sometimes on the right leg. Intravenous diazepam resulted in drowsiness with no other change in his clinical state.

Electroencephalography (EEG) recording at admission consist of bilateral, pseudo-periodic spike and wave discharges of high voltage and <1 second duration, associated by myoclonic jerks. This discharges may be followed by high voltage, irregular, sharp and slow waves localised on the right temporal region (Fig. 1) with sometimes contralateral propagation (Fig. 2) correlated with the clonic jerks on the right arm.

Initial biochemical data on admission included serum glucose 1540 mg/dl (normal, 70–110 mg/dl) without ketonuria; serum sodium concentration, 150 mEq/l; serum potassium, 3.0 mEq/l; serum calcium, 9.2 mEq/l; serum blood urea nitrogen 99 mg/dl and calculated serum osmolality, 391 mOsm/l.

$$\text{Serum osmolality} = 2 \times \frac{[\text{sodium (mEq/l)} + \text{potassium (mEq/l)}] + \text{blood glucose (mg/dl)}}{18}$$

Both CT and MRI studies of head were normal. The following day EEG showed repetitive sharp waves either synchronous or asynchronous over the right and left temporal regions, on a mildly slow background activity (Fig. 3). After appropriate fluid replacement and correction of the metabolic disorder by insulin therapy both the seizures and agitation resolved. Neurological examination returned normal in 1 week. No further episodes of focal seizures occurred during 8 months of follow up and EEG became normal.

DISCUSSION

Several causes have been implicated in the genesis of EPC. In childhood, the most common cause is Rasmussen encephalitis. Cerebral tumour or vascular disease were the most frequent underlying processes for adult patients³. In a subject with EPC, focal brain lesions are considered at first plan but especially in elderly patients metabolic disorders should also be regarded. Focal epileptic seizures with or without further neurological symptoms may be induced by non-ketotic hyperosmolar diabetic comas accompanied by severe hyperglycaemia, hyperosmolality and dehydration with minimal or no ketoacidosis². Focal motor seizures and EPC are the most common type, although generalised tonic-clonic seizures also occur^{2–6}. Singh and Strobos reviewed 158 subjects with NKH who were reported in literature and reported focal seizures in 30 (19%) of them⁴. In their

own study same researchers reported 21 NKH subjects presenting with EPC⁴. Focal motor seizures and EPC may occur in up to 25% of patients with NKH⁵. Rarely, patients with NKH reported with partial motor seizures triggered by movement or posturing of a body part, defined as reflex seizures or posture-induced focal motor seizures^{6–8}.

NKH can be seen most commonly in elderly diabetics with mild disease or as a first clinical manifestation of DM. Focal seizures, particularly EPC may be the presenting feature of non-ketotic hyperosmolar coma and may also be the initial symptom of DM^{2, 4, 6}. In three of seven reported patients with hyperglycaemia and focal seizures, the seizure disorder was the first sign of DM⁶. In the study by Singh and Strobos, out of 21 cases presenting with EPC, 9 were diagnosed with DM for the first time⁴. In our subject with a positive family history for DM but without prior complaints of DM such as polydipsia and polyuria, EPC presents as the first clinical symptom of DM. We believe that hyperglycaemia observed in our subject possibly

resulted from excessive intake of food rich in carbohydrates in recent months. A retrospective review revealed that our subject had a mild dry mouth again in recent months but later this complaint has been attributed to use of antidepressive treatment. It is obvious that DM could easily be missed when symptoms are very mild or insignificant.

The pathogenesis of EPC in NKH is not completely understood. Several hypotheses regarding cause–result association of NKH and focal epilepsy seizures have been proposed. Despite focal seizures associated with NKH are resistant to antiepileptic drugs and respond best to insulin^{4, 6} and recur when blood glucose is not controlled⁶, the explanation of this condition by hyperglycaemia alone is unsatisfactory because seizures are rare in diabetic ketoacidosis⁹. It was hypothesised that hyperglycaemia led to a decrease in epileptic seizure threshold by increasing metabolism of gamma-aminobutyric acid accordingly decreasing the level of GABA, which is known to be an inhibitory neurotransmitter in the central nervous system⁶. Given that fewer or no seizures occur in diabetic ketoacidosis, an anti-convulsant effect of ketosis may be considered. It has been hypothesised that in this case, intracellular acidosis elevates GABA level by increasing activity of glutamic acid decarboxylase⁶. Another hypothesis involves decrease of seizure threshold due to metabolic disturbance. Hyperosmolality and dehydration induced by hyperglycaemia or hyponatremia

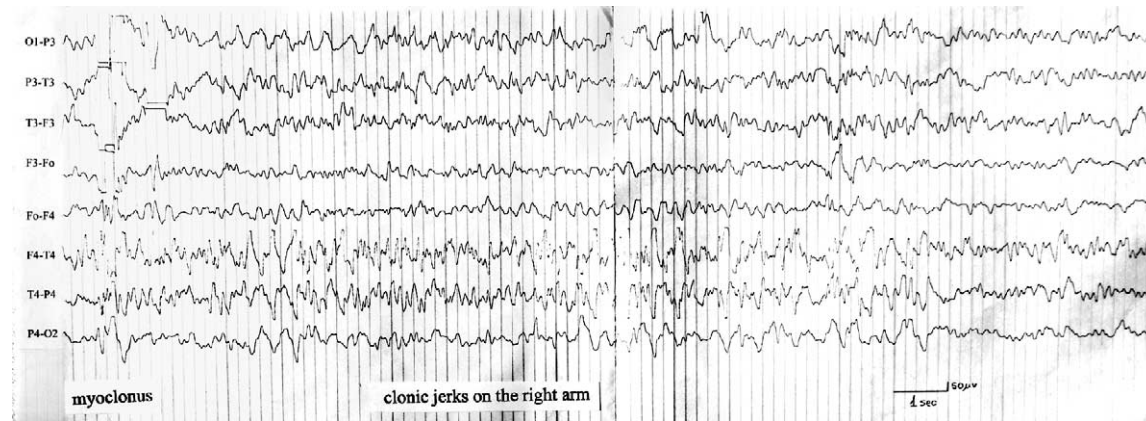


Fig. 1: Bilateral, pseudo-periodic spike and wave discharges of high voltage associated by myoclonic jerks, followed sometimes by high voltage, irregular, sharp and slow waves localised on the right temporal region correlated with the clonic jerks on the right arm.

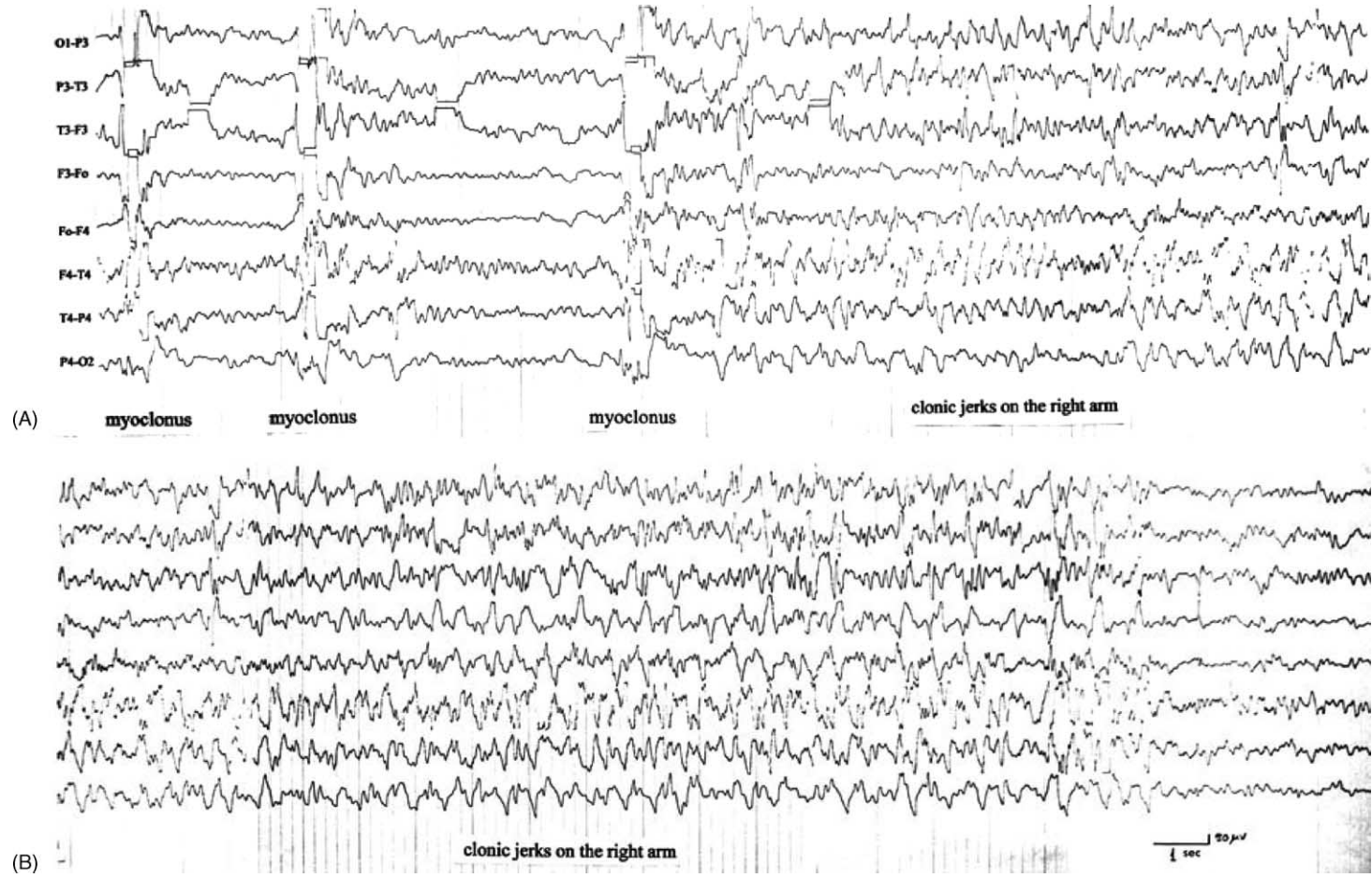


Fig. 2: (A and B) Ictal discharges more marked over the right hemisphere with contralateral propagation.

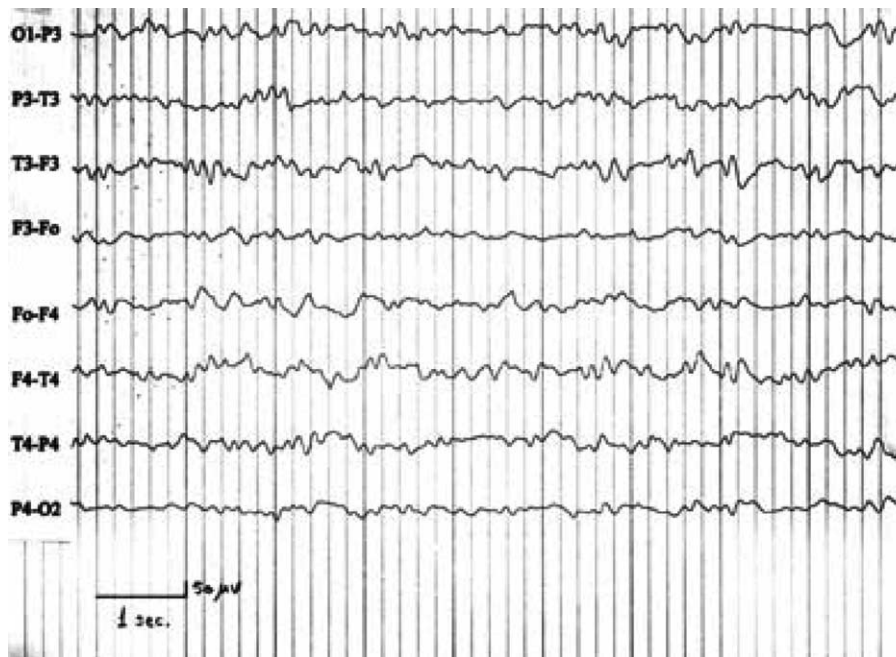


Fig. 3: Repetitive sharp waves either synchronous or asynchronous over the right and left temporal regions, on a mildly slow background activity.

accompanying hyperglycaemia were suggested to trigger EPC and focal seizures and lead to neurological deficit in some patients⁴. Other authors suggested that a previously existing cortical lesion of ischaemic nature might lead to these seizures after acquiring an epileptogenic characteristic under altered metabolic conditions. Nevertheless, some patients have been reported without evidence of brain damage⁴. Cranial imaging results of our patient during clinical symptoms were normal. Subsequent studies demonstrated that hyperglycaemia resulted in reversible focal ischaemia without structural damage by decreasing local blood flow in certain cerebral areas¹⁰.

EPC occur in any location but most often localised over the central and frontal regions, associated with low amplitude rapid spikes. In general, EEG has not been successful in determining the origin of EPC. At times no spike discharges may be visible on surface recordings and only focal slow wave abnormality or an asymmetry of activity may be present over the involved region. Various ictal EEG abnormalities have been reported in NKH seizures in the literature. While in some cases periodic lateralised epileptiform discharges correlated with clonic contractions are observed in EEG during seizures⁴, focal seizure discharge is recorded in frontal or temporal region in some⁴ and no paroxysmal activity is recorded in others⁸. In a study by Tedrus *et al.*, three cases with a history of diabetes mellitus and focal motor seizures triggered by movement of posture of an extremity have been reported. Two of them had NKH. During seizures

EEG showed focal seizure activity in parieto-occipital region in two cases and in mid-temporal region in another⁷.

Although occipital partial seizures have also been described, the clinical features of partial seizures in NKH are usually those of frontal lobe epilepsy. Patients with epileptic zones in the frontal lobe or mesial interhemispheric surfaces can pose lateralisation problems, with bifrontal or bitemporal spiking. In the series of Singh and Strobos, some of these focal discharges spread bilaterally with continuing focal preponderance. The clinical seizures were not always fully correlated with the EEG discharges. For example, discharges may stop when seizure is clinically ongoing or no temporal association between focal activity in EEG and seizure is observed⁴. In a study by Guerreiro *et al.*, three NKH cases presenting with focal motor seizures and EPC were reported. In one of these cases bilateral temporal spiky activity accompanying focal seizure was observed¹¹. Brick *et al.* reported a 65-year-old patient in NKH in whom passive or active elevation of right arm produced focal seizures manifested by right wrist clonus. Concurrent EEG recording showed bifrontal sharp waves on the EEG¹².

In our patient, focal seizures localised on the right arm were associated with the ictal activity over the right temporal region on the EEG. Only one previous case, that of Adelman *et al.* had a similar case presentation. In this study, they reported a patient with EPC involving the right leg who demonstrated sharp waves located over the vertex and right hemisphere. The

authors postulate that generators situated on the mesial surface of the left hemisphere projected their activity obliquely, leading to paradoxical lateralisation of the recorded electrical activity¹³.

Consciousness level and major neurological findings are known to be closely associated with elevated serum glucose and osmolality in cases with NKH^{2, 4}. In our case with elevated serum glucose (1540 mg/dl), sodium (150 mEq/l), blood urea nitrogen (99 mg/dl) and serum osmolality (391 mOsm/l), progressively increasing alterations in consciousness was observed and he presented to our clinic with confusion and right hemiparesia in addition to EPC. It is well recognised that an osmolality higher than 400 mOsm/l is associated with poor prognosis. However, possibility of complete resolution without any sequelae is substantially high with early diagnosis of NKH.

Knowing or considering that EPC may concurrently occur with NKH is very important for early diagnosis and institution of appropriate therapy in such condition resistant to antiepileptic drugs and also for avoiding unnecessary etiological workup. Early diagnosis is necessary also to decrease the morbidity associated with non-ketotic hyperglycaemic coma. Thus assessment of DM, especially in the elderly is of substantial importance in cases presenting with EPC regardless of its presence in medical history.

REFERENCES

1. Wasterlain, C. G. Epilepsia partialis continua. *Emedicine*. Last updated: March 6, 2002 (Medline).

2. Windebank, A. J. and McEvoy, K. M. Diabetes and the nervous system. In: *Neurology and General Medicine: The Neurological Aspect of Medical Disorders*, 2nd edn. (Ed. M. J. Aminoff). New York, Churchill Livingstone, 1995; pp. 349–381.
3. Schomer, D. Focal status epilepticus and epilepsy partialis continua in adults and children. *Epilepsia* 1993; **34** (Suppl. 1): S29–S36.
4. Singh, B. M. and Strobos, R. J. Epilepsia partialis continua associated with nonketotic hyperglycaemia: clinical and biochemical profile of 21 patients. *Annals of Neurology* 1980; **8**: 155–160.
5. Cochin, J. P., Hannequin, D., Delangre, T., Guegan-Massardier, E. and Augustin, P. Continuous partial epilepsy disclosing diabetes mellitus. *Revista de Neurologia (Paris)* 1994; **150** (3): 239–241.
6. Hennis, A., Corbin, D. and Fraser, H. Focal seizures and non-ketotic hyperglycaemia. *Journal of Neurology, Neurosurgery, and Psychiatry* 1992; **55**: 195–197.
7. Tedrus, G. M., Albertin, M. C., Odashima, N. S. and Fonseca, L. C. Partial motor seizures induced by movement in diabetic patients (abstract). *Arquivos de Neuro-psiquiatria* 1991; **49** (4): 442–446.
8. Suarez-Moro, R., Salas-Puig, J., Amorin, M., Roiz, C. and Lahoz, C. H. SPECT finding in reflex seizures induced by movement in non-ketotic hyperglycemia. *Epileptic Disorders* 1999; **1** (3): 199–201.
9. Placidi, F., Floris, R., Bozzao, A. *et al.* Ketotic hyperglycemia and epilepsy partialis continua. *Neurology* 2001; **57**: 534–537.
10. Duckrow, R. B., Beard, D. C. and Brennan, R. W. Regional cerebral blood flow decreases during hyperglycaemia. *Annals of Neurology* 1985; **17**: 267–272.
11. Guerreiro, C. A., Falcao, A. E. and Silveira, D. C. Focal seizures in nonketotic hyperglycaemia (abstract). *Arquivos de Neuro-psiquiatria* 1991; **49** (4): 447–449.
12. Brick, J. F., Gutrecht, J. A. and Ringel, R. A. Reflex epilepsy and non-ketotic hyperglycemia in the elderly: a specific neuroendocrine syndrome. *Neurology* 1989; **39**: 394–399.
13. Adelman, S., Lueders, H., Dinner, D. S. and Lesser, R. P. Paradoxical lateralization of parasagittal sharp waves in a patient with epilepsy partialis continua. *Epilepsia* 1982; **23** (3): 291–295.