

Progressive neurological decline after partial spontaneous thrombosis of a Spetzler–Martin Grade 5 arteriovenous malformation in a patient with *Leiden factor V* mutation: management and outcome

Case report

MICHAEL J. LINK, M.D., THOMAS C. SCHERMERHORN, M.D., JIMMY R. FULGHAM, M.D., AND DOUGLAS A. NICHOLS, M.D.

Departments of Neurologic Surgery, Neurology, and Radiology, Mayo Clinic, Rochester, Minnesota

✓ The coexistence of a large intracranial arteriovenous malformation (AVM) and a hypercoagulation disorder is rare. The AVM puts the patient at risk for progressive neurological deficit, seizures, and, most importantly, intracranial hemorrhage. The hypercoagulation disorder may result in an increased risk of stroke. The authors describe a 42-year-old man with a Spetzler–Martin Grade 5 AVM who experienced progressive neurological decline. He was subsequently discovered to have partial thrombosis of the AVM, deep cerebral and cortical venous thrombosis, and a hypercoagulation disorder. Hypercoagulation disorders causing neurological deficits are usually treated with anticoagulant medications; however, this approach was not thought to be safe in the presence of a large AVM. Therefore, the AVM nidus was surgically extirpated and a ventriculoperitoneal shunt was placed to treat the increased intracranial pressure caused by the cortical and deep cerebral venous thrombosis. Subsequently, lifelong oral anticoagulation was prescribed. The patient had a progressive neurological recovery and is now living independently at home. The occurrence of partial or complete spontaneous thrombosis of an AVM nidus should raise the possibility of an underlying hypercoagulation disorder.

KEY WORDS • arteriovenous malformation • hypercoagulation • thrombosis • *Leiden factor V* mutation

THE COEXISTENCE of a large intracranial AVM and a hypercoagulation disorder in the same patient is rare. The presence of an AVM places the patient at risk for hemorrhage, progressive neurological deficit, or seizures. The risk of clinically evident hemorrhage ranges between 2 and 4% per year.^{6,12,26} In the study by Ondra, et al.,²⁶ the authors suggest that the risk of hemorrhage from an AVM is independent of the mode of presentation. In addition, Brown, et al.,⁶ have noted that, in the 168 patients with AVMs whom they observed, 6.6% experienced progressive neurological dysfunction even without having had a hemorrhage. When the results of psychometric testing are also included as determinants of disability, the risk of disability may be as high as 25%, unrelated to the hemorrhage.³ When treatment is deemed necessary, the aforementioned risks must be balanced against those of proposed treatments such as surgical extirpation, endovascular embolization, and radiosurgery, alone or in combination.

A hypercoagulation disorder that causes cerebral venous thrombosis may result in increased intracranial pressure

(30–40% of cases), focal neurological deficit and seizures (50–60% of cases), or diffuse encephalopathy (10–20% of cases).^{2,7–9} Intravenous or oral anticoagulant therapy may be combined with endovascular thrombolysis, symptomatic treatment of seizures or increased intracranial pressure, and the correction of any causal agent that may be present.

The presence of both disorders in the same patient poses a treatment dilemma. We describe a patient who had a Spetzler–Martin Grade 5 AVM³³ and progressive intracranial venous thrombosis secondary to *Leiden factor V* mutation.

Case Report

History. This 42-year-old man with no history of neurological illness presented to his local hospital in March 1999 with a generalized tonic-clonic seizure. A subsequent workup revealed a Spetzler–Martin Grade 5 AVM in the right temporoparietooccipital area (Figs. 1 and 2). The arterial supply was provided by numerous distal cortical branches of the right posterior cerebral, anterior cerebral, and middle cerebral circulations. Venous drainage was both superficial and deep. The patient was treated with phenytoin sodium and valproic acid, but continued to experience between three and five seizures per month.

Abbreviations used in this paper: APC = activated protein C; AVM = arteriovenous malformation; DVT = deep venous thrombosis; MR = magnetic resonance; VP = ventriculoperitoneal.

Spontaneous thrombosis of a Spetzler–Martin Grade 5 AVM

In September 1999, the patient experienced a prolonged (70-minute) generalized tonic–clonic seizure that was complicated by aspiration. Persistent mild hemiparesis appeared on his left side after that episode, but he was able to return to work. Deep venous thrombosis was suspected in his calf but, because of the AVM, no anticoagulant therapy was recommended.

One month later, the man was readmitted to his local hospital because of further seizures, culminating in status epilepticus and aspiration pneumonia. Following this, hypersomnolence and left hemiplegia developed. Computerized tomography scans of his head yielded no evidence of hemorrhage from the AVM. The patient remained lethargic but arousable with left-sided hemiplegia and was transferred to the Mayo Clinic on December 14, 1999.

Examination. Magnetic resonance imaging revealed increased edema and a mass effect surrounding the AVM with no evidence of hemorrhage (Fig. 3). The patient's neurological deficit appeared to be progressing as a result of the seizures and possibly ischemia related to the large high-flow AVM. Ultrasonography of the lower extremities did not demonstrate DVT. The initial treatment plan was for staged embolization (three–five sessions) followed by resection of the AVM.

On December 31, angiography and embolization were performed. Surprisingly, in the 8-month period after the initial angiography, extensive cortical venous thrombosis had occurred, including thrombosis of many of the cortical veins draining the AVM and of a large portion of the AVM nidus (Fig. 4). The arteriovenous transit time of the man's normal brain parenchyma was delayed markedly (Fig. 5). There was also thrombosis of the right internal cerebral vein, basal vein of Rosenthal, and vein of Galen. Findings of diffuse cortical and right-sided deep cerebral venous thrombosis accounted for the patient's near-comatose state and left-sided hemiplegia.

Intervention. The discussion of treatment concerned whether to proceed with embolization of the remaining AVM nidus followed by resection or to begin long-term anticoagulant therapy to treat the progressive intracerebral venous thrombosis that was the cause of the progressive neurological deficit. We selected the former treatment course. The anterior cerebral artery supply to the AVM was embolized with polyvinyl alcohol particles without complication and, on January 5, 2000, the AVM was resected completely.

Postoperative Course. Postoperatively, the patient remained obtunded with mildly increased intracranial pressure (25–35 mm Hg). A VP shunt was placed, resulting in excellent control of the intracranial pressure. Follow-up cerebral angiography on January 7 confirmed complete obliteration of the AVM.

The patient's neurological function improved, but on January 25 ultrasonography of the lower extremities revealed DVT, and an inferior vena cava filter was placed. An evaluation of a hypercoagulable state revealed a heterozygous *factor V R506Q (Leiden)* gene mutation, and oral anticoagulant therapy was started with the expectation that the patient would continue this treatment throughout his life. He was transferred to a rehabilitation unit on February 13 and discharged home to independent living on March 17.

At the follow-up examination performed in June 2003,

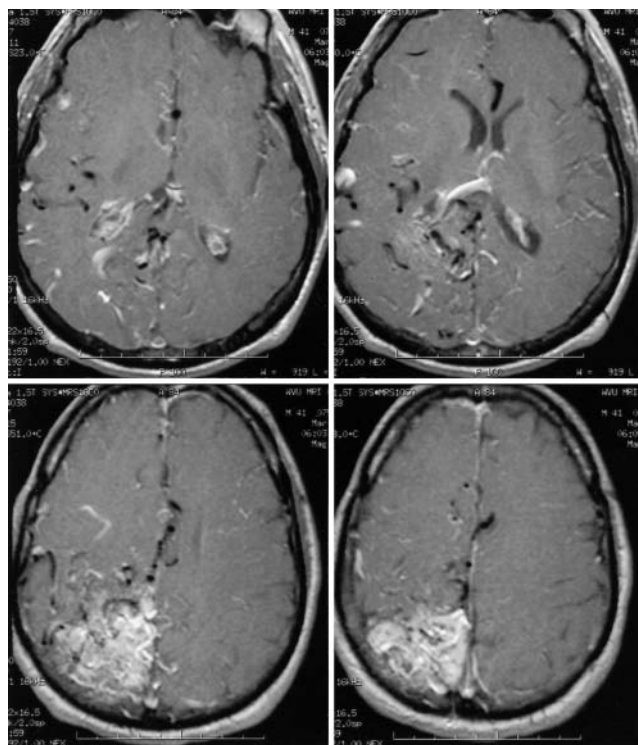


FIG. 1. Axial contrast-enhanced T₁-weighted MR images demonstrating enhancing flow voids in the right parietooccipital lobes, which are consistent with the presence of an AVM. No edema or mass effect is present.

the patient was alert and oriented. There was a homonymous hemianopia on his left side. He walked with a cane and displayed antigravity strength in the proximal left upper extremity. He exhibited a moderate impairment in performing tasks involving constructional skills and basic visual perceptual ability and recall ability.

Discussion

Factor V R506Q (Leiden) Gene Mutation

Factor V (Leiden) mutation, also known as APC resistance, is the most common heritable coagulopathy resulting in a hypercoagulable state. Thrombin, when bound to thrombomodulin on the endothelial surface, activates protein C into APC. The APC then inactivates already activated factors V and VIII. This is one of the mechanisms that inhibit thrombin generation and prevent thrombosis from progressing unchecked.¹⁰

Activated protein C resistance has been found in as many as 50% of selected patients¹³ and approximately 20% of unselected patients¹⁶ with thrombosis. It is present in 5 to 9% of European populations and is extremely rare, if present at all, in Asian and African populations.^{29,30} The relative risk of thrombosis for patients with APC resistance is thought to be increased sevenfold for heterozygous individuals and 80-fold for homozygous persons younger than 70 years of age who do not harbor malignant neoplasms.³¹

To our knowledge, this is the first reported case in which APC resistance contributed to partial spontaneous thrombosis of a cerebral AVM.

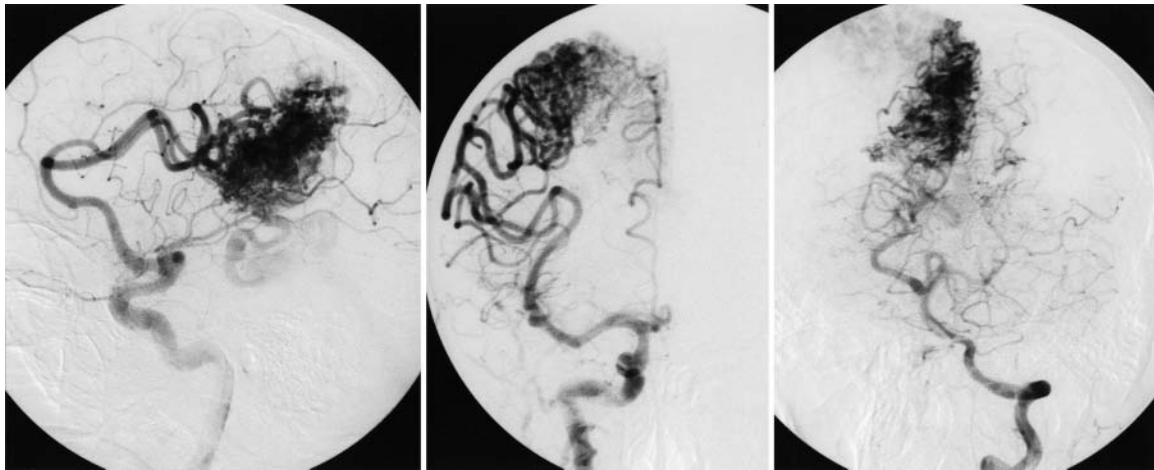


FIG. 2. *Left:* Lateral left carotid artery (CA) angiogram revealing an azygos A_2 segment is fed from the left CA injection, which fills the anterior portion of the AVM. *Center:* Anteroposterior right CA angiogram demonstrating multiple middle cerebral artery branches are feeding the AVM. *Right:* Anteroposterior left vertebral artery angiogram. The posterior portion of the AVM is fed by posterior cerebral artery branches.

Spontaneous Thrombosis of an AVM

Spontaneous complete thrombosis of an intracranial AVM is rare. Only 50 cases have been reported in the literature; in only approximately 50% of these substantiating angiograms were obtained both before and after AVM obliteration. In a review of 24 cases of spontaneous complete thrombosis of an AVM nidus, the median patient age was 40 years (range 25–58 years).¹ Of these, 71% presented with hemorrhage, 13% with seizure, and 8% with headache alone; one patient had hydrocephalus. Only two of 24 AVMs were larger than 6 cm at their largest diameter.¹ The

most popular theory about the cause of spontaneous thrombosis of an AVM is the presence of a single draining vein (present in 84% of 19 patients in the literature in whom venous drainage was described) that occludes and causes retrograde thrombosis of the nidus.^{1,17} The initial draining vein thrombosis may occur secondary to compression by hemorrhage, vasospasm from subarachnoid hemorrhage, turbulent flow from variceal dilation, or a hypercoagulation disorder. Nevertheless, a review of the literature reveals only one case in which a hypercoagulable state was implicated, and this occurred in an infant.²⁰

Six cases described in the literature have documented spontaneous partial thrombosis of an AVM, similar to our case.^{19,25,32} The true incidence of this occurrence is unknown and is probably often unrecognized and unreported.

Interestingly, Kurita, et al.,¹⁸ described two patients with AVMs who had progressive brain edema and slow venous outflow from the nidus, similar to the case described herein. We believe that our patient became symptomatic after progressive thrombosis of his AVM and, specifically, after progressive cortical and deep cerebral venous thrombosis caused an extremely prolonged cerebral transit time and increased intracranial pressure. Our patient clearly had a hypercoagulable state, predisposing him to thrombosis. Additionally, the high venous outflow pressure in the draining veins from the AVM may have initiated the thrombosis, which then became exacerbated by the *Leiden factor V* mutation. Local damage to the venous endothelium caused by turbulent flow and the mechanical action of shearing stress on the endothelial surfaces has been proposed as the initiating event in the narrowing of the lumen and thrombosis of the AVM draining vein.^{11,34} Others have suggested that some instances of narrowing of the AVM draining vein may represent a vasoconstrictive response to increased shunt volume or elevated venous pressure.²⁸ Due to the large size of the AVM in the present case and the large number of draining veins, we thought it would be unlikely that it would progress to complete spontaneous thrombosis and that more urgent treatment of the patient's deteriorating neurological condition was indicated.

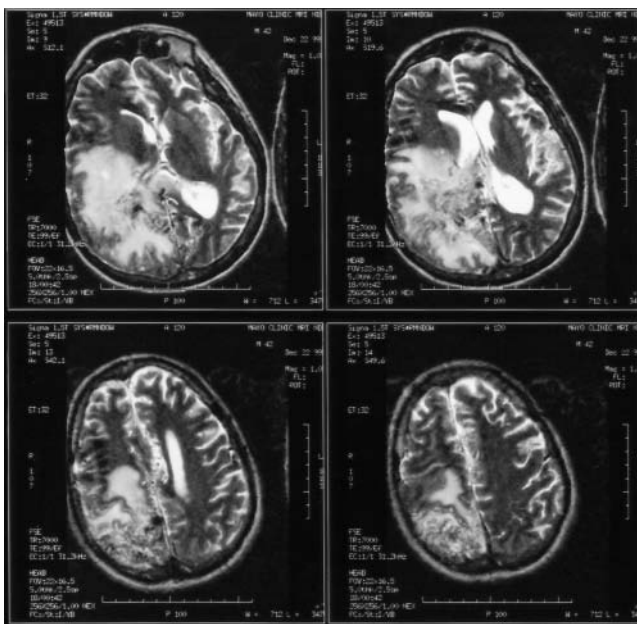


FIG. 3. Axial T_2 -weighted MR images demonstrating new edema with a moderate mass effect surrounding the AVM and no evidence of hemorrhage.

Spontaneous thrombosis of a Spetzler–Martin Grade 5 AVM

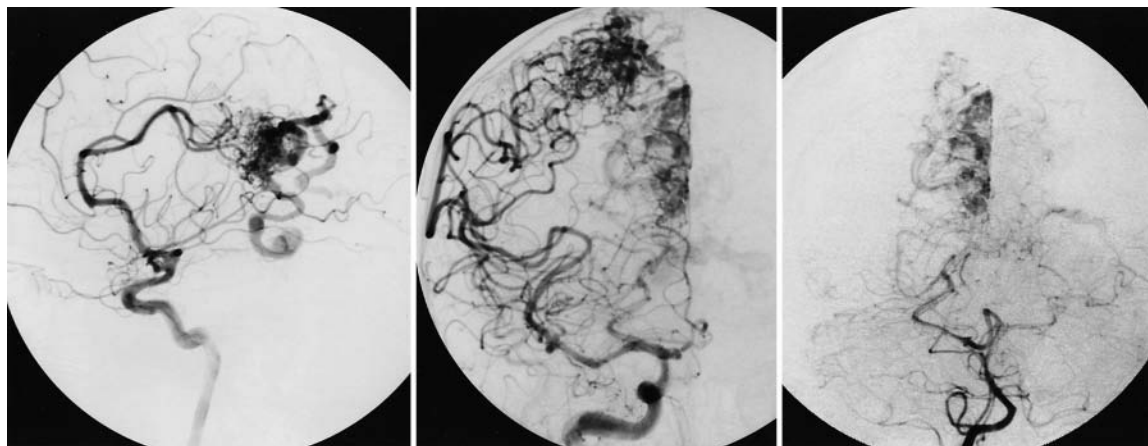


FIG. 4. *Left:* Lateral left CA angiogram revealing the majority of the anterior portion of the AVM, which continues to be filled by the left CA injection. *Center:* Anteroposterior right CA angiogram demonstrating thrombosis of the central portion of the AVM. *Right:* Anteroposterior right vertebral artery angiogram. Blood flow is slower through the posterior portion of the AVM nidus secondary to the venous hypertension.

Outcome From Management of Spetzler–Martin Grade 5 AVMs

Spetzler–Martin Grade 5 AVMs present some of the most challenging problems in neurosurgery. New major neurological deficits can be expected in more than 30% of surgically treated patients.^{15,23,24} Most clinicians do not recommend surgery to treat Grade 5 AVMs, except for patients who have a severe preoperative deficit, multiple hemorrhages, or gradually progressing deficit. As in our case, a combination of preoperative endovascular embolization followed by microsurgical resection is often the best strategy for treatment. Our patient has recovered from his preoperative deficits of a severely depressed level of consciousness and left hemiplegia. He is independent in his activities of daily living, but continues to have left hemiparesis and

neurocognitive deficits such that he cannot resume his former occupation of bank loan officer.

Cerebral Venous Thrombosis

Cerebral venous thrombosis may have an extraordinarily diverse neuroimaging appearance and clinical presentation. There are no pathognomonic signs or symptoms and, thus, the diagnosis depends on clinical acumen. Headache is a prominent complaint in 81 to 93% of patients, papilledema has been reported in 27 to 86% of patients, and focal neurological deficits, seizures, and altered consciousness, as seen in our patient, have been reported in 10 to 66% of nonpuerperal patients.^{4,5,8,9} Once the diagnosis is established, the cause should be identified and treatment started as soon as possible. Treatment is based on the combination

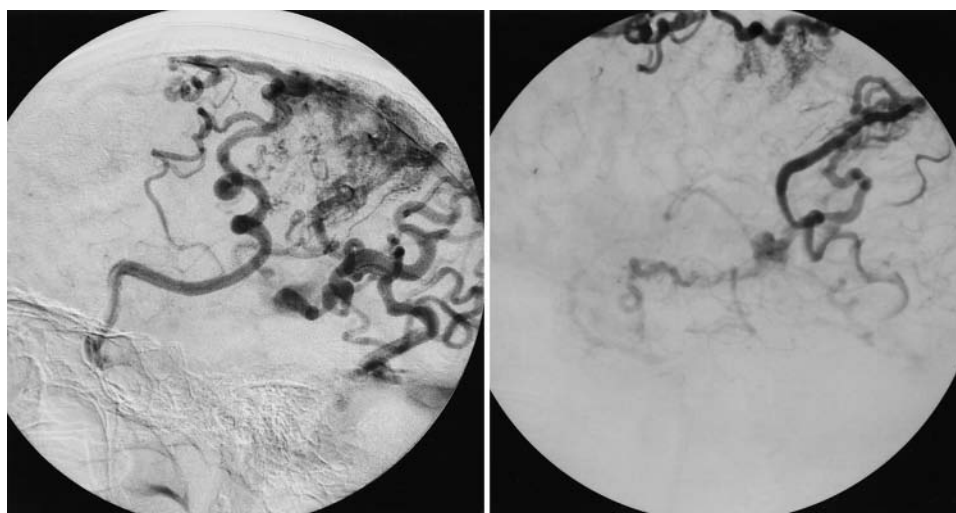


FIG. 5. *Left:* Initial diagnostic right lateral CA angiogram (April 1999) obtained 7.18 seconds after contrast injection shows the dye in the nidus of the AVM and in numerous draining veins. *Right:* Preoperative right lateral CA angiogram (December 1999) obtained 7.16 seconds after contrast injection demonstrates that there has been extensive venous thrombosis in the 8-month imaging interval.

of intravenous heparin sodium (followed by oral anticoagulants for 3–6 months), symptomatic treatment with anticonvulsant and analgesic medications, treatment to lower increased intracranial pressure, and treatment of the cause. Local thrombolysis is indicated if the patient's condition deteriorates because of progressive thrombosis despite adequate anticoagulant therapy.

Treatment was complicated in our patient by the presence of a large AVM. We did not believe that long-term anticoagulation or thrombolysis would be safe in the presence of persistent arteriovenous shunting. We were also concerned that, with continued venous thrombosis, the intracranial pressures would increase and add to the risk of life-threatening hemorrhage. Although somewhat controversial, evidence—both theoretical and derived from case series—suggests that AVMs with venous drainage impairment are associated with an increased risk of hemorrhage.^{14,21,22,27,34,35} Once the AVM was extirpated, we believed it was safe to treat the persistently increased intracranial pressure by implanting a VP shunt. The patient is receiving lifelong anticoagulant therapy for his venous thrombosis, delayed cerebral transit time, and *factor V (Leiden)* mutation.

Conclusions

The occurrence of an intracranial AVM in a patient with a hypercoagulation disorder secondary to *factor V (Leiden)* mutation is rare. The patient presented with a progressive neurological deficit related to cortical and deep cerebral venous thrombosis. Treatment consisted of surgical removal of the AVM followed by implantation of a VP shunt and lifelong oral anticoagulant therapy. The patient made a sufficient neurological recovery to return to independent living, despite the large size and eloquent location of the AVM. Investigation for a hypercoagulation disorder such as *factor V (Leiden)* mutation should be undertaken when either partial or complete spontaneous thrombosis of an AVM occurs. We believe that until all arteriovenous shunting from an AVM is eliminated, the risk for hemorrhage remains and may increase if venous outflow is obstructed by venous thrombosis. Therefore, treatment should first eliminate the AVM and then treat the clinical sequelae of cerebral venous thrombosis.

Disclaimer

The authors have no personal or institutional financial interest in the drugs, materials, or devices described in the manuscript. The authors have received no financial support in conjunction with this manuscript.

References

1. Abdulrauf SI, Malik GM, Awad IA: Spontaneous angiographic obliteration of cerebral arteriovenous malformations. **Neurosurgery** **44**:280–288, 1999
2. Ameri A, Bousser MG: Cerebral venous thrombosis. **Neurol Clin** **10**:87–111, 1992
3. Andersen EB, Petersen J, Mortensen EL, et al: Conservatively treated patients with cerebral arteriovenous malformation: mental and physical outcome. **J Neurol Neurosurg Psychiatry** **51**:1208–1212, 1988
4. Biousse V, Ameri A, Bousser MG: Isolated intracranial hypertension as the only sign of cerebral venous thrombosis. **Neurology** **53**:1537–1542, 1999
5. Bousser MG: Cerebral venous thrombosis: diagnosis and management. **J Neurol** **247**:252–258, 2000
6. Brown RD Jr, Wiebers DO, Forbes G, et al: The natural history of unruptured intracranial arteriovenous malformations. **J Neurosurg** **68**:352–357, 1988
7. Cantu C, Barinagarrementeria F: Cerebral venous thrombosis associated with pregnancy and puerperium. Review of 67 cases. **Stroke** **24**:1880–1884, 1993
8. Daif A, Awada A, al-Rajeh S, et al: Cerebral venous thrombosis in adults. A study of 40 cases from Saudi Arabia. **Stroke** **26**:1193–1195, 1995
9. Einhüpl KM, Villringer A, Haberl RL: Clinical spectrum of sinus venous thrombosis, in Einhüpl KM, Kempfski O, Baethmann A (eds): **Cerebral Sinus Thrombosis: Experimental and Clinical Aspects**. New York: Plenum Press, 1982, Vol 1, pp 27–39
10. Federman DG, Kirsner RS: An update on hypercoagulable disorders. **Arch Intern Med** **161**:1051–1056, 2001
11. Fry DL: Acute vascular endothelial changes associated with increased blood velocity gradients. **Circ Res** **22**:165–197, 1968
12. Graf CJ, Perret GE, Torner JC: Bleeding from cerebral arteriovenous malformations as part of their natural history. **J Neurosurg** **58**:331–337, 1983
13. Griffin JH, Evatt B, Wideman C, et al: Anticoagulant protein C pathway defective in majority of thrombophilic patients. **Blood** **82**:1989–1993, 1993
14. Hademenos GJ, Massoud TF: Risk of intracranial arteriovenous malformation rupture due to venous drainage impairment: a theoretical analysis. **Stroke** **27**:1072–1083, 1996
15. Hartmann A, Stapf C, Hofmeister C, et al: Determinants of neurological outcome after surgery for brain arteriovenous malformation. **Stroke** **31**:2361–2364, 2000
16. Koster T, Rosendaal FR, de Ronde H, et al: Venous thrombosis due to poor anticoagulant response to activated protein C: Leiden Thrombophilia Study. **Lancet** **342**:1503–1506, 1993
17. Krapf H, Siekmann R, Freudenstein D, et al: Spontaneous occlusion of a cerebral arteriovenous malformation: angiography and MR imaging follow-up and review of the literature. **AJNR** **22**:1556–1560, 2001
18. Kurita H, Shin M, Ueki K, et al: Congestive brain oedema associated with a pial arteriovenous malformation with impaired venous drainage. **Acta Neurochir** **143**:339–342, 2001
19. Kushner J, Alexander E Jr: Partial spontaneous regressive arteriovenous malformation: case report with angiographic evidence. **J Neurosurg** **32**:360–366, 1970
20. Mabe H, Furuse M: Spontaneous disappearance of a cerebral arteriovenous malformation in infancy. Case report. **J Neurosurg** **46**:811–815, 1977
21. Marks MP, Lane B, Steinberg GK, et al: Hemorrhage in intracerebral arteriovenous malformations: angiographic determinants. **Radiology** **176**:807–813, 1990
22. Miyasaka Y, Yada K, Ohwada T, et al: An analysis of the venous drainage system as a factor in hemorrhage from arteriovenous malformations. **J Neurosurg** **76**:239–243, 1992
23. Morgan MK, Sekhon LH, Finfer S, et al: Delayed neurological deterioration following resection of arteriovenous malformations of the brain. **J Neurosurg** **90**:695–701, 1999
24. Nussbaum ES, Heros RC, Camarata PJ: Surgical treatment of intracranial arteriovenous malformations with an analysis of cost-effectiveness. **Clin Neurosurg** **42**:348–369, 1995
25. Omojola MF, Fox AJ, Viñuela FV, et al: Spontaneous regression of intracranial arteriovenous malformations. Report of three cases. **J Neurosurg** **57**:818–822, 1982
26. Ondra SL, Troupp H, George ED, et al: The natural history of symptomatic arteriovenous malformations of the brain: a 24-year follow-up assessment. **J Neurosurg** **73**:387–391, 1990
27. Patel SC, Burke T, Chundi V, et al: Venous restrictive disease in cerebral AVMs. **Neuroradiology** **37** (Suppl):118–120, 1995

Spontaneous thrombosis of a Spetzler–Martin Grade 5 AVM

28. Quisling RG, Mickle JP: Venous pressure measurements in vein of Galen aneurysms. **AJNR** **10**:411–417, 1989
29. Rees DC, Cox M, Clegg JB: World distribution of factor V Leiden. **Lancet** **346**:1133–1134, 1995
30. Ridker PM, Miletich JP, Hennekens CH, et al: Ethnic distribution of factor V Leiden in 4047 men and women. Implications for venous thromboembolism screening. **JAMA** **277**:1305–1307, 1997
31. Rosendaal FR, Koster T, Vandenbroucke JP, et al: High risk of thrombosis in patients homozygous for factor V Leiden (activated protein C resistance). **Blood** **85**:1504–1508, 1995
32. Sasaki U, Itagaki T, Shimizu H, et al: [Almost complete regression of cerebral arteriovenous malformation—report of a case.] **No Shinkei Geka** **4**:175–181, 1976 (Jpn)
33. Spetzler RF, Martin NA: A proposed grading system for arteriovenous malformations. **J Neurosurg** **65**:476–483, 1986
34. Viñuela F, Nombela L, Roach MR, et al: Stenotic and occlusive disease of the venous drainage system of deep brain AVM's. **J Neurosurg** **63**:180–184, 1985
35. Willinsky R, Lasjaunias P, Terbrugge K, et al: [Brain arteriovenous malformations: analysis of the angio-architecture in relationship to hemorrhage (based on 152 patients explored and/or treated at the Hôpital de Bicêtre between 1981 and 1986).] **J Neuroradiol** **15**:225–237, 1988 (Fr)

Manuscript received March 19, 2003.

Accepted in final form January 12, 2004.

This study was presented in poster form at the Fifth Joint Annual Meeting of the American Association of Neurological Surgeons/Congress of Neurological Surgeons Section on Cerebrovascular Surgery and the American Society of Interventional and Therapeutic Neuroradiology, Addison, Texas, February 3–6, 2002.

Address reprint requests to: Michael J. Link, M.D., Department of Neurologic Surgery, Mayo Clinic, 200 First Street SW, Rochester, Minnesota 55905. email:link.michael@mayo.edu.