

Regional Anesthesia and Pain

Spontaneous recovery from a spinal epidural hematoma with atypical presentation in a nonagenarian

[La récupération spontanée après un hématome épidural rachidien de présentation atypique chez une nonagénaire]

Stephan K.W. Schwarz MD DR Med PhD,* Clinton L. Wong MD FRCPC,† William N. McDonald BSc MD FRCPC†

Purpose: Spinal epidural hematoma following epidural anesthesia is extraordinarily rare in association with low-dose sc heparin, and the prognosis for neurologic recovery without rapid surgical decompression poor. We report a case of spinal epidural hematoma in a nonagenarian who received low-dose sc unfractionated heparin postoperatively in accordance with standard guidelines, presented with no back pain, and made full neurologic recovery without surgical intervention.

Clinical features: A 90-yr-old female with gastric adenocarcinoma presented for subtotal gastrectomy. Her past medical history and physical examination were largely unremarkable and she had no bleeding diathesis. She took no medications other than preoperative ranitidine, and had a normal coagulation profile. A thoracic epidural catheter was placed uneventfully before induction of general anesthesia. Postoperatively, low-dose sc unfractionated heparin was started 12 hr after the epidural catheter insertion. On postoperative day two, the patient developed flaccid lower extremity paralysis and paresthesia without back pain. Her coagulation profile remained normal. Subsequent magnetic resonance imaging showed a large epidural hematoma extending from T3 to T11. With conservative treatment and no surgery, the patient slowly made full neurologic recovery and was discharged home on postoperative day 56.

Conclusion: Complete neurologic recovery from flaccid paralysis following spinal epidural hematoma occurred without surgical decompression in a nonagenarian. Low-dose sc heparin may be a greater risk factor for spinal epidural hematoma than previously assumed, and the absence of back pain does not rule out this diagnosis.

Objectif: L'hématome épidural rachidien postanesthésie péridurale est extrêmement rare en association avec une faible dose d'héparine sc et, sans décompression chirurgicale rapide, le pronostic de récupération est pauvre. Nous présentons un cas d'hématome épidural rachidien chez une nonagénaire qui a reçu de faibles doses sc d'héparine standard postopératoire selon les directives uniformisées, ne présentait pas de dorsalgie et a connu une récupération neurologique complète sans intervention chirurgicale.

Éléments cliniques : Une femme de 90 ans atteinte d'adénocarcinome gastrique s'est présentée pour une gastrectomie partielle. Les antécédents médicaux et l'examen physique étaient sans particularité et sans diathèse hémorragique. Elle n'avait pris d'autres médicaments que la ranitidine préopératoire et présentait un profil de coagulation normal. Un cathéter épidural thoracique a été inséré sans problème avant l'induction de l'anesthésie générale. Après l'opération, l'administration sc d'héparine standard a été amorcée 12 h après l'insertion du cathéter. Au jour deux postopératoire, la patiente présentait une paralysie flasque et une paresthésie des membres inférieurs sans dorsalgie. Son profil de coagulation est demeuré normal. Un examen d'imagerie par résonance magnétique a montré un important hématome épidural s'étendant de T3 à T11. Un traitement conservateur, sans chirurgie, a permis une récupération neurologique complète et un retour à domicile 56 jours après l'opération.

Conclusion : La récupération neurologique complète d'une paralysie flasque suivant un hématome épidural rachidien est survenue sans décompression chirurgicale chez une nonagénaire. L'administration sc de faibles doses d'héparine peut présenter un risque plus important d'hématome épidural rachidien qu'on ne l'avait d'abord cru et l'absence de dorsalgie n'exclut pas ce diagnostic.

From the Centre for Anesthesia and Analgesia,* Department of Anesthesia and Department of Pharmacology and Therapeutics, The University of British Columbia; and the Division of Acute and Interventional Pain Management,† Department of Anesthesia, St. Paul's Hospital, Vancouver, British Columbia, Canada.

Address correspondence to: Dr. Stephan Schwarz, Department of Pharmacology and Therapeutics, The University of British Columbia, 2176 Health Sciences Mall, Vancouver, British Columbia V6T 1Z3, Canada. Phone: 604-822-5565; Fax: 604-822-6012; E-mail: Schwarz@neuro.pharmacology.ubc.ca

This work was supported exclusively by institutional/departmental sources. Financial arrangements that could lead to conflict: none.

Accepted for publication September 16, 2003.

Revision accepted December 1, 2003.

SPINAL epidural hematoma is a rare complication of epidural anesthesia with an estimated incidence of 1:190,000 and potentially devastating consequences.¹ Identified risk factors include difficult or traumatic needle/catheter insertion, ankylosing spondylitis, and anticoagulation/coagulopathy^{1,2} whereas treatment with low-dose unfractionated heparin is generally considered safe.³ Typical presentation is with sharp back pain and associated motor and sensory deficit progressing to paraplegia, with a poor prognosis of recovery if decompressive laminectomy is not performed within eight hours. Here, we report a case of spinal epidural hematoma in a 90-yr-old patient with no history of coagulopathy, multiple/traumatic needle insertion or catheter manipulation who received low-dose *sc* unfractionated heparin postoperatively in accordance with current standard guidelines, presented with no back pain, and made full neurologic recovery without surgical intervention.

Case report

A 90-yr-old Caucasian female [weight, 57 kg; American Society of Anesthesiologists (ASA) physical status class II] presented with gastric adenocarcinoma and was taken to the operating room for subtotal gastrectomy with creation of a Roux-en-Y anastomosis and feeding jejunostomy. She generally had enjoyed good health prior to admission and lived independently by herself. Her past medical history was negative for cardiorespiratory disease, diabetes mellitus, bleeding diathesis, or easy bruising. She had suffered from peptic ulcer disease for 25 years and had been diagnosed with hyperuricemia three years prior. Her past surgical history included appendectomy, cholecystectomy, and excision of a vulvar tumour, all performed several decades prior with no anesthetic problems. She had no history of back problems and was able to walk unlimited distances without dyspnea, angina, or claudication. She stated that she was allergic to aspirin and diazepam, both of which gave her gastrointestinal upset. She had quit smoking 30 years prior and drank no alcohol. She had not taken any medications or herbal preparations prior to admission and was placed on *iv* ranitidine preoperatively in the hospital. There was no family history of coagulation disorders. On physical examination, the patient's heart rate was 76·min⁻¹ and regular, blood pressure 165/60 mmHg, and respirations 20 breaths·min⁻¹. She had upper and lower dentures and a Mallampati class II airway. Heart sounds were normal and the chest was clear. Neurologic examination was unremarkable and no spinal abnormalities were noted. Her preoperative hemoglobin was 106 g·L⁻¹ and the platelet count

176,000 per mm³. The international normalized ratio (INR) was 1.1 and an activated partial thromboplastin time (aPTT) 31.2 sec. An electrocardiogram showed a normal sinus rhythm with non-specific anterolateral ST segment abnormalities. The results of all other investigations were non-contributory.

Before induction of general anesthesia, a 19-G thoracic epidural catheter (FlexTip Plus®, Arrow International, Inc., Reading, PA, USA) was placed at T8/9 on the first attempt under aseptic conditions with the patient sitting, using a "loss of resistance" technique with a 17-G Tuohy needle inserted via a left paramedian approach. There was no history of traumatic needle insertion or paresthesia, nor were cerebrospinal fluid (CSF) or blood aspirated. The epidural catheter was easily advanced 5 cm into the epidural space and a test dose of 3 mL lidocaine 2% administered without incident. Following uneventful induction of general anesthesia, combined general and regional anesthesia was maintained with desflurane and nitrous oxide in oxygen and a total epidural dose of 100 µg fentanyl, 1 mg preservative-free morphine, and 23 mL bupivacaine 0.25% throughout the 2.5 hr procedure. A Foley catheter inserted after induction of anesthesia. The patient was stable intraoperatively and no adverse events were noted. The surgical team found that the tumour had infiltrated surrounding tissues including the pancreas and completed the procedure with palliative intent. Intraoperative blood loss was estimated at 200 mL and no blood products were administered. Hemostasis was satisfactory with no clinical evidence of coagulopathy.

Postoperatively, the patient was transferred to a surgical ward where continuous epidural analgesia was maintained with bupivacaine 0.1% and preservative-free morphine 0.05 mg·mL⁻¹, infusing at 5 to 7 mL·hr⁻¹ and producing satisfactory pain relief. A positive motor response of the lower extremities was noted. Low-dose *sc* unfractionated heparin was started at 5000 IU twice daily, with the first dose administered 12 hr after insertion of the epidural catheter. Other postoperative medication included *iv* cefazolin, metronidazole, and ranitidine. No antiplatelet drugs were given. The Foley catheter remained *in situ*. There was no history of epidural catheter manipulation. On the evening of postoperative day two, the patient complained to the surgical house staff of bilateral lower extremity weakness and paresthesia without back pain or chills. This was felt to be due to the epidural infusion, which was held overnight. In the morning of postoperative day three, there was little improvement of the patient's symptoms. The attending Acute Pain Service anesthesiologist assessed the patient and a neurologist was consulted.

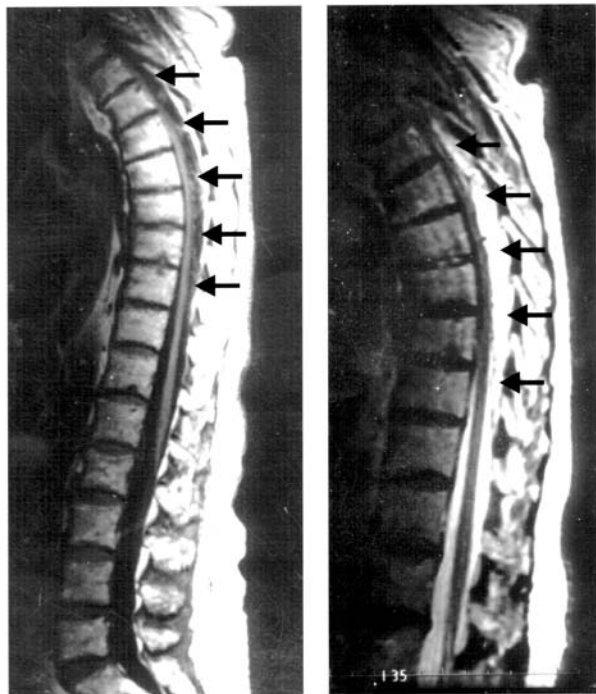


FIGURE 1 Sagittal magnetic resonance images of the thoracolumbar spine. A large complex epidural hematoma extending from ~ T3 to T10/11 is seen with hypo- and isodense signal characteristics on a T1-weighted image (left; arrows) and hyperintense signal characteristics on a T2-weighted image (right; arrows). At the centre of the hematoma, the spinal cord abuts the posterior aspect of the thoracic vertebral bodies (left). No signal abnormalities of the cord itself are seen.

Back pain continued to be absent. On physical examination, the patient was afebrile and had normal vital signs. The epidural insertion site was unremarkable except for some mild serosanguinous drainage. Neurologic examination showed markedly reduced muscle tone in both legs. Motor power of the lower extremities was 2/5 in all muscle groups except right ankle dorsiflexors (1/5) and left knee extensors, ankle dorsiflexors, and ankle plantar flexors (3/5). Deep tendon reflexes were absent bilaterally. Sensation to pinprick and light touch was absent below the L2 dermatome on the right and below T12 on the left. There was paresthesia with patches of allodynia to light touch in the area of the L1 dermatome on the right and T12 on the left. A coagulation profile showed a platelet count of 185,000 per mm^3 , an INR of 1.1, and an aPTT of 32.6 sec. The white blood cell count was 12,600 per mm^3 (neutrophil granulocytes, 74%).

Urgent magnetic resonance imaging (MRI) of the patient's thoracic and lumbar spine showed a large epidural hematoma extending from T3 to T11, with no evidence of vascular abnormalities, ischemic changes, or spinal stenosis (Figure).

The epidural catheter was removed and analgesia provided with *iv* morphine, administered via a patient-controlled analgesia pump. Based on the patient's age, advanced malignancy, and questionable benefit of surgical decompression > 12 hr after presentation, the decision was made after consultation with the neurologist, a neurosurgeon, and the patient to proceed with conservative treatment. Over the following weeks and with continuous physiotherapy and mobilization efforts, the patient improved steadily. On postoperative day 15, she was able to stand on her legs with the assistance of two helpers. Her motor power was 4/5 in all lower extremity muscle groups except both hip flexors (2/5). The patellar tendon reflexes were present bilaterally. Sensation to pinprick and light touch was intact. On postoperative day 30, the patient was able to walk independently with the aid of a walker. Further physiotherapy and rehabilitation measures were continued until the patient was discharged on postoperative day 56 with normal motor power and sensation of her lower extremities. She died at home three months later of her underlying disease.

Discussion

The incidence of spinal epidural hematoma following epidural anesthesia is extremely low and our knowledge about this complication is largely derived from analysis of previous case reports, as prospective randomized trials are not feasible due to the very large sample sizes that would be required. Here, we describe a case of spinal epidural hematoma in a nonagenarian whose multiple atypical features add to the existing data and illustrate several critical points about the clinical care of patients receiving epidural anesthesia.

Firstly, spinal epidural hematoma should always be considered early in the differential diagnosis of patients on continuous epidural analgesia who present with motor and sensory deficits. This may represent a diagnostic challenge, since the presence of lower extremity weakness and sensory changes may be interpreted as being due to the local anesthetic infusion, particularly by non-anesthesiologists and in the absence of back pain or inadequate analgesia, as was the case in this patient. Analysis of the ASA closed claims project database supports this diagnostic approach: in at least ten claim files, delayed diagnosis of epidural hematoma was a major factor in the resultant nerve injury.⁴ It must be re-emphasized that the

absence of back pain does not exclude spinal epidural hematoma. In a series of 61 cases reviewed in 1994, back pain was the first symptom in only 38% of patients.² Aggressive early MRI scanning will lead to early diagnosis in this situation, and such a strategy should be considered standard of care.

Another important differential diagnosis of consideration is intrathecal migration of the epidural catheter, which may produce flaccid lower extremity paralysis due to subarachnoid infusion of local anesthetic solution, often in association with hypotension and/or respiratory compromise. Whereas this diagnosis may be made acutely by aspirating CSF from the epidural catheter, the persistence of the neurologic deficit in the present patient after the epidural infusion had been held overnight was more consistent with spinal epidural hematoma.

A third consideration is anterior spinal artery syndrome, recently reviewed in the literature.⁵ In addition to the clinical constellation of a sudden onset of flaccid paralysis, areflexia, patchy sensory deficit, and absence of back pain in an elderly patient, the discrepancy between the largely lumbar distribution of the neurologic deficit and the thoracic insertion site of the epidural catheter was noteworthy and appeared to support this possibility. Again, MRI scanning proved to be instrumental in establishing the correct diagnosis.

A final important differential diagnosis is spinal epidural abscess formation, which was considered less likely in this patient given the rapid onset, absence of generalized symptoms including fever, and normal white blood cell count.

Secondly, treatment with low-dose *sc* unfractionated heparin may have been a predisposing factor. The 2003 consensus statement of the American Society of Regional Anesthesia (ASRA) does not regard low-dose heparin a contraindication to the use of neuraxial anesthesia,³ similar to others in the past.^{6,7} Nonetheless, there are at least four reported cases of spinal epidural hematoma associated with epidural anesthesia in patients who received low-dose *sc* unfractionated heparin for prophylaxis of venous thromboembolism.⁸⁻¹⁰ In addition, at least one case associated with spinal anesthesia has been reported,¹¹ and one after combined spinal epidural anesthesia that manifested following epidural catheter removal.¹² However, the question whether patients receiving low-dose heparin truly carry an increased risk of bleeding compared to patients receiving no heparin or placebo remains unanswered. Low-dose *sc* heparin may produce unpredictable aPTT prolongations;¹³ in the present patient, however, no postoperative coagulation abnormalities were found. It is of note that the

time interval between placement of the epidural catheter and the first dose of heparin was significantly longer than the current ASRA recommendation (12 hr *vs* 1 hr).

Thirdly, advanced age *per se* is a risk factor for spinal epidural hematoma.^{1,2} Until recently, however, it did not appear reasonable to consider advanced age a contraindication for epidural anesthesia in light of the evidence for the potential benefits of this technique compared to general anesthesia alone.¹⁴⁻¹⁶ In the last three years, on the other hand, the magnitude of such benefits has come into question,¹⁷⁻¹⁹ which may lead clinicians to re-evaluate the risk-benefit analysis of epidural anesthesia in the elderly.

Finally, this case provides the first document to our knowledge of neurologic recovery from spinal epidural hematoma following epidural anesthesia without decompressive laminectomy in a nonagenarian. Persson *et al.* reported recently on a 74-yr-old patient who had received a thoracic epidural catheter and recovered neurologically despite surgery being delayed for three days after diagnosis.²⁰ Interestingly, several series of cases of recovery without surgery have been reported in the neurosurgical literature in patients who developed spontaneous spinal epidural hematomas without neuraxial anesthesia or lumbar puncture.²¹⁻²⁴ This may be a reflection of the epidemiology of this condition, as the vast majority of spinal epidural hematomata occur spontaneously without association with neuraxial anesthesia.^{1,25} However, such cases represent the exception in the literature, where the prognosis for patients in whom surgical decompression is not performed within eight hours has been poor.^{1,2,25}

In conclusion, we report here the first case of full neurologic recovery without surgery from spinal epidural hematoma following epidural anesthesia in a nonagenarian. The occurrence of this complication in the absence of established risk factors other than age and treatment with low-dose unfractionated heparin as well as its atypical presentation without back pain emphasize the need for clinical vigilance in the routine postoperative care of patients receiving epidural anesthesia.

Acknowledgements

We gratefully acknowledge the invaluable contributions of Drs. M. Solylo, I. Dumitru, J. Hooge, S. Clarke, S. Bicknell, and P. Harrison.

References

- 1 Wulf H. Epidural anaesthesia and spinal haematoma. *Can J Anaesth* 1996; 43: 1260-71.
- 2 Vandermeulen EP, Van Aken H, Vermeylen J.

- Anticoagulants and spinal-epidural anesthesia. *Anesth Analg* 1994; 79: 1165–77.
- 3 Horlocker TT, Wedel DJ, Benzon H, *et al.* Regional anesthesia in the anticoagulated patient: defining the risks (the Second ASRA Consensus Conference on Neuraxial Anesthesia and Anticoagulation). *Reg Anesth Pain Med* 2003; 28: 172–97.
 - 4 Cheney FW, Domino KB, Caplan RA, Posner KL. Nerve injury associated with anesthesia. A closed claims analysis. *Anesthesiology* 1999; 90: 1062–9.
 - 5 Horlocker TT, Wedel DJ. Neurologic complications of spinal and epidural anesthesia. *Reg Anesth Pain Med* 2000; 25: 83–98.
 - 6 Schwander D, Bachmann F. Heparin and spinal or epidural anaesthesia: clinical decision making (French). *Ann Fr Anesth Reanim* 1991; 10: 284–96.
 - 7 Liu SS, Mulroy MF. Neuraxial anesthesia and analgesia in the presence of standard heparin. *Reg Anesth Pain Med* 1998; 23(Suppl 2): 157–63.
 - 8 Darnat S, Guggiari M, Grob R, Guillaume A, Viars P. Lumbar epidural haematoma following the setting-up of an epidural catheter (French). *Ann Fr Anesth Reanim* 1986; 5: 550–2.
 - 9 Metzger G, Singbartl G. Spinal epidural hematoma following epidural anesthesia versus spontaneous spinal subdural hematoma. Two case reports. *Acta Anaesthesiol Scand* 1991; 35: 105–7.
 - 10 Sandhu H, Morley-Forster P, Spadafora S. Epidural hematoma following epidural analgesia in a patient receiving unfractionated heparin for thromboprophylaxis. *Reg Anesth Pain Med* 2000; 25: 72–5.
 - 11 Dupeyrat A, Dequire PM, Meronani A, Moullier P, Eid G. Subarachnoid haematoma and spinal anaesthesia (French). *Ann Fr Anesth Reanim* 1990; 9: 560–2.
 - 12 Pay LL, Chiu JW, Thomas E. Postoperative epidural hematoma or cerebrovascular accident? A dilemma in differential diagnosis. *Acta Anaesthesiol Scand* 2002; 46: 217–20.
 - 13 Gallus AS, Hirsh J, Tuttle RJ, *et al.* Small subcutaneous doses of heparin in prevention of venous thrombosis. *N Engl J Med* 1973; 288: 545–51.
 - 14 Yeager MP, Glass DD, Neff RK, Brinck-Johnsen T. Epidural anesthesia and analgesia in high-risk surgical patients. *Anesthesiology* 1987; 66: 729–36.
 - 15 Liu S, Carpenter RL, Neal JM. Epidural anesthesia and analgesia. Their role in postoperative outcome. *Anesthesiology* 1995; 6: 1474–506.
 - 16 Rodgers A, Walker N, Schug S, *et al.* Reduction of postoperative mortality and morbidity with epidural or spinal anaesthesia: results from overview of randomised trials. *BMJ* 2000; 321: 1–12.
 - 17 Park WY, Thompson JS, Lee KK. Effect of epidural anesthesia and analgesia on perioperative outcome: a randomized, controlled Veterans Affairs cooperative study. *Ann Surg* 2001; 234: 560–71.
 - 18 Rigg JR, Jamrozik K, Myles PS, *et al.* Epidural anaesthesia and analgesia and outcome of major surgery: a randomised trial. *Lancet* 2002; 359: 1276–82.
 - 19 Peyton PJ, Myles PS, Silbert BS, Rigg JR, Jamrozik K, Parsons AR. Perioperative epidural analgesia and outcome after major abdominal surgery in high-risk patients. *Anesth Analg* 2003; 96: 548–54.
 - 20 Persson J, Flisberg P, Lundberg J. Thoracic epidural anesthesia and epidural hematoma. *Acta Anaesthesiol Scand* 2002; 46: 1171–4.
 - 21 Silber SH. Complete nonsurgical resolution of a spontaneous spinal epidural hematoma. *Am J Emerg Med* 1996; 14: 391–3.
 - 22 Duffill J, Sparrow OC, Millar J, Barker CS. Can spontaneous spinal epidural haematoma be managed safely without operation? A report of four cases. *J Neurol Neurosurg Psychiatry* 2000; 69: 816–9.
 - 23 Dam-Hieu P, Mihalescu M, Tadie M. Spontaneous cervico-thoracic epidural hematoma with spontaneously regressive paraplegia (French). *Neurochirurgie* 2001; 47: 442–4.
 - 24 Hentschel SJ, Woolfenden AR, Fairholm DJ. Resolution of spontaneous spinal epidural hematoma without surgery: report of two cases. *Spine* 2001; 26: E525–7.
 - 25 Schmidt A, Nolte H. Subdural and spinal haematoma following spinal, epidural, or caudal anaesthesia (German). *Anaesthesist* 1992; 41: 276–84.