

# Necrobiotic xanthogranuloma with cutaneous and cerebral manifestations

## Case report and review of the literature

KIRITKUMAR CHHANALAL SHAH, M.S., SANTOSH ISAAC POONNOOSE, M.CH.,  
RENU GEORGE, M.D., MARY JACOB, M.D., AND VEDANTAM RAJSHEKHAR, M.CH.

*Departments of Neurological Sciences, Dermatology, and Pathology, Christian Medical College Hospital, Vellore, India*

✓ Necrobiotic xanthogranuloma (NXG) is a rare inflammatory histiocytic disease of the skin. Xanthogranuloma of the central nervous system is rare and few cases have been reported. To the authors' knowledge, there has been no previously reported case of NXG in which an intracranial lesion was found.

This 52-year-old man, in whom NXG with all its cutaneous manifestations had been diagnosed, presented with three episodes of generalized tonic-clonic seizures. A contrast-enhanced computerized tomography scan of his brain revealed a bifrontal, dura-based mass lesion. The lesion was excised and reported to be an NXG that was similar, but not identical to the skin lesions. The patient was placed on a regimen of antiepileptic drug and chlorambucil after surgery.

**KEY WORDS** • necrobiotic xanthogranuloma • brain neoplasm

**N**ECROBIOTIC xanthogranuloma is a rare inflammatory histiocytic disease that is characterized by indurated, nontender, dermal, or subcutaneous yellow nodules and plaques that primarily infiltrate the eyelids, periorbital structures, flexor aspect of the extremities, and trunk. Several case series and reports have been published since the first description of the disorder by Kossard and Winkelmann<sup>14</sup> in 1980. Systemic associations include multiple myeloma, chronic lymphocytic leukemia, Hodgkin disease, non-Hodgkin lymphoma, asthma, and Quinke edema;<sup>7,15,23</sup> however, there have been no reports of an association of NXG with a CNS lesion.

In this case we describe a patient whose NXG included cutaneous and intracranial lesions. To our knowledge intracranial involvement has never been reported with NXG.

### Case Report

*History.* This 52-year-old man originally presented with a 5-year history of multiple, painless, firm-to-hard nodules over his entire body and hoarseness of voice. He also had a scleral growth in the left eye that was excised by an ophthalmologist and reported to be a granulomatous inflammation. A biopsy sample of one of the skin lesions was examined and identified as NXG. While the patient was un-

dergoing evaluation for these lesions he experienced three episodes of generalized tonic-clonic seizures.

*Examination.* A physical examination revealed multiple nodules measuring 1 to 1.5 cm, particularly concentrated in the periorbital region and also over the neck, posterior axillary folds, flexor aspect of the right arm and forearm, left upper limb, and left foot. He also had a saddle nose, gynecomastia, and loss of all body hair. The neurological evaluation revealed a minimal right-upper motor facial paresis but no other deficits. Indirect laryngoscopy revealed the epiglottis to be deformed and shrunken. The arytenoids were congested but the vocal cords were seen to be normal and mobile. The glottic airway was normal.

Routine laboratory investigations revealed a total leukocyte count of 4600/ml and an erythrocyte sedimentation rate of 72 mm at the end of 1 hour. The results of liver function tests and levels of total protein, albumin, cholesterol, triglycerides, and blood glucose were all normal. The results of serum electrophoresis and a bone scan were also normal.

A contrast-enhanced CT scan of the brain showed a homogeneously contrast-enhancing, dura-based bifrontal mass lesion (Fig. 1). There was no perilesional edema and a minimal mass effect. The rest of the brain parenchyma appeared normal.

*Preoperative Treatment and Operation.* Before surgery, the patient was given oral chlorambucil (2.5 mg, 5 days a week) because the skin biopsy sample had been determined to be NXG. The patient was examined 4 months later, at which time the size of the nodules around his eyes, neck,

Abbreviations used in this paper: CNS = central nervous system; CT = computerized tomography; NXG = necrobiotic xanthogranuloma.

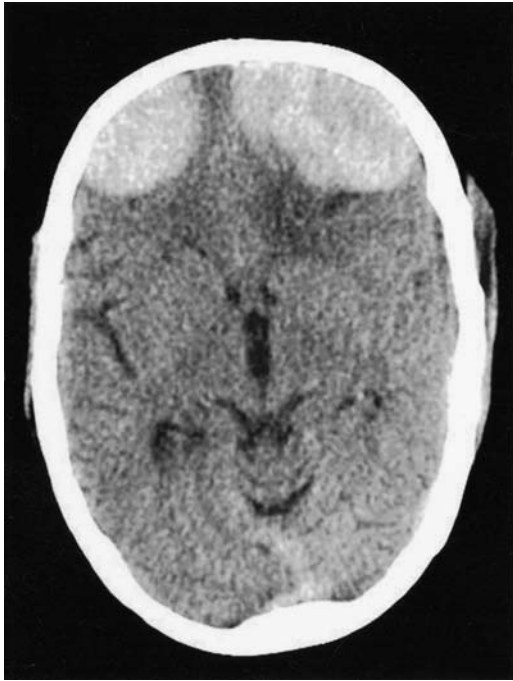

FIG. 1. Contrast-enhanced axial CT scan of the brain revealing a well-defined, homogeneously contrast enhancing, dura-based lesion located in the bilateral frontobasal region.

and posterior axillary folds had decreased by 20 to 30%. It was at this time that he experienced the seizures. The CT scan revealed a large bifrontal mass lesion and, therefore, the patient underwent a bifrontal craniotomy and total excision of the lesions.

The tumor was yellowish, lobulated, firm, avascular, and attached to the dura mater. There was a good interface between the tumor and brain, and the lesion was totally excised.

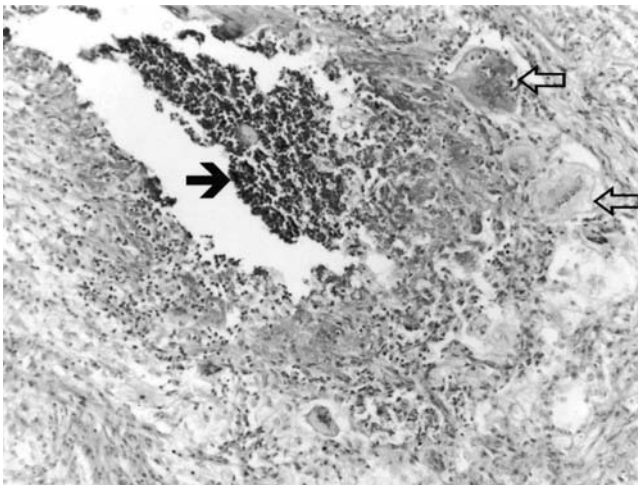

FIG. 2. Photomicrograph of subcutaneous tissue showing focal necrosis (solid arrow) with neutrophils bordered by histiocytes admixed with Touton giant cells (open arrows). H & E, original magnification  $\times 90$ .

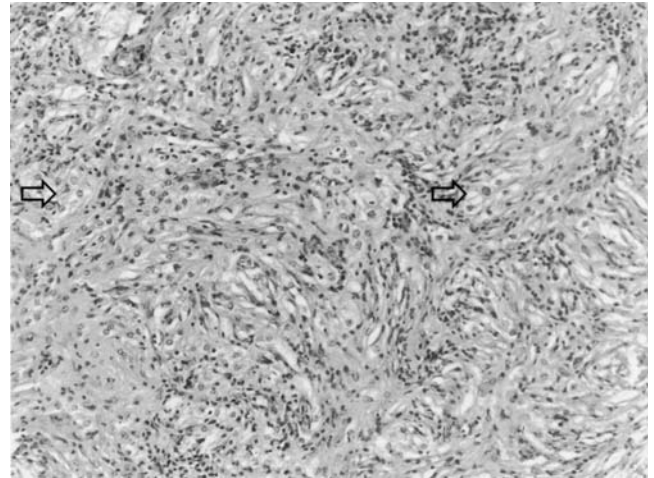


FIG. 3. Photomicrograph of the intracranial lesion showing slender spindle cells interspersed with foam cells (arrows). A small collection of lymphocytes, plasma cells, and eosinophils is present. H & E, original magnification  $\times 90$ .

**Postoperative Course.** The postoperative period was uneventful and there was good wound healing. The patient was discharged from the hospital with the advice to resume treatment with chlorambucil. Three months following surgery, he experienced a progressive difficulty in breathing because of laryngeal cicatrization; a tracheostomy was performed. At the time of the last follow-up examination 6 months after surgery, lesions all over the patient's body had regressed by 80 to 90%. At that time the regimen of chlorambucil was stopped and he was advised to schedule regular follow-up examinations at 6-month intervals.

**Pathological Findings.** The biopsy samples of skin and subcutaneous tissue from the axilla and those of soft tissue from the cervical region revealed lesions composed of sheets and nodules of foamy macrophages. Focal incipient necrosis with neutrophils bordered by histiocytes admixed with Touton and foreign body-type giant cells were present (Fig. 2). Aggregates of lymphoid cells and a scattering of eosinophils, neutrophils, and lymphocytes were seen in the lesions.

Histological investigation of the intracranial lesion (Fig. 3) demonstrated sheets of uniform slender spindle cells arranged in a storiform pattern against a collagenous background. These spindle cells expressed vimentin, but not epithelial membrane antigen or CD34. Interspersed within these sheets of spindle cells were lymphocytes, plasma cells, and eosinophils, which in areas tended to be perivascular. Also present in many places were sheets of CD68-positive foam cells. There were lymphoid follicles. Occasional multinucleated giant cells were present. Special stains for fungi and acid-fast bacilli were negative.

## Discussion

Juvenile xanthogranulomatous tumors of the CNS are uncommon and, when present, the most common location is the choroid plexus of the third and lateral ventricles.<sup>1,11-13,19-21,25-27</sup> A variant of these xanthogranulomas, seen in adults,

## Necrobiotic xanthogranuloma with a cerebral manifestation

is called NXG. The first case of NXG with paraproteinemia was reported by Kossard and Winkelmann<sup>14</sup> in 1980. Since then several additional cases of NXG have been reported.<sup>5,7,24</sup>

This is a progressive and destructive disease that is associated with paraproteinemia (in 80% of cases), multiple organ involvement, and an increased risk for hematological and lymphoproliferative malignancy.<sup>6,9,10,22</sup> In a review of 48 cases, Mehregan and Winkelmann<sup>18</sup> described eight patients with multiple myeloma, two with lymphoproliferative disorder, and nine with plasmacytosis or a plasmaproliferative disorder. The time to emergence of hematological malignancies varied from 8 years before to 11 years after the development of skin lesions. Patients with NXG require a lifelong follow up. Systemic diseases such as asthma have also been described in association with NXG.

Most histological features of the lesion are found from the middle dermis through the panniculus. The granulomas consist of sheets of histiocytes, giant cells of both the Touton and foreign-body types, and a few lymphocytes. Large zones of necrobiosis are characteristically seen. Cholesterol clefts, lymphoid nodules with or without germinal centers, and foci of plasma cells are variable but significant. Electron microscopy in three cases revealed lipid vacuoles in macrophages in the dermis and dendritic cells in the epidermis, and the study confirmed this disease entity to be a non-Langerhans cell histiocytosis.

The differential diagnosis of NXG includes necrobiosis lipoidica, juvenile xanthogranuloma, foreign-body granuloma, and primary and secondary amyloidosis.

Various hypotheses have been proposed to explain the pathophysiology of NXG. One hypothesis is based on a patient with NXG and multiple myeloma, in whom an immunoglobulin G kappa monoclonal protein was identified in serum, urine, bone marrow, and bilateral periorbital lesions. It has been speculated that increased serum immunoglobulins complexed with lipid are deposited into the skin, leading to a foreign-body giant cell reaction and subsequent, characteristic histopathological features of NXG.<sup>2</sup> Another group observed a case of NXG with severe hypocholesterolemia and analyzed the function of monocytes in that case. Histological examinations performed using light microscopy revealed a large amount of lipid deposition in the patient's freshly isolated monocytes. These monocytes showed a threefold increase in cholesteryl ester content and a threefold enhancement of acetyl low-density lipoprotein uptake compared with control monocytes. In addition, the phagocytotic ability of the patient's monocytes was enhanced 1.5-fold compared with that of control monocytes. These findings indicate that activated monocytes may have degraded the modified low-density lipoprotein via an alternate pathway and accumulated a great amount of lipids in vivo. The authors, therefore, concluded that activation of monocytes in vivo may contribute to the intracellular accumulation of lipoprotein-derived lipids, leading to noninherited xanthomatosis and marked hypocholesterolemia.<sup>17</sup>

The treatment options are many; some authors have reported that low-dose chlorambucil has been used successfully,<sup>16</sup> whereas others have used oral steroids with good results.<sup>4</sup> There have also been reports of studies in which patients have been treated with recombinant interferon  $\alpha$ -2b<sup>28</sup> or with plasmapheresis.<sup>8</sup> There are no clear-cut guidelines of how to treat this rare disorder, and trials of

various treatment modalities with appropriate follow up to assess the response would be the best option.<sup>3</sup>

### Conclusions

Necrobiotic xanthogranuloma is a rare disorder; in 80% of cases it is associated with paraproteinemia, although in our case there was no such association. Lesions are predominantly located in the periorbital area, as in our patient. We report the first case of a CNS lesion in a patient with NXG. Treatment consisted of excision of the intracranial lesion followed by a regimen of chlorambucil. These patients require regularly scheduled follow-up examinations.

### References

1. Bruck W, Sander U, Blackenberg P, et al: Symptomatic xanthogranuloma of choroid plexus with unilateral hydrocephalus. Case report. **J Neurosurg** 75:324-327, 1991
2. Bullock JD, Bartley GB, Campbell RJ, et al: Necrobiotic xanthogranuloma with paraproteinemia. Case report and a pathogenetic theory. **Ophthalmology** 93:1233-1236, 1986
3. Char DH, LeBoit PE, Ljung BM, et al: Radiation therapy for ocular necrobiotic xanthogranuloma. **Arch Ophthalmol** 105:174-175, 1987
4. Chave TA, Chowdhury MM, Holt PJ: Recalcitrant necrobiotic xanthogranuloma responding to pulsed high-dose oral dexamethasone plus maintenance therapy with oral prednisolone. **Br J Dermatol** 144:158-161, 2001
5. Codere F, Lee RD, Anderson RL: Necrobiotic xanthogranuloma of the eyelid. **Arch Ophthalmol** 101:60-63, 1983
6. Dupre A, Viraben R: Necrobiotic xanthogranuloma: a case without paraproteinemia but with transepithelial elimination. **J Cutan Pathol** 15:116-119, 1988
7. Finan MC, Winkelmann RK: Necrobiotic xanthogranuloma with paraproteinemia. A review of 22 cases. **Medicine** 65:376-388, 1986
8. Finelli LG, Ratz JL: Plasmapheresis: a treatment modality for necrobiotic xanthogranuloma. **J Am Acad Dermatol** 17:351-354, 1987
9. Fortson JS, Schroeter AL: Necrobiotic xanthogranuloma with IgA paraproteinemia and extracutaneous involvement. **Am J Dermatopathol** 12:579-584, 1990
10. Furner BB, Stevens CS: Diffuse ulcerating plaques and nodules. Necrobiotic xanthogranuloma (NXG) with paraproteinemia. **Arch Dermatol** 125:287-290, 1989
11. Gherardi R, Nguyen JP, Gaston A, et al: Symptomatic xanthogranuloma of the third ventricle: a clinicopathological report. **Eur Neurol** 23:156-162, 1984
12. Handagoon P, Pitakdamrongwong N, Shuangshoti S: Xanthogranulomas of the choroid plexus. **Neuroradiology** 29:172-173, 1987
13. Jaer O, Loken AC, Nesbakken R: Hydrocephalus due to xanthogranuloma. Case report. **J Neurosurg** 39:659-661, 1973
14. Kossard S, Winkelmann RK: Necrobiotic xanthogranuloma. **Australas J Dermatol** 21:85-88, 1980
15. Macfarlane AW, Verbov JL: Necrobiotic xanthogranuloma with paraproteinaemia. **Br J Dermatol** 113:339-343, 1985
16. Machado S, Alves R, Lima M, et al: Cutaneous necrobiotic xanthogranuloma (NXG)—successfully treated with low dose chlorambucil. **Eur J Dermatol** 11:458-462, 2001
17. Matsuura F, Yamashita S, Hirano K, et al: Activation of monocytes in vivo causes intracellular accumulation of lipoprotein-derived lipids and marked hypocholesterolemia—a possible pathogenesis of necrobiotic xanthogranuloma. **Atherosclerosis** 142:355-365, 1999

18. Mehregan DA, Winkelmann RK: Necrobiotic xanthogranuloma. **Arch Dermatol** **128**:94–100, 1992
19. Montaldi S, Deruaz JP, Cai ZT, et al: Symptomatic xanthogranuloma of the third ventricle: report of two cases and review of the literature. **Surg Neurol** **32**:200–205, 1989
20. Morello A, Campesi G, Bettinazzi N, et al: Neoplastiform xanthomatous granuloma of choroid plexus in a child affected by Hand-Schuller-Christian disease. Case report. **J Neurosurg** **26**: 536–541, 1967
21. Razavi-Encha F, Gray F, Gaston A, et al: Symptomatic xanthogranuloma of the choroid plexus of the third ventricle. A new case with ultrastructural study. **Surg Neurol** **27**:569–574, 1987
22. Reeder CB, Connolly SM, Winkelmann RK: The evolution of Hodgkin's disease and necrobiotic xanthogranuloma syndrome. **Mayo Clin Proc** **66**:1222–1224, 1991
23. Robertson DM, Winkelmann RK: Ophthalmic features of necrobiotic xanthogranuloma with paraproteinemia. **Am J Ophthalmol** **97**:173–183, 1984
24. Rose GE, Patel BC, Garder A, et al: Orbital xanthogranuloma in adults. **Br J Ophthalmol** **75**:680–684, 1991
25. Rush JL, Kusske JA, Porter RW, et al: Xanthogranulomas of the third ventricle. **Neurosurgery** **4**:329–333, 1979
26. Shuangshoti S, Netsky MG: Xanthogranuloma (xanthoma) of choroid plexus. The origin of foamy (xanthoma) cells. **Am J Pathol** **48**:503–533, 1966
27. Vaquero J, Leunda G, Cabezudo JM, et al: Posterior fossa xanthogranuloma. Case report. **J Neurosurg** **51**:718–722, 1979
28. Venencie PY, Le Bras P, Toan ND, et al: Recombinant interferon alfa-2b treatment of necrobiotic xanthogranuloma with paraproteinemia. **J Am Acad Dermatol** **32**:666–667, 1995

---

Manuscript received July 21, 2003.

Accepted in final form February 11, 2004.

*Address reprint requests to:* Vedantam Rajshekhar, M.Ch., Department of Neurological Sciences, Christian Medical College Hospital, Vellore 632004, India. email: rajshekhar@cmcvellore.ac.in.